

A case of short-root anomaly in a female from medieval Istria

Šikanjić, P. Rajić; Meštrović, S.

Source / Izvornik: **International Journal of Osteoarchaeology, 2006, 16, 177 - 180**

Journal article, Published version

Rad u časopisu, Objavljena verzija rada (izdavačev PDF)

<https://doi.org/10.1002/oa.825>

Permanent link / Trajna poveznica: <https://um.nsk.hr/um:nbn:hr:127:895468>

Rights / Prava: [In copyright](#) / [Zaštićeno autorskim pravom.](#)

Download date / Datum preuzimanja: **2025-01-02**



Repository / Repozitorij:

[University of Zagreb School of Dental Medicine
Repository](#)



SHORT COMMUNICATION

A Case of Short-root Anomaly in a Female from Medieval Istria

P. RAJIĆ ŠIKANJIĆ^{a*} AND S. MEŠTROVIĆ^b

^a Institute for Anthropological Research, Amruševa 8, 10 000 Zagreb, Croatia

^b Department of Orthodontics, School of Dental Medicine, University of Zagreb, Zagreb, Croatia

ABSTRACT Dental examination of a young female skeleton from medieval Istria revealed very short-roots of both maxillary central incisors. This developmental pathological condition is known in the literature as short-root anomaly, occurring mostly in maxillary incisors. In affected teeth, the crown:root ratio is 1:1.6. Although the prevalence of this condition has been reported in modern populations, this appears to be the first documented case of the anomaly from the medieval period. Unfortunately, fragmentary preservation of the skeletal material prevents us from making a full diagnosis of possible aetiology. Copyright © 2006 John Wiley & Sons, Ltd.

Key words: tooth abnormalities; root shape; female; Middle Ages; Istria

Introduction

Almost 40 years ago, in 1966, remains of an early medieval Slav cemetery were discovered next to the chapel of St. Lovro at Ferenci in northwestern Istria (Croatia). The excavation was led by B. Marušić of the Archaeological Museum of Istria, Pula. Results of that excavation remain unpublished, and the available documentation is incomplete. The excavator dated the cemetery to the 11th century, based on archaeological finds from the graves and general characteristics of the burials (Marušić, 1995). These burials provide an example of a new type of cemetery, located around the newly built churches, which emerged after the end of the 10th century, when christianisation of Slavs was completed (Marušić, 1995).

Recently, we analysed the available skeletal material from the cemetery. Apparently, only the

better preserved skulls were kept, while the rest of the skeletal material had been discarded. Our sample consisted of six incomplete skulls, all from single inhumations. Although the bones were in a rather poor state of preservation, a full osteological report was written. During the osteological examination a dental developmental pathological condition—short-root anomaly—was recognised on the skeleton from grave number 10. The aim of this paper is to present this example of dental anomaly found in an individual from a medieval cemetery in Istria.

The material

The skeleton involved is incomplete and consists of a fragmented skull, two parts of the mandible and a small part of maxilla. Based on the morphology of the skull and mandible, the individual is a female (Ferembach *et al.*, 1980; Schwartz, 1995). The cranial suture closure (Meindl & Lovejoy, 1985) and slight attrition on the teeth

* Correspondence to: Institute for Anthropological Research, Amruševa 8, 10 000 Zagreb, Croatia.
e-mail: petra@inantro.hr

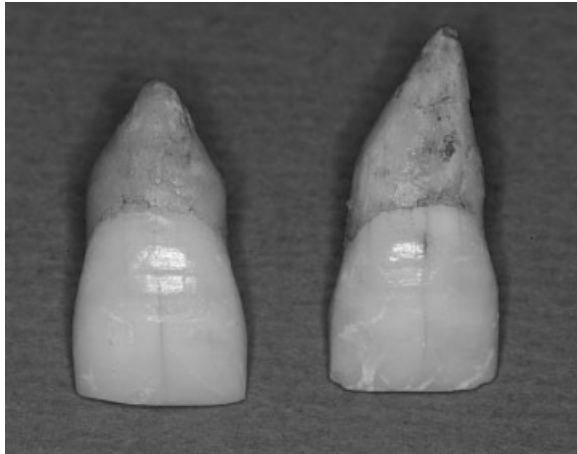


Figure 1. The maxillary central incisors with very short, blunt roots.

(Brothwell, 1981; Lovejoy, 1985) suggest that she was in her mid 20s.

A detailed dental inventory shows that only two broken parts of the left and right mandible have survived, while premolars, molars, right

canine and both left incisors are present without the associated alveolar bone. Only a small part of the left maxillary alveolar bone containing the second molar has been preserved. Maxillary central incisors, all four premolars and the left first molar are present, but without the associated alveolar bone. All present teeth, both in the mandible and the maxilla, show slight attrition. Two small interproximal carious lesions were noted, one on the lower right first molar and the other on the upper left first molar. There is no evidence of enamel hypoplasia or of an alveolar abscess.

During the examination, a dental developmental pathological condition was recognised on both maxillary central incisors (Figure 1). The affected teeth have a normal crown shape and size, but very short, blunt roots. The measured crown:root ratio is 1:1.5. A macroscopic inspection of teeth shows that—besides those unusual root forms—there is no evidence of other abnormalities or disturbances (Figure 2). This condition, occurring mostly in maxillary incisors, is known in the literature as short-root anomaly.

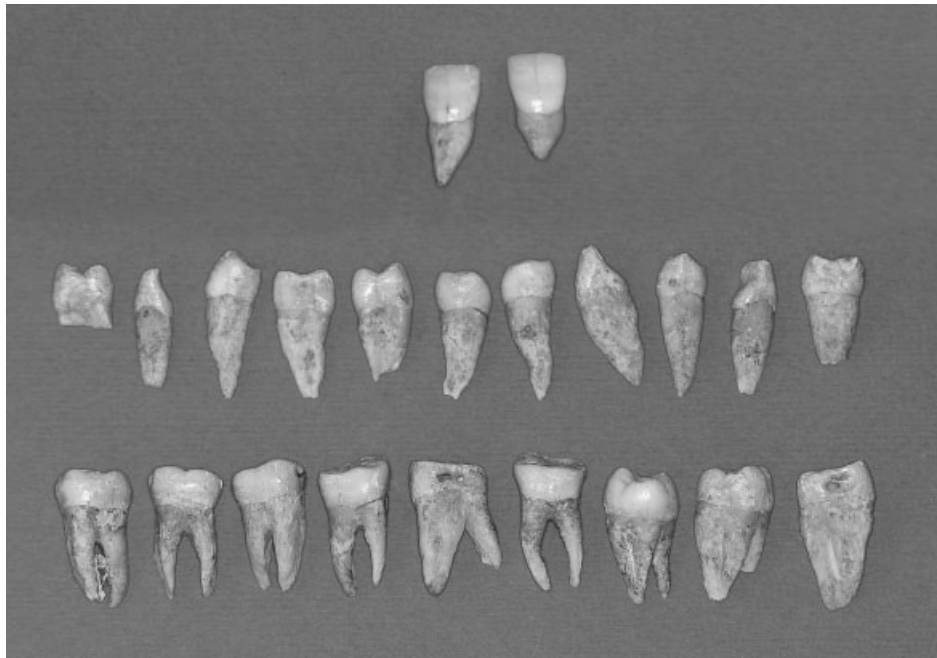


Figure 2. The maxillary central incisors compared with other teeth from the same individual.

Discussion

Short-root anomaly (SRA) in maxillary central incisors has been described as short roots whose crown:root ratio exceeds 1:1.6 (Lind, 1972). Assessment of ratios has been shown to be less variable than absolute measurement (Brook & Holt, 1978). The prevalence of isolated short-rooted maxillary central incisors has been reported to be 2.4% to 2.7% in Caucasians (Jakobsson & Lind, 1973; Brook & Holt, 1978), while in Mongolian populations it is 10% (Ando *et al.*, 1967). In contrast, generalised root shortening, a phenomenon in which almost all the permanent teeth are markedly shorter than normal, is a very rare finding with only two cases reported (Edwards & Roberts, 1990).

The pathogenesis of this condition is still uncertain and there are several possible explanations. Some authors explain the aetiology of the condition by local factors such as trauma and resorption due to severe stress (Apajalahti *et al.*, 2002). Research on parents and children from the same family has shown that the condition also has familial occurrence, and an autosomal dominant pattern of inheritance has been suggested (Lind, 1972; Lerman & Gold, 1977; Edwards & Roberts, 1990). Apajalahti *et al.* (2002) reported that the prevalence of genetic short-root anomaly in healthy Finnish young adults is close to 1.3%, affecting females significantly more often, and with a predisposition for the maxillary incisors and premolars as well as mandibular second premolars to be affected.

According to Apajalahti *et al.* (2002), some types of environmental insults during tooth development may result in cessation of root development. Short-root anomaly can also appear after chemotherapy for childhood malignancies in the craniofacial region (Jaffe *et al.*, 1984; Sonis *et al.*, 1990) and in total body irradiation (Näsman *et al.*, 1997). The root shortening has also been observed in individuals with disorders such as scleroderma (Foster & Fairburn, 1968), Stevens-Johnson syndrome (Thornton & Worley, 1991), Down syndrome (Prah Andersen & Oerlemans, 1976), Laurence-Moon-Bardet-Biedl syndrome (Borgström *et al.*, 1996), Aarskog syndrome (Aarskog, 1970) and dwarfism (Tsuchiya *et al.*, 1981). Some authors associate

shortness of the roots with other dental anomalies, such as tooth agenesis (Brook & Holt, 1978; Edwards & Roberts, 1990), *dens invaginatus* (Edwards & Roberts, 1990), supernumerary teeth (Lerman & Gold, 1977) and generalised microdontia (Brook & Holt, 1978; Edwards & Roberts, 1990).

As noted previously, short-root anomaly occurs mostly in maxillary incisors. This is also true in the case of the young female from Istria. Because of the nature of the material (dry bone) and its fragmentary state, we could not determine a possible aetiology of the condition. The shortness of the roots of both maxillary central incisors is the only observed pathological condition on the teeth and the preserved fragments of the skull. The cranial bones present seem to belong to a healthy individual and do not suggest association of the anomaly with the aforementioned disorders and syndromes. Chemotherapy as a possible cause of the anomaly can also be excluded, considering the time period of the sample. Unfortunately, because of the poor state of preservation of the skeletal material from the site and small sample size, we were not able to search for possible familial occurrence, which is sometimes observed in modern populations.

Conclusion

To the best of our knowledge, this is the first documented case of short-root anomaly from an archaeological context. Consequently, we can compare it only with the documented cases in modern populations. Even in such populations, the number of recognised cases is relatively low, possibly due to the fact that the condition is easily overlooked or misdiagnosed.

Since the aetiology of short-root anomaly in modern populations is not yet defined, we are not in the position to propose a differential diagnosis for this isolated archaeological case. Some of the mentioned possible causes, such as chemotherapy or modern environmental factors, cannot apply by default. Poor preservation of skeletal material and small sample size prevented us from searching for any familial occurrence. It is clear that better understanding of the

anomaly in modern populations is a prerequisite for the study of this condition in archaeological populations.

Acknowledgements

This research was supported by the Ministry of Science and Technology of the Republic of Croatia (project 0196004, 0065013).

Reference

- Aarskog D. 1970. A familial syndrome of short stature associated with facial dysplasia and genital anomalies. *Journal of Pediatrics* **77**: 856–861.
- Ando S, Kiyokawa K, Nakashima T, Shinbo K, Sanaka Y, Oshima S, Aizawa K. 1967. Studies on the consecutive survey of succadaneous and permanent dentition in the Japanese children. *Journal of Nihon University School of Dentistry* **9**: 67–80.
- Apajalahti S, Holttä P, Turtola L, Pirinen S. 2002. Prevalence of short-root anomaly in healthy young adults. *Acta Odontologica Scandinavica* **60**: 56–59.
- Borgström MK, Riise R, Törnqvist K, Granath L. 1996. Anomalies in the permanent dentition and other oral findings in 29 individuals with Laurence-Moon-Bardet-Biedl syndrome. *Journal of Oral Pathology and Medicine* **25**: 86–89.
- Brook AH, Holt RD. 1978. The relationship of crown length to root length in permanent maxillary central incisor. *Proceedings of British Paedodontic Society* **8**: 17–20.
- Brothwell DR. 1981. *Digging up Bones* (3rd edn). British Museum of Natural History: London.
- Edwards DM, Roberts GJ. 1990. Short root anomaly. *British Dental Journal* **169**: 292–293.
- Ferembach D, Schwidetzky I, Stluokal M. 1980. Recommendation for age and sex diagnosis of skeletons. *Journal of Human Evolution* **9**: 517–549.
- Foster TD, Fairburn EA. 1968. Dental involvement in scleroderma. *British Dental Journal* **124**: 353–356.
- Jaffe N, Toth BB, Hoar RE, Ried HL, Sullivan MP, McNeese MD. 1984. Dental and maxillofacial abnormalities in long-term survivors of childhood cancer: effects of treatment with chemotherapy and radiation to the head and neck. *Pediatrics* **73**: 816–823.
- Jakobsson R, Lind V. 1973. Variations in root length of the permanent maxillary central incisors. *Scandinavian Journal of Dental Research* **81**: 335–338.
- Lerman RL, Gold R. 1977. Idiopathic short root anomaly. *Journal of Pedodontics* **1**: 327–333.
- Lind V. 1972. Short root anomaly. *Scandinavian Journal of Dental Research* **80**: 85–93.
- Lovejoy CO. 1985. Dental wear in the Libbean population: its functional pattern and role in the determination of adult skeletal age at death. *American Journal of Physical Anthropology* **68**: 47–56.
- Marušić B. 1995. *Istra i sjevernojadranski prostor u ranom srednjem vijeku*. Monografije i katalogi 4, Arheoloski muzej Istra: Pula.
- Meindl RS, Lovejoy CO. 1985. Ectocranial suture closure: a revised method for the determination of skeletal age at death based on the lateral-anterior Sutures. *American Journal of Physical Anthropology* **68**: 57–66.
- Näsman M, Forsberg CM, Dahllöf G. 1997. Long-term dental development in children after treatment for malignant disease. *European Journal of Orthodontics* **19**: 151–159.
- Prahl-Anderson B, Oerlemans J. 1976. Characteristics of permanent teeth in persons with trisomy. *Journal of Dental Research* **55**: 633–638.
- Schwartz JH. 1995. *Skeleton Keys*. Oxford University Press: Oxford.
- Sonis AL, Tarbel N, Valachovich RW, Gelber R, Schwenn M, Sallan S. 1990. Dentofacial development in long-term survivors of acute lymphoblastic leukaemia. A comparison of three treatment modalities. *Cancer* **66**: 2645–2652.
- Thornton JB, Worley AR. 1991. Short root anomaly in a patient with a history of Stevens-Johnson syndrome: report of case. *Journal of Dentistry for Children* **58**: 256–259.
- Tsuchiya H, Kobayashi S, Cervenka J, Mori H, Ogurno A. 1981. Analysis of the dentition and orofacial skeleton in Seckel's birdheaded dwarfism. *Journal of Maxillofacial Surgery* **9**: 170–175.