

Prevalence of mandibular osteomyelitis in roe deer (capreolus capreolus) in Slovenia

Konjević, Dean; Jelenko, Ida; Severin, Krešimir; Poličnik, Helena; Janicki, Zdravko; Slavica, Alen; Njemirovskij, Vera; Stanin, Damir; Pokorny, Boštjan

Source / Izvornik: **Journal of Wildlife Diseases, 2011, 47, 393 - 400**

Journal article, Published version

Rad u časopisu, Objavljena verzija rada (izdavačev PDF)

<https://doi.org/10.7589/0090-3558-47.2.393>

Permanent link / Trajna poveznica: <https://urn.nsk.hr/urn:nbn:hr:127:786266>

Rights / Prava: [In copyright](#) / [Zaštićeno autorskim pravom.](#)

Download date / Datum preuzimanja: **2025-01-01**



Repository / Repozitorij:

[University of Zagreb School of Dental Medicine
Repository](#)



PREVALENCE OF MANDIBULAR OSTEOMYELITIS IN ROE DEER (*CAPREOLUS CAPREOLUS*) IN SLOVENIA

Dean Konjević,¹ Ida Jelenko,² Krešimir Severin,³ Helena Poličnik,² Zdravko Janicki,¹
Alen Slavica,^{1,6} Vera Njemirovskij,⁴ Damir Stanin,⁵ and Boštjan Pokornj²

¹ Department for Game Biology, Pathology and Breeding, University of Zagreb Veterinary Faculty, Heinzelova 55, 10 000 Zagreb, Croatia

² ERICo Velenje, Ecological Research and Industrial Cooperation, Koroška 58, 3320 Velenje, Slovenia

³ Department of Forensics, University of Zagreb Veterinary Faculty, Heinzelova 55, 10 000 Zagreb, Croatia

⁴ Department of Anthropology, Dental School, University of Zagreb, Gundulićeva 5, 10 000 Zagreb, Croatia

⁵ Department of Radiology, Ultrasound Diagnostics and Physical Therapy, University of Zagreb Veterinary Faculty, Heinzelova 55, 10 000 Zagreb, Croatia

⁶ Corresponding author (email: slavica@vef.hr)

ABSTRACT: Mandibular osteomyelitis in free-ranging cervids is a rare, but eventually fatal, disease. We examined 41,895 defleshed mandibles of roe deer collected throughout Slovenia in 2007. Mandibles from 14,679 fawns had no signs of osteomyelitis, and were excluded from further analysis. Of the remaining 27,216 specimens, chronic osteomyelitis (“lumpy jaw”) was found in 113 mandibles (4.2%; 7.0% of adults). The majority of cases were observed from the Mediterranean and subalpine regions, near larger cities and thermal power plants. There was no statistically significant correlation between severity of the mandibular osteomyelitis and body weight. Females were more frequently affected than males. Coarse and abrasive food, and to some extent dental fluorosis, are the most probable triggers for development of lesions.

Key words: *Capreolus capreolus*, epidemiology, fluorosis, geographic, lumpy jaw, mandibular osteomyelitis, roe deer, Slovenia.

INTRODUCTION

Most confirmed cases of chronic pyo-granulomatous osteomyelitis of the mandibula (less commonly the maxilla) in domestic cattle and sheep are caused by bacteria of the genus *Actinomyces*. Other causes of the disease may include *Arcanobacterium* (formerly *Corynebacterium*) *pyogenes* and *Fusobacterium necrophorum* (Wobeser, 2001). Although *Actinomyces bovis* is the most commonly reported etiologic agent, multiple infectious agents have been reported as causes of mandibular osteomyelitis (Roeder et al., 1989; Carter and Wise, 2004). Carek et al. (2001) reported that, in humans, infections from multiple etiologic agents are the rule rather than exception. Thus, bacteriologic analyses are generally required prior to final diagnosis.

Although infections are mainly localized in bone or parenchymal organs, generalized infections have been described (Turnquist and Fales, 1998). “Lumpy jaw” is a frequently used descriptive but nonspecific term for chronic mandibular

osteomyelitis with bone remodeling that sometimes includes surrounding soft tissue cellulitis, causing a visible facial contour disturbance. The term does not explain the underlying etiology or pathogenesis, and may include mandibular or dental anomalies with or without osteomyelitis. Chronic inflammation of the maxillar or mandibular bone appears initially in the form of small nodules composed of centrally located bacteria surrounded by leukocytes, fibroblasts, plasma cells, giant cells, and connective tissue (Cvetnić, 2002). The presence of bacteria, leucocytes, and suppurative processes results in the formation of pus and, with time, leads to the formation of fistulae. The spread of the infection throughout the bone with bone lysis and remodeling leads to the formation of expanding, pus-filled cavities resulting in a characteristic macroscopic appearance of the affected region. The bone pathology may also be associated with diffuse soft-tissue cellulitis, which may be distant from the area where the bacteria entered the soft tissues (Fagan et al., 2005). In the

initial stage there are no obvious clinical signs; however, in the chronic event, the effects of the processes with damaged alveolar bone and displaced teeth are painful and may disturb mastication (Cvetnić, 2002) and lead to death (Aguirre et al., 1999; Mainar-Jamie et al., 2007).

Among wild ungulates, lumpy jaw-like and other suppurative lesions caused by bacteria of the *Actinomyces* and *Arcanobacterium* genera have been reported in white-tailed deer (*Odocoileus virginianus*; Rosen and Holden, 1961; Howe, 1981; Davidson et al., 1990; Mainar-Jaime et al., 2007), moose (*Alces alces*; Howe, 1981), European reindeer (*Rangifer tarandus*; Leader-Williams, 1980), wild sheep (*Ovis* spp.; Hoefs and Bunch, 2001), pronghorn (*Antilocapra americana*; Howe, 1981), blue duiker (*Philantomba monticola*; Roeder et al., 1989), Alpine ibex (*Capra ibex*; Fagan et al., 2005), and chamois (*Rupicapra rupicapra*; Radaelli et al., 2007). For roe deer (*Capreolus capreolus*), lumpy jaw may represent an important cause of mortality (0.6% of 985 samples; Aguirre et al., 1999). However, the majority of previous reports on the presence of lumpy jaw or chronic mandibular osteomyelitis in free-ranging ungulates are incidental, and systematic surveys of the prevalence and spatial distribution of the disease are scarce. In addition, there is a lack of data on the influence of environmental factors on the prevalence of mandibular osteomyelitis in free-ranging ungulates, as well as the influence of the disease on the health of individuals and populations.

In Slovenia, mandibles from all free-ranging ungulates shot during the hunting season or killed for any other reason (e.g., road mortality, predation, disease) are collected for management and control purposes. Annually, mandibles from about 40,000–45,000 roe deer, 5,000–7,000 red deer (*Cervus elaphus*), 8,000–10,000 wild boar (*Sus scrofa*), and 100–200 fallow deer (*Dama dama*) and mouflons (*Ovis ammon*)

musimon) are collected. The research potential of this collection has not been explored. Our aims were to 1) define the prevalence of mandibular osteomyelitis in roe deer mandibles collected throughout Slovenia in 2007, 2) plot the spatial distribution of mandibular osteomyelitis in roe deer in Slovenia, and 3) compare the frequency of mandibular osteomyelitis in roe deer by sex and age class.

MATERIALS AND METHODS

In total, 41,895 mandibles from roe deer were collected throughout Slovenia in 2007 during the annual inspection of the hunting management areas. All mandibles were used as part of various biomonitoring and dental pathology studies. Following Slovenian legislation, usually only the left side of the mandible was collected; in cases when chronic osteomyelitic lesions were present on the right side, the complete mandible was submitted for study. Mandibles were boiled, defleshed, cleaned, dried, individually labeled, and stored in plastic bags.

Each sample was accompanied with data about origin and gender. Age was determined according to criteria of Wagenknecht (1984), and the animals were categorized as fawns (<1 yr), yearling (1 yr), young (2–4 yr), middle-aged (5–7 yr) and older adults (≥ 8 yr). Each mandible was thoroughly examined visually for the presence of bone and dental lesions. All mandibles with visible local extensive lesions indicative of lumpy jaw were separated and graded (1 to 5 in increasing order of severity) according to the macroscopic appearance and size of the affected area.

Mandibles were carefully inspected for any dental anomalies or pathologies, variations in size and shape, periodontal disease, and diseases and injuries of dentary bone. Mandibles were separated into groups by pathology type and by hunting management district (HMD). Criteria used to divide mandibular osteomyelitis according to the severity of lesion were size of the affected area, effect on the adjacent teeth, and destructive nature of the lesion. Some mandibles were subjected to radiographic analysis (settings 41 kV, 2.8 mA), using lateral and dorsoventral projections. Differences in the prevalence of bony lesions were compared among HMDs using chi-square (χ^2) tests using STATISTICA version 8.0 (Statsoft, Inc., Tulsa, Oklahoma, USA).

RESULTS

Visual inspection of roe deer mandibles revealed localized mandibular widening with periosteal new bone formation with characteristic cavitations and exostoses (Fig. 1), identified as mandibular osteomyelitis. X-ray analysis of selected mandibles showed, depending on the severity of lesions, shallow attachment of premolars and molars in their sockets (horizontal bone loss indicating periodontitis), and the creation of exostoses on the periosteum with characteristic irregular spongiform appearance of the mandible (Fig. 2).

Table 1 summarizes the prevalence of actinomycotic lesions in the mandibles of roe deer collected in Slovenia in 2007 by HMD. Of 41,854 samples, characteristic mandibular lesions were found only in yearlings and older age classes; 14,679 fawns were excluded from further analyses. Mandibular osteomyelitis was present in 113 of 27,216 remaining mandibles, representing 4.2% of all animals (including fawns) or 7.0% of adults.

Lesions were detected in samples from throughout Slovenia; the highest occurrence was in the sub-Mediterranean and alpine regions (Fig. 3). Western Slovenia had the highest prevalence of mandibular osteomyelitis. The areas with Mediterranean ecosystems appeared to have a higher prevalence than those HMDs with typical continental climates (e.g., Zahodno visoko kraško with a prevalence of 8.5% versus the northeastern Slovenia HMD Pomursko with a prevalence of 1.9%). However, a high prevalence of bony lesions was also recorded near a large aluminum plant (Kidričevo, northeastern Slovenia), near thermal power plants, and near larger cities (i.e., Kranj, Maribor; Fig. 3). Statistically significant differences in prevalence were found among HMDs: Gorenjsko vs. Novomeško ($\chi^2=4.906$; $P=0.02$), Primorsko vs. Pomursko ($\chi^2=4.957$; $P=0.02$), and Zahodno visoko kraško vs. Pomursko ($\chi^2=8.98$; $P=0.002$), Slovensko-Goriško ($\chi^2=5.18$;

$P=0.02$), Kočevsko-Belokranjsko ($\chi^2=3.95$; $P=0.04$), Posavsko ($\chi^2=4.65$; $P=0.03$), and Savinjsko-Kozjansko ($\chi^2=7.21$; $P=0.007$).

Most infected jaw bones were from young and middle-aged adults, followed by older adults. There was no apparent relationship of age and severity of mandibular lesions. Grade 1 ($n=56$) and 2 ($n=34$) lesions were most common. Overall, females appeared to be more frequently affected than males (Fig. 4). Eleven mandibles without data on location, sex, or weight were not included in Figure 4.

There was no clear relationship between the degree of lesion and average weight of the animals from different age classes; small sample sizes in some categories precluded making statistical comparisons.

DISCUSSION

The family Actinomycetaceae comprises five genera, of which *Actinomyces*, *Actinobaculum*, and *Arcanobacterium* are important in veterinary medicine (Naglić et al., 2005). The remaining two genera include *Varibaculum* and *Mobiluncus* (Schaal et al., 2006). Chronic pyogranulomatous osteomyelitis of the mandible, and less frequently the maxilla, can be caused by *Actinomyces bovis*, *Actinomyces israelii*, and *Actinomyces viscosus*. These microorganisms are a normal part of the oral flora in humans (Sutter, 1984) and other animals (Sørum and Sunde, 2001), and are found as commensals in the oral and nasal mucosa, on tooth surfaces, and in the digestive and genital system. Infections with these organisms are usually opportunistic and can occur as a result of injured mucosa, most frequently due to sharp bits of vegetation or food impaction in the periodontal area. Horizontal transmission of the infection may occur via bite wounds. One cause of injury to the oral mucosa is abrasives in food. Our results support these tenets in that majority of the

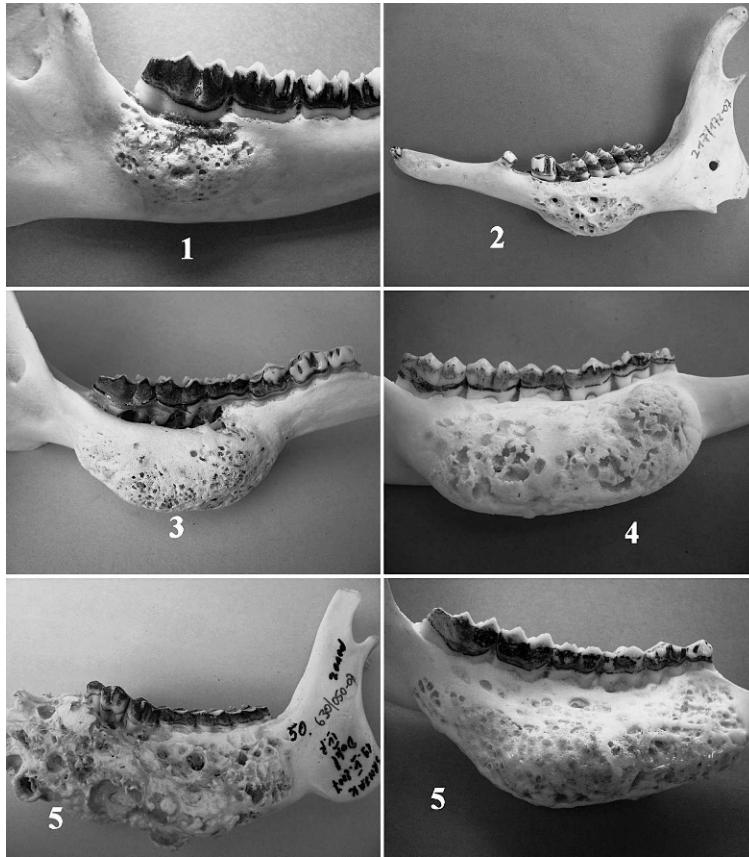


FIGURE 1. Roe deer mandibles. Characteristic external macroscopic appearance of mandibular osteomyelitis, sorted according to severity of lesions (1–5). (1) A circumscribed area of bone undergoing destruction and osteogenesis, thickening of mandible on the area of one or two teeth, normal contour of mandible preserved; (2) enlarged area of mandibular widening covering area of three teeth, loss of normal contour, moderate periodontitis; (3) gross thickening of mandible on area of four teeth, advanced periodontitis; periosteal reaction and bone widening along entire teeth row, marked cavities indicate position of pockets of pyogranulomatous exudates; (4) marked enlargement of the mandible involving the complete teeth row, advanced periodontitis; (5) two photographs showing excessive periosteal proliferation with necrosis and loss of bone affecting the complete body of the mandible; teeth are loose and misplaced, advanced periodontitis.

osteomyelitic samples were found in the sub-Mediterranean and alpine regions (Fig. 3). Both regions have karst habitats (landscape consisting of soluble bedrock of mainly calcium or magnesium carbonate with limited surface water due to subterranean drainage). Karst habitats are rich in abrasive sandy or gravel substances that are frequently ingested with plants, leading to increased tooth wear and an elevated risk of periodontal disease (Glaze et al., 1982).

Host factors that lead to increased

susceptibility of the periodontium to disease could also facilitate the spread of the bacteria to soft tissues and bone. Dental fluorosis with increased tooth wear is a possible explanation for the increased occurrence of actinomycosis. Dental fluorosis causes increased porosity of subsurface enamel due to fluoride-induced impairment of clearance, mainly of amelogenin, during enamel maturation. Severe fluorosis will result in rapid tooth wear. Schultz et al. (1998) described the enlargement of interdental gaps with rapid

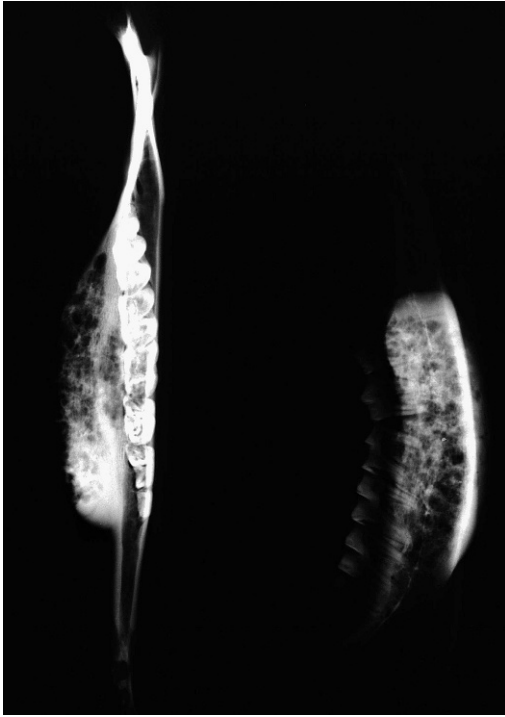


FIGURE 2. Radiographs of mandible affected by osteomyelitis, lateral and dorsoventral projections showing shallow attachments of premolars and characteristic spongiform appearance. Note osteolytic pattern with darker areas representing areas of bone lysis and formation of well-defined cavities surrounded by new and sclerotic bone that appears as lamellated, thin, radiolucent bands. The bone margin is ill defined. The remaining part of the mandible appears to be of normal density.

dental attrition in red deer with fluorosis. Gap creation was enhanced by periodontitis, horizontal bone loss, root exposure, and tooth fracture. In all these cases, injury to the gingiva by impaction of forage or sharp-edged crowns of the antagonist tooth could result in infection. The frequent mandibular osteomyelitis observed in hunting grounds around the aluminum smelter is likely the consequence of fluoride pollution, which causes moderate to severe dental fluorosis of roe deer in this region (Jelenko et al., 2010).

Disturbances of tooth eruption, such as persistent deciduous premolar and consequent difficult eruption of the permanent tooth, as observed in our study, can result

in a slight rotation of the erupting tooth and consequent enlargement of the interdental gap (D. Konjević, unpubl. data). This interdental area is larger for P4 and M1, where neighboring dental surfaces are small. These interdental areas are a predisposing factor for food packing and injuries of the soft tissues. Mandibular osteomyelitis may also result from dental abscess drainage and erosion into the alveolar bone, followed by spread of inflammation of the mandible and secondary abscess and sinus tract formation over the jaw. In addition, different forms of traumatic impact can result in contamination of the soft tissues with oral bacteria. In some cases, the cause may be a combination of these factors.

Similar to findings by Hoefs and Bunch (2001), we did not observe that actinomycosis increases with age of the animal in individuals with finalized teeth formation (adults). As most cases were young adults (ca. 2 yr), we speculate that one of the predisposing factors is the replacement of deciduous dentition, which, in roe deer, occurs at the age of 12–14 mo. Permanent molars erupt approximately at the ages of 2 mo, 6 mo, and 10 mo. The last deciduous tooth to be replaced is the three-cusped fourth premolar. The higher occurrence of mandibular osteomyelitis in young and middle-aged adults could explain the lower incidence in older deer, as actinomycosis is a slowly developing disease that takes several years to cause death. Therefore, the young animals that develop such mandibular lesions probably will not survive to an old age; in roe deer this may be an important mortality factor (Aguirre et al., 1999).

We observed a higher incidence of mandibular osteomyelitis in females. Hoefs and Bunch (2001) found the same sex-dependent distribution in wild sheep. As a possible explanation they gave sex-dependent differences in range use strategies; females, especially when accompanied by fawns, preferred secure familiar territories. Such territories support large

TABLE 1. Prevalence of mandibular osteomyelitis in different hunting management districts in roe deer (*Capreolus capreolus*) in Slovenia.

HMD ^a No.	HMD name	No. of mandibles ^b	Mandibular osteomyelitis (n; % in parentheses)
1	Novomeško	1,291	3 (2.3)
2	Gorenjsko	2,755	12 (4.4)
3	Kočevsko-Belokranjsko	1,752	6 (3.4)
4	Notranjsko	1,465	8 (5.5)
5	Primorsko	2,096	13 (6.2)
6	Pohorsko	2,247	11 (4.9)
7	Posavsko	1,674	5 (3.0)
8	Pomursko	2,136	4 (1.9)
9	Savinjsko-Kozjansko	2,807	8 (2.9)
10	Slovensko-Goriško	1,547	4 (2.6)
11	Triglavsko	941	4 (4.3)
12	Zahodno visoko kraško	1,999	17 (8.5)
13	Zasavsko	1,428	7 (4.9)
14	Kamniško-Savinjsko	1,263	4 (3.2)
15	Ptujsko-Ormoško	1,815	7 (3.9)
	Total	27,216	113 (4.2)

^a HMD = hunting management district.

^b The number of mandibles includes the total number of roe deer (excluding fawns), shot or found dead in specific HMD.

numbers of animals and, due to overgrazing and heavy use of the food resources, may contain scarce and less-palatable, coarse food. This hypothesis is not particularly applicable for roe deer in Slovenia

because these animals are territorial during periods of vegetative growth, living in small groups comprising mother and fawns (sometimes accompanied by female yearlings).

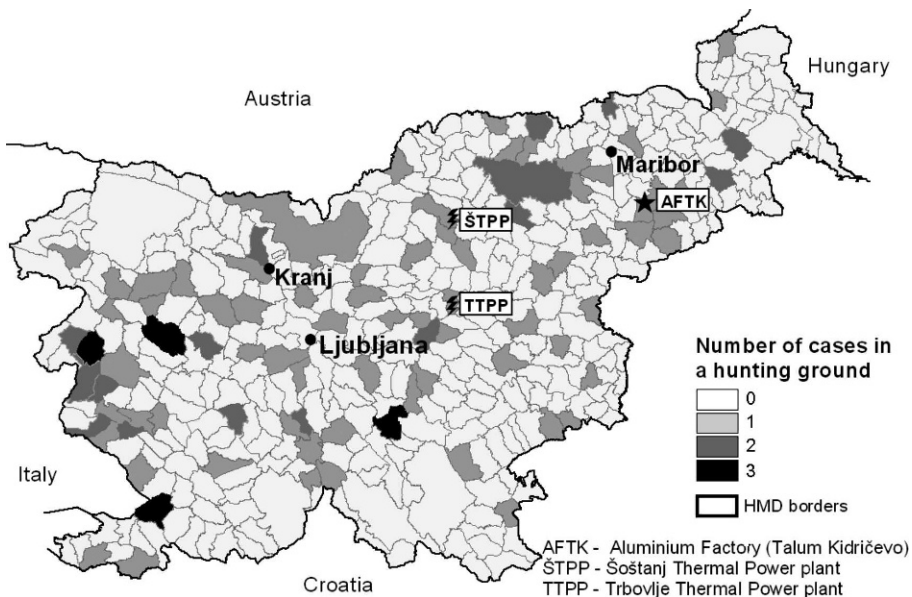


FIGURE 3. Distribution of mandibular osteomyelitis in roe deer, collected in hunting grounds of Slovenia in 2007. Numbers represent hunting management districts (Table 1). Note position of aluminium producer and thermal power plants.

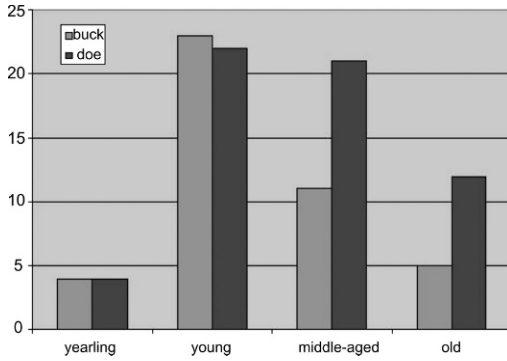


FIGURE 4. Distribution of mandibular osteomyelitic lesions in mandibles of roe deer collected in Slovenia in 2007 according to age and gender (yearling=1 yr; young=2–4 yr; middle-aged=5–7 yr; old adults≥8 yr).

The bony lesions observed in this study frequently result in death of the animal. However, our results suggest that, until its terminal stage with severe tooth displacement, tooth loss, accompanying pain, and decreased food intake, the actinomycotic lesion does not influence body weight, a coarse indicator of health (Table 2). The slight decrease in body weight after the

age of 7 yr may be attributable to age-related decrease in overall health rather than solely to the influence of the mandibular lesion.

In conclusion, mandibular osteomyelitis is a rare condition with low apparent impact on the survival of free-ranging roe deer in Slovenia. Environmental factors and pollution are factors that may increase the occurrence of mandibular osteomyelitis. Given the low frequency of the condition, its apparently negligible influence on the health of populations, and the difficulties involved with capturing and treating free-ranging animals, we believe that treatment is not needed and is highly dissuaded.

ACKNOWLEDGMENTS

The study was supported financially by the Slovene Research Agency (project L7-0026: “Roe deer mandibles as bioindicators of environmental pollution and assistance for population management”), by the Šoštanj Thermal Power Plant, and by the Ministry of Science, Education, and Sport of the Republic of Croatia (“Dental pathology of wild mam-

TABLE 2. Estimated age and weight of eviscerated roe deer (mean, maximum, and minimum value) with the degree of mandibular osteomyelitis lesions.

Degree of lesion	Age (yr)	Mean weight (kg)	Maximum (kg)	Minimum (kg)	n
1	1	12.5	13.0	11.5	3
	2–4	16.6	22.0	12.0	25
	5–7	16.7	21.0	13.0	8
	≥8	14.8	16.0	13.5	3
2	1	14.0	16.0	12.0	2
	2–4	16.4	18.0	15.0	6
	5–7	18.6	22.0	13.0	10
	≥8	18.5	21.5	15.0	4
3	1	10.7	11.0	10.5	2
	2–4	17.3	19.0	16.5	3
	5–7	19.0	19.0	19.0	2
	≥8	12.0	12.0	12.0	1
4	1	0	0	0	0
	2–4	16.3	19.0	17.0	3
	5–7	15.9	20.0	12.0	5
	≥8	13.0	13.0	13.0	1
5	1	0	0	0	0
	2–4	20.0	20.0	20.0	1
	5–7	0	0	0	0
	≥8	14.0	14.0	14.0	1

mals” and “Applied biomedical research on deer game”).

LITERATURE CITED

- AGUIRRE, A. A., C. BRÖJER, AND T. MÖRNER. 1999. Descriptive epidemiology of roe deer mortality in Sweden. *Journal of Wildlife Diseases* 35: 753–762.
- CAREK, P. J., L. M. DICKERSON, AND J. L. SACK. 2001. Diagnosis and management of osteomyelitis. *American Family Physician* 63: 2413–2420.
- CARTER, G. R., AND D. J. WISE. 2004. *Essentials of veterinary bacteriology and mycology*. 6th Edition. Iowa State University Press, Ames, Iowa, 290 pp.
- CVETNIĆ, S. 2002. Bakterijske i gljivične bolesti životinja. Medicinska naklada, Zagreb, Croatia, 473 pp.
- DAVIDSON, W. R., V. F. NETTLES, L. E. HAYES, E. W. HOWERTH, AND C. E. COUVILLION. 1990. Epidemiologic features of an intracranial abscessation/suppurative meningitis complex in white-tailed deer. *Journal of Wildlife Diseases* 26: 460–467.
- FAGAN, D. A., J. E. OOSTERHUIS, AND K. BENIRSCHKE. 2005. “Lumpy jaw” in exotic hoof stock: A histopathologic interpretation with a treatment proposal. *Journal of Zoo and Wildlife Medicine* 36: 36–43.
- GLAZE, R., M. HOEFS, AND T. D. BUNCH. 1982. Aberrations of the tooth arcade and mandible in Dall’s sheep from southwestern Yukon. *Journal of Wildlife Diseases* 18: 305–309.
- HOEFS, M., AND T. D. BUNCH. 2001. Lumpy jaw in wild sheep and its evolutionary implications. *Journal of Wildlife Diseases* 37: 39–48.
- HOWE, D. L. 1981. Miscellaneous bacterial diseases. In *Infectious diseases of wild mammals*, J. W. Davis, L. H. Karstad, and D. O. Trainer (eds.). Iowa State University Press, Ames, Iowa, pp. 418–422.
- JELENKO, I., K. JERINA, AND B. POKORNY. 2010. Impact of environmental factors on the appearance and distribution of dental fluorosis of roe deer (*Capreolus capreolus* L.) in eastern Slovenia. *Zbornik gozdarstva in lesarstva* 92: 21–32.
- LEADER-WILLIAMS, N. 1980. Dental abnormalities and mandibular swellings in South Georgia reindeer. *Journal of Comparative Pathology* 90: 315–330.
- NAGLIĆ, T., D. HAJSIG, J. MADIĆ, AND L. PINTER. 2005. Veterinarska mikrobiologija, Specijalna bakteriologija i mikologija. Veterinarski fakultet Sveučilišta u Zagrebu i Hrvatsko mikrobiološko društvo, Zagreb, Croatia, 351 pp.
- MAINAR-JAIME, R. C., M. R. WOODBURY, AND M. CHIRINO-TREJO. 2007. Survey on “lumpy jaw” on deer farms in western Canada: Prevalence and distribution, and identification of associated factors. *New Zealand Veterinary Journal* 55: 30–39.
- RADAELLI, E., E. ANDREOLI, S. MATTIELLO, AND E. SCANZIANI. 2007. Pulmonary actinomycosis in two chamois (*Rupicapra rupicapra*). *European Journal of Wildlife Research* 53: 231–234.
- ROEDER, B. L., M. M. CHENGAPPA, K. F. LECHTENBERG, T. G. NAGARAJA, AND G. A. VARGA. 1989. *Fusobacterium necrophorum* and *Actinomyces pyogenes* associated facial and mandibular abscesses in blue duiker. *Journal of Wildlife Diseases* 25: 370–377.
- ROSEN, M. N., AND F. F. HOLDEN. 1961. Multiple purulent abscesses (*Corynebacterium pyogenes*) of deer. *California Fish and Game* 47: 293–299.
- SCHAAL, K. P., A. E. YASSIN, AND E. STACKEBRANDT. 2006. The family Actinomycetaceae: The genera *Actinomyces*, *Actinobaculum*, *Arcanobacterium*, *Varibaculum*, and *Mobiluncus*. In *The prokaryotes*, Vol. 3, Part B, M. Dworkin, S. Falkow, E. Rosenberg, K. H. Schleifer and E. Stackebrandt (eds.). Springer-Verlag, New York, New York, pp. 430–537.
- SCHULTZ, M., U. KIERDORF, F. SEDLACEK, AND H. KIERDORF. 1998. Pathological bone changes in the mandibles of wild red deer (*Cervus elaphus* L.) exposed to high environmental levels of fluoride. *Journal of Anatomy* 193: 431–442.
- SØRUM, H., AND M. SUNDE. 2001. Resistance to antibiotics in the normal flora of animals. *Veterinary Research* 32: 227–241.
- SUTTER, V. 1984. Anaerobes as normal oral flora. *Reviews of Infectious Diseases* 6(Suppl 1): S62–S66.
- TURNQUIST, S. E., AND W. H. FALES. 1998. Disseminated *Actinomyces pyogenes* infection in a free-ranging white-tailed deer. *Journal of Veterinary Diagnostic Investigation* 10: 86–89.
- WAGENKNECHT, E. 1984. Alters-bestimmung des erlegten Wildes. Neumann–Neudamm, Melsungen, Germany, 148 pp.
- WOBESER, G. 2001. *Actinomyces* and *Arcanobacterium* infections. In *Infectious diseases of wild mammals*. 3rd Edition, E. S. Williams and I. K. Barker (eds.). Iowa State University Press, Ames, Iowa, pp. 487–488.

Submitted for publication 21 June 2010.

Accepted 23 October 2010.