

# Sinus bone graft - what do we know so far?

---

**Radić, Ozren**

**Master's thesis / Diplomski rad**

**2024**

*Degree Grantor / Ustanova koja je dodijelila akademski / stručni stupanj:* **University of Zagreb, School of Dental Medicine / Sveučilište u Zagrebu, Stomatološki fakultet**

*Permanent link / Trajna poveznica:* <https://um.nsk.hr/um:nbn:hr:127:368527>

*Rights / Prava:* [In copyright](#)/[Zaštićeno autorskim pravom.](#)

*Download date / Datum preuzimanja:* **2024-10-06**



*Repository / Repozitorij:*

[University of Zagreb School of Dental Medicine  
Repository](#)





Sveučilište u Zagrebu  
Stomatološki fakultet

Ozren Radić

# **SINUS BONE GRAFT – WHAT DO WE KNOW SO FAR?**

GRADUATE THESIS

Zagreb, 2024

Rad je ostvaren u:                   Klinička bolnica Dubrava, Zavod za oralnu kirurgiju  
Mentor rada:                         docent Ivan Zajc, Klinička bolnica Dubrava  
Lektor hrvatskog jezika:         prof. Vanja Nekich  
Lektor engleskog jezika:         Michael Nekich (stalni sudski tumač za Engleski jezik)

Rad sadrži:    49 stranica  
                  1 tablica  
                  5 slika

Rad je vlastito autorsko djelo, koje je u potpunosti samostalno napisano uz naznaku izvora drugih autora i dokumenata korištenih u radu. Osim ako nije drukčije navedeno, sve ilustracije (tablice, slike, sheme i dr.) u radu su izvorni doprinos autora diplomskog rada. Autor je odgovoran za pribavljanje dopuštenja za korištenje ilustracija koje nisu njegov izvorni doprinos, kao i za sve eventualne posljedice koje mogu nastati zbog nedopuštenog preuzimanja ilustracija odnosno propusta u navođenju njihovog podrijetla.

## **PODIZANJE DNA SINUSA - ŠTO DO SADA ZNAMO?**

### **Sažetak**

Kirurgija podizanja sinusa važna je metoda za postizanje dovoljne visine alveolarnog grebena u stražnjem dijelu maksile za postavljanje implantata. Izravni i neizravni postupci podizanja sinusa i dalje imaju važne implikacije u kliničkoj praksi te se stalno unapređuju. Novi instrumenti, materijali za presađivanje i postupci čine operaciju podizanja sinusa sigurnijom uz s dosljednije rezultate. Općenito se može primijetiti trend prema minimalno invazivnim zahvatima. Uz trenutno dostupne metode, stopa preživljenja implantata postavljenih u presađene maksilarne sinuse je veća od 90%. Najčešća komplikacija je i dalje perforacija membrane koja se može minimizirati novim tehnikama i instrumentima. Ostale komplikacije, kao što su krvarenje, oštećenja živaca ili infekcija, mogu se izbjeći pažljivim planiranjem i pripremom pacijenta. Cilj ovog rada je prikazati trenutne trendove u kirurgiji podizanja sinusa. Konkretno, razmatra se razvoj tehnika, planiranje, anatomija sinusa, pregled materijala za presađivanje, kirurške tehnike, upravljanje komplikacijama i buduće perspektive.

**Ključne riječi:** sinus lift, sinusni graft, elevacija sinusa, implantati, koštani graft, lateralni prozor, izravni pristup, neizravni pristup, transkrestalni pristup, krestalni pristup, maksilarni sinus, augmentacija maksilarnog sinusa

## **SINUS BONE GRAFT – WHAT DO WE KNOW SO FAR?**

### **Abstract**

Sinus lift surgery is an important method for obtaining sufficient alveolar ridge height in the posterior maxilla for implant placement. The direct and indirect sinus lift procedures both continue to have implications in clinical practice, and are being constantly improved. New instruments, grafting materials and procedures make sinus elevation surgery safer, with more consistent results. A general trend towards minimal invasiveness can be observed.

With the currently available methods, the survival rate of implants placed in grafted maxillary sinuses is over 90%. The most common complication remains membrane perforation, which can be minimised with new techniques and instruments. Other complications, such as bleeding, nerve damage or infections, can be avoided with meticulous planning and patient preparation.

The current work aims to delineate the current trends in sinus elevation surgery. Specifically, the development of the techniques, planning, sinus anatomy, an overview of grafting materials, surgical techniques, management of complications, and future perspectives are discussed.

**Keywords:** sinus lift, sinus graft, sinus elevation, implants, bone graft, lateral window, direct approach, indirect approach, transcrestal approach, crestal approach, maxillary sinus, maxillary sinus augmentation

## **TABLE OF CONTENTS**

1. INTRODUCTION	1
2. DEVELOPMENT OF SINUS GRAFTING	4
3. SURGERY PLANNING	6
3.1 General Indications and Contra-indications to Sinus Grafting	7
3.2 Preoperative Patient Evaluation	9
3.3 Maxillary Sinus Anatomy	12
3.4 Grafting Materials	15
4. SURGICAL TECHNIQUES	20
4.1 Prerequisites for Successful Bone Grafting	21
4.2 Transcrestal Approach	23
4.3 Lateral Window Approach	27
4.4 Managing Crestal Width and Height Deficiencies	30
4.5 Managing Complications	32
5. DISCUSSION	34
6. CONCLUSION	37
7. REFERENCES	39
8. BIOGRAPHY	49

## LIST OF ABBREVIATIONS

AAA	Anterior antral artery
ASAA	Anterior superior alveolar artery
BMP	Bone morphogenic protein
CAD/CAM	Computer-aided design / computer-aided manufacturing
CBCT	Cone beam computed tomography
DASK	Dentium Advanced Sinus Kit
DFDBA	Demineralised freeze-dried bone allograft
EA	Extraosseous anastomosis
FDBA	Freeze-dried bone allograft
GBR	Guided bone regeneration
HA	Hydroxyapatite
HU	Hounsfield unit
IA	Intraosseous anastomosis
IGF	Insulin-like growth factor
IOA	Infraorbital artery
IPO	Implant-protected occlusion
MSP	Maxillary sinus pneumatisation
NSAID	Non-steroidal anti-inflammatory drugs
OMC	Osteomeatal complex
OSFE	Osteotome sinus floor elevation
PDGF	Platelet-derived growth factor
PCL	Polycaprolactone
PGA	Polyglycolic acid
PGLA	Lactide co-glycolide
PLA	Polylactic acid
PRP	Platelet rich plasma
PRF	Platelet rich fibrin
PSAA	Posterior superior alveolar artery
PTFE	Polytetrafluorethylene
RPD	Removable partial denture
SAD	Simplified Antrostomy Design
TGF	Transforming growth factor

**1. INTRODUCTION**



The prevalence of edentulism and untreated dental caries is relatively common in the general population worldwide, varying greatly among countries, socioeconomic statuses and age groups (1). In the posterior segment of the dentition, the consequences of not restoring missing teeth can be severe, including localised bone loss, tilting of adjacent teeth, extrusion of opposing teeth and loss of vertical height (2). Importantly, as time passes, it becomes increasingly difficult to restore missing teeth due to these progressive changes. These changes can also lead to the further gradual loss of teeth due to increased caries risk and compromised periodontal or pulpal health.

Different treatment options are available for managing partial edentulism in the posterior segment of the dentition, such as partial prostheses, bridges and implants. In comparison to conventional removable partial dentures (RPDs), implant-supported RPDs generally result in higher patient satisfaction (3), although there is no convincing evidence of higher patient satisfaction with implant therapy than with conventional bridgework (4). In other words, patients are more satisfied with fixed solutions than with removable solutions, regardless of whether they are implant-based or not. However, it can be debated that if only one tooth is missing and the adjacent teeth are in good condition, implant placement would be a less invasive option than a bridge preparation, which includes sound teeth.

Dental implants have an important role in modern dental medicine, and the prevalence in the United States of at least one dental implant has increased from 1.3% in the period from 1999 to 2004 to 8.4% in the period from 2015 to 2020 (5). In Europe, the size of the dental implant market was USD 2.44 billion in 2023, and the IMARC Group expects it to reach USD 3.12 billion by 2032 (6). Furthermore, it is a well-known fact that older age leads to increased tooth loss (7), and with the ongoing trend of an ageing population (8), the expectation is that the demand for implant rehabilitation will only increase in the future.

In the posterior maxilla, implant rehabilitation has always been a challenge, mainly because of the high trabecular bone content (9, 10) and close proximity of the maxillary sinus. In a quest for methods that produce more bone mass in this region, limited by interocclusal space, sinus grafting techniques have been developed (9, 11). Traditionally, a minimum of 10 mm of crestal bone height is often required for predictable implant placement, while in some clinical cases, the crestal bone height can be reduced to as little as 1 mm (the thickness of the cortical bone plate).

To combat this problem, sinus elevation and grafting procedures were developed, first described by Tatum in 1976 and subsequently published by Boyne and James in 1980 (12). Almost 50 years of development has seen sinus grafting become a predictable and successful

treatment option, utilised in many dental practices around the world. Chiapasco et al. investigated literature reviews and found that the overall implant survival rate was 92.6% (13). They confirmed this result based on a longitudinal follow-up study with 692 patients and 952 sinus graft procedures, spanning a mean follow-up period of 59 months, and concluded that the overall survival rate is 95.8% (14). Sinus grafting continues to be an important method for bone augmentation and implant rehabilitation in the posterior maxilla. New technological advancements have made the technique safer, more predictable and accessible to a greater group of clinicians and patients.

Aim of this paper is to provide a brief overview of contemporary sinus grafting techniques. It describes the development of such techniques, the indications and contraindications to sinus grafting, surgery planning, patient preparation and possible complications. Additionally, the two main methods of entering the sinus (lateral and transcrestal approaches) are described in detail, including indications for when one method is preferred over the other. Also, the treatment of horizontal and vertical ridge defects will be briefly explained. Lastly, future developments in sinus grafting methods will also be explored, with a few examples of alternative treatments to sinus grafting.

## **2. DEVELOPMENT OF SINUS GRAFTING**

Sinus augmentation was developed in the 1970s in an effort to create more bone for implant placement in the posterior segment of the maxilla—an area affected by bone loss due to pneumatisation of the sinuses or alveolar bone atrophy.

Before the advent of sinus elevation, alveolar bone augmentation was performed using only blocks of autologous bone (15). The first successful alveolar bone graft using tibial bone was performed by Drachter in 1914. Later attempts encountered problems and were often unsuccessful. It was not until the 1950s that interest in bone grafting returned, and surgeons began to experiment with primary bone grafting for cleft lip and palate defects. Johanson and Ohlsson developed an operation for primary bone grafting of the alveolus in 1961 (16). In 1967, Dr. James Alley successfully used remote incision in combination with a tunnelling approach for alveolar grafting in denture patients (17). Inspired by this method, Dr. Hilt Tatum used the same tunnelling technique for bone augmentation with subsequent implant placement in 1970 (18, 19). The technique initially used autologous rib bone, but later, autologous particulate iliac bone was used as grafting material.

The sinus augmentation procedure was first described by Dr. Hilt Tatum in 1976 at the Implant Congress in Alabama (20). It was then published in 1980 by Boyne and James (12), and then later, in 1986, it was also published by Tatum (21). During the first five surgeries, access to the sinus was obtained through the alveolar crest by means of a palatal incision, after which the procedure evolved into a modified Caldwell-Luc procedure where access is obtained through the lateral wall of the maxilla, anterior to the zygomatic process. During the first years of conducting sinus augmentations, instruments were limited, and initially modified Fogarty catheters were used to lift the Schneiderian membrane until suitable instruments were developed in 1978. Autologous iliac bone was the primary source of augmentation material prior to 1984, after which freeze-dried demineralized augmentation products became widely available. In 1994, Summers introduced a less invasive method for sinus elevation through the alveolar crest, which he termed osteotome sinus floor elevation (OSFE) (22). This technique uses an osteotome to break the cortical bone lining the sinus floor and elevate it together with the sinus membrane to gain a few millimetres of vertical height. The sinus lifting procedure developed by Tatum is also known as the external or direct sinus lift procedure or lateral window sinus lift, while the approach by Summers is known as the internal or indirect sinus lift or transcrestal sinus lift. Both techniques continue to be developed since they are both useful for different clinical cases.

### **3. SURGERY PLANNING**

### **3.1 General Indications and Contraindications to Sinus Grafting**

As mentioned earlier, the indication for sinus grafting is an inadequate residual alveolar bone with a height of less than 10 mm in the posterior maxilla (23). This can either be due to pneumatization of the maxillary sinuses or the resorption of the residual alveolar ridge. There are three main ways of entering the sinus: 1) the lateral window approach, 2) the transcrestal approach and 3) the alveolar split approach (24). Whether a lateral or transcrestal approach is chosen depends on the available height of the vertical bone. The transcrestal approach is less invasive but generally provides a maximum of 2-5 mm of additional vertical height. It means that if there is less than 5 mm of bone height remaining, this method will not provide sufficient bone gain simultaneous implant placement. However, the more invasive lateral approach can easily elevate the membrane by more than 10 mm, making it more suitable for the insertion of multiple implants. Additionally, the more advanced alveolar split approach can be used in the case of horizontal bone resorption when the alveolar crest is deficient in the bucco-palatal plane. In such cases, the alveolar split enables buccal repositioning of the collapsed buccal plate and grafting of the intersplit area. In this same procedure, the sinus membrane can be elevated and grafted.

Contraindications to sinus grafting can be classified as general implant contraindications, as well as absolute and relative contraindications specific to sinus grafting (9, 23, 25). Patients with absolute general implant contraindications are also contraindicated for sinus augmentation, given that the ultimate goal of sinus augmentation is implant placement. Absolute contraindications to implant placement include recent myocardial infarction, recent cerebrovascular incident, recent cardiac valvular prosthesis replacement, systemic immunosuppression, bleeding disorders, psychiatric disorders, intravenous bisphosphonate treatment and chemotherapy or radiotherapy (26). Relative contraindications to implant placement need to be resolved before sinus elevation surgery and include unfinished growth, osteoporosis, smoking, diabetes, cardiovascular disease, HIV infection and hypothyroidism (27).

These are then followed by absolute contraindications and relative contraindications, more specific to sinus grafting (9, 23, 25). Absolute contraindications include severe or uncontrollable systemic disease, mental disorders, large dose radiation therapy to the maxilla, heavy smoking or drug abuse. Absolute contraindications can not be reversed, such as for example scarring due to high-dose radiation therapy or mental disorders such as psychoses. Relative contraindications usually involve local factors, such as infections, polyps, oroantral fistula, history of sinus surgery and allergic rhinitis. Most relative contraindications can be

resolved before surgery. Infections are problematic because they impair healing and risk loss of the grafting material, while local factors such as polyps can result in blockage of the osteomeatal complex (OMC) or lacrimal canal. Mucous retention cysts can also be problematic when they are larger than 10 mm. For smaller cysts, a 10 mL syringe and 21-gauge needle can be used to aspirate the contents of the cyst during sinus elevation. The relative and absolute contraindications to sinus grafting are summarised in Table 1.

<b>Relative</b>	<b>Absolute</b>
<ul style="list-style-type: none"> <li>● Allergic rhinitis</li> <li>● Acute sinusitis</li> <li>● Low-dose radiation therapy maxilla</li> <li>● Antral polyps</li> <li>● Mucous retention cysts (&gt; 10 mm)</li> <li>● Previous sinus surgery</li> <li>● Oroantral fistula</li> <li>● Presence of septa</li> </ul>	<ul style="list-style-type: none"> <li>● Uncontrollable systemic disease</li> <li>● Mental disorders</li> <li>● Chronic sinusitis</li> <li>● High-dose radiation therapy maxilla</li> <li>● Heavy smoking</li> <li>● Alcohol or drug abuse</li> <li>● Inhaled steroids</li> </ul>

Table 1: Contra-indications to sinus augmentation surgery

Sinus infections are a common reason for clinical visits and need to be addressed before sinus grafting surgery. For this reason, the treatment of sinus infections is briefly discussed here. Rhinosinusitis can be classified into four forms (28):

Acute rhinosinusitis:	<i>lasting &lt; 4 weeks</i>
Subacute rhinosinusitis:	<i>lasting &lt; 12 weeks</i>
Chronic rhinosinusitis:	<i>lasting &gt; 12 weeks</i>
Recurrent acute rhinosinusitis:	<i>4 episodes of acute sinusitis per year, lasting at least 7 days each</i>

Acute rhinosinusitis is mostly caused by viruses and is usually self-limiting. Allergic rhinitis can also sometimes lead to sinusitis due to obstruction of the osteomeatal complex. In both cases, antibiotics are not warranted, however, the inability of existing clinical criteria to distinguish bacterial from viral infections often results in inappropriate antibiotic therapy (29). Acute bacterial sinus infections often have a more severe course, and there is usually

little improvement 10 days after infection. In such cases, standard empirical antibiotic therapy (amoxicillin with or without clavulanic acid for 7 days) is usually sufficient. For chronic and recurrent cases, microbiological culturing for antibiotic susceptibility testing is recommended. However, samples should be obtained from the inside of the sinus (by means of endoscopy or needle aspiration) and not from the nose. A minority of sinus infections are fungal, which are more aggressive and often require surgical debridement in addition to antimycotic therapy (30). Additionally, up to one-third of sinus infections have an odontogenic origin and most often result from the roots of maxillary first molars or premolars (31). Such cases require endodontic treatment or extraction of the affected tooth.

### **3.2 Preoperative Patient Evaluation**

Modern implant dentistry takes into consideration future restoration when planning implant positions, wherever possible (32). An inappropriate implant position can cause a range of problems, ranging from as simple as difficulty in maintaining oral hygiene to peri-implantitis and loss of implants. Guided surgery has enabled clinicians to better plan the placement of implants and execute the surgical procedure with more precision. However, details on the planning of such procedures are beyond the realm of this thesis. Nevertheless, following the rules of prosthetic-driven implantology, occlusal considerations dictate the position of the implants and should follow the principles of implant-protected occlusion (IPO) (33). The most important aspects of IPO which need to be taken into account are no premature occlusal contacts, even surface area distribution, interdependent articulation, mutually protected occlusion, passive fit, correct crown height, axial loading and no cantilevers. However, compromises sometimes have to be made due to unfortunate resorption patterns of the jaws or anatomic variations.

After a tooth is lost, resorption of the alveolar crest begins (34). The rate of residual ridge resorption is the fastest during the first few months following extraction, after which it slows down. The resorption rate in the maxilla slows down faster than in the mandible, resulting in that over time, the resorption rate in the mandible occurs up to four times faster than in the maxilla. Furthermore, the maxilla follows a centripetal resorption pattern, while the mandible follows a centrifugal resorption pattern (35). This phenomenon can sometimes result in class III occlusal relations. As the bone volume between the buccal and lingual or palatal cortical plates decreases, the ridges assume a more knife-edged morphology. This is important when



planning implant rehabilitations because sufficient crest height does not guarantee sufficient crest width in a buccolingual direction.

Physiologically, the sinus is increasingly pneumatized after birth until females reach 20 years of age and males 30 years of age (36). It is unclear which factors govern physiological maxillary sinus pneumatization (MSP), but genetics, craniofacial configuration, bone density, growth hormones and air pressure in the sinus cavity seem to play a role. Post-physiologically, tooth extraction can provoke MSP. Extraction of a second molar seems to lead to the greatest pneumatization. There is great variability in MSP in the general population, and males seem to have more extensive MSP than females (37).

Due to the combination of residual ridge resorption and maxillary sinus pneumatisation, both occurring at the same time, two patients with similar residual bone levels can present two completely different clinical situations. Possible situations are vertical resorption of the alveolar ridge only, sinus pneumatisation only, or a combination of ridge resorption and sinus pneumatisation.

To evaluate the atrophic posterior maxilla with regard to the residual bone height and width, also considering vertical and horizontal interarch relations, Chiapasco et al. developed a classification system and associated treatment recommendations (38). The classification is as follows:

Class A	Residual ridge height: 4 - 8 mm Residual alveolar width: $\geq 5$ mm Absence of significant vertical alveolar ridge resorption
Class B	Residual ridge height: 4 - 8 mm Residual alveolar width: $< 5$ mm Absence of significant vertical alveolar ridge resorption
Class C	Residual ridge height: $< 4$ mm Residual alveolar width: $\geq 5$ mm Absence of significant vertical alveolar ridge resorption
Class D	Residual ridge height: $< 4$ mm Residual alveolar width: $< 5$ mm

Absence of significant vertical alveolar ridge resorption

Classes E - H      Residual alveolar height and width classified as in classes A - D respectively

With significant vertical alveolar ridge resorption

Unfavourable vertical interarch relation

Class I              Severe 3 dimensional atrophy of maxilla

With significant vertical alveolar ridge resorption

With significant centripetal maxillary resorption

Unfavourable vertical interarch relation

Unfavourable horizontal relation (maxillary retrusion)

Importantly, in this classification, the authors arbitrarily chose a residual height of 4 mm as they found it to be sufficient for primary implant stability in bone of adequate quality. It can be argued that higher trabecular bone content necessitates a greater vertical height. However, the classification system is useful for classifying different clinical cases, and when considering functional and esthetic outcomes in planning surgery. Class A patients are characterised by sinus pneumatisation only, with sufficient residual bone volume and good interarch relations. These patients only require a sinus elevation procedure. Class B patients have a combination of sinus pneumatisation and alveolar resorption but with a normal interarch relation. In such cases, horizontal guided bone regeneration (GBR) is combined with sinus lifting. Classes C and D are similar to Classes A and B but have more severe sinus pneumatisation. Class C only requires sinus lifting, while Class D also requires GBR to increase bone width in the bucco-palatal direction. Regarding Classes E-H, sinus pneumatisation is classified identically as in the respective A-D groups (A = E; B = F, etc.), but the interarch distance is increased. These patients need to be treated with vertical and horizontal GBR as well as sinus elevation. Class I patients, the most severe cases, have severe three-dimensional maxillary atrophy due to a centripetal resorption pattern, as discussed earlier. Sinus lifting and GBR are unable to correct the maxillary retrusion, and in such cases, a Le Fort 1 osteotomy and forward repositioning of the maxilla with interpositional iliac grafting is needed.

Bone quality is important for primary implant stability, whereas poor bone quality or quantity may lead to early implant failure (39). Importantly, bone quality should be evaluated during treatment planning. For this purpose, in 1985, Lekholm et al. developed a classification system for bone quality that is still relevant and widely used in implant dentistry today (40). According to this system, the jawbone is classified based on the proportion of trabecular and cortical bone content. Class 1 is homogenous cortical bone with little to no trabecular content. Class 2 is a thick layer of cortical bone with a core of dense trabecular bone. Class 3 describes a thin layer of cortical bone with a core of dense trabecular bone. And lastly, Class 4 describes a thin layer of cortical bone with a low-density trabecular core. Similar to this classification, Misch also proposed four bone types (D1-D4) and additionally described their localization (41). Bone type D2 is the most common type and is found in most areas of the mandible. Bone type D1 is rare, and is most commonly found in the anterior mandible. Type D3 is most frequent in the anterior maxilla, while D4 is found most commonly in the posterior maxilla.

Due to all of the above factors, radiographic imaging is necessary for diagnostics, treatment planning and outcome assessment. Cone beam computed tomography (CBCT) assists clinicians in detecting anatomy and planning the surgical procedure three-dimensionally (42). It visualises cross sections of the alveolar crest, on which the alveolar bone height and width can be accurately measured. Based on this information, an appropriate treatment plan for GBR, sinus elevation, and implant placement can be chosen. Furthermore, bone quality can be determined using CBCT by measuring the density in Hounsfield units (HU). The anatomy of the maxillary sinus, as discussed next, can be depicted by CBCT. It is used for volumetric analysis of the maxillary sinus to help monitor bone remodelling after the procedure. Surgical guides can be manufactured using CBCT, and many new medical technological developments are dependent on 3D diagnostics. Overall, CBCT provides clinicians with a tool to detect potential pathology and anatomical problems in advance and plan the procedure accordingly. It allows for a safer procedure with fewer complications and morbidity for the patient. When creating CBCT images, the “as low as reasonably achievable” (ALARA) principle must be followed, which means that the field of view (FOV) and radiation dose must be chosen to include all relevant anatomical details, with as little as possible radiation to the patient.

### **3.3 Maxillary Sinus Anatomy**

The maxillary sinuses are two air-filled cavities on either side of the nasal cavity (43). Unlike the ethmoidal sinus, which is present at birth, the maxillary (and frontal) sinus develops gradually during the course of cranial growth (pneumatisation). The maxillary sinus is pyramidal in shape, with the base adjacent to the nasal cavity and apex directed towards the zygomatic process (44). It is bordered by the orbital floor superiorly and by the alveolar and palatine processes inferiorly (45). The nasal cavity is situated medially, and the zygomatic process forms the lateral border. The posterior border is formed by the infratemporal fossa, and the maxillary sinus is found just behind the anterior wall of the maxilla (46). Several recesses are formed by the walls of the maxillary sinus (44). The alveolar recess and palatine recess point inferiorly. The zygomatic recess points laterally and the infraorbital recess is found superiorly towards the orbital floor.

The maxillary sinus has a volume of approximately 15 mL, and drains into the middle nasal meatus after it passes through the ethmoidal infundibulum and semilunar hiatus (45). On average, the OMC is found at 27.05 mm and 23.40 mm above the sinus floor in dentate and edentulous patients, respectively (47). This is the maximal amount that the sinus floor can be elevated without obstructing the OMC.

The root apices of all the maxillary posterior teeth are in close proximity to the sinus floor, and the first and second molars, particularly in close proximity, are most likely to penetrate the sinus floor (48). Moreover, there are different types of apical protrusions into the sinus. It may be that the apices are only touching the sinus floor, they may be protruding, or that the sinus membrane is interposed in the root furcation. Such configurations need to be taken into account when choosing the appropriate surgical technique. For example, it will be very hard to elevate a membrane situated in the root furcation through the lateral window approach. It would be much easier to separate the remaining bone within the furcation, and elevate it together with the membrane by means of the transcrestal approach, as will be seen in subsequent chapters.

The maxillary sinus can contain septa, which are composed of cortical bone. Their prevalence ranges from 16-61%, as reported in the literature (49, 50, 51). Generally, the prevalence of septa is greater in edentulous patients than in dentate individuals. These septa are associated with a higher membrane perforation risk (52), and surgical techniques to avoid perforations will be discussed later during the lateral window procedure.

Blood supply to the maxillary sinus is derived from the maxillary artery branches: the posterior superior alveolar artery (PSAA), infraorbital artery (IOA) and the descending palatine artery (53). In 60% of cases, the PSAA and the IOA have a common trunk from the

maxillary artery. The PSAA then travels inferiorly in close relation to the bone of the maxillary tuberosity, while the IOA travels superiorly into the inferior orbital fissure, after which it enters the infraorbital canal. Before the IOA exits the infraorbital foramen, it gives off the anterior superior alveolar artery (ASAA) branch, which supplies the incisors, canines and mucous membrane of the maxillary sinus. The PSAA and the ASAA anastomose form an intraosseous branch termed the intraosseous anastomosis (IA). This anastomosis is present in all cases but is only visible on radiographs in 50% of cases. The IOA also anastomoses with the PSAA after it exits the infraorbital foramen to give rise to the extraosseous anastomosis (EA). Together, the IA and EA thus form an anastomosis arcade which supplies blood to the maxillary sinus (**Fig. 1 A**). This arcade must be visualised using CBCT to prevent bleeding complications during window access preparation. Of less importance are the greater palatine artery and the sphenopalatine artery, which also supply blood to the maxillary sinus (11). Importantly, the greater palatine artery and nerve should be avoided if raising a palatal flap or using a palatal approach to the sinus floor (45).

Innervation to the maxillary sinus is provided by the V2 maxillary division of the trigeminal nerve, which enters the infraorbital canal together with the infraorbital artery (11, 44). Before the infraorbital nerve exits the infraorbital foramen, it gives off branches of the posterior superior alveolar, middle superior alveolar and anterior superior alveolar nerves, which innervate the posterior and anterior sinus walls (**Fig. 1 B**). Additionally, the maxillary sinus superior and medial walls are innervated by the infraorbital nerve, while the inferior wall and ostium are innervated by the greater palatine nerve. Importantly, in a small number of cases (5.6-10.8%), the infraorbital canal may protrude into the anterosuperior aspect of the maxillary sinus, and be attached to a sinus wall (44). Failure to recognize this anatomical variation can result in injury to the infraorbital nerve.

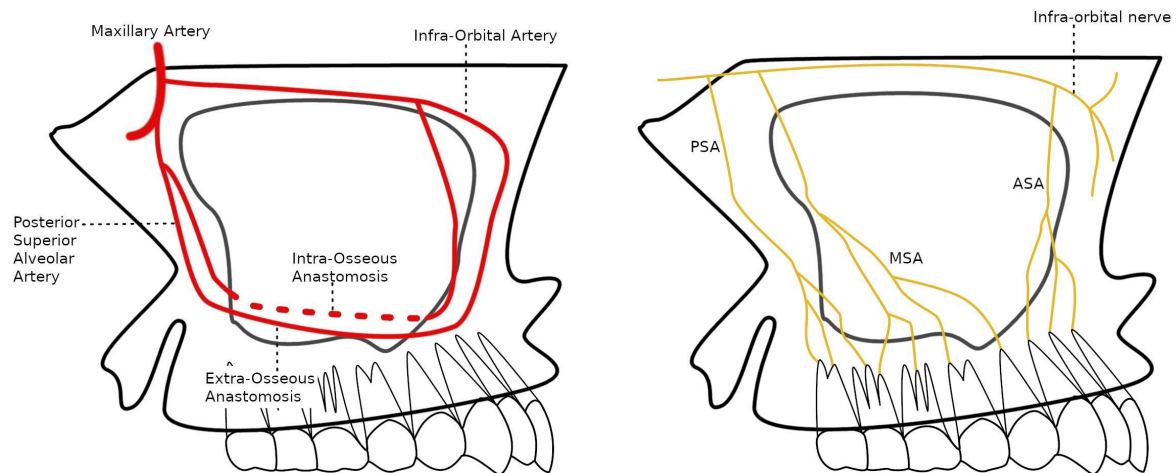


Figure 1. Vascularisation and innervation of the maxillary sinus

Lining the maxillary sinus from the inside is the Schneiderian membrane (54). This tissue consists of a periosteum overlaid with highly vascularized connective tissue and pseudostratified ciliated epithelium. Normally, the Schneiderian membrane is around 1 mm thick; however, asymptomatic thickening of the membrane is commonly found in everyday clinical practice. Thickening up to 4 mm is considered, therefore, physiological. Furthermore, males tend to have a thicker membrane than females. The thickness of the Schneiderian membrane is correlated with perforation risk, and it is found that perforation is more likely to occur with thin phenotypes (< 3 mm) (55).

Another important aspect for determining the perforation risk is the angle of the alveolar recess (54). This angle is measured at the angle formed by the alveolar recess between the buccal and palatal walls (10 mm above the sinus floor). On average, this angle is 73 degrees. There is a higher chance of perforation when this angle is steep, and the alveolar recess is narrow.

### 3.4 Grafting Materials

Different grafting materials with varying characteristics are available for bone augmentation procedures. They are classified based on the biologic mechanism, origin, physical form and resorption time.

The biologic mechanisms involved in bone grafting are osteoconduction, osteoinduction, and osteogenesis (56, 57). Osteoconduction occurs when the grafting material does not stimulate bone growth but instead serves as a scaffold, allowing osteoblasts from the surrounding tissue to grow into it. On the other hand, osteoinductive materials promote the differentiation of

osteoprogenitor cells into osteoblasts, thereby stimulating the formation of new bone. The most extensively studied osteoinductive mediators are bone morphogenic proteins (BMPs). When osteogenic graft materials are used, osteoblasts originate from the grafting material, stimulating new bone deposition. Additionally, some osteopromotive materials do not automatically stimulate bone formation but increase the osteoinductive effect of other grafting materials.

On the basis of the origin, grafting materials are classified as autografts, allografts, xenografts and synthetic alloplastic materials (58). For autologous or autogenous grafts, the donor and the recipient are the same individual. This is the most preferred type of bone, as it has the smallest risk of graft rejection. Autologous bone is osteoconductive, osteoinductive and osteogenic. However, a disadvantage is that a secondary surgical field is required. Autologous grafts can be harvested from different intraoral and extraoral locations.

Allografts are also human-derived, but the donor and recipient are not the same individual. Allografts come from cadavers or living donors who have donated bone tissue. There are three types of allogeneic bone grafts available: fresh bone, freeze-dried bone allograft (FDBA) and demineralized freeze-dried bone allograft (DFDBA). Allografts are processed to remove proteins which can cause an immune response in the host. Due to this reason, they are mainly a source of collagen type I and BMPs and, therefore, possess only osteoconductive and osteoinductive capabilities, unlike autologous bone which is also osteogenic. In addition, the availability of allografts is scarce in some countries.

Xenografts are materials of animal origin and have been used in dental medicine for over three decades. Xenografts are the most commonly used grafting materials in dentistry. They are obtained by removing all organic material, leaving only an inorganic structure composed mostly of hydroxyapatite (HA). Xenogenic materials have a calcium-to-phosphate ratio identical to human bone and, therefore, are good osteoconductive material. Although they can be of different animal origin, most are bovine and porcine xenografts.

Synthetic or alloplastic materials are manufactured. They are designed to be easily manipulated and have good osteoconductive properties. They have no intrinsic osteoinductive properties; however, other osteoinductive materials, such as growth factors or autologous bone, can be incorporated into their scaffold. Many different alloplastic materials possessing various characteristics are available. The most widely used alloplastic materials are calcium phosphate cements, calcium phosphate ceramics, calcium sulphate bioactive glasses and different polymers (natural or synthetic).

Bone grafting materials come in different forms, specifically particulate (large or small particles), putty or block grafts (57). They come as cortical or cancellous bone from different locations in the body. Furthermore, they have specific characteristics with regard to mineralization, resorption time, healing time and ease of application. Also, some materials provide more bone volume, while others provide a higher percentage of vital bone.

Growth factors are responsible for regulating cellular activity (56, 57). They can be manufactured by recombinant DNA techniques and incorporated into different grafting materials to increase their osteoinductive capability. A combination of different growth factors creates an environment for controlled deposition and resorption of bone. The transforming growth factor (TGF- $\beta$ ), BMP-2, BMP-4 and BMP-7 are mostly responsible for the differentiation of stem cells into osteoblasts.

Another source of growth factors is platelet-rich plasma (PRP) and platelet-rich fibrin (PRF), obtained by centrifugation of the patient's blood and subsequent separation of the platelet-containing fractions (59, 60). This provides a suspension rich in platelet growth factors such as platelet-derived growth factor (PDGF), insulin-like growth factor (IGF-I) and TGF- $\beta$ . These growth factors participate in the metabolism, proliferation, differentiation and migration of cells. In addition, PRP and PRF contain cytokines which help to attract leukocytes and stimulate platelet activation.

PRF is used more often in dentistry than PRP, due to the fact that the fibrogen matrix is more practical for clinical applications (59, 60). Also, PRP preparation uses bovine thrombin, which carries the risk of the development of autoantibodies against factor V, factor X and thrombin. This can result in life-threatening coagulopathies. PRF is a purely autologous product without additives. It provides a leukocyte-platelet-rich fibrin matrix containing platelets, leukocytes, growth factors and cytokines, acting as a biodegradable scaffold. The material mimics a blood clot, which enables slow remodelling of tissue. PRP is used in many fields of dentistry and in regenerative surgery as a biologic scaffold or adhesive to hold grafting particles together. It can also be used as a partially permeable, biodegradable membrane, which dissolves in 2-4 weeks.

Barrier membranes play a central role in GBR to cover bone defects and prevent non-osteogenic tissue invasion (61, 62). Without barriers, endothelial cells proliferate into the defect site and prevent osteoblasts from populating the lesion. A continuous isolation of the defect is therefore required for 16 to 24 weeks to enable bone regeneration. Barrier membranes for GBR can be divided into resorbable and non-resorbable, made from natural or synthetic materials (61, 62). However, the current trend is the development and use of



resorbable membranes, given that they do not require a second surgical removal, have improved soft tissue healing, and resorb in case of exposure (preventing infection). The disadvantages of resorbable membranes in comparison to non-resorbable membranes are possibly too fast resorption times and usually poorer mechanical properties.

Non-resorbable membranes are synthetic and most often made of polytetrafluorethylene (PTFE) or some derivative of PTFE (61, 62). These are the barriers first used for GBR, giving excellent results. Non-resorbable membranes made out of metal (usually titanium) also exist, which have better mechanical characteristics than PTFE membranes (62). However, non-resorbable membranes require a second surgical procedure to remove the membrane. Additionally, exposure of non-resorbable membranes often leads to infections and, consequently, dehiscences (61) or compromise of bone regeneration and osseointegration (62).

Resorbable membranes are natural or synthetic, and natural collagen membranes are most commonly used (61, 62). However, such membranes resorb in 4-12 weeks through enzymatic degradation (by collagenase), which is often insufficient time for complete regeneration of the defect. To increase the resorption time, newer collagen membranes contain cross-linked collagen to improve resistance to enzymatic degradation. Synthetic barrier membranes have better resorption time and improved mechanical properties, in comparison to collagen resorbable membranes. They are made of polylactic acid (PLA), polyglycolic acid (PGA) or a combination of the two molecules, lactide-co-glycolide (PGLA). The disadvantage of synthetic resorbable membranes is that they are mostly hydrophobic in nature, limit cell adhesion and lead to poorer outcomes. Additionally, their degradation due to hydrolytic cleavage leads to the release of lactate or pyruvate, which is acidic. Newer synthetic membranes are under development with the addition of additives to make them less hydrophobic, more osteoinductive and with better mechanical properties.

Due to the great variability in the characteristics of different materials, differences in success rates of the materials available should be taken into consideration. Autologous bone is considered the gold standard for bone grafting procedures due to its osteoconductive, osteoinductive and osteogenic properties. A systematic review by del Fabro et al. investigated the influence of grafting material, implant surface type and immediate as opposed to delayed loading on the implant survival rate (63). They found an overall implant survival rate of more than 92% for more than 12,000 implants placed in grafted sinuses of over 4,000 patients. The follow-up periods ranged from 12-57 months. They found no statistical differences between the different grafting materials. Additionally, there was no difference in survival rate between

delayed or immediate implant placement. Implant surface type had a significant effect on implant survival rate, and it was found that machine-surfaced implants have a lower survival rate than rough-surfaced implants. This may be explained due to the better retention of the blood coagulum on rough-surfaced implants, in comparison to machine-surfaced implants. A retrospective study by Wim et al. evaluated the effect of various grafting materials on implant survival rate and marginal bone loss around implants in 80 patients over a period of 3-10 years (64). They found that the overall implant survival rate was 92% for xenografts, in comparison to autografts or allografts, which both had a success rate of 100%. No significant difference in marginal bone loss between the three types of materials was found. In a retrospective study by Jamcoski et al., the influence of grafting material, residual crest height and membrane perforation on the implant survival rate was studied in a sample of 472 sinus lift procedures (65). The follow-up time ranged from 3 months to 13 years. Also, in this study, no significant difference was found in implant survival rates between different grafting materials. Additionally, residual crest height does not seem to influence outcomes, given that the correct surgical method and loading protocols are followed. The conclusion is that membrane perforations do not seem to compromise implant survival if properly managed.

Interestingly, systematic reviews have shown that the volumetric reduction of the grafting material over time is smaller for xenografts (whether mixed with autologous bone or not) in comparison with autologous bone (66, 67, 68). Additionally, Dansesh-Sani et al. found that the percentage of vital bone formation is higher for autologous bone in comparison to xenografts (68). This outcome may, in part, explain the greater residual graft reduction with autologous bone. It is probable that the xenografts yield a greater bone volume, given that they are primarily osteoconductive, whereas autologous bone is more osteoinductive and osteogenic and less osteoconductive, resulting in more vital bone. Nevertheless, as discussed, there is no significant difference in implant survival rates for different grafting materials.

#### **4. SURGICAL TECHNIQUES**

#### **4.1 Prerequisites for Successful Bone Grafting**

Some aspects of bone physiology should be understood, including the factors that govern bone regeneration procedures during surgical procedures. For a bone graft to be incorporated into a defect, the three most important things to be considered are the biologic activity of the graft, the condition of the tissue environment of the graft, and the mechanical compression on the graft (69). Biologic activity of the graft was discussed in the previous chapter, specifically whether the graft is osteoconductive, osteoinductive or osteogenic. Osteogenic materials contain osteoblasts, while osteoconductive and osteoinductive materials are dependent on cells from the environment to differentiate into osteoblasts (causing delayed bone formation). The more biologically active a grafting material is, the less it is dependent on the environment in which it is grafted, and vice versa. Additionally, in dental medicine, generally, non-vascularized bone grafts are used, which are entirely dependent on the surrounding tissue for revascularization. Cancellous bone grafts are revascularised rapidly over several weeks to months and then completely due to their open architecture. In contrast, cortical bone grafts are revascularized more slowly, and not completely (70, 71).

The tissue environment of the graft is of great importance for both vascularisation and mechanical stability of the graft (69). Motion between the graft and the soft tissue of the host will prevent revascularisation, which is why immobilisation of the graft is so important. Moreover, onlay grafts, which are covered by relatively tight soft tissue, have to deal with a significant amount of compressive force, consequently, exhibit a greater amount of resorption. (70). On the other hand, inlay grafts are shielded from compressive soft tissue forces.

However, physical forces also appear in bone remodelling, and bone is deposited in areas which are subjected to stress and resorbed in areas where there is little stress (69, 70, 72). This mechanotransduction theory is far from fully understood, but physical forces are converted into cellular responses through various cell components, such as integrins, calcium channels, cell membrane deformation or hypoxia, resulting in the activation of different pathways and genes, and the production of a range of different molecules. The target genes of mechanotransduction are numerous, and also not very prominent in the literature. However, it has been demonstrated that the production of BMP proteins becomes elevated upon mechanical stimulation (73, 74).

Besides vascularity, a scaffolding function and mechanical stability, bone-forming cells and signalling molecules are also needed for bone regeneration to take place (71). A scaffolding function is provided by the grafting material or a blood clot, into which progenitor cells

migrate from adjacent tissues or are present in the case of autologous tissues. In this regard, space maintenance and isolation of the defect from non-osteogenic tissues are the key factors for successful bone regeneration. Lastly, as discussed previously, the lack of infections is crucial, given that they modulate the immune response towards inflammation instead of tissue repair, causing graft failure. Primary wound closure and asepsis are therefore important.

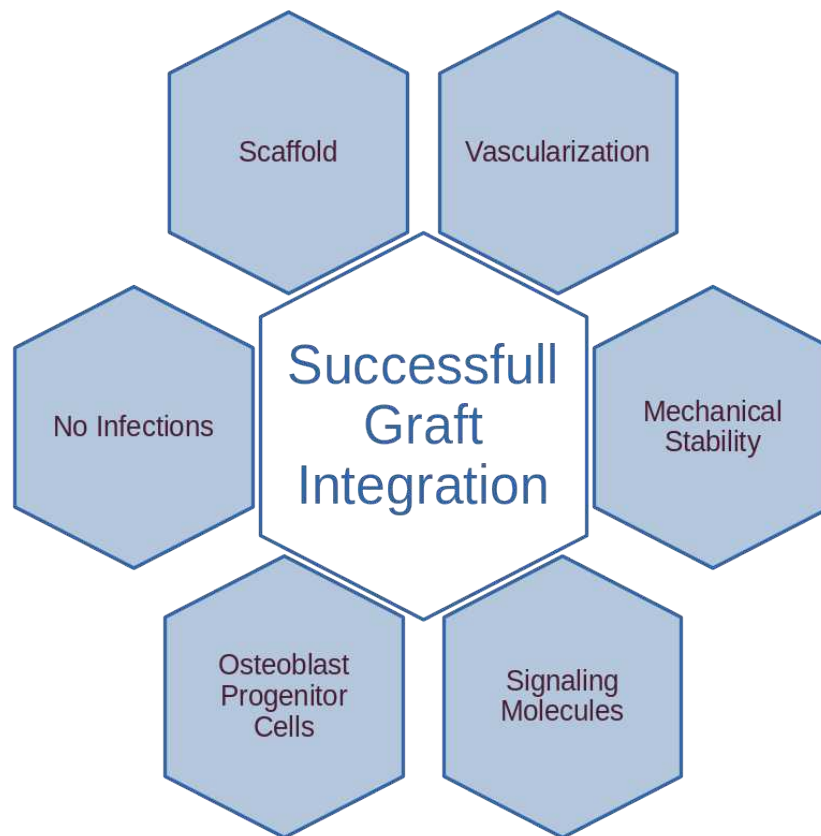


Figure 2. Prerequisites for successful bone graft integration.

To summarise, successful integration of the grafting material and maturation of woven bone into lamellar bone is dependent on the following: a scaffold, vascularisation, mechanical stability, bone-forming cells, signalling molecules and lack of infection, as schematically represented in (Fig. 2).

## 4.2 Transcrestal Approach

The transcrestal approach is the least invasive sinus lifting procedure, and can be used for mild cases of sinus pneumatisation where limited vertical height has to be gained. However, the technique is not suitable when insufficient bone in the bucco-palatal direction is present or significant vertical crestal bone resorption results in interarch discrepancies. In such cases, the transcrestal approach needs to be combined with horizontal and vertical GBR procedures. Since the transcrestal approach is the simplest and least invasive sinus lift procedure, it will be discussed here first, with the underlying philosophy focusing on minimising surgical intervention, time, cost, morbidity and complications to the patient whenever possible. When used in clinical situations as indicated, the implant survival rates of the transcrestal approach and the lateral window approaches are similar (75), and the current trend of mini implants and alternative methods means that this method will become even more popular in the future. In the subsequent chapters, the traditional lateral window procedure and methods for horizontal and vertical bone augmentation will be discussed.

The transcrestal sinus lift procedure can either be performed directly after extraction, by means of the furcation intrusion procedure, as described by Jensen (76, 77), or after the socket has healed, by means of the osteotome sinus floor elevation (OSFE) as originally described by Summers (22, 77, 78). Additionally, if the transcrestal approach is performed after the extraction socket has healed, it can either be executed with or without simultaneous implant placement, depending on obtaining primary implant stability.

The furcation intrusion procedure is very useful, given that the furcation of maxillary first molars often is within the maxillary sinus, and is associated with the sinus membrane. Besides that, it is difficult to lift the membrane from this region without perforating it, and this configuration typically leaves a low remaining bone height of around 5 mm (76, 77). To prevent this clinical situation, the furcation intrusion procedure can be used immediately after extraction to lift the furcation region up another 5 mm, creating sufficient height for implant placement 4 to 6 months later. If the crestal bone height is still insufficient after the healing period, the sinus floor can be elevated again during implant placement by means of OSFE to gain an additional few millimetres of vertical height. In this way, the lateral window approach can be avoided altogether.

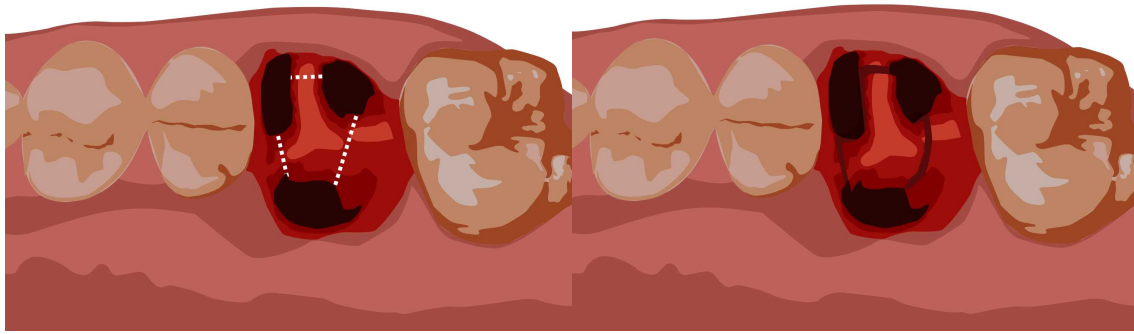


Figure 3. Illustration of the furcation intrusion procedure, where the inter-radicular bone is separated between the roots, and the fragment is up-fractured superiorly towards the sinus.

The goal of this procedure is to cut the inter-radicular bone inside the alveolar socket (Fig. 3) in an effort to free it from the surrounding bone and elevate it upwards to lodge it onto the sinus floor. Originally, the cuts inside the socket were performed with a spade osteotome (76). However, technological advances enabled the use of piezoelectric serrated tips, which carry a smaller risk of membrane perforation (77). Nevertheless, both techniques depend on tactile sensation (loss of resistance) to determine the depth of the osteotomies.

After the fragment is sectioned, a round-end osteotome is used to break it loose and elevate it superiorly, along with the membrane (77). The fragment is lodged between the sinus floor and membrane, and subsequent grafting, membrane placement or primary closure is not necessary. However, grafting the alveolar sockets results in a flatter and thicker alveolus (77). As for grafting materials, both xenografts and allografts can be used, given that one material has not proven to be superior to the other (77, 79). If the decision is made to graft the alveolus, a tension-free closure should be obtained (collagen membranes can be used to cover soft tissue deficiencies).

The osteotome sinus floor elevation (OSFE) is performed on a healed alveolar socket. There are certain limitations to when the technique can be used with simultaneous implant placement. A minimal bone height of 5 mm is required for multiple reasons (77). Firstly, if the crestal bone height is less, there will generally be insufficient bone for the simultaneous placement of regular-length implants. Recent studies are inconclusive on the use of short implants in the maxillary posterior region (80, 81, 82). Secondly, it is very probable that the primary stability of the implant will not be achieved. Lastly, the success rate drops when the remaining bone height is below 5 mm (77), so there is more evidence supporting the use of

the lateral window approach in such cases. When the remaining bone height is 5 mm or more, the sinus can be elevated with the OSFE approach and simultaneous placement of implants.

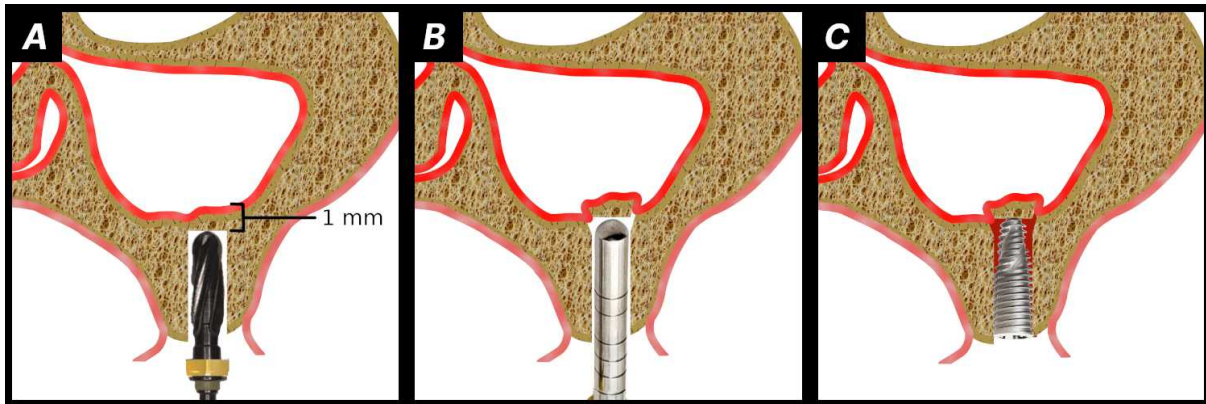


Figure 4. Schematic illustration of the osteotome sinus floor elevation (OSFE).

First, a crestal incision is made, and a minimal, full-thickness mucoperiosteal flap is elevated to visualise the alveolar crest. In the original method by Summers, only osteotomes were used for the preparation of the OSFE osteotomies and placement of the implants (22). However, newer methods involve drilling to a depth 1 mm short of the Schneiderian membrane (Fig. 4 A) (77, 79). The conical shape of the bur apex and the shape of the flutes result in an upward condensation of bone, facilitating easier lifting of the membrane. Even more modern techniques, such as the smart lift technique, have sequences of burs and calibrated stoppers, which limit the depth of preparation and reduce the risk of user errors (83). Moreover, the autologous bone collected in the flutes of the burs can be used as autologous grafting material (optionally mixed with xenograft for more volumetric gain). If the bone quality is low and there is very high trabecular bone content, the osteotomy for the implant can be slightly under-prepared for greater primary stability (84).

A conical osteotome and a mallet are then used to break this cortical bone plate and elevate it upward by about 1 mm, together with the sinus membrane (Fig. 4 B) (77, 79). Elevating the membrane further requires placing a small amount of graft material, and the floor is gently and incrementally elevated with the osteotome to the desired height. An alternative method for using osteotomes to elevate the sinus membrane is the transcresal hydraulic technique, where a hydraulic lifter is used towards this purpose for a smaller perforation risk (85, 86). If an implant is placed while using the OSFE procedure (Fig. 4 C), it will stabilise the Schneiderian membrane in a superior position, creating a vascularised space for a blood clot, which will be infiltrated by bone-forming cells from the surrounding tissue to differentiate



into viable bone (77). If implants are not placed simultaneously with OSFE, the site is grafted with a xenograft and left to heal for 4-6 months, after which implants are placed. If primary closure cannot be obtained in this case, a collagen membrane is used to cover the grafting material. When implants are placed simultaneously with OSFE, there is no evidence that the placement of grafting material results in higher implant survival in comparison to procedures where no graft is placed (87, 88, 89). It seems that a blood clot and space maintenance alone are sufficient for vital bone formation inside the sinus. Accordingly, several studies also used platelet-rich fibrin (PRF) as grafting material leading to successful results (90, 91, 92, 93). It appears that PRF is able to accelerate the healing process, possibly enabling earlier implant placement; however, according to systematic reviews, more research is needed on this topic (94, 95).

### **4.3 Lateral Window Approach**

The lateral window approach is suitable for more severe cases of sinus pneumatisation, given that the expected increase in bone height using this method is around twice as much as using the transcrestal method (96, 97). The technique can be used with any residual crest height. Furthermore, the lateral window approach is more appropriate when multiple implants have to be placed in the same region to avoid the need for multiple osteotomies through the transcrestal approach. It also provides direct access to bypass septa and other anatomical obstacles or to repair membrane perforations. However, the lateral window approach does not correct horizontal or vertical interarch deficiencies and, in such cases, has to be combined with horizontal and vertical GBR.

If there is sufficient crestal bone height and bone quality for primary implant stability, the window approach can be used for the simultaneous placement of implants; otherwise, a second surgical procedure for implant placement is needed (98, 99, 100, 101, 102). In general, sufficient primary implant stability can be expected when the residual crestal height is around 4-5 mm. However, recent studies have reported success when crestal bone height is smaller (98, 99, 101). This outcome is possibly due to the development of tapered implant designs containing microthreads in the coronal part (99). The implant surface area and treatment (acid etched, sand blasted etc.) are also important in this regard. Interestingly, one particular study seemed to find a greater correlation between smoking and graft resorption than between lack of residual crest height and graft resorption (101).

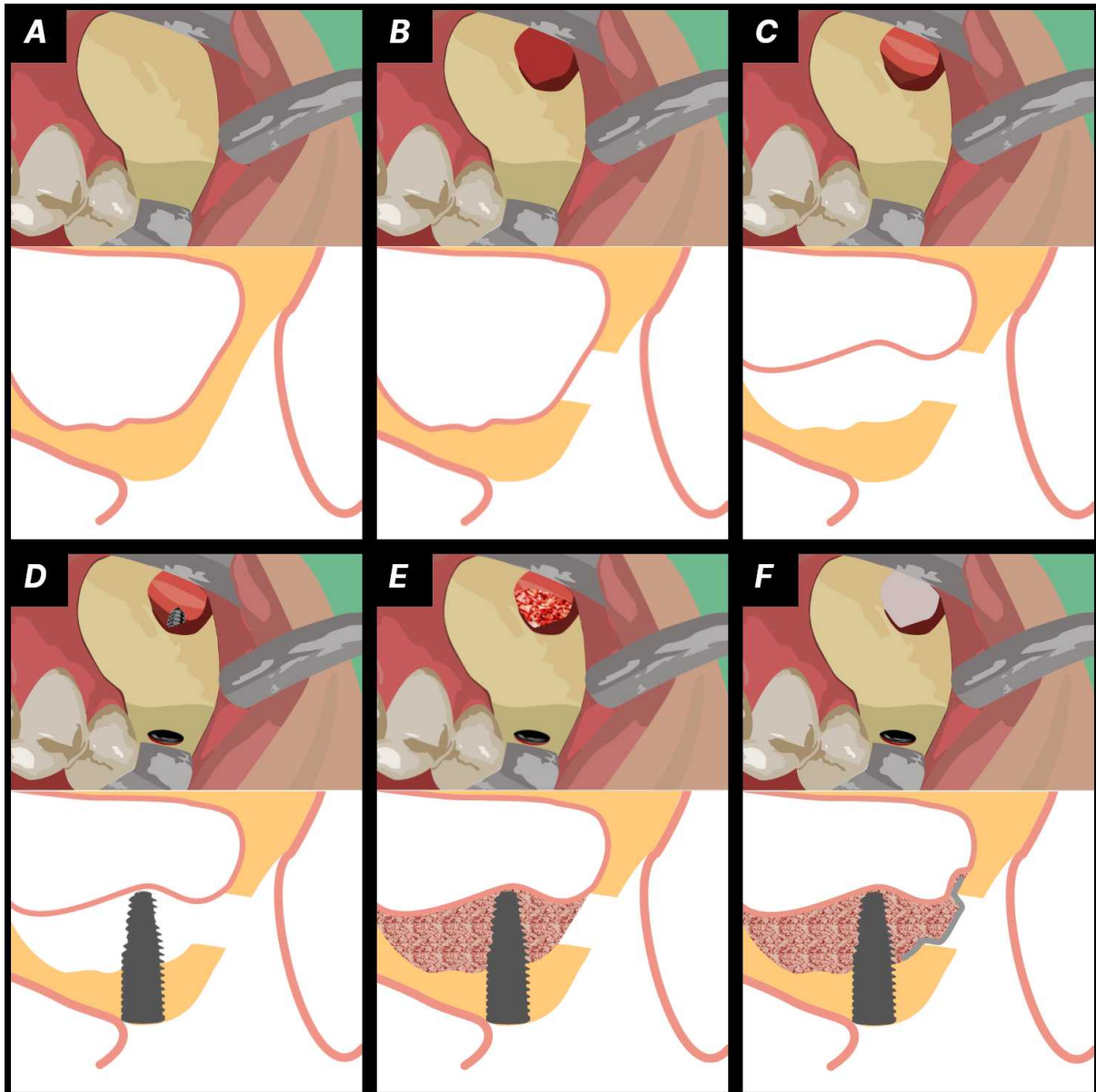


Figure 5. Illustration of the lateral window procedure

The lateral window procedure starts with a crestal incision (in keratinized gingiva) (97). If needed, two releasing incisions are made to create a flap with a broad base in order to preserve vascular supply. A full-thickness mucoperiosteal flap is raised to expose the area of the future window location (Fig. 5 A). When making the vertical releasing incisions, care must be taken to not damage the infra-orbital nerve and posterior superior alveolar artery.

The window location is dependent on the internal sinus anatomy, and it is best to create a window slightly distal (2-3 mm) to the anterior sinus wall and slightly superior to the sinus floor (3 mm). The window is then expanded to reach the anterior wall, distally and superiorly, as needed to account for the internal anatomy (Fig. 5 B). This approach is called the

Simplified Antrostomy Design (SAD) (97, 103, 104). Another option is a low window design, where the window is created as low and mesially as possible (104, 105, 106, 107). The precision of these procedures is increased using CBCT planning and CAD/CAM surgical guide manufacturing. In the case of the presence of septa inside the sinus cavity, it is wise to create windows on either side of this septum so that lifting the membrane in an anteroposterior direction over the septum (which greatly increases perforation risk) can be avoided (97).

As for window (antrostomy) design, there are many options, and certain designs have advantages over others. Either an outlining technique or osteoplasty can be used (97). In the case of a thin wall, the window is outlined with a bur and then removed or hinged into the sinus cavity. An osteoplasty is used in the case of a thick wall, where bone is removed to reach the Schneiderian membrane. Boyne originally used a carbide bur for the preparation of the window (12). The use of carbide burs in slow-speed surgical handpieces is still common today; however, the technique has been modified to switch to diamond burs as the membrane is approached to minimise the risk of membrane perforation (97). The continued development of instruments, such as piezoelectric devices, allows more precise differentiation between hard and soft tissues, reducing membrane perforation and bleeding risks even further. Another example is the Dentium Advanced Sinus Kit (DASK), which includes rotary, dome-shaped diamond burs. These burs also greatly reduce the risk of membrane perforation. When performing an outlining technique, an island or hinge design can be used. The island design is useful for removing the bone plate, while the hinge design is used when the fragment is up-fractured and elevated together with the membrane into the sinus.

Membrane elevation (Fig. 5 C) is traditionally performed with sinus elevators (97). Initiating membrane elevation is a difficult process, and there is a risk of perforating the membrane against the sinus walls if pinching occurs during the insertion of the elevator. Elevators should be sharp and be in contact with the bone surface at all times. Furthermore, membrane adhesions need to be dissected with a scalpel prior to elevation. As with window preparation, piezoelectric instruments enabled safer sinus membrane elevation. Different piezoelectric sinus elevators are available, including a funnel or trumped-shaped starting tip, which is used to avoid the pinching of the membrane upon insertion of the elevator. This tip makes a 2 mm circumferential membrane separation, after which subsequent elevator tips can be easier used. However, if managed correctly, membrane perforation does not influence surgical outcomes (108). The management of membrane perforations will be discussed later in the complications section.

After the membrane is elevated, optionally, an implant can be placed (Fig. 5 D) if it is expected that primary stability can be obtained. Grafting (Fig. 5 E) is performed using xenograft (with or without adjunctive autologous bone). However, the clinical outcomes in regard to implant survival are not affected by whether grafting is performed or not (109). Similarly, as with transcrestal approaches, PRF has also been used in direct sinus lifts; however, more research on this method is needed concerning its effectiveness (110, 111, 112).

Before suturing, it is advisable to place a resorbable collagen membrane over the antrostomy (Fig. 5 F) to prevent soft tissue invagination and adhesions of the Schneiderian membrane to the buccal mucosa (97). The membrane can be placed inside the window and stabilised against the sinus walls. It can also be stabilised with an overlying horizontal mattress suture. Primary intention closure can be obtained with either interrupted or continuous suturing techniques. It is advisable to start at the apical part of the releasing incisions (if present) and advance coronally in order to position the flap in a coronal position.

#### **4.4 Managing Crestal Width and Height Deficiencies**

As discussed previously, sinus elevation surgery does not correct horizontal and vertical crestal bone deficiencies. In such cases, reconstructive surgery is needed in addition to sinus lifting. The execution of these procedures will not be elaborated in this thesis, however, different available options for horizontal and vertical bone augmentation will be discussed here briefly.

Traditionally, horizontal bone regeneration is much more predictable than vertical bone regeneration (113, 114, 115). This is due to the fact that vertical bone augmentation requires extensive flap manipulation and closure over a large area without tension because pressure or tension from the flap results in greater resorption of the graft. Additionally, often the periosteum is damaged when the flap is stretched, which compromises soft tissue vascularisation and may result in the development of dehiscences. Bone block grafting has long been used for the treatment of vertical alveolar ridge defects, and there are well-documented uses in different clinical scenarios (115). The simplest approach is onlay grafting, where a bone block is fixed over the recipient site. Autologous bone is the gold standard for such grafting procedures because the proliferation of osteogenic cells into the defect is needed. Autologous bone can be obtained relatively easily from the mandibular ramus or maxillary tuberosity, and a bone scraper or trephine bur can be used for collection

(113). If more bone volume is needed, autologous bone can be combined with xenograft (116, 117). All soft tissue should be removed from the defect because soft tissue fibres left on the recipient site prevent proper attachment of the graft onto the underlying bone tissue (113). Furthermore, for onlay grafting, the recipient bed must be prepared by decortication to enable blood flow into the graft tissue. This can be achieved by drilling multiple small holes through the cortical plates into the trabecular bone. Another more advanced option is the use of inlay grafts, where the graft is placed between two segmental osteotomies (115). There is no detachment of soft tissues, and consequently, vascularisation to the graft is improved. Harvested plates of cortical bone can also be used in a so-called “shell” technique to create a space into which particulate bone graft can be contained.

If using GBR techniques for vertical bone augmentation, membranes must be used for space maintenance, and to prevent soft tissue ingrowth into the defect. However, PTFE and collagen membranes provide insufficient mechanical stability for large vertical defects, and PTFE membranes are often reinforced with titanium. Titanium meshes, which are completely fabricated from titanium alloy, have also been developed (119, 120, 121). The use of titanium meshes results in great vertical bone gain, but they have other disadvantages, such as requiring a second surgery for removal, and soft tissue dehiscences are not uncommon. Resorbable rigid membranes are now on the market in the form of magnesium membranes (122, 123, 124). These membranes provide mechanical stability similar to bone and are resorbed by corrosion over a period of around 10 weeks. Additionally, the degradation of such membranes results in the release of magnesium ions, which can be utilised for other biochemical processes, such as promoting cortical bone growth (in periosteal stem cells) and soft tissue adhesion (in gingival fibroblast cells) (123).

Regenerating the horizontal aspect of bony defects is easier because of the presence of walls containing the grafting material and providing osteogenic cells for the initiation of bone formation (113). Nevertheless, more and less demanding configurations of defects exist. In regard to vertical reconstructions, clinicians are limited to the height of the bone level of the adjacent teeth. A ridge cannot be raised higher than this level.

Another procedure for horizontal ridge augmentation, which can be combined with sinus elevation, is the alveolar split approach (24, 124). The alveolar split is a form of osteoperiosteal flap, and is used for horizontal ridge augmentation. A segmental osteotomy is performed through the alveolar crest, with two vertical osteotomies on the buccal aspect. This segment is then greenstick outfractured in the form of an osteoperiosteal book or island flap. The difference between a book or an island flap is whether the fragment is attached to the

underlying bone, and the amount of mobilisation. For additional vertical height, the sinus membrane can then be lifted from the alveolar crest by means of an osteotome, and the intersplit area is grafted with a particulate bone graft. The principle of the alveolar split approach is opposite to that of an onlay bone block, and vascularisation is provided by the intact overlying periosteum and soft tissues of the osteoperiosteal flap. Consequently, healing is relatively fast and uneventful. Additionally, if primary stability can be obtained, implants can be placed immediately, which is often the case with thick book flaps. The procedure can also be performed immediately post-extraction; however, in such cases, implant placement is usually delayed.

#### **4.5 Managing Complications**

Unfortunately, despite the high predictability and success rates of sinus lifting procedures, complications do occur. Complications may be intra-operative or post-operative. The most frequent intra-operative complication with sinus elevation procedures is Schneiderian membrane perforation. According to different studies, the lateral window approach has a perforation incidence within the range of 7- 44%, and the perforation incidence is between 0-17% for the transcresal method (23, 11, 125). According to a meta-analysis, the perforation rate is found to be significantly lower when using piezoelectric instruments in comparison to conventional rotary instrumentation (126). Anatomical and procedural risk factors which lead to membrane perforation have been discussed earlier in this text. Most membrane perforations can be avoided with correct planning and careful elevation of the membrane. However, if they do occur, the management of membrane perforations consists of patching the defect with a resorbable collagen membrane or PRF. Suturing is also an option but can be quite difficult to perform. Minor perforations may not necessarily need to be treated. On the other hand, if the perforation is very large, the procedure should be abandoned and the membrane left to heal over a period of 4-6 months (11).

Another intraoperative complication is profuse bleeding from damage to the anterior antral artery (AAA) (23, 25, 103). As discussed previously, the AAA should be visualised on CBCT. In the case of a large-diameter intraosseous artery, a recommended approach is to dissect the surrounding bone with piezoelectric instruments, ligate and cut the artery. Another option is to isolate it by performing a double window antrostomy. If bleeding does occur, digital compression with gauze and local hemostatic factors should be applied first. If the

bleeding cannot be resolved, other methods include crushing the bone around the vessel with a hemostat or electrocautery.

Nerve damage to the infraorbital nerve is a very serious complication which can result in sensory deficits, ranging from a minor loss of sensation (hypoesthesia) to a major painful experience (dysesthesia) (127). The damage can be transitory or permanent, and patients find it very hard to cope with these neurosensory deficits, which interfere with many functions such as eating, speaking, or shaving. If the infraorbital nerve is intra-operatively damaged, the severed ends should be approximated, and topical dexamethasone (4 mg / mL) should be applied to the severed nerve. Dexamethasone may minimise the damage by reducing neural inflammation. The procedure should be abandoned because the placement of implants or grafting material may further irritate the damaged nerve fibres. Pharmacologic intervention should also commence immediately with systemic corticosteroids and non-steroidal anti-inflammatory drugs (NSAIDs). Additionally, cooling with ice packs is beneficial to minimise secondary nerve injury caused by compression from oedema. Referral to a neurologist is necessary in certain situations, such as in the case of complete nerve transection or persisting symptoms.

Ostium blockage may occur if the membrane is elevated over the opening of the osteomeatal complex and results in loss of sinus ventilation with subsequent post-operative chronic sinus infections and graft failure (125). Ostium blockage necessitates the removal of the graft and the prescription of systemic antibiotics. Graft or implant displacement can also occur, either intra-operatively or post-operatively. If an implant is displaced into the sinus, it must be recovered by means of a Cadwell-Luc operation (23, 125). Graft material can also be displaced through perforated Schneiderian membranes, and if the particles are large, they can block the osteomeatal complex (97). In such cases, the grafting material should be removed. Other less serious complications are buccal flap tears (which can be managed by suturing) and transient benign paroxysmal vertigo using the transcrestal approach (125).

Besides anatomical and procedural considerations, patient preparation is also an important aspect in preventing complications (97). In this regard, all relative contraindications must be resolved prior to surgery, and antibiotic prophylaxis and post-operative antibiotic therapy should be provided. Post-operative corticosteroids are also useful in reducing post-operative swelling and inflammation. Post-operative instructions given to the patient should include a liquid diet, no chewing on the surgical site and no nose blowing (23).



**5. DISCUSSION**

Sinus lifting, and implant dentistry, in general, is a very dynamic field of dentistry, and many new techniques and materials are under development. Discussing every method in detail in this paper is impossible. Therefore, the focus has been on a fundamental understanding of how bone grafting and implant placement in the posterior maxilla are performed by discussing the two most applied methods of sinus elevation surgery. Different grafting materials have been compared, including a discussion on how they affect implant survival rates and clinical success. Furthermore, the indications for sinus grafting, and the various methods more suitable for specific cases have also been discussed. Risk factors for certain complications and how they can be avoided by meticulous planning for the best possible outcome have also been addressed.

Future developments in sinus elevation surgery should focus on improving different aspects of the procedure, such as grafting materials, implant design, membranes, growth factors, new surgical instruments for safer membrane elevation, and safer procedures in terms of better planning and guided surgery.

Research is performed on the development of new synthetic bone grafting materials and tissue-engineered scaffolds with improved characteristics such as mechanical stability and resorption rates (128, 129). Based on these new synthetic materials, there are efforts to develop scaffolds for bone tissue regeneration. Polymers such as polylactic acid (PLA) and polycaprolactone (PCL) are widely used for developing bio-engineered scaffolds. For example, these polymers can be combined into nanostructures by electrospinning, altering characteristics such as pore size and surface area (130). However, the integration of these scaffolds with the microvascular network of the recipient site remains a challenge (128). Consequently, the clinical application of these innovations remains on a small scale. Phytogetic materials for bone grafting, either algae or plant-based, have also been developed (131, 132). Some of these materials have satisfactory characteristics and are cost-effective, however, the lack of data about their clinical efficacy is a limiting factor to their widespread use. Furthermore, grafting materials are enhanced with growth factors such as BMP-2, FGFs and VEGFs to increase their osteogenic capacity, and are already in clinical use with promising results (56, 128). New generations of rigid resorbable membranes are now on the market, such as magnesium membranes, which can provide a good solution to vertical bone augmentation, without the need for secondary surgery (133). However, more research is needed on the exposure rates of magnesium membranes and the possible onset of dehiscences upon exposure.

New instruments and procedures make sinus elevation a more predictable procedure. Some of these instruments, such as piezoelectric instruments and the DASK kit, have already been discussed in the surgical procedures section of this thesis. Guided sinus elevation surgery has also been mentioned, which was developed by Mandelaris and Rosenfeld in 2009 (134). Guided surgery improves the precision of sinus elevation, making the procedure easier with fewer complications. There are static and dynamic approaches to guided surgery (42). In static guided surgery, physical guides are designed on the basis of a CBCT image and produced by 3D printing. This approach has been demonstrated to yield more consistent results (135, 136). Dynamic guided surgery, where no physical guide is used but real-time navigation is performed, also shows promising results (137, 138, 139). However, most investigations performed on dynamic guided surgery are in the form of case reports or small-scale studies, and further clinical research is needed to support its efficacy (42, 140).

It should also not be forgotten that for the severely resorbed maxilla alternative methods to sinus grafting are also available, such as zygomatic and pterygoid implants. Zygomatic implants were introduced by Prof. P. I. Brånemark in 1988 in an effort to rehabilitate patients with massive trauma or those undergoing aggressive resective surgery (141). Later, in 1998, he presented the idea of using zygomatic implants to rehabilitate patients with severe maxillary atrophy (142). The survival rates of zygomatic implants and regular-size implants placed after sinus lifting are similar (143, 144). However, zygomatic implants are associated with more complications. Mini implants also hold promise for the future; however, researchers acknowledge that long-term follow-up studies are needed on implant survival rates (81, 145, 146, 147). Another alternative is that individualised subperiosteal implants exist for most atrophic cases (148). These implants are individually designed on the basis of the CBCT image and fabricated using 3D printing.

In summary, a great volume of promising new research is appearing, but more clinical trials are needed to prove the efficacy of these new materials and methods. Unfortunately, options for the heavily resorbed mandible remain much more limited.

**6. CONCLUSION**

Sinus elevation surgery has been successfully performed for almost half a century, evolving into a highly predictable and successful procedure performed in dental offices all over the world. The demand for sinus lifting will grow in the future, and new methods will continue to be developed, making the procedure easier, safer, less invasive, cheaper and more readily available. There is a general trend towards minimally invasiveness and personalised medicine. An example of minimal invasiveness is the development of safer instruments that can distinguish between hard and soft tissue. Guided surgery is a form of personalised medicine which further reduces invasiveness. Moreover, as implants develop in synergy with the development of surgical procedures, more possibilities for immediate loading are emerging with less need for secondary surgeries. As of now, the choice of grafting material does not seem to influence outcomes of sinus grafting; however, that may change in the future as new materials come on the market, providing higher success rates, faster healing rates and earlier implant placement. In conclusion, sinus elevation surgery has become a routine surgical procedure, with success rates similar to that of implants placed in bone which is not grafted, and will continue to play an important role in implant dentistry.

**REFERENCES**

1. Borg-Bartolo R, Rocuzzo A, Molinero-Mourelle P, Schimmel M, Gambetta-Tessini K, Chaurasia A, et al. Global prevalence of edentulism and dental caries in middle-aged and elderly persons: A systematic review and meta-analysis. *J Dent.* 2022;127:104335. doi:10.1016/j.jdent.2022.104335
2. Shugars D, Bader J, Phillips S, White B, Brantley C. The consequences of not replacing a missing posterior tooth. *J Am Dent Assoc.* 2000;131:1317–23. doi:10.14219/jada.archive.2000.0385
3. Bandiaky ON, Lokossou DL, Soueidan A, le Bars P, Gueye M, Mbodj EB, et al. Implant-supported removable partial dentures compared to conventional dentures: A systematic review and meta-analysis of quality of life, patient satisfaction, and biomechanical complications. *Clin Exp Dent Res.* 2022;8(1):294–312. doi:10.1002/cre2.521
4. Duong HY, Rocuzzo A, Stähli A, Salvi GE, Lang NP, Sculean A. Oral health-related quality of life of patients rehabilitated with fixed and removable implant-supported dental prostheses. *Periodontol 2000.* 2022;88(1):201–37. doi:10.1111/prd.12419
5. Weatherspoon DJ, Chen H, Dye BA. Implant and implant restoration trends among adults 50 years and older in the United States, National Health and Nutrition Examination Survey 1999-2020. *J Am Dent Assoc.* 2024;22(1):185. doi:10.1016/j.adaj.2024.03.005
6. IMARC Group. Europe Dental Implants Market Report by Material (Titanium Dental Implants, Zirconium Dental Implants), Product (Endosteal Implants, Subperiosteal Implants, Transosteal Implants, Intramucosal Implants), End Use (Hospitals, Dental Clinics, Academic and Research Institutes, and Others), and Country 2024-2032. Brooklyn; 2023 Jul. Report ID: SI2452.
7. Lin M, Griffin SO, Gooch BF, Espinoza L, Wei L, Li C-H, et al. Oral health surveillance report: trends in dental caries and sealants, tooth retention, and edentulism, United States: 1999–2004 to 2011–2016. 2019; Available from: [www.cdc.gov/oralhealth/publications/OHSR-2019-index.html](http://www.cdc.gov/oralhealth/publications/OHSR-2019-index.html)
8. Directorate-General for Economic and Financial Affairs. 2024 Ageing Report. Economic and budgetary projections for the EU Member States (2022-2070). Brussels: European Commission; 2024 Apr 18. doi:10.2765/022983.
9. Kaufman E. Maxillary sinus elevation surgery: an overview. *J Esthet Restor Dent.* 2003;15(5):272–82; discussion 283. doi:10.1111/j.1708-8240.2003.tb00298.x
10. Shemtov-Yona K. Quantitative assessment of the jawbone quality classification: A meta-analysis study. *PLoS One.* 2021;16(6). doi:10.1371/journal.pone.0253283
11. Alshamrani AM, Mubarki M, Alsager AS, Alsharif HK, Al Humaidan SA, Al-Omar A. Maxillary Sinus Lift Procedures: An Overview of Current Techniques, Presurgical Evaluation, and Complications. *Cureus.* 2023. doi:10.7759/cureus.49553
12. Boyne PJ, James RA. Grafting of the maxillary sinus floor with autogenous marrow and bone. *J Oral Surg.* 1980;38(8):613–6. PMID: 6993637
13. Chiapasco M, Zaniboni M, Boisco M. Augmentation procedures for the rehabilitation of deficient edentulous ridges with oral implants. *Clin Oral Implants Res.* 2006;17 Suppl 2:136–59. doi:10.1111/j.1600-0501.2006.01357.x
14. Chiapasco M, Zaniboni M, Rimondini L. Dental implants placed in grafted maxillary sinuses: a retrospective analysis of clinical outcome according to the initial clinical situation and a proposal of defect classification. *Clin Oral Implants Res.* 2008;19(4):416–28. doi:10.1111/j.1600-0501.2007.01489.x
15. Coots BK. Alveolar bone grafting: past, present, and new horizons. *Semin Plast Surg.* 2012;26(4):178-183. doi:10.1055/s-0033-1333887

16. Johanson B, Ohlsson A. Bone grafting and dental orthopedics in primary and secondary cases of cleft lip and palate. *Acta Chir Scand.* 1961;122:112-124,
17. Liang W. Natural Implant Restoration in Stable Alveolar Bone (NIRISAB)-Concepts in Clinical Practice: Long-Term Follow-up on Three Cases of Ridge Reconstruction Using the Tunnel Approach With Remote Incision. *J Oral Implantol.* 2023;49(2):130-146. doi:10.1563/aaid-joi-D-22-00032
18. Tatum H Jr. Endosteal implants. *CDA J.* 1988;16(2):71-76.
19. Jensen OT, ed. *The sinus bone graft.* 3rd ed. Chicago: Quintessence Publishing; 2019. p. xiii-xx.
20. Tatum H Jr. Lecture presented to the Alabama Implant Congress. 1976.
21. Tatum H Jr. Maxillary and Sinus Implant Reconstructions. *Dent Clin North Am.* 1986;30(2):207-229.
22. Summers RB. A new concept in maxillary implant surgery: the osteotome technique. *Compendium.* 1994;15(2):152-162.
23. Bathla SC, Fry RR, Majumdar K. Maxillary sinus augmentation. *J Indian Soc Periodontol.* 2018;22(6):468–73. doi:10.4103/jisp.jisp\_236\_18.
24. Tolstunov L, Cullum DR, Jensen OT. The alveolar split approach for sinus floor intrusion. In: Jensen OT, ed. *The Sinus Bone Graft.* 3rd ed. Chicago, IL: Quintessence Publishing; 2019. p. 32-41.
25. Kim J, Jang H. A review of complications of maxillary sinus augmentation and available treatment methods. *J Korean Assoc Oral Maxillofac Surg.* 2019;45(4):220-224. doi:10.5125/jkaoms.2019.45.4.220
26. Hwang D, Wang HL. Medical contraindications to implant therapy: part I: absolute contraindications. *Implant Dent.* 2006;15(4):353–60. doi:10.1097/01.id.0000247855.75691.03
27. Hwang D, Wang HL. Medical contraindications to implant therapy: Part II: Relative contraindications. *Implant Dent.* 2007;16(1):13–23. doi:10.1097/ID.0b013e31803276c8
28. Battisti AS, Modi P, Pangia J. Sinusitis. [Updated 2023 Mar 2]. In: *StatPearls [Internet]. Treasure Island (FL): StatPearls Publishing; 2024 Jan.* Available from: <https://www.ncbi.nlm.nih.gov/books/NBK470383/>
29. Chow AW, Benninger MS, Brook I, et al. IDSA clinical practice guideline for acute bacterial rhinosinusitis in children and adults. *Clin Infect Dis.* 2012;54(8):e72-e112. doi:10.1093/cid/cir1043
30. Akhondi H, Woldemariam B, Rajasurya V. Fungal Sinusitis. [Updated 2023 Jul 3]. In: *StatPearls [Internet]. Treasure Island (FL): StatPearls Publishing; 2024 Jan-.* Available from: <https://www.ncbi.nlm.nih.gov/books/NBK551496/>
31. Patel NA, Ferguson BJ. Odontogenic sinusitis: an ancient but under-appreciated cause of maxillary sinusitis. *Curr Opin Otolaryngol Head Neck Surg.* 2012;20(1):24-28. doi:10.1097/MOO.0b013e32834e62ed
32. Nulty A. A literature review on prosthetically designed guided implant placement and the factors influencing dental implant success. *British Dental Journal.* 2024;236(3):169–80. doi:10.1038/s41415-024-7050-3
33. Sharma A, Rawat P, Gupta U, Tomar S, Tyagi M, Shukla K. Occlusion considerations in implant supported prosthesis: A Review. 2023 Apr 15;3:11. doi:10.5281/zenodo.7834087
34. Kovacic I, Celebić A, Knezovic D, Stipetić J, Papić M. Influence of body mass index and the time of edentulousness on the residual alveolar ridge resorption in complete denture wearers. *Collegium antropologicum.* 2003 Feb 1;27 Suppl 2:69–74.
35. Pietrokovski J, Starinsky R, Arensburg B, Kaffe I. Morphologic characteristics of bony edentulous jaws. *J Prosthodont.* 2007;16(2):141–7. doi:10.1111/j.1532-849X.2007.00165.x

36. Lim HC, Kim S, Kim DH, Herr Y, Chung JH, Shin S il. Factors affecting maxillary sinus pneumatization following posterior maxillary tooth extraction. *J Periodontal Implant Sci.* 2021;51(4):285–95. doi:10.5051/jpis.2007220361
37. Marino MJ, Riley CA, Wu EL, Weinstein JE, Emerson N, McCoul ED. Variability of Paranasal Sinus Pneumatization in the Absence of Sinus Disease. *Ochsner J.* 2020;20(2):170–5. doi:10.31486/toj.19.0053
38. Chiapasco M, Zaniboni M. Methods to treat the edentulous posterior maxilla: implants with sinus grafting. *J Oral Maxillofac Surg.* 2009;67(4):867-871. doi:10.1016/j.joms.2008.11.023
39. Chrcanovic BR, Albrektsson T, Wennerberg A. Bone Quality and Quantity and Dental Implant Failure: A Systematic Review and Meta-analysis. *Int J Prosthodont.* 2017;30(3):219–237. doi:10.11607/ijp.5142
40. Lekholm U, Zarb GA. In: Patient selection and preparation. *Tissue integrated prostheses: osseointegration in clinical dentistry.* Branemark PI, Zarb GA, Albrektsson T, editor. Chicago: Quintessence Publishing Company; 1985. p. 199–209.
41. Resnik RR, Misch CE. Bone Density: A Key Determinant for Treatment Planning. fourth. In: Resnik RR, editor. *Misch’s contemporary implant dentistry.* 4th edition. Elsevier Inc.; 2020. pp. 450–466.
42. Morgan N, Meeus J, Shujaat S, Cortellini S, Bornstein MM, Jacobs R. CBCT for Diagnostics, Treatment Planning and Monitoring of Sinus Floor Elevation Procedures. *Diagnostics (Basel).* 2023;13(10). doi:10.3390/diagnostics13101684
43. Baker EW, Schuenke M, Schulte E. *Anatomy for Dental Medicine.* 2nd edition. Thieme; 2015. pp. 174–177.
44. Whyte A, Boeddinghaus R. The maxillary sinus: physiology, development and imaging anatomy. *Dentomaxillofac Radiol.* 2019;48(8):20190205. doi:10.1259/dmfr.20190205
45. Iwanaga J, Wilson C, Lachkar S, Tomaszewski KA, Walocha JA, Tubbs RS. Clinical anatomy of the maxillary sinus: application to sinus floor augmentation. *Anat Cell Biol.* 2019;52(1):17-24. doi:10.5115/acb.2019.52.1.17
46. Tiwana PS, Kushner GM, Haug RH. Maxillary Sinus Augmentation. *Dental Clinics of North America.* 2006;50(3):409–24. Available from: <https://www.sciencedirect.com/science/article/pii/S0011853206000358>
47. Vaddi A, Villagran S, Muttanahally KS, Tadinada A. Evaluation of available height, location, and patency of the ostium for sinus augmentation from an implant treatment planning perspective. *Imaging Sci Dent.* 2021;51(3):243–50. doi:10.5624/isd.20200218
48. Shokri A, Lari S, Yousefi F, Hashemi L. Assessment of the relationship between the maxillary sinus floor and maxillary posterior teeth roots using cone beam computed tomography. *Journal of Contemporary Dental Practice.* 2015;15(5):618–22.
49. Krennmair G, Ulm C, Lugmayr H. Maxillary sinus septa: incidence, morphology and clinical implications. *J Craniomaxillofac Surg.* 1997;25(5):261–5. doi:10.1016/s1010-5182(97)80063-7
50. Kim M, Jung U, Kim C, Kim K, Choi S, Kim C, et al. Maxillary Sinus Septa: Prevalence, Height, Location, and Morphology. A Reformatted Computed Tomography Scan Analysis. *Journal of Periodontology.* 2006 May;77(5):903–8.
51. Assari A, Alotaibi N, Alajaji MA, Alqarni A, Ali Alarishi M. Characteristics of Maxillary Sinus Septa: A Cone-Beam Computed Tomography Evaluation. *Int J Dent.* 2022;2022:2050257. doi:10.1155/2022/2050257
52. Iwanaga J, Tanaka T, Ibaragi S, Okui T, Hamaguchi J, Min S, et al. Revisiting major anatomical risk factors of maxillary sinus lift and soft tissue graft harvesting for dental implant surgeons. *Surg Radiol Anat.* 2020;42(9):1025–31. doi:10.1007/s00276-020-02468-w



53. Kqiku L, Biblekaj R, Weiglein AH, Kqiku X, Städtler P. Arterial blood architecture of the maxillary sinus in dentate specimens. *Croat Med J*. 2013;54(2):180–4. doi:10.3325/cmj.2013.54.180
54. Kalyvas D, Kapsalas A, Paikou S, Tsiklakis K. Thickness of the Schneiderian membrane and its correlation with anatomical structures and demographic parameters using CBCT tomography: a retrospective study. *Int J Implant Dent*. 2018;4(1):32. Published 2018 Oct 19. doi:10.1186/s40729-018-0143-5
55. Rapani M, Rapani C, Ricci L. Schneider membrane thickness classification evaluated by cone-beam computed tomography and its importance in the predictability of perforation. Retrospective analysis of 200 patients. *British Journal of Oral and Maxillofacial Surgery*. 2016 Dec 1;54(10):1106–10. doi:10.1016/j.bjoms.2016.08.003
56. Kumar P, Vinita B, Fathima G. Bone grafts in dentistry. *J Pharm Bioallied Sci*. 2013;5(Suppl 1):S125-S127. doi:10.4103/0975-7406.113312
57. Horowitz RA, Leventis MD, Rohrer MD, Prasad HS. Bone grafting: history, rationale, and selection of materials and techniques. *Compend Contin Educ Dent*. 2014;35(4 Suppl):1-6;quiz7. Available from: <https://www.ncbi.nlm.nih.gov/pubmed/25455148>
58. Ferraz MP. Bone Grafts in Dental Medicine: An Overview of Autografts, Allografts and Synthetic Materials. *Materials (Basel)*. 2023;16(11). doi:10.3390/ma16114117
59. Pietruszka P, Chruścicka I, Duś-Ilnicka I, Paradowska-Stolarz A. PRP and PRF-Subgroups and Divisions When Used in Dentistry. *J Pers Med*. 2021;11(10):944. Published 2021 Sep 23. doi:10.3390/jpm11100944
60. Borie E, Oliví DG, Orsi IA, et al. Platelet-rich fibrin application in dentistry: a literature review. *Int J Clin Exp Med*. 2015;8(5):7922-7929. Published 2015 May 15.
61. Wang D, Zhou X, Cao H, Zhang H, Wang D, Guo J, et al. Barrier membranes for periodontal guided bone regeneration: a potential therapeutic strategy. *Frontiers in Materials*. 2023;10. Available from: <https://www.frontiersin.org/articles/10.3389/fmats.2023.1220420>
62. Elgali I, Omar O, Dahlin C, Thomsen P. Guided bone regeneration: materials and biological mechanisms revisited. *Eur J Oral Sci*. 2017;125(5):315-337. doi:10.1111/eos.12364
63. del Fabbro M, Testori T, Francetti L, Weinstein R. Systematic review of survival rates for implants placed in the grafted maxillary sinus. *Int J Periodontics Restorative Dent*. 2004;24(6):565–77. Available from: <https://www.ncbi.nlm.nih.gov/pubmed/15626319>
64. Win KZ, Pimkhaokham A, Kaboosaya B. Comparing Bone Graft Success, Implant Survival Rate, and Marginal Bone Loss: A Retrospective Study on Materials and Influential Factors. *J Oral Implantol*. Published online April 30, 2024. doi:10.1563/aaid-joi-D-23-00165
65. Jamcoski VH, Faot F, Marcello-Machado RM, Melo ACM, Fontão FNGK. 15-Year Retrospective Study on the Success Rate of Maxillary Sinus Augmentation and Implants: Influence of Bone Substitute Type, Presurgical Bone Height, and Membrane Perforation during Sinus Lift. *Biomed Res Int*. 2023;2023:9144661. Published 2023 Feb 20. doi:10.1155/2023/9144661
66. Shanbhag S, Shanbhag V, Stavropoulos A. Volume changes of maxillary sinus augmentations over time: a systematic review. *Int J Oral Maxillofac Implants*. 2014;29(4):881-892. doi:10.11607/jomi.3472
67. Starch-Jensen T, Deluiz D, Vitenson J, Bruun NH, Tinoco EMB. Maxillary sinus floor augmentation with autogenous bone graft compared with a composite grafting material or bone substitute alone: A systematic review and meta-analysis assessing volumetric stability of the grafting material. *J Oral Maxillofac Res*. 2021;12(1):e1. doi:10.5037/jom.2021.12101
68. Danesh-Sani SA, Engebretson SP, Janal MN. Histomorphometric results of different grafting materials and effect of healing time on bone maturation after sinus floor augmentation: a systematic review and meta-analysis. *J Periodontal Res*. 2017;52(3):301–12. doi:10.1111/jre.12402

69. Stevenson S, Emery SE, Goldberg VM. Factors affecting bone graft incorporation. *Clin Orthop Relat Res.* 1996;(324):66-74. doi:10.1097/00003086-199603000-00009
70. Oppenheimer AJ, Tong L, Buchman SR. Craniofacial Bone Grafting: Wolff's Law Revisited. *Cranio-maxillofac Trauma Reconstr.* 2008;1(1):49-61. doi:10.1055/s-0028-1098963
71. Donos N, Akcali A, Padhye N, Sculean A, Calciolari E. Bone regeneration in implant dentistry: Which are the factors affecting the clinical outcome? *Periodontol* 2000. 2023;93(1):26–55. doi:10.1111/prd.12518
72. Dissaux C, Wagner D, George D, Spingarn C, Rémond Y. Mechanical impairment on alveolar bone graft: A literature review. *Journal of Cranio-Maxillofacial Surgery.* 2019;47(1):149–57. Available from: <https://www.sciencedirect.com/science/article/pii/S1010518218304451>
73. Santos A, Bakker AD, Willems HME, Bravenboer N, Bronckers ALJJ, Klein-Nulend J. Mechanical loading stimulates BMP7, but not BMP2, production by osteocytes. *Calcif Tissue Int.* 2011;89(4):318–26. doi:10.1007/s00223-011-9521-1
74. Rui YF, Lui PPY, Ni M, Chan LS, Lee YW, Chan KM. Mechanical loading increased BMP-2 expression which promoted osteogenic differentiation of tendon-derived stem cells. *J Orthop Res.* 2011;29(3):390–6. doi:10.1002/jor.21218
75. Shah D, Chauhan C, Shah R. Survival rate of dental implant placed using various maxillary sinus floor elevation techniques: A systematic review and meta-analysis. *J Indian Prosthodont Soc.* 2022;22(3):215–24. doi:10.4103/jips.jips\_283\_22
76. Jensen OT, Brownd C, Baer D. Maxillary molar sinus floor intrusion at the time of dental extraction. *J Oral Maxillofac Surg.* 2006;64(9):1415–9. doi:10.1016/j.joms.2006.05.027
77. Block MS. Transcrestal Window Surgical Technique for Sinus Elevation. In: Jensen OT, ed. *The Sinus Bone Graft.* 3rd ed. Chicago, IL: Quintessence Publishing; 2019. p. 92-104.
78. Summers RB. Sinus floor elevation with osteotomes. *J Esthet Restor Dent.* 1998;10(3):164–71. doi:10.1111/j.1708-8240.1998.tb00352.x
79. Romero-Millán J, Martorell-Calatayud L, Peñarrocha M, García-Mira B. Indirect osteotome maxillary sinus floor elevation: an update. *J Oral Implantol.* 2012;38(6):799–804. doi:10.1563/AAID-JOI-D-11-00160
80. Atieh M, Zadeh H, Stanford C, Cooper L. Survival of Short Dental Implants for Treatment of Posterior Partial Edentulism: A Systematic Review. *The International journal of oral & maxillofacial implants.* 2012 Nov 1;27(6):1323–31.
81. Emfietzoglou R, Dereka X. Survival rates of short dental implants ( $\leq 6$  mm) used as an alternative to longer ( $> 6$  mm) implants for the rehabilitation of posterior partial edentulism: A systematic review of RCTs. *Dent J.* 2024;12(185). doi:10.3390/dj12060185
82. Xu X, Huang J, Fu X, Kuang Y, Yue H, Song J, et al. Short implants versus longer implants in the posterior alveolar region after an observation period of at least five years: A systematic review and meta-analysis. *Journal of Dentistry.* 2020;100(103386). Available from: <https://www.sciencedirect.com/science/article/pii/S0300571220301329>
83. Trombelli L, Farina R, Oltra DP, Franceschetti G. A minimally invasive technique for transcrestal sinus floor elevation. *Journal of Oral Science & Rehabilitation.* 2018;4(4):26–34.
84. Elian S, Abdelaal A. Measurement of implant insertion torque in intentionally undersized osteotomy site preparation in the posterior maxilla: A prospective clinical study. *J Oral Implantol.* 2024;50(2):119–24. doi:10.1563/aaid-joi-D-23-00067
85. Choi BH. Flapless Crestal Sinus Augmentation: Hydraulic Technique. In: *Vertical Alveolar Ridge Augmentation in Implant dentistry : A Surgical Manual.* Hoboken, New Jersey: John Wiley & Sons, Inc.; 2016. p. 152–60. doi:10.1002/9781119082835.ch15
86. Andreasi Bassi M, Lopez MA, Confalone L, Carinci F. Hydraulic sinus lift technique in future site development: clinical and histomorphometric analysis of human biopsies. *Implant Dent.* 2015;24(1):117–24. Available from: <http://dx.doi.org/10.1097/ID.0000000000000200>

87. Andrés-García R, Ríos-Santos JV, Herrero-Climent M, Bullón P, Fernández-Farhall J, Gómez-Menchero A, et al. Sinus floor elevation via an osteotome technique without biomaterials. *Int J Environ Res Public Health*. 2021;18(3):1103. doi:10.3390/ijerph18031103
88. Suk-Arj P, Wongchuensoontorn C, Taebunpakul P. Evaluation of bone formation following the osteotome sinus floor elevation technique without grafting using cone beam computed tomography: a preliminary study. *Int J Implant Dent*. 2019;5(1):27. doi:0.1186/s40729-019-0181-7
89. Starch-Jensen T, Bruun NH, Spin-Neto R. Outcomes following osteotome-mediated sinus floor elevation with Bio-Oss Collagen or no grafting material: a one-year single-blind randomized controlled trial. *Int J Oral Maxillofac Surg*. 2023;52(9):988–97. doi:10.1016/j.ijom.2022.12.009
90. Powell CA, Casarez-Quintana A, Zellner J, Al-Bayati O, Font K. The application of leukocyte-and platelet-rich fibrin (L-PRF) in maxillary sinus augmentation. *Clinic Adv Periodontics*. 2022;12(4):277–86. doi:10.1002/cap.10216
91. Shreehari, Sahoo NK, Kumar D, Malhi RS. Efficacy of platelet-rich fibrin in maxillary sinus augmentation and simultaneous implant placement in deficient maxillary ridges: A pilot comparative study. *Med J Armed Forces India*. 2022; doi:10.1016/j.mjafi.2022.08.007
92. Karagah A, Tabrizi R, Mohammadhosseinzade P, Mirzadeh M, Tofangchiha M, Lajolo C, et al. Effect of sinus floor augmentation with platelet-rich fibrin versus allogeneic bone graft on stability of one-stage dental implants: A split-mouth randomized clinical trial. *Int J Environ Res Public Health*. 2022;19(15):9569. doi:10.3390/ijerph19159569
93. Aoki N, Maeda M, Kurata M, Hirose M, Ojima Y, Wada K, et al. Sinus floor elevation with platelet-rich fibrin alone: A Clinical retrospective study of 1-7 years. *J Clin Exp Dent*. 2018;10(10):e984–91. doi:10.4317/jced.55113
94. Otero AIP, Fernandes JCH, Borges T, Nassani L, Castilho R de M, Fernandes GV de O. Sinus lift associated with leucocyte-platelet-rich fibrin (second generation) for bone gain: A systematic review. *J Clin Med*. 2022;11(7):1888. doi:10.3390/jcm11071888
95. Ali S, Bakry SA, Abd-Elhakam H. Platelet-rich fibrin in maxillary sinus augmentation: A systematic review. *J Oral Implantol*. 2015;41(6):746–53. doi:10.1563/aaaid-joi-D-14-00167
96. Pal US, Sharma NK, Singh RK, Mahammad S, Mehrotra D, Singh N, et al. Direct vs. indirect sinus lift procedure: A comparison. *Natl J Maxillofac Surg*. 2012;3(1):31–7. doi:10.4103/0975-5950.102148
97. Testori T, Sciani R, Deflorian M, Wallace SS, Tarnow DP. Lateral Window Surgical Techniques for Sinus Elevation. In: Jensen OT, ed. *The Sinus Bone Graft*. 3rd ed. Chicago, IL: Quintessence Publishing; 2019. p. 48-65.
98. Khandelwal P, Dhupar V, Akkara F, Hajira N. Direct maxillary sinus floor augmentation and simultaneous implant placement for rehabilitation of the severely resorbed posterior maxilla: A prospective clinical study. *Indian J Dent Res*. 2020;31(3):449–56. doi:10.4103/ijdr.IJDR\_848\_18
99. Cha HS, Kim A, Nowzari H, Chang HS, Ahn KM. Simultaneous sinus lift and implant installation: prospective study of consecutive two hundred seventeen sinus lift and four hundred sixty-two implants. *Clin Implant Dent Relat Res*. 2014;16(3):337–47. doi:10.1111/cid.12012
100. Valentini P, Artzi Z. Sinus augmentation procedure via the lateral window technique-Reducing invasiveness and preventing complications: A narrative review. *Periodontol* 2000. 2023;91(1):167–81. doi:10.1111/prd.12443
101. Gao S, Jiang Y, Yao Y, Li S, Cai X. Minimally invasive techniques for lateral maxillary sinus floor elevation: small lateral window and one-stage surgery a 2-5-year retrospective study. *Int J Oral Sci*. 2023;15(1):28. doi:10.1038/s41368-023-00233-4

102. D'Elia C, Baldini N, Gabriele G, Nuti N, Juloski J, Gennaro P. the Simultaneous sinus lift and implant placement using lateral approach in atrophic posterior maxilla with residual bone height of 5 mm or less. A systematic review. *J Osseointegration*. 2019;11(4):525–34. Available from: <https://www.journalofosseointegration.eu/index.php/jo/article/view/254>
103. Testori T, Tavelli L, Scaini R, Saibene AM, Felisati G, Barootchi S, et al. How to avoid intraoperative and postoperative complications in maxillary sinus elevation. *Periodontol* 2000. 2023;92(1):299–328. doi:10.1111/prd.12480
104. Zaniol T. Low window technique: A technical note. *Adv Dent Oral Health*. 2022;15(2). doi:10.19080/adoh.2022.15.555906
105. Zaniol T, Zaniol A. A rational approach to sinus augmentation: The Low Window Sinus Lift. *Case Rep Dent*. 2017;2017:7610607. doi:10.1155/2017/7610607
106. Zaniol T, Zaniol A, Tedesco A, Ravazzolo S. The Low Window sinus lift: A CAD-CAM-guided surgical technique for lateral sinus augmentation: A retrospective case series. *Implant Dent*. 2018;27(4):512–20. doi:10.1097/ID.0000000000000776
107. Zaniol T, Zaniol A, Ravazzolo S. The low window technique: Comparison between manual and CAD/CAM-guided design. *J Contemp Dent Pract*. 2021;22(4):400–5. doi:10.5005/jp-journals-10024-3079
108. Viña-Almunia J, Peñarrocha-Diago M, Peñarrocha-Diago M. Influence of perforation of the sinus membrane on the survival rate of implants placed after direct sinus lift. Literature update. *Med Oral Patol Oral Cir Bucal*. 2009;14(3):E133-6. Available from: <https://www.ncbi.nlm.nih.gov/pubmed/19242393>
109. Hegde R, Prasad K, Shroff KK. Maxillary sinus augmentation using sinus membrane elevation without grafts - A Systematic Review. *J Indian Prosthodont Soc*. 2016;16(4):317–22. doi:10.4103/0972-4052.191289
110. Pocaterra A, Caruso S, Bernardi S, Scagnoli L, Continenza MA, Gatto R. Effectiveness of platelet-rich plasma as an adjunctive material to bone graft: a systematic review and meta-analysis of randomized controlled clinical trials. *Int J Oral Maxillofac Surg*. 2016;45(8):1027–34. doi:10.1016/j.ijom.2016.02.012
111. Dominiak S, Karuga-Kuźniewska E, Popecki P, Kubasiewicz-Ross P. PRF versus xenograft in sinus augmentation in case of HA-coating implant placement: A 36-month retrospective study. *Adv Clin Exp Med*. 2021;30(6):633–40. doi:10.17219/acem/134202
112. Kumar M, Chopra S, Das D, Gupta M, Memoalia J, Verma G. Direct maxillary sinus floor augmentation for simultaneous dental implant placement. *Ann Maxillofac Surg*. 2018;8(2):188–92. doi:10.4103/ams.ams\_168\_18
113. Cadwell CS. Particulate Membrane grafting / Guided Bone Regeneration. In: Resnik RR, ed. *Misch's Contemporary Implant Dentistry*. 4th ed. St. Louis, MO: Elsevier; 2021. p. 933-986.
114. Rocchietta I, Fontana F, Simion M. Clinical outcomes of vertical bone augmentation to enable dental implant placement: a systematic review. *J Clin Periodontol*. 2008;35(8 Suppl):203–15. doi:10.1111/j.1600-051X.2008.01271.x
115. Urban IA, Montero E, Amerio E, Palombo D, Monje A. Techniques on vertical ridge augmentation: Indications and effectiveness. *Periodontol* 2000. 2023;93(1):153–82. doi:10.1111/prd.12471
116. Arnal HM, Angioni CD, Gaultier F, Urbinelli R, Urban IA. Horizontal guided bone regeneration on knife-edge ridges: A retrospective case-control pilot study comparing two surgical techniques. *Clin Implant Dent Relat Res*. 2022;24(2):211–21. doi:10.1111/cid.13073
117. Meloni SM, Jovanovic SA, Urban I, Baldoni E, Pisano M, Tallarico M. Horizontal ridge augmentation using GBR with a native collagen membrane and 1:1 ratio of particulate xenograft and autologous bone: A 3-year after final loading prospective clinical study. *Clin Implant Dent Relat Res*. 2019;21(4):669–77. doi:10.1111/cid.12808

118. Rocuzzo M, Ramieri G, Spada MC, Bianchi SD, Berrone S. Vertical alveolar ridge augmentation by means of a titanium mesh and autogenous bone grafts. *Clin Oral Implants Res.* 2004;15(1):73–81. doi:10.1111/j.1600-0501.2004.00998.x
119. Lee SY, Choi SH, Lee DW. Vertical ridge augmentation with customized titanium mesh using a 3D-Printing Model: A Prospective Study in Humans. *Int J Oral Maxillofac Implants.* 2024;39(1):153–63. doi:10.11607/jomi.10184
120. Zeynalzadeh F, Zahedpasha A. Vertical ridge augmentation by titanium mesh. In: *Innovative Perspectives in Oral and Maxillofacial Surgery.* Cham: Springer International Publishing; 2021. p. 259–65. doi:10.1007/978-3-030-75750-2\_28
121. Rider P, Kačarević ŽP, Elad A, Tadic D, Rothamel D, Sauer G, et al. Biodegradable magnesium barrier membrane used for guided bone regeneration in dental surgery. *Bioact Mater.* 2022;14:152–68. doi:10.1016/j.bioactmat.2021.11.018
122. Elad A, Rider P, Rogge S, Witte F, Tadić D, Kačarević ŽP, et al. Application of biodegradable magnesium membrane shield technique for immediate dentoalveolar bone regeneration. *Biomedicines.* 2023;11(3). doi:10.3390/biomedicines11030744
123. Blašković M, Butorac Prpić I, Blašković D, Rider P, Tomas M, Čandrlić S, et al. Guided bone regeneration using a novel magnesium membrane: A literature review and a report of two cases in humans. *J Funct Biomater.* 2023;14(6). doi:10.3390/jfb14060307
124. Jensen OT. Segmental alveolar split combined with dental extractions and osteotome sinus floor intrusion in posterior maxilla using BMP-2/ACS allograft for alveolar reconstruction: technical note and report of three cases. *J Oral Maxillofac Surg.* 2013;71(12):2040–7. doi:10.1016/j.joms.2013.07.017
125. Molina A, Sanz-Sánchez I, Sanz-Martín I, Ortiz-Vigón A, Sanz M. Complications in sinus lifting procedures: Classification and management. *Periodontol 2000.* 2022;88(1):103–15. doi:10.1111/prd.12414
126. Jordi C, Mukaddam K, Lambrecht JT, Kühl S. Membrane perforation rate in lateral maxillary sinus floor augmentation using conventional rotating instruments and piezoelectric device—a meta-analysis. *International Journal of Implant Dentistry.* 2018;4(1):3. doi:10.1186/s40729-017-0114-2
127. Resnik RR. 9 - Neurosensory Deficit Complications in Implant Dentistry. In: Resnik RR, Misch CE, editors. *Misch's Avoiding Complications in Oral Implantology.* Mosby; 2018. p. 329–63. ISBN: 978-0-323-37580-1
128. Valtanen RS, Yang YP, Gurtner GC, Maloney WJ, Lowenberg DW. Synthetic and Bone tissue engineering graft substitutes: What is the future? *Injury.* 2021;52 Suppl 2:S72–7. doi:10.1016/j.injury.2020.07.040
129. Alqahtani AM. Guided tissue and bone regeneration membranes: A review of biomaterials and techniques for periodontal treatments. *Polymers (Basel).* 2023;15(16). doi:10.3390/polym15163355
130. Ortega Z, Alemán ME, Donate R. Nanofibers and Microfibers for Osteochondral Tissue Engineering. In: *Osteochondral Tissue Engineering.* Cham: Springer International Publishing; 2018. p. 97–123. (Advances in experimental medicine and biology). doi:10.1007/978-3-319-76711-6\_5
131. Abu Alfar Sr TM, Alaida WS, Hammudah HA, Mohamado LL, Gaw RR, Al-Salamah L, et al. Exploring the potential of phytogenic materials for bone regeneration: A narrative review of current advances and future directions. *Cureus.* 2023;15(11):e48175. doi:10.7759/cureus.48175
132. Georgeanu V al, Gingu O, Antoniac I v, Manolea HO. Current options and future perspectives on bone graft and biomaterials substitutes for bone repair, from clinical needs to advanced biomaterials research. *Appl Sci (Basel).* 2023;13(14):8471. doi:10.3390/app13148471

133. Palkovics D, Rider P, Rogge S, Kačarević ŽP, Windisch P. Possible applications for a biodegradable magnesium membrane in alveolar ridge augmentation-retrospective case report with two years of follow-up. *Medicina (Kaunas)*. 2023;59(10). doi:10.3390/medicina59101698
134. Mandelaris GA, Rosenfeld AL. A novel approach to the antral sinus bone graft technique: the use of a prototype cutting guide for precise outlining of the lateral wall. A case report [published correction appears in *Int J Periodontics Restorative Dent*. 2009 Feb;29(1):105]. *Int J Periodontics Restorative Dent*. 2008;28(6):569-575. PMID: 19146052
135. Pistilli R, Canullo L, Pesce P, Pistilli V, Caponio VCA, Sbricoli L. Guided implant surgery and sinus lift in severely resorbed maxillae: A retrospective clinical study with up to 10 years of follow-up. *J Dent*. 2022;121(104137):104137. doi:10.1016/j.jdent.2022.104137
136. Tattan M, Chambrone L, González-Martín O, Avila-Ortiz G. Static computer-aided, partially guided, and free-handed implant placement: A systematic review and meta-analysis of randomized controlled trials. *Clin Oral Implants Res*. 2020;31(10):889–916. doi:10.1111/clr.13635
137. Dotia A, Selvaganesh S, R P A, Nesappan T. Dynamic navigation protocol for direct sinus lift and simultaneous implant placement: A case report. *Cureus*. 2024;16(2):e53621. doi:10.7759/cureus.53621
138. Jain S, Solanki A. A dynamic surgical navigational approach for immediate implantation and transcresal sinus augmentation. *J Indian Soc Periodontol*. 2021;25(5):451–6. doi:10.4103/jisp.jisp\_581\_20
139. Yang M, Ma Y, Han W, Qu Z. The safety of maxillary sinus floor elevation and the accuracy of implant placement using dynamic navigation. *PLoS One*. 2024;19(5):e0304091. doi:10.1371/journal.pone.0304091
140. Gargallo-Albiol J, Barootchi S, Salomó-Coll O, Wang HL. Advantages and disadvantages of implant navigation surgery. A review. *Ann Anat*. 2019;225:1–10. doi:10.1016/j.aanat.2019.04.005
141. Migliorança R, Irschlinger A, Peñarrocha-Diago M, Fabris R, Aizcorbe-Vicente J, Zotarelli Filho I. History of zygomatic implants: A systematic review and meta-analysis. *Dent Oral Craniofac Res*. 2019;5(2):1–9. doi:10.15761/docr.1000289
142. Brånemark PI. *Surgery and Fixture Installation: Zygomaticus Fixture Clinical Procedures*. 1st ed. Goteborg, Sweden: Nobel Biocare AB; 1998. p. 1.
143. Balaji SM, Balaji P. Comparative evaluation of direct sinus lift with bone graft and zygoma implant for atrophic maxilla. *Indian J Dent Res*. 2020;31(3):389–95. doi:10.4103/ijdr.IJDR\_410\_20
144. Gutiérrez Muñoz D, Obrador Aldover C, Zubizarreta-Macho Á, González Menéndez H, Lorrio Castro J, Peñarrocha-Oltra D, et al. Survival rate and prosthetic and sinus complications of zygomatic dental implants for the rehabilitation of the atrophic edentulous maxilla: A systematic review and meta-analysis. *Biology (Basel)*. 2021;10(7):601. doi:10.3390/biology10070601
145. Mundt T, Heinemann F, Müller J, Schwahn C, al Jaghsi A. Survival and stability of strategic mini-implants with immediate or delayed loading under removable partial dentures: a 3-year randomized controlled clinical trial. *Clin Oral Investig*. 2023;27(4):1767–79. doi:10.1007/s00784-022-04805-2
146. Elsyad MA, Gebreel AA, Fouad MM, Elshoukouki AH. The clinical and radiographic outcome of immediately loaded mini implants supporting a mandibular overdenture. A 3-year prospective study. *J Oral Rehabil*. 2011;38(11):827–34. doi:10.1111/j.1365-2842.2011.02213.x

147. Chen Y, Cai Z, Zheng D, Lin P, Cai Y, Hong S, et al. Inlay osteotome sinus floor elevation with concentrated growth factor application and simultaneous short implant placement in severely atrophic maxilla. *Sci Rep.* 2016;6(1). doi:10.1038/srep27348
148. Ângelo DF, Vieira Ferreira JR. The role of custom-made subperiosteal implants for rehabilitation of atrophic jaws - A case report. *Ann Maxillofac Surg.* 2020;10(2):507–11. doi:10.4103/ams.ams\_263\_20

## **Biography**

Ozren Radić was born in Bosnia and Herzegovina in 1989 and grew up in the Netherlands. He completed his master's degree in biomedical sciences in 2018 at the Vrije Universiteit in Amsterdam. During his studies, he did internships at the Academisch Centrum Tandheelkunde Amsterdam (ACTA), Amsterdam Universiteit Medisch Centrum (Amsterdam UMC, formerly AMC) and Toegepast Natuurwetenschappelijk Onderzoek (TNO). During these internships, he performed experimental research in immunology (ACTA and AMC) and was involved in business development of governmental healthcare programs (TNO). While studying dental medicine at the University of Zagreb, he became involved in implant dentistry in the 5th year of his studies.