

The dental pulp - biology, pathology and regenerative potential

Oellerich, Hendrik Benjamin

Master's thesis / Diplomski rad

2024

Degree Grantor / Ustanova koja je dodijelila akademski / stručni stupanj: **University of Zagreb, School of Dental Medicine / Sveučilište u Zagrebu, Stomatološki fakultet**

Permanent link / Trajna poveznica: <https://um.nsk.hr/um:nbn:hr:127:955122>

Rights / Prava: [Attribution-NonCommercial 4.0 International/Imenovanje-Nekomercijalno 4.0 međunarodna](#)

Download date / Datum preuzimanja: **2024-10-02**



Repository / Repozitorij:

[University of Zagreb School of Dental Medicine Repository](#)





University of Zagreb
School of Dental Medicine

Hendrik Benjamin Oellerich

**THE DENTAL PULP –
BIOLOGY, PATHOLOGY AND
REGENERATIVE POTENTIAL**

GRADUATE THESIS

Zagreb, 2024

The work was carried out at: Department of Dental Anthropology, School of Dental Medicine,
University of Zagreb.

Thesis mentor: Professor Ivana Savić Pavičin, DMD, PhD, Department of Anthropology

English language proofreader: Christiane Storm-Oellerich, StD'in, former Head of Department
at BBS BRV

Croatian language proofreader: Vesna Pudrlja

The composition of the Commission for the defense of the thesis:

1. Professor Ivana Savić Pavičin, DMD, PhD, Department of Anthropology

2. Professor

3. Professor

Dentistry

Date of thesis defense:

Paper contains: 50 pages

0 tables

3 figures

0 CD

The work is the author's own work, which is completely independently written with an indication of the sources of other authors and documents used in the work. Unless it is not otherwise stated, all illustrations (tables, pictures, etc.) in the paper are the original contribution of the post-graduate author specialist work. The author is responsible for obtaining permission to use illustrations that are not his original contribution, as well as for all possible consequences that may arise due to the illegality downloading of illustrations, i.e. failure to state their origin.

I would like to dedicate this work to my loving parents, my twin brother and in memory to my grandfather Rudolf. I am truly thankful for your tireless support and encouragement in the pursuit of my dreams. I am honored to look up to your shining examples of accomplished and honest lives. Thank you for your wisdom and unwavering guidance on my journey and for always believing in me. I could not have done it without you. You made me the man I am today, and I am forever grateful to have you in my life.

THE DENTAL PULP – BIOLOGY, PATHOLOGY AND REGENERATIVE POTENTIAL

Summary

Today the field of endodontics has become an indispensable part of dentistry. The term endodontics is derived from the Greek words “endo”, meaning inside and “odont”, meaning tooth referring to treatments of pulp and root canal system located inside of the tooth. The current treatment gold standard in endodontics is root canal treatment including partial or total removal of the pulpal tissues followed by root canal obturation.

New findings in the fields of genetics, tissue engineering and stem cell research give reason to believe that regeneration of the tissues which comprise the tooth pulp may be possible in the future.

The aim of this thesis is to provide an overview of the research and therapeutic approaches of regenerative strategies in endodontics. Current research advances, discussion approaches and potential future clinical applications of these technologies in endodontics are presented. The reader is equipped with the relevant knowledge to understand the basics of anatomy, pathology, and regenerative treatment approaches in endodontics.

The recent research advances regarding endodontic regenerative therapies documented in scientific literature are promising. However, the development of guidelines for the clinical application has so far failed due to the lack of sufficient successful patient trials as well as ethical and safety concerns. The technological complexity of such treatment approaches and the associated costs for regenerative endodontic interventions indicate clear obstacles to a timely and wide application of this desirable advance in endodontics.

Key words: endodontic therapy; regeneration; tissue engineering

ZUBNA PULPA – BIOLOGIJA, PATOLOGIJA I REGENERATIVNI POTENCIJAL

Sažetak

Danas je područje endodoncije neizostavan dio stomatologije. Riječ endodoncija izvedena je iz grčkih riječi "endo", što znači 'unutar' i "odont", što znači 'zub'. Pojam se odnosi na tretmane liječenja pulpe i sustava korijenskih kanala koji se nalaze unutar zuba. Trenutno zlatni standard liječenja u endodonciji podrazumjeva liječenje korijenskih kanala uključujući djelomično ili potpuno uklanjanje pulpnog tkiva nakon čega slijedi obturacija odnosno punjenje korijenskih kanala.

Nova otkrića i istraživanja iz područja genetike, tkivnog inženjerstvu te istraživanja matičnih stanica daju nadu za moguću regeneraciju tkiva koja čine zubnu pulpu u budućnosti.

Cilj ovog rada je dati pregled istraživanja, terapijskih pristupa i regenerativnih strategija u endodonciji. Prikazan je trenutačni napredak u istraživanjima, značajne diskusije u tom području i potencijalna buduća klinička primjena ovih tehnologija u endodonciji. Čitatelj je opskrbljen relevantnim spoznajama bitnim za razumijevanje osnova anatomije, patologije i regenerativnih pristupa liječenju u endodonciji.

Nedavna istraživanja u vezi s endodontskim regenerativnim terapijama dokumentirana u znanstvenoj literaturi obećavaju mnogo i vrlo su optimistična. Međutim, smjernice za kliničku primjenu nisu još uvijek dostupne zbog nedovoljnog broja uspješnih ispitivanja na pacijentima, kao i zbog etičkih i sigurnosnih pitanja. Tehnološka složenost takvih pristupa liječenja i povezani troškovi regenerativnih endodontskih intervencija ukazuju jasno na prepreke pravodobnoj i širokoj primjeni ovog poželjnog napretka u endodonciji.

Ključne riječi: endodontska terapija; regeneracija; tkivno inženjerstvo

TABLE OF CONTENTS

1. INTRODUCTION.....	1
1.1. Definition of tissue engineering.....	2
1.2. Definition of stem cell therapy.....	2
1.3. Aim.....	2
2. STRUCTURE AND HISTOLOGY OF THE PULP.....	3
2.1. The dentin layer.....	4
2.2. The predentin layer	4
2.3. The odontoblast layer	4
2.4. The subodontoblastic layer	5
2.5. The pulp	6
3. DEVELOPMENT OF TOOTH AND PULP	7
3.1. Embryonal development of the face	8
3.2. Embryonal development of teeth and pulp	8
3.2.1. Initiation of tooth development	8
3.2.2. Bud stage, cap stage, and bell stage	9
3.2.3. Development of enamel and dentin	10
4. PATHOLOGY OF THE PULP AND ITS REACTION TO OUTSIDE STIMULI	11
4.1. Demineralization by cariogenic bacteria	12
4.2. Destruction of dental tissue by caries	13
4.2.1. The enamel caries lesion	14
4.2.2. The dentin caries lesion	14
4.3. Reaction of the dentinopulpal complex to harmful stimuli	15
4.4. Progression from reversible pulpitis to periapical disease	18
5. REGENERATIVE THERAPIES IN ENDODONTICS	19
5.1. Regenerative endodontic procedures / revascularization	21
5.2. Acellular approach	23
5.2.1. Exogenous signaling molecules	24
5.2.2. Scaffolds	24
5.2.3. Endogenous signaling molecules	26
5.3. Cellular approach	26
5.3.1. The stem cell niche	29

5.4. Ectopic and orthotopic models for pulp regeneration	30
5.5. Gene therapy	32
5.6. Risks and safety concerns associated with stem cell therapy and tissue engineering	33
6. DISCUSSION	34
7. CONCLUSION	37
8. REFERENCES	39
9. BIOGRAPHY	49

List of abbreviations

BMP	Bone morphogenetic protein
CRISPR-Cas9	clustered regular interspaced short palindromic repeats
DPSC	dental pulp stem cells
EDTA	Ethylenediamine tetraacetic acid
ICDAS	International Caries Detection and Assessment System
FGF	Fibroblast growth factor
NGF	Nerve growth factor
PDGF	Platelet-derived growth factor
PDLSC	Periodontal ligament stem cells
PRF	Platelet-rich fibrin
PRP	Platelet-rich plasma
SCAP	Stem cells from the apical papilla
SHED	Stem cells from human exfoliated deciduous teeth
TGF- β	Transforming growth factor β

1. INTRODUCTION

Currently, the most common treatment for diseases of the endodontic system of the teeth is pulpectomy or pulpotomy, that is, the complete or partial removal of the pulp, depending on the severity of the disease, followed by disinfection and obturation of the endodontic system. Although this approach has proven effective in relieving patients' symptoms, it is only a reparative approach. Current research with two main focusses – tissue engineering and stem cell research – shows that regeneration of the dental pulp could be possible in the future (1).

1.1. Definition of Tissue Engineering

“Tissue Engineering” deals with the artificial building of tissues. In most cases, cells are harvested from the patient, proliferated in vitro under controlled conditions, and then reimplanted with a structural framework to replace damaged tissue. In the field of dentistry, research focuses on the use of stem cells to regenerate the dental pulp. Further investigations are underway, aiming to regenerate the whole tooth and its supporting structures (2,3).

1.2. Definition of Stem Cell Therapy

Stem cell therapy comprises all treatment procedures in which stem cells are a vital component of the therapy. The longest practiced form of stem cell therapy is the treatment of leukemia.

In the 1990s, many more stem cells were discovered and isolated. Stem cells can be obtained from both embryonic and adult tissues. Embryonic stem cells are pluripotent, adult stem cells are multipotent, meaning they have a decreased differentiation potential. Research focuses on the factors that allow for the differentiation of stem cells into specific tissue types.

For ethical reasons, the development of stem cell research, especially regarding the use of embryonic stem cells, has been repeatedly delayed and banned in several countries around the world. As current research focuses more on the use of adult stem cells, it is to be hoped that a variety of treatment options will nonetheless emerge in the future (4,5).

1.3. Aim

The focus of this work is to provide an overview of the developing regenerative therapies in the field of endodontics with a focus on tissue engineering and stem cell therapy.

Initially the description of the structure and development process of the dentinopulpal complex is explained. Further, the pathogenic influences affecting the pulp are described and the structures and mechanisms by which teeth are protected against damage are clarified. Following this, current clinical trends, research advances and future applications of regenerative therapies are critically analyzed and considered in terms of their clinical applicability and potential risks.

2. STRUCTURE AND HISTOLOGY OF THE PULP

The dental pulp is situated inside the pulp chamber, centrally located inside the tooth, and protected by encapsulating layers of dentin, cementum and enamel. In histological sections different layers of the “dentin-pulp complex” can be distinguished, namely the dentin layer, predentin layer, odontoblast layer, the subodontoblastic layer which can be divided into the cell free and cell rich zone and the pulp proper (6).

The dentinopulpal complex constitutes the functional unity of both tissues and comprises highly mineralized dentin, which provides protection against outside stimuli, and the pulp situated inside the dentin, which provides nutrients and innervation to the dentin. Further the pulp keeps the tooth vital, thereby enabling it to adapt to external influences and fend off infections (7).

2.1. The dentin layer

The dentin layer is positioned subjacent to the enamel coronally or cementum in the radicular area. It forms the bulk of the tooth's structure. The dentin layer has a specific outer zone in the coronal area, called “mantle dentin”. It is 15-30 nm thick and has sparse tubules interspaced in its structure. It is less mineralized enabling it to dissipate forces acting on the enamel above to prevent potential enamel cracks. Below the mantle dentin is the “circumpulpal dentin” which constitutes the bulk of the dentin mass. It is interspersed with canals, called “dentin tubules”. The tubules extend all the way through the circumpulpal dentin and reach the odontoblastic layer. The dentin between its tubules is called intertubular dentin and makes up most of the dentin mass. The tubular lumen is lined with peritubular dentin and houses the odontoblastic processes, which secrete dentin and extend from the odontoblasts' cell bodies. Further, the tubular fluid fills the space between odontoblastic processes and peritubular dentin and is associated with the sensation of pain (8).

2.2. The predentin layer

The predentin layer is an unmineralized matrix, 10 to 50 µm thick, situated between dentin and odontoblasts. Predentin is composed of collagen and is gradually mineralized to turn into dentin by the integration of noncollagenous matrix proteins (9).

2.3. The odontoblast layer

The odontoblast layer is located directly subjacent to the predentin layer with the processes of the odontoblasts extending through the predentin and partly through the dentin layer. Therefore, only the cell bodies of the odontoblasts can be found in the odontoblast layer. Also, capillaries, dendritic cells and nerve fibers are located among the odontoblasts. Odontoblasts in the young

coronal portion of the pulp appear to be layered in 3-5 layers although there is only one layer of cells present here. This appearance is caused by the differing height of the tall columnar form of the odontoblasts at this stage, which causes their nuclei to be positioned at various levels; therefore, the cells assume what is described as a palisade appearance.

Odontoblasts have intercellular spaces of 30 to 40 nm. Adjacent odontoblasts' cell bodies are connected by desmosomes, tight and gap junctions. Gap junctions are formed by connexin proteins that permit cell-to-cell passage of signal molecules and further allow passage of molecules to synchronize secretion activity and enable production of uniformly secreted predentin layers. Desmosomes, in the apical portion of the cell bodies, mechanically anchor the odontoblasts to each other. Tight junctions are mostly present apically in odontoblasts of young teeth. They close off intercellular spaces and potentially determine the permeability of the odontoblast layer of ions and molecules when dentin is covered by enamel or cementum. Further, desmosomes and gap junctions join odontoblasts to fibroblast processes in the subodontoblastic region (7,10).

There are more cells in the coronal area of the odontoblast layer than in the radicular area. In the coronal area the cells obtain a columnar shape, while being more cuboidal in the midportion of the radicular area and flattened squamous in appearance at the apical foramen. Changes in shape here are thought to be caused by the presence of fewer dentinal tubules in the radicular area compared to the coronal area, and therefore allow the cell bodies to spread out laterally, resulting in a more flattened appearance (11). Continued secretion by the odontoblasts throughout life causes narrowing of the pulp space. Therefore, crowding in the odontoblast layer, especially in the coronal portion of the pulp, is inevitable and will lead to apoptosis of several odontoblasts to account for the loss of space during development (7,12).

2.4. The subodontoblastic layer

The subodontoblastic layer is positioned directly below the odontoblastic layer in the pulp. It is divided into two different zones with different histology. The first zone, immediately in contact with the odontoblastic layer, is of approximately 40 nm in diameter and relatively free of cells. Therefore, it was named "cell-free zone of Weil". Albeit its name, there are several contents of this layer, namely traversing capillaries, unmyelinated nerve fibers and cytoplasmic processes of fibroblasts (7).

Previously, different authors labelled the cell-free zone as a fixation artifact (6). This might not be the case and studies suggested that the presence of the cell-free zone depends on the

functional and developmental state of the pulp. Since odontoblasts may move towards the pulp during development and later to a limited extent during secretion of dentin as well. Therefore, the absence of the cell-free zone might be explained by odontoblasts that filled the space during their function with dentin or occupy the space themselves while moving continuously further towards the center of the pulp (7,13).

Subjacent to the cell free zone, resides the “cell-rich zone”. It contains a large number of fibroblasts, immune cells like macrophages and dendritic cells, undifferentiated mesenchymal stem cells and capillaries, which arise from blood vessels deeper in the pulp.

It has been proposed that, around eruption of the teeth, the migration of the cell populations that stem from the central pulp region towards the periphery caused the formation of the cell-rich zone. Antigenic challenge has been shown to cause movement of immune cells to and from the cell-rich zone. Therefore, migration of the tooth into the oral cavity via eruption might symbol such an antigenic challenge, justifying migration of cells and development of the cell-rich zone (7,14,15).

2.5. The pulp

The pulp proper is the most central area of the pulp and constitutes the mass of the pulp. It is largely composed of connective tissues, blood vessels and nerves. It harbors numerous cells, albeit not as densely packed as in the cell-rich zone. Like the cell-rich zone it contains fibroblasts, which make up the majority of the cells here, and undifferentiated mesenchymal stem cells. In addition, many immune cells can be found in the pulp proper, namely macrophages, dendritic cells, mast cells, neutrophils, eosinophils, basophils, lymphocytes and monocytes. The numbers of these immune cells rise during inflammatory processes in the area.

The blood vessels that supply the pulp originate from the superior and inferior alveolar arteries, which enter through the apical foramen of the root or through lateral and accessory openings (7,16). Upon entering the root apex, these arteries branch into smaller arterioles and ascend upward, running in the central area of the radicular pulp. These arterioles give off lateral branches towards the odontoblast layer, which ramify and form capillary fishnet-like plexuses. In the coronal area the arterioles spread out towards the dentin and form a dense network of capillaries, which supplies the odontoblasts there (17,18).

The blood flow in these capillary networks is twice as high in the coronal segment compared to the radicular area, and highest overall in the pulp horns (19).

3. DEVELOPMENT OF TOOTH AND PULP

To understand the development of the teeth and their pulps we must first dive into the topic of embryology, so that we are able to understand the interplay of the involved tissues.

3.1. Embryonal development of the face

Initially the fertilized ovum undergoes rapid cell division to form the morula, which organizes itself into the blastocyst. In the second week of the development the blastocyst differentiates into a bilaminar disc which is divided into epiblast and hypoblast. In the third week, during gastrulation, cells from the epiblast migrate inward through the primitive streak and give rise to the three germ layers ectoderm, mesoderm and endoderm. These layers will eventually give rise to all the tissues in the human body. Afterwards, during and after the third week in utero, the neurulation starts and forms the neural crest cells which play a significant role later (20).

Fast forwarding to the fourth week of intrauterine development, we can already differentiate several structures of the embryo. In the sagittal section we can appreciate the primitive mouth, termed “stomatodeum” or “stomodeum”, which represents the area of greatest interest for our understanding regarding the teeth (9,21,22).

3.2. Embryonal development of teeth and pulp

In the sixth intrauterine week, the stomodeum is lined with primitive oral epithelium. Underneath this is a layer of connective tissue into which neural crest cells have migrated from their ectodermal origin. This tissue is therefore called ectomesenchyme. The process of the development of the teeth and their pulps can be described as an intricate interplay between this primitive oral epithelium and the ectomesenchymal cells.

3.2.1. Initiation of tooth development

This complex process begins around day thirty-seven, in the sixth week of intrauterine development. Initially the basal cells of the oral epithelium start proliferating into the underlying ectomesenchyme. There they form two continuous bands of epithelium. One in the space where the maxilla will eventually be located and another where the mandible will form later. These epithelial proliferations, which are termed “primary epithelial bands”, are located between the tongue, that forms on one side, and the tissues that differentiate into the cheek and lip on the other side.

The horseshoe-shaped primary epithelial bands bifurcate to first form an inner process, called “dental lamina” located towards the tongue, and shortly after an outer process, called “vestibular lamina” towards the side of cheek and lip. The vestibular lamina will give rise to the oral

vestibule by quickly proliferating and growing deeper into the underlying tissue, followed by the degeneration of the cells in the center of this proliferation, which leave behind a furrow. This furrow marks the oral vestibule, the area between the tooth bearing area on one side and the lip and cheek on the other side.

On the other hand, the teeth will originate from the dental lamina. This process starts with the dental lamina displaying localized growths of cells, termed “dental placodes”. The upper and lower dental lamina will each give rise to ten placodes, which correspond to the deciduous teeth later. The permanent teeth develop from lingually positioned outgrowths, called “successional laminae”, which are associated with these 20 initial placodes respectively. The permanent molars, however, do not have respective predecessors in the deciduous dentition and therefore develop in a different way. To give rise to the dental placodes of the permanent molars the dental laminae grow longer distally, and then delve posteriorly into the ectomesenchymal tissue below. This posterior expansion of the tissue then forms the placodes of the permanent molars (23).

3.2.2. Bud stage, cap stage and bell stage

The following development from the dental placode to the complete tooth is a continuous process but has been broken down to several phases, termed bud, cap and bell stage. These names refer to the morphology that is assumed by the cells of the oral epithelium in respective stages of development.

The further differentiation of the dental placodes starts in the eighth week with the oral epithelium proliferating and invaginating into the underlying ectomesenchymal tissue to then assume the shape of a bud. This tooth bud consists of central polygonal cells and low columnar cells in its periphery. Furthermore, the ectomesenchyme subjacent to the tooth bud will become more condensed in its cellular structure.

In the ninth week, the bud will undergo morphological transformation caused by an unequal rate of cell proliferation. This will lead to the formation of an invagination in the central part of the bud which will thereby assume a different appearance that is termed cap or cap stage. Furthermore, the cells of the cap are now referred to as enamel organ, since they will eventually give rise to the enamel. Additionally, the condensation of ectomesenchymal cells below the enamel organ will be termed dental papilla and will give rise to the dentin and pulp of the tooth. Moreover, the cells surrounding the dental papilla and enclosing the enamel organ are termed dental follicle and differentiate into the periodontal ligament and participate in the development of cementum and alveolar bone. The inner enamel epithelium is constituted of short columnar

cells lining the enamel organ towards the dental papilla, while the low cuboidal cells lining its periphery are termed outer enamel epithelium.

In the transition from cap to bell stage, the central cells between inner and outer enamel epithelium will secrete hydrophilic glycosaminoglycans, which attract water into their extracellular compartments. The central cells will thereby become pushed apart, only remaining connected by their desmosomal junctions, which gives them a star-shaped appearance, hence this cell group is called stellate reticulum. Enamel knots form as dense nondividing collection of cells above the inner enamel epithelium and function as signaling centers and determine the shape of the tooth crown.

Continuing growth of the cap leads to yet another shape of the enamel organ around the 11th week of development, which is called bell or bell stage. Early in the bell stage histodifferentiation and morphodifferentiation take place. Histodifferentiation describes processes, in which cells of the dental papilla are induced by the inner enamel epithelium to differentiate into odontoblast and the cells of the inner enamel epithelium themselves differentiate into ameloblasts. Morphodifferentiation refers to the determination of the tooth shape. The stratum intermedium, a layer of cells that develops in between the stellate reticulum and inner enamel epithelium, is important in enamel production.

3.2.3. Development of enamel and dentin

Later in the bell stage, the dental lamina will undergo degeneration and leave behind the cell rests of Serres (24).

Further the ameloblasts and odontoblasts will start to form enamel and dentin. Then the stellate reticulum will collapse. When the formation of dentin and enamel reaches the cervical loop, the area where inner and outer enamel epithelium meet, a two-cell layer called Hertwig's epithelial root sheath, is formed. This extension of the outer and inner enamel epithelium grows into the underlying ectomesenchyme and separates dental papilla and dental follicle. It extends further to correspond to the later shape of the root, leaving only a small apical space, the epithelial diaphragm, which eventually constitutes the apical foramen. Hertwig's epithelial root sheath induces neighboring cells of the dental papilla to differentiate into odontoblasts, which lay down dentin of the root. Afterwards the root sheath degrades and leaves behind remnants, called cell rests of Malassez. Subsequently after degradation of the root sheath, the cells of the dental follicle will contact the newly formed root dentin, which causes them to develop into cementoblasts and lay down cementum on the outer side of the root (9).

4. PATHOLOGY OF THE PULP AND ITS REACTION TO OUTSIDE STIMULI

The aim of this chapter is to understand the outside stimuli (e.g. caries, dental materials) and how the dentinopulpal complex reacts to these insults.

Since caries is the most prevalent cause of major insult to the tooth structure, it will be the major concern of this paragraph.

Teeth, in comparison to other tissues that are derived from the ectoderm (e.g. skin), are of a non-shedding nature and therefore are faced with different challenges regarding the fight against microorganisms that colonize their surface.

We know today that the oral cavity is inhabited by many different bacterial species, some beneficial and some detrimental to the health of the oral cavity and the body as a whole organism. There are a few bacterial species that are especially harmful to the tooth structure, since they drive the process of caries development, hence we call them cariogenic bacteria (25).

4.1. Demineralization by cariogenic bacteria

The group of cariogenic bacteria is mainly constituted by two distinct species: the lactobacilli and mutans streptococci. The detrimental effect of these bacteria is caused by their capacity to break down hard tooth structure, which is due to the organic acids these species produce as byproducts during metabolization of carbohydrates. Carbohydrates are readily available to these bacteria since they are found in abundance in our modern diet. Organic acids like lactic acid and acetic acid are capable of demineralizing dental hard tissues. The process of demineralization is brought about by the shifting equilibrium of the oral milieu to become more acidic in nature, caused by increased amounts of acidic metabolic byproducts of said cariogenic bacteria. This will in turn cause the loss of important minerals from enamel and dentin and thereby continuously weaken its structure, thereby making the dental structures more easily prone to further physical breakdown and degradation (26).

On one side of this equation symbolizing the challenge of caries, we have the cariogenic bacteria and sugar-rich diet contents. On the other side, trying to balance out these harmful stimuli is our saliva, which has proven important in counteracting the effects of said cariogenic bacteria. It contains antibacterial compounds and serves as a buffer system with the capacity to keep the pH of the saliva at a moderate level (pH 6.5 – 7). It must balance out the acidic contents that our diet and the fermentation of carbohydrates by cariogenic bacteria introduce into the oral cavity. If this balance is disturbed and the pH of the saliva tilts too far into the acidic direction, demineralization occurs.

To prevent demineralization, the saliva provides a solution saturated with minerals important for enamel and dentin structure, which are, if they pH is neutral, integrated into the tooth structure and hereby promote remineralization. Caries develops due to repeated cycles of demineralization, which occurs several times a day whenever the pH decreases too far. In the same manner does remineralization occur if the pH is adequate and minerals are available in the solution of the saliva to be incorporated into the dental structures (26).

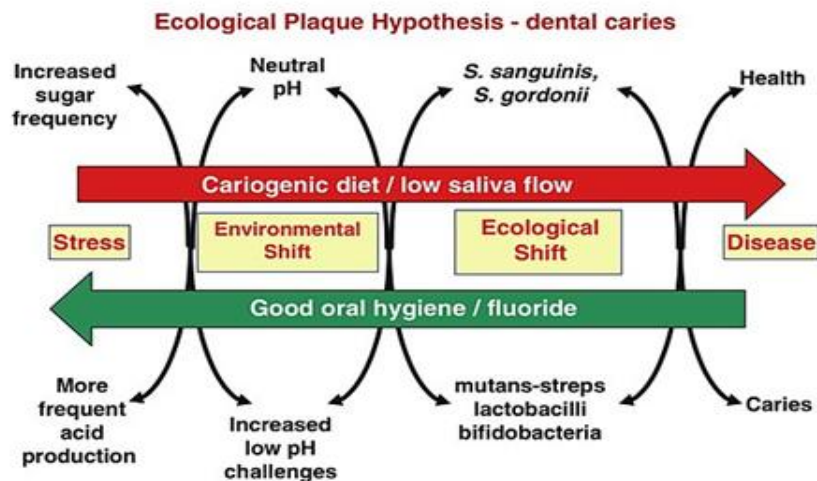


Figure 1 shows the effect of the acid-base balance in the oral cavity on the dental hard tissues, which result in demineralization (27) [source: Wikicommons; CC0 - public domain image]

Moreover, the accumulation of microorganisms on the tooth surface leads to the formation of plaque, which makes it harder for the saliva to bathe the tooth surface in its buffering and mineral providing solution. Another problem is that the presence of plaque on the teeth protects the microorganisms inside the plaque and prevents the saliva from properly cleaning and washing away leftover dietary contents and microorganisms, so that the acids produced by the cariogenic bacteria stay in contact with the tooth's surface longer and hereby lead to increased damage (28).

4.2. Destruction of dental tissue by caries

Macroscopically the progressing caries lesion is seen as an advancing process that can be divided into several stages. According to the International Caries Detection and Assessment System (ICDAS) a caries lesion encountered upon clinical examination can assume several distinct stages. These range from a small white or brownish spot to an extensive deep caries lesion, involving large parts of dentin and possibly the dental pulp (29).

Breakdown of dental hard tissue is clinically detectable, and the experienced clinician might be able to estimate the damage caused by the caries insult via analysis of dental radiographs, but clinicians can seldom accurately judge the pulpal status. Today no technical device or clinical test is available to accurately predict the degree of pulp inflammation. Diagnoses determining reversible or irreversible pulpal damaged can therefore rarely be more than a prediction (30).

Albeit the difficulty of judging dental pulps as reversibly or irreversibly damaged from a clinical perspective, the microscopical point of no return for a dental pulp is quite clearly visible. To understand the changes that take place in the dentin and pulp, we must therefore enter the realm of histology and pay close attention to the changes that are visible on this level (6).

4.2.1. The enamel caries lesion

Microscopically several different zones are detectable in the caries-enamel lesion that penetrates deeper than the superficial white spot, which correspond to the depth of invasion. The surface zone seems to be the least affected by the invasion of the caries lesion. This can be explained by the elevated levels of fluoride found in the plaque, which precipitate and strengthen the dissolved enamel on the surface. The remineralization of enamel in the surface zone decreases the destruction that is microscopically detectable. Fewer minerals can reach the zones below the surface, which therefore display greater tissue destruction (28).

4.2.2. The dentin caries lesion

If the caries lesion is allowed to spread deeper into the underlying tissue, it will eventually reach the dentin. Once the caries lesion reaches the dentin, it spreads down the Dentinoenamel-junction. If the lesion continues to burrow deeper into the dentin, the overlaying enamel will lose its foundation and become undermined. If the masticatory forces ever become too high for the weakened tooth structure, it will eventually break away and open the underlying carious area to the surrounding oral environment. Such an open lesion will usually present a temporary decrease in caries activity. Possibly due to the remineralization properties of the saliva that can now reach the exposed dentin cavity (6,31). The breaking away of the enamel surface layer does not always happen but is a usual step in the further progression of the caries lesion. It is dependent on the extent of caries destruction of the dental structures caused by caries invasion.

However, in dentin the presentation of advancing caries is different. Since the composition of dentin is different from enamel it is logical that the destruction of this structure appears histologically different than enamel. Caries destruction progresses more rapidly in dentin due

to its less mineralized structure. Microscopically we can differentiate five zones in dentin caries lesions: From the Dentinoenamel-junction towards the pulp these are: zone of decomposed dentin, zone of bacterial invasion, zone of decalcification of dentin, zone of dentinal sclerosis and zone of fatty degeneration (28).

The surface zones of decomposed dentin and bacterial invasion represent irreversibly damaged tooth tissue and cannot be remineralized. In the zone of decomposed dentin, we can observe serious destruction of the dentin that leads to a complete loss of its structure and substantial amounts of bacteria. Beneath this zone, denatured collagen and vast demineralization of the dentin are present. Furthermore, distention of the dentinal tubules is visible, which are densely populated with microorganisms and liquefaction foci. In the zone of decalcified dentin, demineralization and decalcification occur along the walls of the dentinal tubules through which the bacteria advance. The zone of dentinal sclerosis shows the protective response of the odontoblasts that try to establish protection from the advancing bacteria and acids. This protective response manifests as calcification of dentinal tubules to shield off bacterial entry into them. In the deepest zone, below the dentinal sclerosis, no bacteria are present. The dentin here is normal in appearance but the odontoblastic processes between the dentin degenerate and leave behind tissues of fatty degeneration (28).

The first visible sign of the advancing caries process that reaches the dentin beneath the enamel, is an area of demineralization which can be observed under the microscope. This demineralization is caused by the bacterial acids that diffuse ahead of the acidogenic bacteria. Then bacteria invade along the dentinal tubules, which represent the easiest entrance into the dentinal tissue for these microorganisms. After initial invasion of the tubules, demineralization increases, the tubules distend, and the dentin matrix becomes increasingly degraded ultra-structurally. The escalating tissue destruction allows the bacteria to escape the dentinal tubules and spread laterally through the intertubular dentin (9,32).

4.3. Reaction of the dentinopulpal complex to harmful stimuli

Since caries is often but not always a slowly advancing process that happens in a cyclic nature of demineralization and remineralization, odontoblasts that are located inside the dentinal tubules might have enough time to take reactive measures accordingly. If the insult to the dentin is of a slowly progressive character, the odontoblasts will start to close the dentinal tubules towards the advancing caries front and retract further into the tubule to create a physical barrier. The aftermath of such a retracted or degenerated odontoblastic process in a sealed-off tubule

can be seen in the form of so-called dead tracts that are essentially empty dentinal tubules devoid of the odontoblastic processes they once harbored (33).

Thereby they shield themselves and other vital tissues inside the pulp from further harm of the invasion of microorganisms and their acidic metabolic byproducts. The dentinal tubule will gradually become more obstructed until it is completely sealed. This process is thought to be partially caused by the odontoblasts that deposit collagen and partially by the expansion of the peritubular dentin, which lines the dentinal tubules, towards the tubule center. The expansion of the peritubular dentin is thought to result from reintegration of mineral salts that become available due to the advancing caries process. This process is called dentin sclerosis (9,34).

Tertiary dentin is, compared to the formation of secondary or primary dentin, not a developmental process but rather a defense mechanism of the dentinopulpal complex to protect itself from outside harm (e.g. caries, mechanical insults or chemical stimuli from composite monomers). Tertiary dentin is only produced directly underneath the area of harmful stimuli. When referring to tertiary dentin, one must differentiate reactionary and reparative dentin (35).

Reactionary dentin is formed by injured odontoblasts that survived the damaging stimulus and now try to seal themselves off from harm. Reactionary dentin is similar to secondary dentin in that it is secreted by the same odontoblasts that formed the secondary dentin and is tubular in structure but has a lower hardness and a decreased elastic modulus (36).

Reparative dentin is different in many ways from the reactionary dentin and therefore from the secondary dentin. The most significant difference might be that it is not secreted by odontoblasts but instead by so-called odontoblast-like cells that are stem or progenitor cells originating from the dental pulp. These cells proliferated and differentiated to take the place of the odontoblasts that died during the injurious insult. This differentiation only takes place if the caries lesion is arrested or controlled (by the pulp defense itself or by means of surgical intervention of the dentist). Furthermore, the reparative dentin is different in structure to reactive dentin. It is rich in noncollagenous content but poor in collagen compared to secondary dentin (37,35). During this process odontoblasts can become entrapped in the secreted tertiary dentin matrix and resemble lacunae in bone; hence this type of dentin is termed osteodentin (35,38).

If the carious destruction advances too fast for the odontoblasts to wall themselves off by producing further layers of dentin or closure of the tubules, a different reaction ensues. Once odontoblasts encounter bacteria invading their space by detection of certain bacteria cell wall components (e.g. lipoteichoic acid of gram-positive bacteria), they will respond with activation

of their defense mechanisms. If the bacteria are detected by the odontoblasts, the odontoblasts in turn start production and release of cytokines and chemokines. Subsequently, these molecules will initiate the immune response and attract immune cells into the area and thereby increase the level of inflammation. Afterwards the immune response is then further mediated by dendritic cells that migrated to the area of inflammation. The degree of inflammation corresponds directly to the depth of bacterial invasion and level of tissue destruction (37).

If the insult to the tooth happens abruptly or at least too fast for the odontoblasts to react accordingly in time, the odontoblasts will potentially die, and the harmful stimulus will progress further into the tissue and thereby cause damage to the pulp. This will elicit a massive increase in the inflammatory response of the pulp which will either be able to fight off the harmful stimulus by shielding itself off via formation of a dentin bridge of reparative dentin or will undergo necrosis. This necrosis can be partial, meaning only the coronal part of the pulp or only one pulp canal could be affected while the remaining tissue is able to survive.

In the scenario that the pulp manages to produce a dentin-bridge and seal itself off from the insulting agent it is still not completely clear which cells proliferate to produce the reparative dentine bridge, but the odontoblast-like cell, which differentiated from dental pulp stem cells, are suspected to react in this manner (9,34).

The tooth and with it its pulp are not just exposed to the insults of carious bacteria but also to several different potentially harmful stimuli. Heat is one of these stimuli that can elicit deterioration responses of the dental pulp, once the heat exposure is too high for the pulp to bear. Such scenarios of heat exposure to the pulp or close to the pulp resemble tooth preparation performed without adequate water cooling or direct and intense exposure of the pulp to heat generated from dental light curing units.

Other stimuli that are potentially harmful to the pulp can be caused by exposure to different dental materials like amalgam, dental cements or resin composites. These insults are especially dangerous to the pulp if they are placed in direct contact, which is the case in deep cavities or pulp exposure. The reaction of the pulp to such stimuli depends on the toxicity of the material itself, the thickness of residual dentin shielding the pulp from direct exposure to the stimulus and regenerative capabilities of the pulp. Reactions of the pulpal tissue to these insults can range from temporary inflammatory responses to chronic inflammation and eventually ensuing necrosis of the pulp (6,39).

4.4. Progression from reversible pulpitis to periapical disease

Pulpitis or inflammation of the pulp can be caused by several different stimuli, e.g. by incipient caries and thermal or mechanical irritation from recent dental treatment.

Reversible pulpitis is described as a condition that displays pulpal inflammation with the associated changes in increased blood flow and infiltration of inflammatory cells. This inflamed pulp however can quickly return to its normal physiological state after the harmful stimulus is removed, therefore it is termed reversible. Clinically the pulp presents with a heightened sensitivity, which can be elicited by thermal stimulation.

Irreversible Pulpitis on the contrary describes the state of a pulp, which is irreversibly damaged and cannot reverse to a healthy state again, even after all harmful stimuli are removed. Histologically it presents with small abscess formations and necrotic areas in the affected region of the pulp, accompanied by many polymorphonuclear cells and signs of a chronic inflammatory response in the periphery. Irreversible pulpitis and its focal tissue necrosis can be confined to local parts of the pulp. Irreversible pulpitis can present with symptoms or completely asymptomatic and shows intense painful responses to thermal stimulation, which usually lingers even after stimulus removal.

Necrosis ensues if the pulpal inflammation progresses further towards the apical region – affected tissues die. Nutrient supply in the form of vasculature and innervation are lost and therefore the pulpal cells are inevitably doomed to undergo tissue death, which results in liquefaction necrosis and gross destruction with loss of cellular organization. The necrotic pulp becomes mostly nonresponsive to clinical tests.

Gangrene is a term referring to bacterial invasion as the source of pulp tissue death. The pulp's defense mechanisms are overpowered by harmful effects of the advancing bacteria. The tissue degradation facilitated by the bacteria results in a characteristically foul odor that can be detected upon instrumentation of the affected root canal system.

If the infection spreads to periapical tissues beyond the apical foramen of the tooth root, apical or periapical disease ensues. This presents as accumulation of pus beyond the apex and starts to erode the surrounding alveolar bone. Clinically periapical lesions show painful responses to percussion and palpation due to the compressive force that is exerted onto the contents of the lesion in a confined space. Periapical disease can either become chronic and continuously drain via a sinus tract or spread to surrounding soft tissue spaces (6,7).

5. REGENERATIVE THERAPIES IN ENDODONTICS

The practice of modern endodontic procedures, which today is regarded as an essential tool in the arsenal of almost every dentist on the globe, began its development in the early 20th century. The breakthrough in the fields of aseptic operation techniques as well as local anesthesia made it possible to operate in the root canal system without intensifying the present infection or spreading to distant sites in the organism. Since its beginning, the endodontic or root canal treatment, as it was named by Dr. Louis I. Grossman, often regarded as the father of modern endodontics (40), has ever since followed a systematic protocol of steps. This protocol is comprised of the initial step of trepanation, meaning accessing the pulp chamber and root canal system by mechanically opening the tooth. Followed by the cleaning and shaping as well as disinfection of the whole root canal system, which aims to remove all infected tissue, bacteria and organic debris. And finally, obturation is performed, which is filling and sealing the root canal system in a manner that prevents microleakage and the re-entry of bacteria. If the obturation posed successful, a filling is fabricated over the obturated root canal system to shield it from bacteria of the oral cavity and enhance its stability to withstand the forces of mastication (41).

Since the development of this technique, many new materials and instruments have become available to the endodontist to make his treatment more efficient and ensure a curative outcome. Besides these advancements also a development of more conservative treatment approaches has been formulated and found useful in clinical practice, namely pulpotomy. Today it is customary practice to not completely remove the contents of the root canal system but instead only clean the parts of the infected pulp that are irreversibly damaged. This technique must be judged carefully regarding its usefulness to the patient and can only be employed if the present level of infection and degradation in the pulp is in accordance with required indications.

Although the field of endodontics saw many impressive developments that made the procedure more predictable and easier to perform, it did not change much at its core until today. The basic principle of repair that is so quite common in dentistry is applied here as well. The only aim of the endodontic treatment approach is to alleviate the patient of his symptoms and provide a solution for his disease, but it does not heal the tooth and instead only repairs it. This approach, although exceptionally useful in dentistry, can in the long term only be seen as a compromise in the quest to complete healing of disease-afflicted teeth.

New techniques are emerging in dentistry, which focus on the use of stem cells and cell signaling, to cause complete healing of diseases. These new developments are promising and seem to be the next step in the quest to the complete regeneration of the lost tissue or restitutio ad integrum. This goal, which was regarded far outside of our reach years ago, seems not so utopic anymore with the advent of such novel technologies on the horizon of medicine and dentistry.

In the following section an overview of the emerging technologies in regenerative endodontics will be presented. It will also shed light on novel procedures that are available already today as well as possibilities in the future and the current focus of research in the field of regenerative endodontics.

The aim of pulpal regeneration can be summarized as the complete regeneration of its tissues and function, preferably in a manner that makes them identical or at least like the lost tissues. Therefore, a renewal of innervation, vasculature, and odontoblasts' capability to generate dentin as well as immunological functions of the dentinopulpal complex must be restored to be able to speak of complete regeneration.

Generally, the field of regenerative endodontics can be divided into two different approaches. The cellular approach, which deals mainly with the use of stem cells and their employment to regenerate the lost tissue, and the acellular approach, which is focused on the development of treatment procedures that use what is called cell homing. These are strategies that utilize signaling molecules and similar methods to activate and heighten the regenerative capability of the body itself (42).

5.1. Regenerative endodontic procedures/ revascularization

The first development towards pulpal regeneration was the advent of the revascularization technique. It did not live up to the promise of complete pulp regeneration but proves successful in stimulating the healing capacities of the human body to a higher degree than it was possible before in endodontics. Revascularization is a procedure officially recognized and performed today in clinical settings.

Revascularization, also called revitalization or regenerative endodontic procedure, is a novel approach that is used to treat immature permanent teeth. Such immature permanent teeth are often afflicted with endodontic disease as a consequence of trauma or caries. If the dentist

performs treatment on these teeth to resolve the underlying pulpal necrosis, further root growth is arrested and the tooth keeps a wide-open apex and usually thin dentin walls, which significantly increase its fracture risk. The standard treatment modality for these immature permanent teeth today is the so-called apexification.

Apexification is a treatment approach in which the clinician first removes the pulp tissues, disinfects the root canal system, and then positions calcium hydroxide or a similar material in a monthly repeated fashion at the apex of the open root canal to induce calcification and apical closure (43).

Revascularization poses a different and potentially better treatment solution to immature permanent teeth since it aims at regenerating the lost pulpal tissue. Even though this goal has not been completely achieved until now, revascularization is a technique that is practiced successfully in dentistry already today. The treatment of revascularization is already recognized as a valid alternative to apexification and guidelines for the procedure were published by the American Association of Endodontists and the European Society of Endodontology.

The procedure of revascularization is performed by removal of the necrotic pulp with minimal debridement of the root canal walls followed by canal disinfection. Then an intracanal medicament is placed and the patient is rescheduled for a further appointment in several weeks. On the second visit any prior swelling and signs of persistent endodontic infection must have subsided to enable the dentist to continue the treatment protocol of revascularization. Re-accessing and repeated irrigation as well as complete removal of the intracanal dressing which was placed on the initial visit are mandatory steps in preparation of revascularization.

After this preparation, the essential step is performed where the clinician will purposefully over-instrument the open tooth apex to cause damage in the periapical region and introduce bleeding in the area. The blood will then fill the root canal system and form a blood clot, which is capped with a collagen membrane and a bio-ceramic material. The goal of this intentional bleeding beyond the apical tooth region is to produce a scaffold for healing inside the root canal system and to attract growth factors and stem cells located in the periodontal ligament and apical area into the root canal, which will potentially promote regeneration of the pulp tissue.

Endodontic revascularization has produced remarkable results of completed root development and increased dentin wall thickness as well as in some cases return of sensitivity to pulp vitality tests. The degree of success in this treatment approach, however, largely depends on the age of the patient and therefore the tooth's regenerative capabilities. The outcome of such procedures,

although successful in alleviating patient's symptoms and producing a biological filling of the root canal system, did not completely regenerate the contents of the dentinopulpal complex that were lost. Instead, histological analysis revealed that the tissue inside the root canal system was in fact not pulp-like but bone, cementum, or tissues of the periodontal ligament. Therefore, the results of revascularization cannot be regarded as true regeneration but rather as resolution of apical lesions with inconsistent influence on the completion of root development. Furthermore, the repair of the root canal system by infilling with ectopic tissues is reported as a consequence of the blood clot. Regardless of the incomplete regeneration of pulp tissues, the results of revascularization are already a success compared with apexification, since apexification often involves series of repeated visits and will create an apical barrier of equal or inferior quality compared to the further root development induced by revascularization (44). Although the result of successful revascularization seems promising, the procedure of revascularization or endodontic regeneration has several drawbacks. Namely the inconsistency of successful root maturation, which cannot be predicted efficiently and might be influenced by failure of resolving the inflammation of the bacteria laden pulp cavity. Further increased rates of adverse effects and tooth discoloration compared to apexification contribute to the drawbacks of this novel treatment approach (45,46).

5.2. Acellular approach

The acellular approach does not use any kind of cells that are implanted or reintroduced from outside the patient's body into the root canal system but rather focusses on the stimulation of the body's own regenerative capabilities.

The acellular approach to pulpal regeneration employs the strategy of cell homing, which aims at the attraction of cells, particularly stem cells, from the apical region, to facilitate pulp regeneration. These stem cells from the apical papilla (SCAP) or periodontal ligament (PDLSC) are attracted by different means to migrate into the root canal system and differentiate into the cells needed to renew the dental pulp. The cell homing strategy utilizes active signaling molecules, which are incorporated themselves into the root canal system or continuously released from scaffolds into which they are implanted to attract the stem cells from the apical region into the pulp chamber.

The cell homing concept requires two different cellular processes of the human body to take place to fulfil its task of tissue regeneration. These are recruitment and differentiation of cells.

Recruitment is the attraction and migration of stem cells towards the region that needs to become regenerated. Differentiation refers to the stem cells maturing into the specialized cells needed to replace the lost tissue and its function.

Cell homing is possible due to the great regenerative capability of stem cells. Even though there are many distinct types of stem cells present in and around the root canal system, the main target of cell homing are the stem cells from the apical region and potentially surviving stem cells inside the root canal system. These stem cells are stimulated by utilization of either exogenous or endogenous biological signaling molecules (47).

5.2.1. Exogenous signaling molecules

In the case of exogenous signaling molecules, it is wise to acknowledge that many different small molecules are contributing to the signaling cascade that will cause pulpal regeneration. Since the dentinopulpal complex is a quite sophisticated construct of cells, extracellular matrix and interactions of both, the signaling needed to introduce regeneration of such complicated structure is quite challenging and requires extensive knowledge of the molecular interactions of tissues and chemotactic as well as differentiation factors.

Different molecules, especially growth factors, can introduce many different cellular processes, such as maturation, proliferation, and migration of cells. A wide range of different growth factors comes into play in this intricate process of tissue regeneration, but the most important ones are Bone morphogenetic protein (BMP), Platelet-derived growth factor (PDGF), Transforming growth factor β (TGF- β), Nerve growth factor (NGF) and Fibroblast growth factor (FGF). Bone morphogenetic protein influences the regeneration of bone matrix and its repair by stem cells. Platelet-derived growth factor induces wound healing and stem cell proliferation while Transforming growth factor β facilitates wound healing as well and regulates the inflammatory response of the tissue. Nerve growth factor is essential in proliferation of nerve cells and Fibroblast growth factor promotes proliferation of stem cells (48).

5.2.2. Scaffolds

Another component that is used to introduce cell signaling and tissue regeneration is the incorporation of scaffolds usually with implanted bioactive molecules into the pulp chamber. Scaffolds are employed to resemble the three-dimensional structure and functions of the extracellular matrix. The scaffold must fulfil several essential functions. Ideally it provides a supporting structure that colonizing cells can migrate into, securing cell survival by oxygen and

nutrient passage as well as allowing growth factors to reach their target cells and stimulate extracellular matrix formation. Further it must be biocompatible and non-immunogenic to prevent adverse reactions and damage to the migrating cells and forming tissues. If the scaffold serves as a temporary framework for the colonizing cells, it must be degradable. Its degradation rate must equal the rate at which the migrating cells will lay down their own extracellular matrix so that the replacement of the scaffold with a true extracellular matrix will take place without interruption of the supporting network for the cells. Stiffness of the scaffold is another important aspect since it will change important characteristics like cell adhesion and the morphology of the colonizing cells (49,50).

Scaffold materials can either be natural or synthetic. Natural polymers like alginate or cellulose possess an intrinsic biodegradability and chemical tailoring with functional groups present in the polymer is possible but are associated with drawbacks like undesired pathogen transmission or evoked immune responses. Hydrogels like fibrin or collagen have high biocompatibility, can be manufactured in an injectable or gel-like consistency and allow for modification with growth factors but lack mechanical strength. Synthetic polymers like polylactic acid are suitable due to their ability to tailor their physical properties and degradation rate but expose the colonizing cells to an environment that is different in structure than the extracellular matrix of the dental pulp (51).

A wide array of varied materials is available to support pulp regeneration with the aid of scaffolds, but the material must be chosen specifically to the needs of the cells and tissue that need to be regenerated. Unfortunately, no single material available at the present moment possesses all the required characteristics that are necessary to seamlessly facilitate cell colonization and differentiation into pulp tissues. To further increase the usefulness of scaffolds, it is possible today to implement biological signaling molecules like growth factors into them. Scaffolds can be modified in this way to possess a wide range of properties to optimally support the colonization of cells. These properties include cell-matrix interactions like adhesion of cells to the matrix or cell proliferation (52).

Although breakthroughs using exogenous growth factors and scaffolds for pulp tissue regeneration have been documented, the development of this technology today is far from being easily available and applicable to the clinical environment. The cascade of growth factors that is needed to influence stem cells in the exact manner to renew the lost pulpal tissues needs more research and better manufacturing protocols to make it available to everyday clinical settings.

5.2.3. Endogenous signaling molecules

Conversely, it was recently demonstrated to be possible to induce regenerative changes in the pulpal tissue without the introduction of exogenous growth factors (53). Endogenous molecules can be harnessed to influence the stem cells in an equivalent way to exogenous sources. The dentin resembles an ample reserve of endogenous growth factors that become trapped in its matrix during dentinogenesis. These endogenous biological signaling molecules become freed once the dentin is broken down by intracanal substances, e.g. ethylenediaminetetraacetic acid (EDTA) or disinfection agents, used in the process of preparing the root canal system for further interventions. The endogenous factors cause chemotaxis, meaning the attraction and migration of cells via chemical stimuli, and aid the regenerative response of the attracted stem cells (54).

Revascularization can be interpreted as a simplistic example of cell homing. Here the artificially created blood clot will induce the migration of stem cells from the apical region into the root canal system. There endogenous growth factors released from the blood clot will further facilitate chemotaxis and differentiation of the stem cells into the tissues that can later be found in the pulp chamber, namely bone, cementum, and periodontal ligament structures (55,56).

Different protocols suggest the use of growth factors like platelet- rich plasma (PRP) or platelet-rich fibrin (PRF) in the revascularization process to further increase its clinical success rate and resemble further advances in the field of acellular cell homing approaches (57).

5.3. Cellular approach

The second approach focuses on the employment of cells, specifically stem cells, to bring about the goal of dentinopulpal regeneration.

“Stem cell” is a generic term for several different cell types with differing origin and regenerative capabilities. One characteristic which all cells in the stem cell category possess is the ability to differentiate into mature cells to repair damaged tissue although the potential for differentiation is not the same in different types of stem cells.

In the following section an overview of different kinds of stem cells that are potentially capable of contributing to the regeneration of pulpal tissue is presented.

Embryonic stem cells originate from the eight to nine days old blastocyst of embryos. These cells are totipotent, meaning theoretically able to differentiate into every single tissue of the

human body. Although it is possible to cultivate such cells *in vitro*, ethical concerns arise regarding the use of embryonic tissues. Furthermore, there is no source of embryonic stem cells available in the adolescent or adult organism, which complicates their use for clinical interventions.

Compared to the embryonic stem cells, adult stem cells are not totipotent and their capability for tissue renewal or stemness becomes limited to more specific tissue ranges. Although they have lost the ability to form a complete organism by continuous proliferation, these cells are still able to differentiate into a vast array of differing phenotypes.

Adult stem cells can be described as undifferentiated cells which undergo self-renewal and have the function of tissue regeneration. They can be found in all kinds of somatic tissue types. These adult stem cells can be distinguished by their differentiation potential, which can reach from the ability to mature into several different specific cell types to the ability to only differentiate into a single cell phenotype. Apart from their differentiation potential they can be set apart due to their origin. Stem cells can originate from many different types of tissues, e.g. from fat tissue or bone marrow, called adipose-derived stem cells and bone marrow-derived mesenchymal stem cells respectively (58).

Another type of stem cells, which are potentially able to aid in dental stem cell therapy are so-called induced pluripotent stem cells. These cells are differentiated somatic cells that were induced to resemble the differentiation potential of embryonic stem cells. The manufacturing process of induced pluripotent stem cells requires manipulation of somatic cells like fibroblasts with transcription factors, which are responsible for the maintenance of the undifferentiated status of embryonic stem cells. After this induction via viral transfection the induced cells resemble embryonic stem cells. Although they hold great potential, these induced pluripotent stem cells did show malignant transformation under certain circumstances (59).

Many different adult stem cells can be found in and around the region of the dental root canal system. They display the properties of general adult stem cells and fulfil the function of tissue repair for the respective tissue niche. The most often used stem cells of the dental space are listed below:

The dental pulp stem cells (DPSC) originate from the neural crest cells and are found in the cell rich zone in the intact dentinopulpal complex. They are thought to facilitate repair of injured dentin by proliferation into odontoblast-like cells, which produce reparative dentin to shield the

pulp from the harmful stimuli. DPSCs can differentiate into adipocytes, odontoblasts or odontoblast-like cells, osteoblasts, and neuron-like cells (60).

Stem cells from human exfoliated deciduous teeth (SHED) originate from the remnants of exfoliated deciduous tooth pulps. SHEDs have high proliferation rates and possess osteoinductive qualities. They differentiate into chondrocytes, adipocytes, myocytes, osteoblasts and neuron-like cells (61).

Periodontal ligament stem cells (PDLSC) are isolated from the periodontal ligament and can differentiate into the cells that form the supporting apparatus or periodontium of the tooth. These are chondrocytes, osteoblasts, cementoblasts and adipocyte neuron-like cells (62).

Stem cells from the apical papilla (SCAP) are cells associated with the developing dental roots. SCAPs can differentiate into odontoblasts, adipocytes and neuron-like cells among others. These cells are thought to contribute to the successful root development initiated by the revascularization treatment in immature permanent teeth (63).

Dental follicle stem or precursor cells (DFPC) surround the tooth germ during development and are responsible for the formation of tissues of alveolar bone, cementum, and the periodontal ligament. These cells can differentiate into adipocytes, osteoblasts, cementoblasts, chondrocytes and dentin-like cells among others (64).

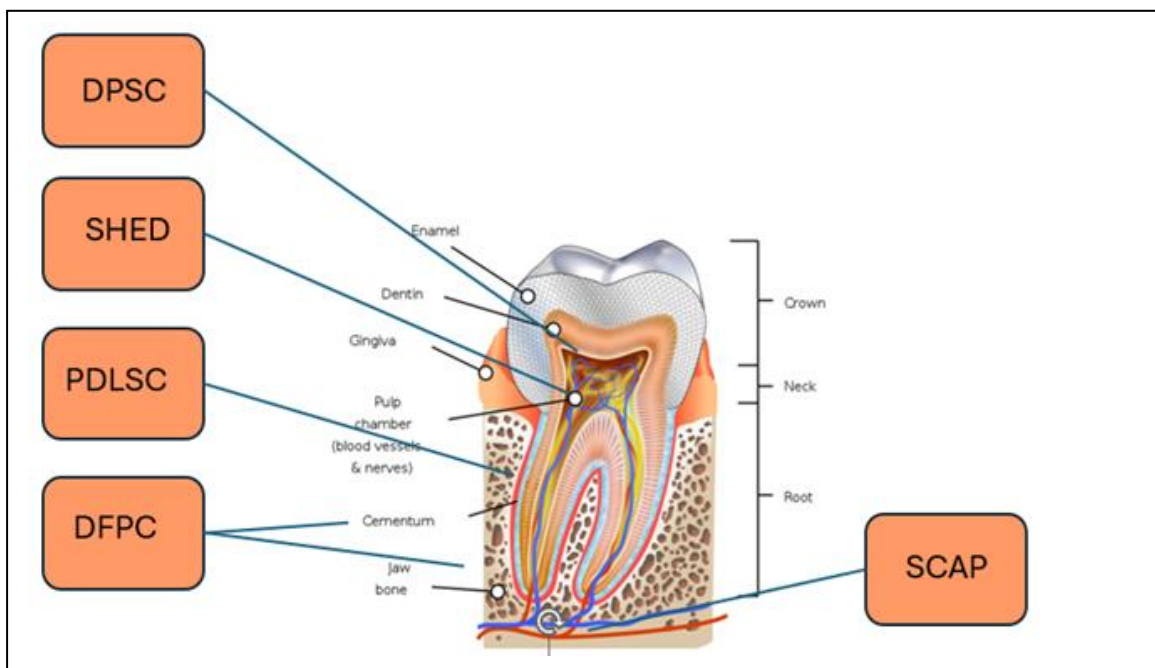


Figure 2 shows various dental stem cells and their site of origin, adapted from (65)
[source: Wikicommons; CC0 - public domain image]

5.3.1. The stem cell niche

An important concept in today's understanding of stem cells and their capabilities is the so-called stem cell niche. The stem cell niche theory can provide answers to the question how the stem cells are influenced to engage into this damage repair and mature into adult cells of specific nature. The theory of the stem cell niche was introduced by Schofield in 1978 (66). According to this concept, stem cells reside in a complex microenvironment that influences stem cells and aids their function of tissue regeneration. The stem cell niche is composed of all the factors that surround the stem cells. These factors include other cells in proximity to the stem cells, the extracellular matrix, growth factors and cytokines, which exert their effects on the stem cells.

Various cells in the proximity of dental pulp stem cells are fibroblasts, different immune cells and endothelial cells. Fibroblasts play an important role in the structural integrity of the extracellular matrix and the pulp as a whole. They secrete growth factors that maintain the pulp structure and influence differentiation and recruitment of dental pulp stem cells. Endothelial cells line the blood vessels present inside the dental pulp. They secrete growth factors concerned with angiogenesis and aid in nutrient and oxygen supply for the stem cells. Various immune cells are tasked with immune surveillance and modulation of the immune response of the pulp. They collaborate with the dental stem cells to reach the goal of tissue regeneration (67).

The extracellular matrix contributes a support structure for the stem cells and other cells in the stem cell niche. The physical properties of the extracellular matrix, namely stiffness and viscoelasticity, are important modifying factors in the differentiation and migration of stem cells. Furthermore, does the extracellular matrix communicate with stem cells via cell surface receptors and mediate growth factor effects in its vicinity (68).

Soluble molecules found in the stem cell niche, mainly growth factors, have major influence on the dental stem cells' capability to proliferate, differentiate and fulfil their role of regeneration in the face of tissue injury. Growth factors and similar biological signaling molecules resemble the major way of cell communication and induce changes to bring about homeostasis and tissue repair (69).

The stem cell niche is the location that stem cells reside in. In this specific niche the number of stem cells present is regulated tightly. The stem cells are instructed by their physiological environment to maintenance of surrounding tissues and self-renewal. Further, these surrounding factors influence the differentiation and proliferation potential of stem cells to contribute to regeneration and replacement of lost cells and tissues.

The discovery of dental pulp stem cells in 2000 led to the quest of regeneration in the endodontic space. After first dental pulp stem cell implantation trials in animal models, it became clear that these stem cells possess regenerative potential. Although guidance of the multipotent stem cells' proliferation and differentiation into the correct direction is complex and needs further research. To artificially influence and direct the stem cells towards regeneration of the desired tissues, it was necessary to understand the factors that exert influence on the stem cells and their environment or stem cell niche (70).

The understanding of the stem cell niche explains the interplay of the different factors in the anatomical space surrounding the stem cells. Therefore, scientific research today aims at artificially creating this environment for the stem cells to guide the cells' proliferation and maturation towards the desired regeneration of tissues. To create this surrounding artificial space, several different factors are necessary as discussed above.

Today the research in the field of endodontic regenerative therapies focusses on the components that are necessary to regenerate the dentinopulpal complex inside the empty root canal system of endodontically treated teeth. Scaffolds made of biomaterials are employed to mimic the surrounding extracellular matrix of the stem cells. A vast range of different synthetic and natural materials is available to provide the required characteristics of this support structure. Furthermore, growth factors are employed to influence the migration, proliferation and differentiation of stem cells into the tissues that comprise the dental pulp. Stem cells are either cultured in vitro, or strategies of cell homing are employed to attract stem cells to the desired location. This method of artificially regenerating biological tissues with the utilization of stem cells, scaffolds and growth factors is termed tissue engineering (71).

5.4. Ectopic and orthotopic models for pulp regeneration

Researchers have employed several different animal models in the quest for tooth regeneration. These models are listed and shortly explained below:

Ectopic models for pulp regeneration are models in which isolated dental stem cells coupled with osteoinductive granules were implanted into the subcutaneous, and therefore ectopic, space of immunocompromised rodents. This model showed first signs of differentiation into pulp or pulp-like tissues, e.g. odontoblast-like cells (72).

In semi-orthotopic models, researchers implanted human tooth slices containing dental stem cells and / or growth factors into immunocompromised animals. Regeneration of pulpal tissues occurred inside the tooth slices (73).

Orthotopic regenerative models involve larger animals like ferrets and dog. These trials utilize the implantation of stem cells or engineered tissues, with various combinations of scaffolds, cells and growth factors, into the original, orthotopic, space, such as dog tooth's pulp chambers. These orthotopic models have more similarity to humans and better resemble the clinical conditions for stem cell therapy and tissue engineering. Therefore, they allow better evaluation of regenerative potentials and risks regarding stem cell use in vivo (74).

Research regarding the basic knowledge of stem cells and tissue engineering in dentistry has been undertaken and progressed rapidly in the past years. Although scientific researchers were able to answer many questions until today, the intricate process of dental stem cell differentiation is still not completely understood until today. Albeit this enormous progress, many studies in the field of regenerative endodontics have been halted in the preclinical stage and focused mainly on animal models. Few trials are progressing to the clinical stage due to rigorous safety and ethical concerns about the use of dental stem cells in patients (75).

First clinical trials in humans were reported successful in further advances to regenerate the injured dental pulp. In 2018 Xuan and colleagues implanted autologous SHEDs into teeth which suffered from pulp necrosis as a consequence of dental trauma, and successfully regenerated the pulpal tissue, which contained sensory nerves. (76).

Although further investigations shed more light on the complex differentiation of dental stem cells and their implementation in tissue engineering, the goal of true regeneration of the dentinopulpal complex with all its tissues and functions is still not reached today. The advancement of clinical trials is complicated by the limited number of available teeth or similar tissues that could be employed to harvest and cultivate stem cells autologous to the patients in such trials. Further, safety concerns and high costs of manufacturing as well as quality control complicate the translation of dental stem cell research from the preclinical stage towards large-scale clinical trials (77).

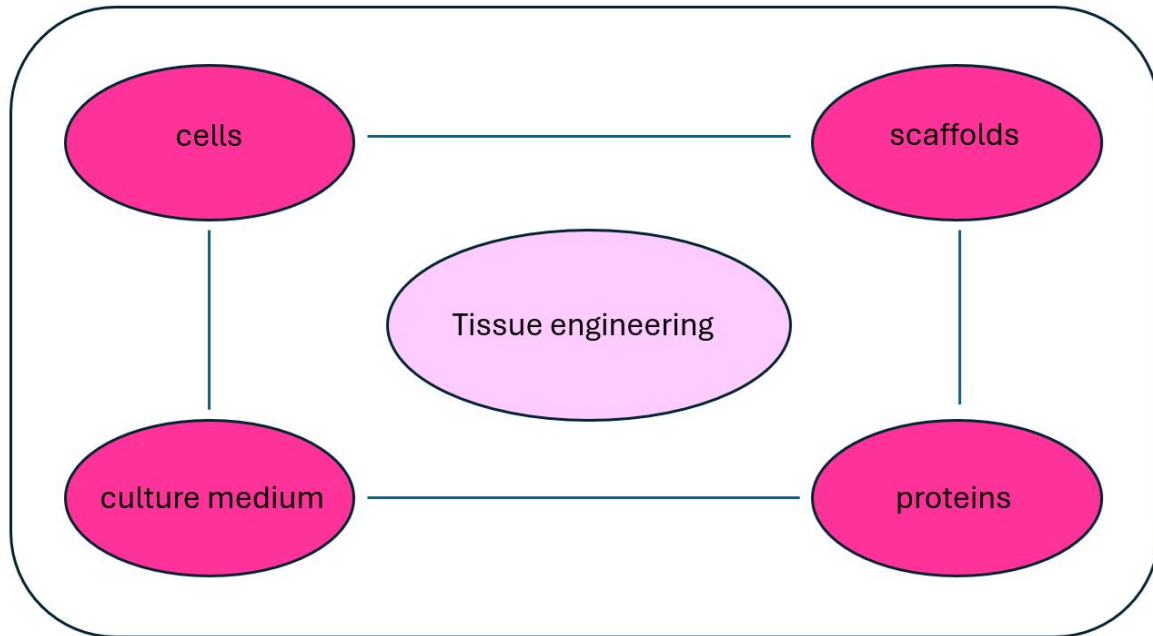


Figure 3 shows the relevant factors that are necessary for successful tissue engineering, adapted from (78)

5.5. Gene therapy

The advances and approaches in gene therapy are shortly mentioned here but not discussed in detail since today's scientific research focuses largely on the techniques stated above to promote endodontic regeneration. Furthermore, gene therapy in dentistry faces various safety and ethical issues and therefore progresses slowly.

The application of gene therapy in the field of regenerative endodontics aims at modifying specific genes of the patient to bring about regeneration and repair of endodontic tissues. Specific genes are identified and can be replaced or repaired in the case of gene damage to facilitate regeneration. Different techniques, such as gene insertion, gene regulation or gene editing, are applied.

Gene insertion aims at the implementation of a gene into a specific or nonspecific site in the genome of the patient. Hereby another gene is substituted by the inserted gene to repair the function of altered or damaged genes. This process can imply the use of viral vectors to transfer the gene into the target cell. Gene regulation is concerned with the process of switching certain identified genes on or off to fulfil specific functions and thereby facilitate tissue regeneration. Gene editing focusses on accurately altering DNA sequences and modifying gene function in

the process. The latest breakthrough in the field of gene editing employs the CRISPR-Cas9 system (clustered regular interspaced short palindromic repeats), which is able to correct genetic errors and turn specific genes on or off with reasonable ease (71,79).

5.6. Risks and safety concerns associated with stem cell therapy and tissue engineering

Recent breakthroughs regarding research in the field of endodontic regeneration and stem cell use in dentistry carry hope for the artificial regeneration of pulpal tissues in endodontically compromised teeth in the not so far future. Albeit these advantageous findings, there are several drawbacks to the use of tissue engineering and stem cell use.

Patient groups that most often require endodontic treatment and would therefore benefit most from the regeneration of endodontic tissues are elderly. Unfortunately, the activity of dental stem cells in elderly patients is decreased compared to stem cells of young or adolescent individuals. Therefore, the use of autogenic stem cells for dental procedures in the geriatric population seems to be diminished in effectiveness. Allogenic stem cell transplants, meaning stem cells from non-self donors, could provide a solution to this problem in the future, although they pose the risk of potential immune responses of the host tissue against the transplanted cells (80).

Adverse effects are known risks that occurred in other medical fields, which employ stem cell therapy approaches and which reaches from mild reactions like fever and localized pain to major adverse reactions such as thromboembolism and fibrosis. Adverse immune responses after stem cell therapy are a potential risk, which must be accessed before dental stem cell therapy can be used clinically.

Furthermore, stem cell transplantation carries the risk of tumorigenicity. In-vitro culturing, especially long-term culturing, poses the risk of malignant cell transformation and an increase in chromosomal abnormalities.

Biological materials and stem cells used in tissue engineering carry the risk of potential pathogen transmission to the transplant patient. Therefore, good manufacturing practice is necessary to ensure no transmission of microorganisms by contaminated cells or materials in tissue engineering (80,81).

The subspeciality of endodontics in the realm of dental medicine has come a long way since its initial emergence. Today millions of patients are successfully treated by endodontic procedures, which alleviate them of pain and potentially more hazardous consequences associated with endodontically diseased teeth. It is safe to say that dentistry took a big leap forward in its development with the clinical application of endodontics. The field of endodontics positioned itself as an important branch of dentistry that is constantly subject to new inventions in regard to materials and techniques to ease the treatment process for clinicians and patients alike. Although endodontic treatment today proves essential for many patients, a look at other branches of medicine shows that the approach in the health care system slowly shifts from mere repair of injuries and pathological processes to true regeneration. Stem cell therapy and similar regenerative procedures prove effective in resolving underlying causes of disease instead of symptomatic treatments.

Research and development of regenerative procedures can certainly be found in endodontics as well. New clinical procedures slowly emerge on the horizon of endodontology. The field of research and clinical practice of endodontic regeneration slowly but surely garnered increasing attention in the last decades. With its declared ultimate goal of true regeneration regarding lost pulpal tissues and their function it poses an alternative or possibly upgrade to past and present endodontic procedures.

First treatment options geared towards endodontic regeneration are already approved by American and European dental associations and gain increasing fame in the clinical sphere. Revascularization, as described earlier, is a clinical treatment modality available today to dentists and represents a regenerative approach to immature permanent teeth which require endodontic treatment. Where past approaches employed repeated deposition of intracanal materials for the formation of an artificial apical barrier, it is possible today to stimulate continued root growth and apex closure by the natural regenerative capabilities of the body itself in the form of revascularization. Although this treatment approach provides a good alternative for past methods in theory, its indication is narrow, and its success is not entirely predictable. Furthermore, even if successful, it does not facilitate true regeneration, namely renewal of lost pulpal structures, but instead replacement with tissues, which are related but functionally and histologically different (44,45,46).

Different approaches towards endodontic regeneration have become increasingly famous in the dental scientific community today. Among them are the techniques of cell homing, stem cell

therapy and tissue engineering as well as gene therapy. Cell homing facilitates cell migration and differentiation of autologous cells towards the injury site to promote regeneration. Revascularization can be regarded as a simple form of cell homing. Different protocols employ biological scaffolds and signaling molecules to further increase the effectiveness of such strategies. Stem cell therapy on the contrary utilizes the culturing and transplantation of donor or autologous cells and belongs to the domain of tissue engineering, which couples stem cells with scaffolds and signaling molecules similar to cell homing, to facilitate tissue renewal. Lastly, gene therapy resembles another approach aimed at tissue regeneration. Gene therapy utilizes different techniques to edit and modify the existing genome of patients to unlock healing capacities and tissue renewal (71,77,79).

Research advances regarding preclinical trials and in vivo-animal models proved successful in regenerating lost pulpal tissues and yielded much useful information for further investigation. Nevertheless, researchers still face several challenges, and further investigation is needed to solve the puzzle of endodontic regeneration as a whole. Clinical trials with patients slowly start to emerge and first progresses were reported. Despite the long way the field of endodontic regeneration has come, there is much to improve today, and further research needs to shed light on the challenges ahead. A deeper understanding of the molecular and genetic processes, which underly endodontic regeneration is necessary to achieve the coordinated safe and successful renewal of lost pulpal tissues.

None of these novel approaches, with the small exception of revascularization, has found broad clinic application nor have they been approved by dental associations in America or Europe. Albeit the possibilities that novel treatment approaches promise, there is much controversy regarding stem cell use and gene therapy. Neither of these new treatment strategies can be considered completely safe and without potentially severe side effects. Risks associated with novel approaches include adverse immune responses, pathogen transmission and cell alteration that can lead to malignant cell transformation. Arising safety and ethical concerns regarding such therapies reveal the need for further research. The transition from animal to clinical trials is slow and faces many challenges regarding ethical and safety regulation. Before these treatment approaches can be available for the broad population, further investigation is required to minimize associated potential side effects. Patients need to be able to reap the full benefit of novel treatment modalities without being exposed to potentially life-threatening adverse effects (80,81).

It has become clear that regenerative endodontic therapies hold much promise for the future. Endodontic procedures and possibly dentistry in general might be altered and completely changed by the developments of further research in stem cell and gene therapy. Endodontics today already utilizes the impressive benefits of available regenerative procedures. One day in the not so far future it might be possible to renew diseased tissues and stimulate tooth growth in edentulous patients or implant artificially grown teeth into the jaws of patients.

Nevertheless, this optimistic vision for the future, the status quo of regenerative approaches in the field of endodontics suffers from major drawbacks in the areas of patient safety. Side effects and outcomes of novel treatment approaches focusing on endodontic regeneration seem inconsistent and associated risks are unpredictable for the individual patient. Therefore, the processes of tissue engineering and gene therapy cannot be regarded as fully understood. Hence it becomes clear that further research must not only focus on the development of safe and efficient treatments but a deeper understanding of molecular and genetic processes in general is necessary before the promise of regenerative endodontics and possibly regenerative dentistry can be fulfilled and become available for broad parts of the population. At the current moment the promise of endodontic regeneration remains a promising vision for the potentially near future.

1. Tang W, Wu Y, Smales RJ. Identifying and reducing risks for potential fractures in endodontically treated teeth. *J Endod.* 2010 Apr;36(4):609-17. doi: 10.1016/j.joen.2009.12.002. PMID: 20307732.
2. Trope M. Regenerative potential of dental pulp. *J Endod.* 2008 Jul;34(7 Suppl):S13-7. doi: 10.1016/j.joen.2008.04.001. PMID: 18565365.
3. Hargreaves KM, Giesler T, Henry M, Wang Y. Regeneration potential of the young permanent tooth: what does the future hold? *J Endod.* 2008 Jul;34(7 Suppl):S51-6. doi: 10.1016/j.joen.2008.02.032. PMID: 18565373.
4. Biehl JK, Russell B. Introduction to stem cell therapy. *J Cardiovasc Nurs.* 2009 Mar-Apr;24(2):98-103; quiz 104-5. doi: 10.1097/JCN.0b013e318197a6a5. PMID: 19242274; PMCID: PMC4104807.
5. Mousaei Ghasroldasht M, Seok J, Park HS, Liakath Ali FB, Al-Hendy A. Stem Cell Therapy: From Idea to Clinical Practice. *Int J Mol Sci.* 2022 Mar 5;23(5):2850. doi: 10.3390/ijms23052850. PMID: 35269990; PMCID: PMC8911494.
6. Goldberg M, editor. *The Dental Pulp: Biology, Pathology and regenerative Therapies.* Berlin: Springer; 2014.
7. Berman LH, Hargreaves KM. *Cohen's pathways of the pulp.* 12th edition. New York: Elsevier; 2020.
8. Goldberg M, Kulkarni AB, Young M, Boskey A. Dentin: structure, composition and mineralization. *Front Biosci (Elite Ed).* 2011 Jan 1;3(2):711-35. doi: 10.2741/e281. PMID: 21196346; PMCID: PMC3360947.
9. Nanci A. *Ten Cate's Oral Histology: Development, Structure and Function.* 9th edition. New York: Elsevier; 2017.
10. Holland GR. Morphological features of dentine and pulp related to dentine sensitivity. *Arch Oral Biol.* 1994;39 Suppl:3S-11S. doi: 10.1016/0003-9969(94)90182-1. PMID: 7702463.
11. Marion D, Jean A, Hamel H, Kerebel LM, Kerebel B. Scanning electron microscopic study of odontoblasts and circumpulpal dentin in a human tooth. *Oral Surg Oral Med Oral Pathol.* 1991 Oct;72(4):473-8. doi: 10.1016/0030-4220(91)90563-r. PMID: 1923448.

12. Mitsiadis TA, De Bari C, About I. Apoptosis in developmental and repair-related human tooth remodeling: a view from the inside. *Exp Cell Res*. 2008 Feb 15;314(4):869-77. doi: 10.1016/j.yexcr.2007.11.001. Epub 2007 Nov 12. PMID: 18054913.
13. Murray PE, About I, Lumley PJ, Franquin JC, Remusat M, Smith AJ. Human odontoblast cell numbers after dental injury. *J Dent*. 2000 May;28(4):277-85. doi: 10.1016/s0300-5712(99)00078-0. PMID: 10722902.
14. Couve E. Ultrastructural changes during the life cycle of human odontoblasts. *Arch Oral Biol*. 1986;31(10):643-51. doi: 10.1016/0003-9969(86)90093-2. PMID: 3477208.
15. Gotjamanos T. Cellular organization in the subodontoblastic zone of the dental pulp. II. Period and mode of development of the cell-rich layer in rat molar pulps. *Arch Oral Biol*. 1969 Sep;14(9):1011-9. doi: 10.1016/0003-9969(69)90071-5. PMID: 5259646.
16. Kim S, Dörscher-Kim JE, Liu M. Microcirculation of the dental pulp and its autonomic control. *Proc Finn Dent Soc*. 1989;85(4-5):279-87. PMID: 2635779.
17. Iijima T, Zhang JQ. Three-dimensional wall structure and the innervation of dental pulp blood vessels. *Microsc Res Tech*. 2002 Jan 1;56(1):32-41. doi: 10.1002/jemt.10007. PMID: 11810704.
18. Takahashi K, Kishi Y, Kim S. A scanning electron microscope study of the blood vessels of dog pulp using corrosion resin casts. *J Endod*. 1982 Mar;8(3):131-5. doi: 10.1016/S0099-2399(82)80249-5. PMID: 7042891.
19. Marion D, Jean A, Hamel H, Kerebel LM, Kerebel B. Scanning electron microscopic study of odontoblasts and circumpulpal dentin in a human tooth. *Oral Surg Oral Med Oral Pathol*. 1991 Oct;72(4):473-8. doi: 10.1016/0030-4220(91)90563-r. PMID: 1923448.
20. O'Rahilly R, Müller F. Neurulation in the normal human embryo. *Ciba Found Symp*. 1994;181:70-82; discussion 82-9. doi: 10.1002/9780470514559.ch5. PMID: 8005032.
21. Chen J, Jacox LA, Saldanha F, Sive H. Mouth development. *Wiley Interdiscip Rev Dev Biol*. 2017 Sep;6(5):e275. doi: 10.1002/wdev.275. Epub 2017 May 17. PMID: 28514120; PMCID: PMC5574021.
22. Ferguson MW. Palate development. *Development*. 1988;103 Suppl:41-60. doi: 10.1242/dev.103.Supplement.41. PMID: 3074914.

23. Balic A. Concise Review: Cellular and Molecular Mechanisms Regulation of Tooth Initiation. *Stem Cells*. 2019 Jan;37(1):26-32. doi: 10.1002/stem.2917. Epub 2018 Nov 20. PMID: 30270477.
24. Wang LL, Olmo H. Odontogenic Cysts. (Updated 2022 Sep 26). In: StatPearls (Internet). Treasure Island (FL): StatPearls Publishing; 2024 Jan-. Available from: <https://www.ncbi.nlm.nih.gov/books/NBK574529/>
25. Featherstone JD. Dental caries: a dynamic disease process. *Aust Dent J*. 2008 Sep;53(3):286-91. doi: 10.1111/j.1834-7819.2008.00064.x. PMID: 18782377.
26. Lyngø Pedersen AM, Belstrøm D. The role of natural salivary defences in maintaining a healthy oral microbiota. *Journal of Dentistry*, Volume 80, Supplement 1, 2019, Pages S3-S12, ISSN 0300-5712, <https://doi.org/10.1016/j.jdent.2018.08.010>. (<https://www.sciencedirect.com/science/article/pii/S030057121830335X>)
27. Ickywiki. Dental Caries Pathogenesis (Internet) Wikimediacommons 2020 Jan. 15, https://commons.wikimedia.org/wiki/File:Dental_Caries_Pathogenesis_.jpg
28. Goldberg M (2020) Enamel and Dentin Carious Lesions. *JSM Dent* 8(1): 1120.
29. Gugnani N, Pandit IK, Srivastava N, Gupta M, Sharma M. International Caries Detection and Assessment System (ICDAS): A New Concept. *Int J Clin Pediatr Dent*. 2011 May-Aug;4(2):93-100. doi: 10.5005/jp-journals-10005-1089. Epub 2010 Apr 15. PMID: 27672245; PMCID: PMC5030492.
30. Mejåre IA, Axelsson S, Davidson T, Frisk F, Hakeberg M, Kvist T, Norlund A, Petersson A, Portenier I, Sandberg H, Tranaeus S, Bergenholtz G. Diagnosis of the condition of the dental pulp: a systematic review. *Int Endod J*. 2012 Jul;45(7):597-613. doi: 10.1111/j.1365-2591.2012.02016.x. Epub 2012 Feb 13. PMID: 22329525.
31. Bjørndal L. The caries process and its effect on the pulp: the science is changing and so is our understanding. *J Endod*. 2008 Jul;34(7 Suppl):S2-5. doi: 10.1016/j.joen.2008.02.037. PMID: 18565367.
32. Love RM, Jenkinson HF. Invasion of dentinal tubules by oral bacteria. *Crit Rev Oral Biol Med*. 2002;13(2):171-83. doi: 10.1177/154411130201300207. PMID: 12097359.
33. Fish EW. Dead Tracts in Dentine. *Proc R Soc Med*. 1928 Dec;22(2):227-36. PMID: 19986764; PMCID: PMC2101950.

34. Yan W, Jiang E, Renteria C, Paranjpe A, Arola DD, Liao L, Ren X, Zhang H. Odontoblast apoptosis and intratubular mineralization of sclerotic dentin with aging. *Arch Oral Biol.* 2022 Apr;136:105371. doi: 10.1016/j.archoralbio.2022.105371. Epub 2022 Feb 8. PMID: 35183920.
35. Duncan HF, Cooper PR, Smith AJ. Dissecting dentine-pulp injury and wound healing responses: consequences for regenerative endodontics. *Int Endod J.* 2019 Mar;52(3):261-266. doi: 10.1111/iej.13064. PMID: 30724394.
36. Senawongse P, Otsuki M, Tagami J, Mjör I. Age-related changes in hardness and modulus of elasticity of dentine. *Arch Oral Biol.* 2006 Jun;51(6):457-63. doi: 10.1016/j.archoralbio.2005.11.006. Epub 2006 Jan 19. PMID: 16426564.
37. Farges JC, Alliot-Licht B, Renard E, Ducret M, Gaudin A, Smith AJ, Cooper PR. Dental Pulp Defence and Repair Mechanisms in Dental Caries. *Mediators Inflamm.* 2015;2015:230251. doi: 10.1155/2015/230251. Epub 2015 Oct 11. PMID: 26538821; PMCID: PMC4619960.
38. Nakashima M. The induction of reparative dentine in the amputated dental pulp of the dog by bone morphogenetic protein. *Arch Oral Biol.* 1990;35(7):493-7. doi: 10.1016/0003-9969(90)90078-o. PMID: 2222252.
39. Smith AJ, Lumley PJ, Tomson PL, Cooper PR. Dental regeneration and materials: a partnership. *Clin Oral Investig.* 2008 Jun;12(2):103-8. doi: 10.1007/s00784-008-0189-5. Epub 2008 Feb 13. PMID: 18270756.
40. Gutmann JL. Grossman's Endodontic Practice – 13th Edition. *J Conserv Dent.* 2016 Sep-Oct;19(5):494. doi: 10.4103/0972-0707.190011. PMCID: PMC5026116.
41. Peters OA, Rossi-Fedele G, George R, Kumar K, Timmerman A, Wright PP. Guidelines for non-surgical root canal treatment. *Aust Endod J.* 2024 Jun 12. doi: 10.1111/aej.12848. Epub ahead of print. PMID: 38864671.
42. Ahmed GM, Abouauf EA, AbuBakr N, Fouad AM, Dörfer CE, Fawzy El-Sayed KM. Cell-Based Transplantation versus Cell Homing Approaches for Pulp-Dentin Complex Regeneration. *Stem Cells Int.* 2021 Sep 29;2021:8483668. doi: 10.1155/2021/8483668. PMID: 34646323; PMCID: PMC8505125.

43. Guerrero F, Mendoza A, Ribas D, Aspiazu K. Apexification: A systematic review. *J Conserv Dent*. 2018 Sep-Oct;21(5):462-465. doi: 10.4103/JCD.JCD_96_18. PMID: 30294103; PMCID: PMC6161512.
44. Wei X, Yang M, Yue L, Huang D, Zhou X, Wang X, Zhang Q, Qiu L, Huang Z, Wang H, Meng L, Li H, Chen W, Zou X, Ling J. Expert consensus on regenerative endodontic procedures. *Int J Oral Sci*. 2022 Dec 1;14(1):55. doi: 10.1038/s41368-022-00206-z. PMID: 36450715; PMCID: PMC9712432.
45. Priya B L, Singh N, Mangalam KK, Sachdev R, P A, Jain HN, Nagi PK. Success and Complication Rates of Revascularization Procedures for Immature Necrotic Teeth: A Systematic Review. *Cureus*. 2023 Dec 30;15(12):e51364. doi: 10.7759/cureus.51364. PMID: 38292962; PMCID: PMC10825383.
46. Galler KM. Clinical procedures for revitalization: current knowledge and considerations. *Int Endod J*. 2016 Oct;49(10):926-36. doi: 10.1111/iej.12606. Epub 2016 Feb 1. PMID: 26715631.
47. Yang J, Yuan G, Chen Z. Pulp Regeneration: Current Approaches and Future Challenges. *Front Physiol*. 2016 Mar 7;7:58. doi: 10.3389/fphys.2016.00058. PMID: 27014076; PMCID: PMC4779938.
48. Wei X, Yang M, Yue L, Huang D, Zhou X, Wang X, Zhang Q, Qiu L, Huang Z, Wang H, Meng L, Li H, Chen W, Zou X, Ling J. Expert consensus on regenerative endodontic procedures. *Int J Oral Sci*. 2022 Dec 1;14(1):55. doi: 10.1038/s41368-022-00206-z. PMID: 36450715; PMCID: PMC9712432.
49. Yan H, De Deus G, Kristoffersen IM, Wiig E, Reseland JE, Johnsen GF, Silva EJNL, Haugen HJ. Regenerative Endodontics by Cell Homing: A Review of Recent Clinical trials. *J Endod*. 2023 Jan;49(1):4-17. doi: 10.1016/j.joen.2022.09.008. Epub 2022 Oct 18. PMID: 36270575.
50. Gathani KM, Raghavendra SS. Scaffolds in regenerative endodontics: A review. *Dent Res J (Isfahan)*. 2016 Sep;13(5):379-386. doi: 10.4103/1735-3327.192266. PMID: 27857762; PMCID: PMC5090995.
51. Mao JJ, Kim SG, Zhou J, Ye L, Cho S, Suzuki T, Fu SY, Yang R, Zhou X. Regenerative endodontics: barriers and strategies for clinical translation. *Dent Clin North Am*. 2012 Jul;56(3):639-49. doi: 10.1016/j.cden.2012.05.005. PMID: 22835543; PMCID: PMC4093795.

52. Yuan Z, Nie H, Wang S, Lee CH, Li A, Fu SY, Zhou H, Chen L, Mao JJ. Biomaterial selection for tooth regeneration. *Tissue Eng Part B Rev.* 2011 Oct;17(5):373-88. doi: 10.1089/ten.TEB.2011.0041. PMID: 21699433; PMCID: PMC3179624.
53. Pelissari C, Paris AFC, Mantesso A, Trierveiler M. Apical Papilla Cells Are Capable of Forming a Pulplike Tissue with Odontoblastlike Cells without the Use of Exogenous Growth Factors. *J Endod.* 2018 Nov;44(11):1671-1676. doi: 10.1016/j.joen.2018.08.005. PMID: 30409448.
54. Widbiller M, Driesen RB, Eidt A, Lambrechts I, Hiller KA, Buchalla W, Schmalz G, Galler KM. Cell Homing for Pulp Tissue Engineering with Endogenous Dentin Matrix Proteins. *J Endod.* 2018 Jun;44(6):956-962.e2. doi: 10.1016/j.joen.2018.02.011. Epub 2018 Mar 29. PMID: 29606400.
55. Lovelace TW, Henry MA, Hargreaves KM, Diogenes A. Evaluation of the delivery of mesenchymal stem cells into the root canal space of necrotic immature teeth after clinical regenerative endodontic procedure. *J Endod.* 2011 Feb;37(2):133-8. doi: 10.1016/j.joen.2010.10.009. PMID: 21238791.
56. Altaï M, Richards L, Rossi-Fedele G. Histological assessment of regenerative endodontic treatment in animal studies with different scaffolds: A systematic review. *Dent Traumatol.* 2017 Aug;33(4):235-244. doi: 10.1111/edt.12338. Epub 2017 Apr 20. PMID: 28342218.
57. Murray PE. Platelet-Rich Plasma and Platelet-Rich Fibrin Can Induce Apical Closure More Frequently Than Blood-Clot Revascularization for the Regeneration of Immature Permanent Teeth: A Meta-Analysis of Clinical Efficacy. *Front Bioeng Biotechnol.* 2018 Oct 11;6:139. doi: 10.3389/fbioe.2018.00139. PMID: 30364277; PMCID: PMC6193104.
58. Morsczeck C, Schmalz G, Reichert TE, Völlner F, Galler K, Driemel O. Somatic stem cells for regenerative dentistry. *Clin Oral Investig.* 2008 Jun;12(2):113-8. doi: 10.1007/s00784-007-0170-8. Epub 2008 Jan 3. PMID: 18172700.
59. Takahashi K, Okita K, Nakagawa M, Yamanaka S. Induction of pluripotent stem cells from fibroblast cultures. *Nat Protoc.* 2007;2(12):3081-9. doi: 10.1038/nprot.2007.418. PMID: 18079707.
60. Takahashi K, Okita K, Nakagawa M, Yamanaka S. Induction of pluripotent stem cells from fibroblast cultures. *Nat Protoc.* 2007;2(12):3081-9. doi: 10.1038/nprot.2007.418. PMID: 18079707.

61. Sabbagh J, Ghassibe-Sabbagh M, Fayyad-Kazan M, Al-Nemer F, Fahed JC, Berberi A, Badran B. Differences in osteogenic and odontogenic differentiation potential of DPSCs and SHED. *J Dent.* 2020 Oct;101:103413. doi: 10.1016/j.jdent.2020.103413. Epub 2020 Jun 22. PMID: 32585262.
62. Seo BM, Miura M, Gronthos S, Bartold PM, Batouli S, Brahim J, Young M, Robey PG, Wang CY, Shi S. Investigation of multipotent postnatal stem cells from human periodontal ligament. *Lancet.* 2004 Jul 10-16;364(9429):149-55. doi: 10.1016/S0140-6736(04)16627-0. PMID: 15246727.
63. Nada OA, El Backly RM. Stem Cells From the Apical Papilla (SCAP) as a Tool for Endogenous Tissue Regeneration. *Front Bioeng Biotechnol.* 2018 Jul 24;6:103. doi: 10.3389/fbioe.2018.00103. PMID: 30087893; PMCID: PMC6066565.
64. Zhou T, Pan J, Wu P, Huang R, Du W, Zhou Y, Wan M, Fan Y, Xu X, Zhou X, Zheng L, Zhou X. Dental Follicle Cells: Roles in Development and Beyond. *Stem Cells Int.* 2019 Sep 15;2019:9159605. doi: 10.1155/2019/9159605. PMID: 31636679; PMCID Q: PMC6766151.
65. Schroeder KD. Human tooth diagram-en.svg (Internet) Wikimediacommons 2016 Oct. 29. https://commons.wikimedia.org/wiki/File:Human_tooth_diagram-en.svg
66. Lo Celso C, Scadden DT. The haematopoietic stem cell niche at a glance. *J Cell Sci.* 2011 Nov 1;124(Pt 21):3529-35. doi: 10.1242/jcs.074112. PMID: 22083139; PMCID: PMC3215569.
67. Álvarez-Vásquez JL, Castañeda-Alvarado CP. Dental Pulp Fibroblast: A Star Cell. *J Endod.* 2022 Aug;48(8):1005-1019. doi: 10.1016/j.joen.2022.05.004. Epub 2022 May 14. PMID: 35577145.
68. Kornsuthisopon C, Nowwarote N, Chansaenroj A, Photichailert S, Rochanavibhata S, Klincumhom N, Petit S, Dingli F, Loew D, Fournier BPJ, Osathanon T. Human dental pulp stem cells derived extracellular matrix promotes mineralization via Hippo and Wnt pathways. *Sci Rep.* 2024 Mar 21;14(1):6777. doi: 10.1038/s41598-024-56845-1. PMID: 38514682; PMCID: PMC10957957.
69. Kim SG, Zhou J, Solomon C, Zheng Y, Suzuki T, Chen M, Song S, Jiang N, Cho S, Mao JJ. Effects of growth factors on dental stem/progenitor cells. *Dent Clin North Am.* 2012 Jul;56(3):563-75. doi: 10.1016/j.cden.2012.05.001. PMID: 22835538; PMCID: PMC4112411.

70. Gronthos S, Mankani M, Brahim J, Robey PG, Shi S. Postnatal human dental pulp stem cells (DPSCs) in vitro and in vivo. *Proc Natl Acad Sci U S A*. 2000 Dec 5;97(25):13625-30. doi: 10.1073/pnas.240309797. PMID: 11087820; PMCID: PMC17626.
71. Li XL, Fan W, Fan B. Dental pulp regeneration strategies: A review of status quo and recent advances. *Bioact Mater*. 2024 May 7;38:258-275. doi: 10.1016/j.bioactmat.2024.04.031. PMID: 38745589; PMCID: PMC11090883.
72. Miura M, Gronthos S, Zhao M, Lu B, Fisher LW, Robey PG, Shi S. SHED: stem cells from human exfoliated deciduous teeth. *Proc Natl Acad Sci U S A*. 2003 May 13;100(10):5807-12. doi: 10.1073/pnas.0937635100. Epub 2003 Apr 25. PMID: 12716973; PMCID: PMC156282.
73. Gonçalves SB, Dong Z, Bramante CM, Holland GR, Smith AJ, Nör JE. Tooth slice-based models for the study of human dental pulp angiogenesis. *J Endod*. 2007 Jul;33(7):811-4. doi: 10.1016/j.joen.2007.03.012. Epub 2007 May 7. PMID: 17804317.
74. Nakashima M, Iohara K, Bottino MC, Fouad AF, Nör JE, Huang GT. Animal Models for Stem Cell-Based Pulp Regeneration: Foundation for Human Clinical Applications. *Tissue Eng Part B Rev*. 2019 Apr;25(2):100-113. doi: 10.1089/ten.TEB.2018.0194. Epub 2019 Jan 9. PMID: 30284967; PMCID: PMC6486672.
75. Thalakiriyawa DS, Dissanayaka WL. Advances in Regenerative Dentistry Approaches: An Update. *Int Dent J*. 2024 Feb;74(1):25-34. doi: 10.1016/j.identj.2023.07.008. Epub 2023 Aug 2. PMID: 37541918; PMCID: PMC10829373.
76. Xuan K, Li B, Guo H, Sun W, Kou X, He X, Zhang Y, Sun J, Liu A, Liao L, Liu S, Liu W, Hu C, Shi S, Jin Y. Deciduous autologous tooth stem cells regenerate dental pulp after implantation into injured teeth. *Sci Transl Med*. 2018 Aug 22;10(455):eaf3227. doi: 10.1126/scitranslmed.aaf3227. PMID: 30135248.
77. Xie Z, Shen Z, Zhan P, Yang J, Huang Q, Huang S, Chen L, Lin Z. Functional Dental Pulp Regeneration: Basic Research and Clinical Translation. *Int J Mol Sci*. 2021 Aug 20;22(16):8991. doi: 10.3390/ijms22168991. PMID: 34445703; PMCID: PMC8396610.
78. Smeets R, Jung O, Hanken A et.al. Regenerative Verfahren in der Zahnmedizin – was ist heute möglich? *DZZ* (Internet). 2015; 70 (6). Available from https://www.online-dzz.de/fileadmin/user_upload/Heftarchiv/DZZ/article/2015/06/44845E29-C7EB-485D-B7D7-E33E21494798/44845E29C7EB485DB7D7E33E21494798_em_ues_reg_verfahren_smeets_jung_1_original.pdf

79. Barhate A, Bajaj P, Shirbhate U, Reche A, Pahade A, Agrawal R. Implications of Gene Therapy in Dentistry and Periodontics: A Narrative Review. *Cureus*. 2023 Nov 26;15(11):e49437. doi: 10.7759/cureus.49437. PMID: 38149156; PMCID: PMC10750132.

80. Zhang J, Huang X, Wang H, Liu X, Zhang T, Wang Y, Hu D. The challenges and promises of allogeneic mesenchymal stem cells for use as a cell-based therapy. *Stem Cell Res Ther*. 2015 Dec 1;6:234. doi: 10.1186/s13287-015-0240-9. PMID: 26620426; PMCID: PMC4665863.

81. Baranovskii DS, Klabukov ID, Arguchinskaya NV, Yakimova AO, Kisel AA, Yatsenko EM, Ivanov SA, Shegay PV, Kaprin AD. Adverse events, side effects and complications in mesenchymal stromal cell-based therapies. *Stem Cell Investig*. 2022 Nov 8;9:7. doi: 10.21037/sci-2022-025. PMID: 36393919; PMCID: PMC9659480.

Hendrik Benjamin Oellerich completed his High School Education at Gymnasium Athenaeum Stade. He finished an apprenticeship as a dental technician at Dental-Werkstätten Stade before doing internships at two different dentist's practices. He studied Dentistry (DMD) at the University of Zagreb, Croatia, from 2018 to 2024. While studying, he continually assisted at a private clinic in Zagreb and at two practices in Germany.

Hendrik is fluent in German and English and has a basic knowledge of Latin and Croatian. He is dedicated to lifelong learning.