

# Digital protocol in implanto-prosthetic therapy

---

Tarle, Frano

Master's thesis / Diplomski rad

2024

Degree Grantor / Ustanova koja je dodijelila akademski / stručni stupanj: **University of Zagreb, School of Dental Medicine / Sveučilište u Zagrebu, Stomatološki fakultet**

Permanent link / Trajna poveznica: <https://um.nsk.hr/um:nbn:hr:127:196345>

Rights / Prava: [In copyright](#) / [Zaštićeno autorskim pravom.](#)

Download date / Datum preuzimanja: **2025-01-02**



Repository / Repozitorij:

[University of Zagreb School of Dental Medicine  
Repository](#)





University of Zagreb

School of Dental Medicine

Franco Tarle

DIGITAL PROTOCOL IN IMPLANTO-  
PROSTHETIC THERAPY

Graduate thesis

Zagreb, 2024

The work was carried out at: Department of Fixed Prosthodontics, School of Dental Medicine, University of Zagreb

Thesis mentor: prof. dr. sc. Marko Jakovac, Department of Fixed Prosthodontics, School of Dental Medicine, University of Zagreb

English language proofreader: Ana Perić, Professor of English language

Croatian language proofreader: Marija Čavar Sopta, Professor of Croatian language

The manuscript contains: 32 pages

5 pictures

The paper is an author's own work, which is completely independently written with an indication of the sources of other authors and documents used in the paper. Unless otherwise stated, all illustrations (tables, pictures, etc.) in the paper are the original contribution of the author of the thesis. The author is responsible for obtaining permission for the use of illustrations that are not his original contribution, as well as for any possible consequences that may arise due to unauthorized downloading of illustrations or failure to indicate their origin.

## **Thanks**

To my mentor, Prof. dr. sc. Marko Jakovac, for Your patience, generous advices and knowledge that helped me go through this process painlessly.

To my friends, for being my shield from everyday obligations.

To my girlfriend, for sharing good and bad with me throughout this journey and being by my side when I needed it the most.

To my grandparents, aunt, uncle and cousins for the overwhelming support in the toughest moments.

To my parents and brother, for their unconditional love. Without them, I would not be where I am today.

# **DIGITAL PROTOCOL IN IMPLANTO-PROSTHETIC THERAPY**

## **Summary**

Digital technologies have strongly impacted dental procedures, particularly in the field of implant prosthetics. Digital dentistry, including digital impressions, CAD/CAM, and 3D printing, has revolutionized traditional practices, streamlining workflows and enhancing treatment accuracy and efficiency. While these advancements are well-established in fixed prosthetics, their application in implant prosthetics remains limited. A comprehensive digital protocol is proposed to solve this issue. The historical development of digital dentistry is documented, starting with the introduction of CT scanners and CAD/CAM systems and ending with the adoption of 3D printing, highlighting significant technological milestones. The digital protocol includes thorough initial consultations using advanced 3D radiographic imaging for precise virtual implant planning, leading to the creation of detailed surgical guides through CAD/CAM and 3D printing. These guides ensure accurate implant placement, reduce surgical risks, and improve outcomes. The protocol also emphasizes the advantages of digital impression techniques over traditional methods, despite challenges in scanning long span or edentulous arches. Solutions such as intraoral scan bodies and photogrammetry are suggested to enhance accuracy. Prosthetic design and fitting are discussed, focusing on factors like crown geometry, abutment design, and material choice to ensure optimal occlusal force distribution and long-term success. The need to extend digital advancements to implant prosthetics is pointed out, providing a pathway to improved outcomes in this critical area of dentistry.

**Keywords:** Digital dentistry, Implant prosthetics, CAD/CAM, Digital impressions, Surgical guides

## DIGITALNI PROTOKOL RADA U IMPLANTOPROTETICI

### Sažetak

Digitalne tehnologije značajno su utjecale na stomatološke postupke, posebno u području implantoprotetike. Digitalna stomatologija, uključujući digitalne otiske, CAD/CAM i 3D ispis, revolucionirala je tradicionalnu praksu, pojednostavljujući rad i poboljšavajući točnost i učinkovitost tretmana. Iako su ova unapređenja dobro uspostavljena u fiksnoj protetici, njihova primjena u implantoprotetici još uvijek je ograničena. Predlaže se sveobuhvatan digitalni protokol kako bi se riješio ovaj problem. Povijesni razvoj digitalne stomatologije je dokumentiran od uvođenja CT skenera i CAD/CAM sustava do usvajanja 3D ispisa, ističući značajne tehnološke prekretnice. Navedeni digitalni protokol uključuje temeljite početne konzultacije korištenjem naprednog 3D radiografskog snimanja za precizno virtualno planiranje implantata, što vodi do izrade detaljnih kirurških vodilica putem CAD/CAM-a i 3D ispisa. Ove vodilice osiguravaju točno postavljanje implantata, smanjuju kirurške rizike i poboljšavaju rezultate. Protokol također naglašava prednosti digitalnih tehnika uzimanja otisaka u odnosu na tradicionalne metode, unatoč izazovima u skeniranju dugih lukova ili bezubih čeljusti. Predložena su rješenja poput intraoralnih nadogradnji za skeniranje i fotogrametrije za poboljšanje točnosti. Raspravlja se o dizajnu i postavljanju protetike, fokusirajući se na čimbenike kao što su geometrija krunice, dizajn bataljka i izbor materijala kako bi se osigurala optimalna raspodjela okluzalnih sila i dugoročni uspjeh. Naglašava se potreba za proširenjem digitalnih napredaka na implantoprotetiku, pružajući put do poboljšanih rezultata u ovom kritičnom području stomatologije.

**Ključne riječi:** Digitalna stomatologija, Implantoprotetika, CAD/CAM, Digitalni otisak, Kirurške vodilice

## TABLE OF CONTENTS

1.INTRODUCTION.....	1
2. HISTORY OF DIGITAL DENTISTRY.....	4
3.DIGITAL PROTOCOL.....	6
3.1. Initial consultation and digital planning.....	7
3.2. Surgical guides.....	9
3.2.1. Fabrication.....	10
3.2.2. Surgical guide design.....	12
3.3. Implant placement.....	12
3.4. Digital impression techniques.....	13
3.5. Prosthetic design and fitting.....	14
3.6. Post-operative care and Follow-Up.....	17
4.DISCUSSION.....	20
5.CONCLUSION.....	24
6.LITERATURE.....	26
7. BIOGRAPHY.....	31

## **List of abbreviations**

CAD/CAM - Computer-Aided Design/Computer-Aided Manufacturing

CT - Computed Tomography

CEREC - Chairside Economical Restoration of Esthetic Ceramics

CB-CT - Cone Beam Computed Tomography

DICOM - Digital Imaging and Communications in Medicine

STL - Standard tessellation language

IOS - Intraoral scanner

ISB - Intraoral scan body

PEEK - Polyether ether ketone

PMMA - Polymethyl methacrylate

NIC - Narrow impression coping

WIC - Wide impression coping

SSB - Short scan body

LSB - Long scan body

RCT- Randomized controlled trial

IC - Interproximal contact

OC - Occlusal contact

IT - Impression time

VAS - Visual analog scale

AI - Artificial intelligence

AR - Augmented reality



## 1. INTRODUCTION



The field of dentistry has witnessed significant technological advancements over the past few decades, revolutionizing traditional practices and enhancing patient care. Among these advancements, the digitalization of dental procedures stands out as a transformative trend. Digital dentistry encompasses technologies, including digital impressions, computer-aided design / computer-aided manufacturing (CAD/CAM), and 3D printing. These technologies have not only simplified workflows but have also improved the efficiency and accuracy of dental treatments. One area where digital dentistry has demonstrated significant potential is fixed prosthodontics, where the digital protocol has become well-established. However, there remains a pressing need to extend these advancements to implant prosthetics, a field that continues to rely heavily on conventional methods (1).

Implant prosthetics involve the placement of dental implants, which serve as artificial tooth roots, followed by the subsequent fitting of prosthetic teeth. This procedure is essential for restoring the function and aesthetics of the patients' dentition, particularly those who have lost teeth due to trauma, decay, or periodontal disease. The patient's journey through the toothless stages, from edentulism (complete tooth loss) to the restoration of dental function with implants, is often challenging. These stages include initial tooth loss, adaptation to edentulism, the planning and placement of implants, and the final prosthetic restoration. (2).

Toothlessness, or edentulism, is when someone is missing their natural teeth. Good oral health is crucial for a person's overall well-being and development. Teeth are important for appearance, eating, speech, balance, and comfort. Losing teeth can have physical, emotional, and psychological effects, impacting daily life. It can be categorized into three categories: partial edentulism, complete edentulism, and the partial-to-complete edentulism transition. Partial edentulism refers to losing some teeth while retaining others, which can significantly affect chewing efficiency and aesthetics. Complete edentulism is the total loss of all teeth in one or both jaws, leading to severe impairment in function and appearance. The transition from partial to complete edentulism often occurs progressively due to ongoing dental issues or aging, complicating the restoration process as patients adapt to increasing tooth loss (1).

Partial edentulism presents unique challenges, as the remaining teeth must be preserved and used as support for dental prosthetics. Digital technology can enhance the precision of fitting

partial dentures or implant-supported crowns, ensuring a better match with the patient's existing teeth. Complete edentulism, on the other hand, often requires full-arch restorations, where digital workflows can significantly improve the planning and execution of implant placement and prosthetic design (1).

The introduction of dental implants provides an effective solution for patients transitioning from any form of edentulism to a restored dental state. However, the traditional process of planning and placing implants is complex and time-consuming. It involves multiple visits, manual impressions, and handcrafted prosthetics, which can introduce inaccuracies and prolong treatment times. Digital technology has the potential to revolutionize this process by providing precise, efficient, and patient-friendly solutions (2).

The purpose of this thesis is to propose a comprehensive digital protocol for implant prosthetics, building upon the latest technological advancements and clinical knowledge. This proposed protocol aims to streamline the workflow from initial patient consultation to post-operative care by integrating digital tools such as 3D imaging, CAD/CAM systems, and computer-guided surgery. The intention of this thesis is to demonstrate how these innovations can revolutionize the planning, fabrication, and placement of prosthetic implants. The goal is to contribute to the growing body of knowledge in digital dentistry and provide a comprehensive framework for future applications in clinical practice (3).

## **2. HISTORY OF DIGITAL DENTISTRY**



The history of digital dentistry is a journey that began with major advancements in medical imaging and gradually expanded to include a wide range of digital tools and technologies. Everything started in the 1970s with the introduction of CT scanners. They revolutionized dental imaging by providing 3D images of the teeth and jaw, significantly improving diagnosis and treatment planning (4).

The initial successful application of CAD/CAM technology in dentistry occurred in 1982 with the launch of the CEREC 1 chairside system by Sirona. That system enabled the design of dental restorations on a computer, which could then be milled from a block of material. This innovation significantly improved the precision and efficiency of dental restorations. In other words, these technological advancements marked significant steps forward in dental care, enhancing both the accuracy and efficiency of dental treatments (5).

In the 1990s, the first 3D printer for dental applications was introduced. This technology rapidly advanced and became widely used in dental practices for creating crowns, bridges, and other restorations (4).

One of the early pioneers of digital dentistry was the CEREC system (Chairside Economical Restoration of Esthetic Ceramics), developed in the early 1990s by Dr. Warner Moorman and engineer Marco Brandestini. CEREC used digital imaging and CAD/CAM technology to create custom restorations in a single visit, significantly reducing the time and complexity of dental procedures. The system quickly gained popularity among dentists (6).

In the last 20 years, digital dentistry has continued to evolve rapidly.

Today, digital workflows are becoming standard practice in dental clinics, continually enhancing the accuracy, efficiency, and patient experience of dental care. As technology advances further, we anticipate even more transformative developments, such as artificial intelligence and augmented reality, which promise to make dental treatments more precise, personalized, and accessible (4).

### **3. DIGITAL PROTOCOL**



### **3.1. Initial consultation and digital planning**

Evolution in implant therapy has contributed a lot to the dynamic progress of modern dentistry. The key to the success of implant prosthetic therapy lies in the development of a comprehensive treatment plan that carefully integrates both the surgical and prosthetic components. Unfortunately, it is not uncommon for clinicians to skip essential prosthetic principles when formulating treatment strategies (7).

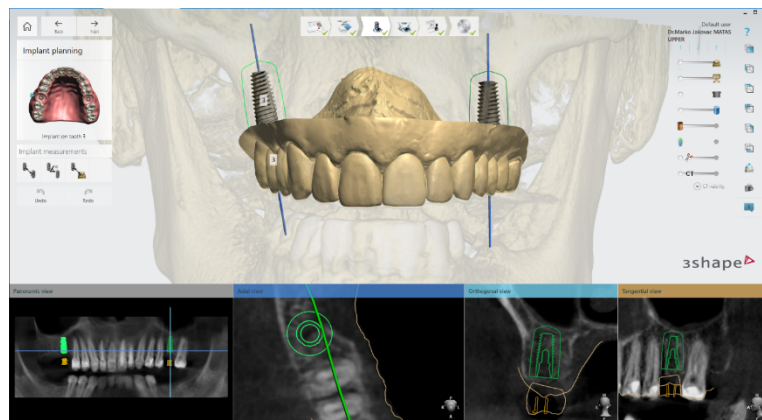
The initial consultation is essential for determining a patient's suitability for a reconstructive procedure. In this phase, a preliminary treatment plan is developed by considering the patient's main complaint, history of the current illness, medical and dental background, and results from radiographic evaluations. Based on the clinical assessment, the appropriate imaging technique (3D radiography) is selected to obtain detailed information about the proposed implant site. Preoperative extraoral and intraoral photographs are taken to document the patient's facial appearance. This consultation also plays a key role in informing and preparing the patient for the upcoming procedures and potential work outcomes (7).

Digital planning has improved modern dentistry a lot. Traditional implant planning uses clinical exams and 2D radiographic images, but 3D imaging like CT and CB-CT provides a more precise evaluation of bone dimensions, nerve paths, and nearby teeth. This 3D data is essential for virtual implant planning and the CAD/CAM process for drill guides or prostheses. CB-CT is often preferred over CT for implant planning due to its lower radiation dose (92–118  $\mu\text{Sv}$  vs. 860  $\mu\text{Sv}$ ). Both CT and CB-CT images are stored in the DICOM format, which includes imaging data and acquisition details (8).

CT and CB-CT data are visualized in 2D cross-sections and 3D models through segmentation, assigning gray values to voxels based on radiation attenuation. However, these scans may not adequately show tooth surfaces needed for prosthetic setup and drill guide production, especially with restorations causing artifacts. Therefore, they are combined with virtual dental models from optical scans of impressions or stone casts, available in STL format (8).

Aligning these datasets, known as registration, can be done using the tooth surface or fiducial markers. Standardized markers enable a single scan protocol, while custom markers require a double scan protocol. If the tooth surface is used, no splint with markers is needed. Registration can be automatic or semi-automatic and is crucial for accurate implant placement (8).

After importing, segmenting, and registering the data, the prosthetic setup and virtual implant position are planned (Picture 1). This involves positioning the implant-supported prosthesis, considering abutment design and tooth morphology. Implants are virtually positioned in cross-sections and 3D models (8).



Picture 1. Implant planning

Taken with permission of prof. dr. sc. Marko Jakovac

A virtual prosthetic setup eliminates the need for traditional preliminary setups and radiographic splints, as all procedures are executed within the software. The planning software provides various tools for creating a virtual setup, including a library of standard tooth shapes, shaping tools, and virtual articulators to facilitate functional setup. A virtual prosthetic setup, developed for automated restoration design in CAD software, is based on a mathematical algorithm that incorporates multiple tooth characteristics to generate a prosthetic setup for missing teeth. Virtual articulators in CAD software enable the analysis of static and dynamic occlusion, replacing mechanical articulators. Depending on the selected virtual articulator, settings like Bennett angle, condylar inclination, and immediate mandibular lateral translation can be adjusted. Additionally, masticatory movements can be simulated, with occlusion marked in color for automatic or manual alignment of the virtual setup (9).



For virtual implant planning, radiographic data on the patient is collected to provide information about bone dimensions in the intended implant placement area. Three-dimensional imaging, such as CB-CT, supplies essential data for virtual implant planning. With the prosthetic setup and individual anatomy information, implants are virtually positioned in cross-sectional images and 3D surface models reconstructed from the radiographic volume. The software helps in measuring distances between planned implants (3 mm) and between implants and the inferior alveolar nerve canal (2 mm). It should allow the virtual placement of various implant systems, with options to modify implant type, length, diameter, height, inclination, and rotation as needed. After finalizing an implant, its position is confirmed by multiplanar images, and the corresponding drill sleeves are chosen for guided implant surgery (9).

### **3.2. Surgical guides**

With the development of computer-assisted implantology, CAD/CAM technologies, and 3D printing, pre-surgical plans can now be implemented using static surgical guides. These guides enable clinicians to replicate virtually all planned therapies during surgery. The surgical guide serves as a crucial tool for ensuring a predictable, safe, and minimally invasive procedure. It is a guiding device that aids in the precise placement and angulation of dental implants. The main objective of a surgical template is to direct the implant drilling process, ensuring implants are accurately positioned according to the surgical treatment plan. Customized conventional radiographic templates and computer image-guided surgical templates have become the preferred methods for transferring the treatment plan accurately to the surgical site (10).

A surgical guide includes two essential components: the contact surface and the guiding cylinders. The contact surface conforms to a specific area of the patient's teeth, bones, or mucosa. Tooth-supported surgical guides are used in cases of partial edentulism and rely on adjacent teeth. These guides allow for minimally invasive surgical techniques without raising a full flap (11).

Bone-supported surgical guides are used in the treatment of completely edentulous patients. The primary advantage of these guides is their ability to provide excellent visibility of the surgical field, thereby allowing optimal control over the depth and location of implant placement. However,

using this type of guide requires raising a full flap to expose the bone, which leads to increased discomfort for the patient during and after surgery. Additionally, there is a risk of bone loss due to reduced postoperative blood supply to the area. These guides are most commonly used in procedures involving the remodeling of the entire alveolar ridge (11).

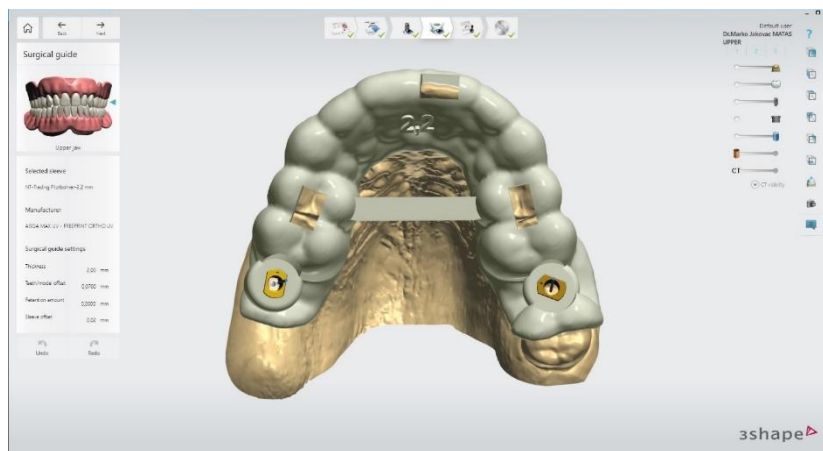
Mucosa-supported surgical guides are also used in completely edentulous patients, relying only on the mucosa. Their main advantage is that they facilitate minimally invasive surgical procedures without the need for flap elevation, which promotes faster healing. The downside is the inability to directly access the bone or shape the soft tissues during surgery (11).

The cylinders in the drill guides are critical for transferring the treatment plan by directing the drill to a precise location and orientation.

Several considerations must be taken into account when placing the implant. Primarily, the implant must be fully surrounded by bone or bone-replacement material on all sides. Additionally, it is important to avoid damaging neighboring anatomical structures, such as the mandibular nerve in the lower jaw, the maxillary sinus in the upper jaw, and the roots of adjacent teeth. Lastly, the implant's position must align with the intended final prosthodontic restoration (10).

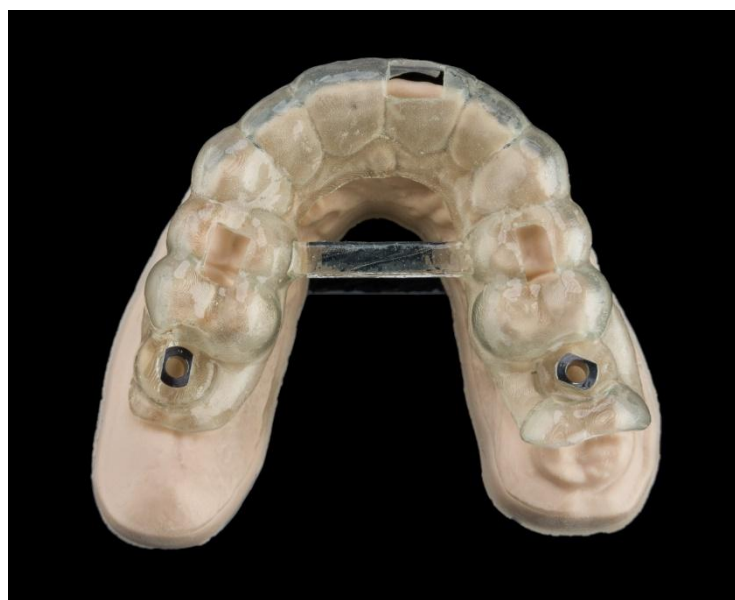### **3.2.1. Fabrication**

The digital workflow for creating a surgical guide involves several key steps. It starts with loading the digital scan into design software to define the outline and exporting the surgical guide file. The next phase focuses on determining the drill hole position by loading the guide file into another piece of software, defining and trimming the drill hole, and exporting the updated guide file (Picture 2.). The final phase involves loading this file into a printer and printing the surgical guide (Picture 3.). This structured process ensures precision in the planning and production of surgical guides (12, 13).



Picture 2. Surgical guide design

Taken with permission of prof. dr. sc. Marko Jakovac



Picture 3. Surgical guide

Taken with permission of prof. dr. sc. Marko Jakovac

### **3.2.2. Surgical guide design**

The design of surgical guides impacts the success of implant placement. Ranging from non-limiting and partially limiting to completely limiting designs, these guides vary in the control they provide over the procedure.

Non-limiting designs indicate the proposed prosthesis's position relative to the implant site without controlling the drill's angulation. They allow excessive flexibility in implant positioning. This can lead to unacceptable placement of the access hole or implant angulation, serving primarily as imaging indicators during surgery.

Partially limiting designs guide the initial drill for the osteotomy, with the remaining procedure completed freehand by the surgeon. These designs involve creating a radiographic template that is later converted into a surgical guide after evaluation.

Completely limiting designs restrict all osteotomy instruments within specific planes and use drill stops to control preparation depth, reducing intraoperative decision-making. This category includes cast-based and CAD/CAM-based surgical guides (14, 15).

### **3.3. Implant placement**

Guided implant surgery can be performed either by raising the entire mucoperiosteal flap to expose the bone or, if conditions are favorable, without raising the flap (flapless surgery). Once the surgical guide is positioned intraorally, the bone site is prepared according to preoperative planning. The implant procedure itself is similar to traditional techniques, with notable differences such as longer drill length and the requirement for metal guides. There are two primary approaches. One approach involves using multiple surgical guides, each one wider to match different drill diameters. This method can be complex due to the need for multiple surgical guides. The other approach uses a single surgical guide with a metal guide diameter matching the final, widest drill bit. It is crucial to ensure sufficient irrigation with sterile saline to avoid thermal injury during surgery (14).

### 3.4 Digital impression techniques

Digital impressions have improved implant dentistry by offering benefits over traditional methods. These include saving space and materials and enabling easier communication in digital workflows. Digital implant impressions are “carried” by the intraoral scanner (IOS), which uses an intraoral scan body (ISB) to transfer implant positions accurately. The success of these impressions depends on two key factors: trueness, which measures how closely the scan matches the actual object, and precision, which assesses the consistency of repeated scans (16).

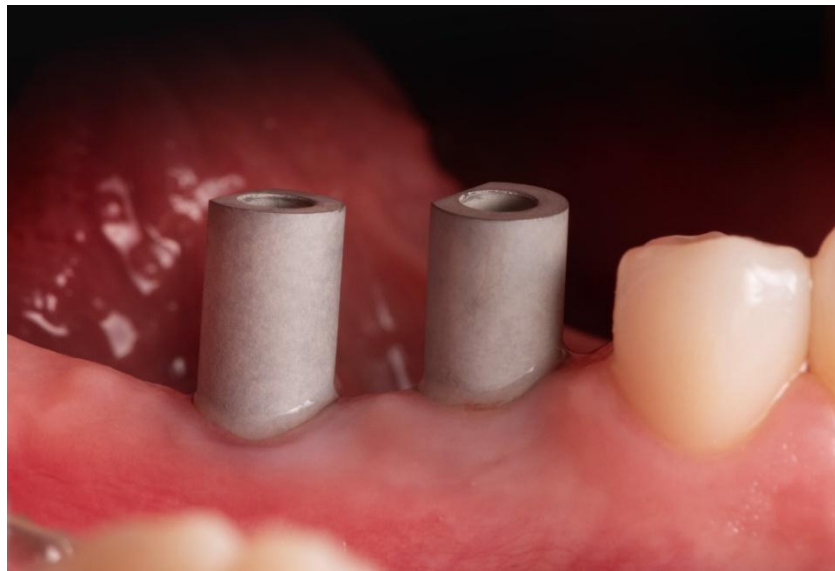An accurate impression is crucial for creating an implant-supported prosthesis and critical for successful restoration. Any distortion in the implant impression can lead to inaccurate positioning of the implant, resulting in a compromised and nonpassive fit of the prosthesis. This misfit can cause various issues, including screw loosening, fractures, peri-implant lesions, and plaque accumulation. Achieving a passive fit of the implant restoration is essential for its long-term success, which directly relies on the accuracy of the impression (16).

Digital impressions can be as accurate as traditional methods, especially for single-unit and short-span implant sites. However, accuracy decreases when scanning long-span or completely edentulous arches due to a lack of distinguishable landmarks and stable reference points between implant mucosal surfaces. This issue affects the image stitching process during scanning, leading to accumulated errors and reduced overall accuracy (17).

Various methods have been developed to improve scanning accuracy for edentulous arches with implants. These include altering the mucosal surface, using auxiliary devices, employing splinted scan bodies, and utilizing photogrammetry. While these methods have enhanced accuracy to some degree, they often involve complex, time-consuming procedures and additional steps for scanning soft tissues (17).

In intraoral scanning, scan bodies are directly attached to the implants (Picture 4.). During indirect scanning in the laboratory, scan bodies are fixed to implant analogs on a working cast created from a conventional impression. For the indirect method, scan bodies are secured to the implant analogs

of the working cast, and a laboratory scanner produces a standard triangulation language (STL) file. This data allows the precise transfer of the implant's position, depth, and angulation into the design software. Intraoral scan bodies (ISBs) are typically made from metal alloys, polymer materials like PEEK, or a combination of both (hybrid ISBs). They vary in geometrical features, design, size, and surface properties. An ISB generally comprises three regions: the base (most apical area), the body (middle region), and the scan region (upper part). Compared to laboratory scan bodies, intraoral scan bodies are smaller to fit the oral cavity and are hand-torqued onto the implant. Some scan bodies feature a retaining screw or a press-fit fixation (17,18).



Picture 4. Intraoral scan body

Taken with permission of prof. dr. sc. Marko Jakovac

### **3.5. Prosthetic design and fitting**

Dental prosthetic design components include a wide variety of aspects associated with the design of dental prostheses. Some of these determining factors are the prosthesis's overall geometry, crown, abutment designs and material choices. They are crucial for implant restorations' functional and aesthetic success and significantly impact peri-implant health.

Occlusal forces are vital for the efficacy of dental implant operations. These forces must be distributed properly on the crown. Inadequately constructed crowns that do not equally transmit

forces might result in high-stress concentrations at certain sites where the implant contacts the bone. These forces may affect adjacent bone and soft tissues, raising the possibility of peri-implant problems. Platform switching is one technique for reducing force-related difficulties, which includes using an abutment with a smaller diameter than the implant fixture. This results in a horizontal discrepancy between the abutment and the implant, which helps to disperse occlusal forces more evenly. A well-constructed crown with platform switching can assure that occlusal forces are transmitted equally over the implant site, lowering the risk of complications. The success of dental implant treatments is dependent on implementing platform switching. Another important consideration in crown design is the emergence profile, which describes how the crown arises from the soft tissue (19).

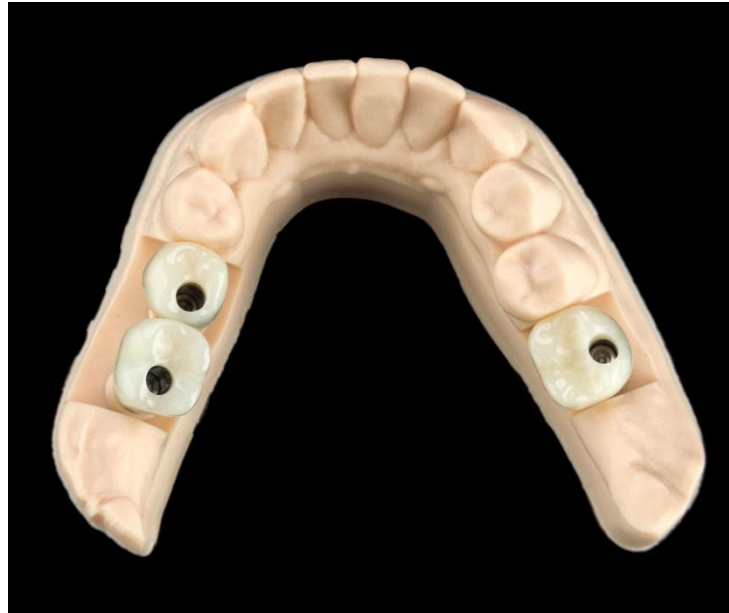Healthy soft tissue shapes and effortless oral hygiene should be supported by an ideal emergence profile. Inadequate emergence profiles can make it difficult to maintain adequate oral hygiene by trapping food and allowing bacteria to colonize. This can cause inflammation and infection, leading to peri-implant mucositis and peri-implantitis. The crown-to-implant ratio also influences peri-implant health. Uneven force distribution can result from a difference in this ratio, particularly if the crown height is too high. This may lead to mechanical problems and greater stress on the implant-bone interface, accelerating loss of bone and peri-implant disease. The abutment's design has a direct impact on the soft tissue shapes surrounding it. The goal of abutments should be to encourage the development of healthy soft tissue surrounding the implant. Soft tissue recession may result from an abutment design that does not encourage optimal soft tissue shapes. Dental practitioners hope to reduce debris retention and promote effective self-care for patients by producing smooth and well-shaped prosthetic components. These design options help to keep the area surrounding the implant healthy and prevent the development of peri-implant disease. As a result, a stable environment is created for implant-supported restorations to succeed over the long term (19, 20).

There are several types of dental implant crowns (Picture 5.). Metal ceramic restorations combine a metal alloy base with a ceramic exterior, providing strength and durability for chewing. However, a thin metal line may be visible at the gumline. Zirconia crowns, solid and white throughout, avoid visible metal and are dense, smooth, and highly resistant to cracking and staining. A translucent zirconia glaze can enhance the natural look of front teeth, and its non-reactivity with metals

minimizes allergic reactions. Lithium disilicate glass-ceramic restorations offer a natural appearance. Still, they are about half as strong as zirconia, making them unsuitable for those with strong bites due to their potential to crack. Acrylic and composite resin materials are used for temporary crowns. At the same time, they can mimic natural teeth, but they are prone to cracking, chipping, and staining and lack the strength and durability of metal-ceramic restorations or zirconia, rendering them unsuitable for long-term use (20).

Using a digital protocol makes it easier to start with polymer materials before working with ceramics. Initial tests can be done with materials like PMMA to avoid costly adjustments later. The process involves trying a provisional restoration to check fit, contacts, retention, and occlusion, but not final aesthetics. If the provisional is satisfactory, the design can be adjusted in CAD and milled into the final material. All scans (initial, wax-up, and working models) must be aligned in the same coordinate system to ensure accurate design transfer. This can be done by rescanning prepared teeth or overlapping digital models in CAD software. Accurate scanning is crucial, capturing as much detail as possible to ensure precise model alignment and minimal distortions. The CAD design process includes final checks for occlusion and functional movements. The CAM program then optimizes milling strategies for the best results. For in-office milling, integrated CAD/CAM systems are preferred for ease, while laboratory milling requires flexible CAM programs for customization. Materials for final milling depend on the prosthetic work. For aesthetic restorations, glass ceramics are used, while zirconia is used for more significant works like bridges. The monolithic work is tried primarily for aesthetics, ensuring consistency with the provisional. Any necessary adjustments are made in CAM to avoid altering the CAD design. During milling, choosing the correct strategy and machine settings is vital. For example, milling in 3+2 axes is more precise than 5-axis simultaneous milling, but the latter provides better detail in complex areas. Advanced CAM programs can switch between these strategies for optimal results. After milling, the final restoration undergoes aesthetic adjustments like staining and glazing. A crystallization process is needed post-grinding for materials like lithium disilicate to achieve the final color and strength. Zirconia restorations, which are milled larger due to shrinkage during sintering, are also stained and glazed for a natural appearance. Using digital protocols with intermediate PMMA trials ensures higher accuracy and efficiency, reducing the costly remakes and adjustments in the final ceramic work (21).





Picture 5. Dental implant crown

Taken with permission of prof. dr. sc. Marko Jakovac

### **3.6 Post-operative Care and Follow-up**

Patient compliance is essential for the long-term success of oral rehabilitation, and clinicians should actively engage with this issue rather than viewing non-compliant patients as problematic. Four key factors must be considered: First, understanding the patient's lifestyle is crucial, as behavioral changes that do not correspond to their social environment are unlikely to be successful. Using various techniques to change attitudes and improve compliance, such as setting small, incremental goals rather than expecting immediate results, is beneficial. Second, every member of the treatment team should prioritize oral hygiene instruction and prosthesis maintenance education, reinforcing this by formally incorporating these activities into the treatment plan and maintenance phase and allocating enough time and effort during routine recall appointments to ensure oral health, prosthesis longevity, and patient satisfaction. Third, evidence suggests that patients actively involved in treatment planning are more likely to comply, whereas

a paternalistic approach results in poorer compliance. Fourth, the relationship between the practitioner and the patient significantly increases compliance.

Additionally, the patient's personality plays a critical role, with accepting and resigned patients more likely to comply and indifferent or ambivalent patients showing moderate compliance. Sceptic patients are not being challenged to engage due to their disbelief in the practitioner's advice. Identifying skeptical patients during the initial interview and treatment planning phase is important (22).

Complications in implant prosthetic work include peri-implant mucositis and peri-implantitis, both of which can impact the success of dental implants.

Peri-implant mucositis is an inflammatory condition that can be cured and affects the soft tissues around dental implants. Pus suppuration is the most certain sign, and it affects about 60% of implant patients. Other symptoms include redness, swelling, bleeding on probing, and sensitivity. It typically results from subgingival cement remnants and poor oral hygiene, and treatment entails the elimination of irritants, professional plaque removal, and strengthened at-home care. Peri-implantitis, a more severe condition, affects both soft and hard tissues, leading to marginal bone loss and potential implant failure, affecting about 20% of implant patients. Diagnosis involves symptoms like bleeding on probing, suppuration, pocket deepening, and progressive bone loss confirmed by radiographs. Causes include subgingival cement remnants, occlusal overload, and untreated peri-implant mucositis. Treatment ranges from decontamination methods such as saline rinsing and mechanical debridement to surgery in severe cases, with advanced bone loss potentially necessitating implant replacement (23).

Aesthetic complications in implant prosthetic work can arise from dissatisfaction with multiple aspects of the prosthesis, such as tooth position, angulation, form, color, texture, feel, and the appearance of soft tissues or the emergence profile of artificial teeth. The initial patient reaction to a new prosthesis is critical, as disappointment can be difficult to overcome, so careful treatment planning and the use of temporary prostheses are essential for matching expectations to reality. If the initial dissatisfaction is limited, patients may be advised to wear the prosthesis for a few days or weeks to allow time for adjustment. When modifications are needed, the clinician must decide whether minor intra-oral adjustments are sufficient or if the prosthesis requires retrieval for more extensive changes. In severe cases where modifications are impossible or would compromise the

prosthesis's integrity, a new prosthesis with a revised design may be necessary. Balancing the patient's desire for a fixed prosthesis with esthetic and oral hygiene considerations is important, as removable prostheses can often better meet esthetic demands, especially when simulating soft tissues (22).

If the patient has no complaints, they are scheduled for a maintenance visit three months post-insertion. A standardized radiograph is taken (if not already done at the one-month mark) to assess bone levels during this visit. Oral hygiene is evaluated, and instruction is given if necessary. The patient's occlusion is measured and adjusted as needed. The soft tissue's texture, color, and amount of keratinized tissue are also examined. This maintenance routine is reviewed every six months and then annually for the first three years. Regular monitoring and early intervention help prevent minor implant complications from becoming serious or irreversible (22, 23).

#### **4. DISCUSSION**



The shift from analog to digital protocols in implant prosthetic work has completely transformed dental practices, offering different advantages and challenges in several process aspects, including planning, time efficiency, accuracy, and impressions. Digital protocols use Cone Beam Computed Tomography (CBCT) and computer-aided design/manufacturing (CAD/CAM) to generate precise three-dimensional images of the patient's jaw.

This enables detailed preoperative planning, allowing for accurate assessment of bone structure and optimal implant placement. Analog protocols, on the other hand, rely on two-dimensional radiographs and physical models from impressions, which can be less precise and more time-consuming in planning. Digital protocols streamline the workflow by reducing the number of patient visits and the time required for each procedure. Digital impressions can be taken quickly and sent directly to the lab, shortening the turnaround time. Analog methods, on the other hand, involve multiple steps, including taking physical impressions, pouring stone models, and manually crafting the prosthesis, which can be time intensive.

Digital impressions involve scanning the patient's mouth using intraoral scanners, which are non-invasive and more comfortable for the patient. Traditional analog impressions, however, affect the use of impression trays and materials, causing discomfort and requiring additional time for setting and manual processing.

An in vitro study compared the accuracy of conventional versus digital impression techniques for angulated and straight implants using two different impressions coping and scan body designs. Conventional impressions were taken using the splinted open-tray technique with narrow impression coping (NIC) and wide impression coping (WIC). These stone casts were digitized with a lab scanner (3Shape D2000). Digital impressions were made using four intraoral scanners (IOS): 3Shape Trios 3, Medit i700, Cerec Omnicam, and Emerald Planmeca, employing short scan bodies (SSB) and long scan bodies (LSB). The study found that the trueness and precision of SSB and WIC were significantly better than those of LSB and NIC ( $p < 0.001$ ). The precision of the platform deviation of digital scans with SSB (12.4 to 34.5  $\mu\text{m}$ ) was higher than that of other scans and conventional impressions (42.9 to 71.4  $\mu\text{m}$ ). The Medit i700 and Trios 3 angle deviation precision with SSB (0.17 and 0.20 degrees, respectively) was higher than other scans with SSB and conventional impressions (0.54 to 1.63 degrees) (24).

These findings highlight that digital scans with SSB are more accurate than conventional splinted open-tray impressions. The type of impression coping and scan body significantly affect the impression accuracy.

Digital protocols also excel in accuracy. CBCT and CAD/CAM technologies ensure high precision in implant placement, reducing the risks of complications such as nerve damage and improper positioning.

In light of the fast and increasingly accurate progress in dental prosthodontics, practitioners can simplify their daily work. These technologies aim to progressively substitute conventional techniques, though their real efficiency and predictability remain under debate. A three-arm clinical randomized controlled trial (RCT) compared fully digital, combined digital and analog, and fully analog workflows. The study aimed to compare the clinical properties of each workflow regarding interproximal (IC) and occlusal contact (OC), marginal fit, impression time (IT), and patient satisfaction through a Visual Analog Scale (VAS). Seventy-two patients participated in the study. Results indicated that the IC and OC of the digital workflow were superior to the others ( $p < 0.001$ ), which obtained similar results. No notable difference was observed in implant-abutment fit ( $p = 0.5966$ ). The IT was shorter in the digital workflow than the others ( $p < 0.001$ ), which were similar. Patient satisfaction was higher in the digital workflow compared to the conventional one (25).

Despite the limitations, this study indicates that the digital workflow offers better accuracy and patient tolerance than conventional techniques, suggesting it is a useful alternative when performed by clinicians experienced in digital dentistry.

Although there are clear advantages, transitioning to digital protocols involves significant initial costs for acquiring advanced imaging systems, CAD/CAM machines, and training dental professionals. Smaller practices may find these costs unsustainable. Analog protocols, while less costly initially, can be more labor-intensive and time-consuming in the long run.

The future of implant prosthetic work will likely see further advancements in digital technology. Artificial intelligence (AI) and augmented reality (AR) are poised to enhance diagnostics, treatment planning, and surgical precision. AI can assist in predictive analytics and decision-making, while AR can provide real-time guidance during surgical procedures.

The study underscores the crucial role that artificial intelligence (AI) plays in enhancing the accuracy, efficiency, and consistency of anatomical landmark segmentation, which is fundamental for virtual patient creation in presurgical dental implant planning. Despite the promising capabilities of AI, investigation reveals that the current array of implant planning software demonstrates varying levels of automation, with only six out of twelve commonly available applications incorporating at least one fully automated step. The evaluated software solutions must provide a fully automated implant planning protocol. These results highlight a significant gap in the complete automation of the implant planning process, which has yet to be scientifically validated. While AI-driven tools show considerable potential for improving presurgical implant planning workflows, their complete integration and automation still need to be realized. This study provides clinicians with critical insights into the current state of AI-based automation in dental implant planning. It underscores the necessity for further research to validate and fully implement these technologies in clinical practice (26).

Both digital and analog protocols have their merits in implant prosthetic work. Digital protocols excel in planning efficiency, patient comfort, and streamlined workflows, making them ideal for straightforward cases and single implants. Analog protocols, however, continue to offer superior accuracy for complex, long-span procedures, maintaining their relevance in comprehensive prosthetic work. Integrating both approaches, leveraging the strengths of each, may provide the most effective outcomes in dental implantology.

## **5. CONCLUSION**





The advancements in digital dentistry have revolutionized dentistry, particularly in the field of implant prosthetics. This thesis has explored the transition from traditional methods to a comprehensive digital protocol, emphasizing the incorporation of technologies such as 3D imaging, CAD/CAM systems, and computer-guided surgery. These innovations have improved accuracy, efficiency, and patient outcomes. Key findings highlight the important advantages of digital workflows, including enhanced precision in implant placement and prosthetic fitting, reduced treatment times, and improved patient comfort. Despite the initial costs and learning time associated with adopting digital technologies, the long-term advantages for both dental professionals and patients are convincing. The proposed digital protocol aims to streamline the entire process of implant prosthetics, from initial consultation to post-operative care. By using the latest technological advancements, this protocol not only addresses the current limitations of conventional methods but also sets a foundation for future developments in digital dentistry.

The integration of artificial intelligence and augmented reality further promises to enhance the precision and personalization of dental treatments. In conclusion, the adoption of digital protocols in implant prosthetics represents a huge step forward in modern dentistry. It offers a path towards a more predictable, efficient, and patient-centered care, ultimately raising the standards and outcomes of dental treatments.



1. Velasco-Ortega E, Del Rocío Jiménez-Martin I, Moreno-Muñoz J, Núñez-Márquez E, Rondón-Romero JL, Cabanillas-Balsera D, et al. Long-Term treatment outcomes of implant prostheses in partially and totally edentulous patients. *Materials (Basel)*. 2022 Jul 14;15(14):4910. Available from: <https://www.ncbi.nlm.nih.gov/pmc/articles/PMC9316310/>
2. Almusallam SM, AlRafee MA. The prevalence of partial edentulism and complete edentulism among adults and above population of Riyadh city in Saudi Arabia. *J Family Med Prim Care*. 2020 Jan 1;9(4):1868. Available from: <https://www.ncbi.nlm.nih.gov/pmc/articles/PMC7346903/>
3. Pita MS, Anchieta RB, Barão VAR, Garcia IR, Pedrazzi V, Assunção WG. Prosthetic platforms in implant dentistry. *the J Craniofac Surg*. 2011 Nov 1;22(6):2327–31. Available from: <https://pubmed.ncbi.nlm.nih.gov/22134269/>
4. Haidar ZS. Digital Dentistry: past, present, and future. *Digital Medicine and Healthcare Technology*. 2023 Jun 6;2. Available from: [https://www.researchgate.net/publication/371725459\\_Digital\\_Dentistry\\_Past\\_Present\\_and\\_Future](https://www.researchgate.net/publication/371725459_Digital_Dentistry_Past_Present_and_Future)
5. Today D. The evolution of digital dentistry and the digital dental team [Internet]. *Dent Today*. 2008. Available from: <https://www.dentistrytoday.com/sp-1323704604/>
6. Mörmann WH. The evolution of the CEREC system. *J Am Dent Assoc*. 2006 Sep 1;137:7S–13S.
7. Gowd MS, Shankar T, Ranjan R, Singh A. Prosthetic consideration in implant-supported prosthesis: A review of literature. *J Int Soc Prev Community Dent*. 2017 Jan 1;7(7):1. Available from: <https://www.ncbi.nlm.nih.gov/pmc/articles/PMC5502545/>
8. Kernen F, Kramer J, Wanner L, Wismeijer D, Nelson K, Flügge T. A review of virtual planning software for guided implant surgery - data import and visualization, drill guide design and manufacturing [Internet]. *BMC Oral Health*. 2020 [cited 2024 Jun 4]. Available from: <https://pubmed.ncbi.nlm.nih.gov/32912273/>
9. Flügge T, Kramer J, Nelson K, Nahles S, Kernen F. Digital implantology—a review of virtual planning software for guided implant surgery. Part II: Prosthetic set-up and virtual implant planning. *BMC Oral Health [Internet]*. 2022 Jan 30;22(1). Available from:

[https://www.researchgate.net/publication/358232277\\_Digital\\_implantology-a\\_review\\_of\\_virtual\\_planning\\_software\\_for\\_guided\\_implant\\_surgery\\_Part\\_II\\_Prosthetic\\_setup\\_and\\_virtual\\_implant\\_planning](https://www.researchgate.net/publication/358232277_Digital_implantology-a_review_of_virtual_planning_software_for_guided_implant_surgery_Part_II_Prosthetic_setup_and_virtual_implant_planning)

10. Nasti S, Anjum S, Kalekhan SM, Ashok A, Bumb PP, Puthenkandathil R. Surgical guides: Precision redefined in implant placement. *IP Int J Perio and Implant*. 2023 Dec 15;8(4):177–80. Available from:

[https://www.researchgate.net/publication/376551727\\_Surgical\\_guides\\_Precision\\_redefined\\_in\\_implant\\_placement](https://www.researchgate.net/publication/376551727_Surgical_guides_Precision_redefined_in_implant_placement)

11. Ramasamy M, Giri, Raja R, Subramonian, Karthik, Narendrakumar R. Implant surgical guides: From the past to the present. *J Pharm Bioallied Sci*. 2013 Jan 1;5(5):98. Available from: <https://www.ncbi.nlm.nih.gov/pmc/articles/PMC3722716/>

12. Donker VJJ, Heijs KH, Pol CWP, Meijer HJA. Digital versus conventional surgical guide fabrication: A randomized crossover study on operator preference, difficulty, effectiveness, and operating time. *Clin Exp Dent Res*. 2024 Jan 18;10(1). Available from: <https://www.ncbi.nlm.nih.gov/pmc/articles/PMC10807550/>

13. Mann N. How to make a surgical guide for dental implants - Oceanic Dental [Internet]. Oceanic Dental. 2024 [cited 2024 Jun 6]. Available from: <https://oceanicdental.au/how-to-make-a-surgical-guide-for-dental-implants/>

14. D'Souza KM, Aras MA. Types of Implant Surgical Guides in Dentistry: A review. *J Oral Implantol*. 2012 Oct 20;38(5):643–52. Available from: <https://meridian.allenpress.com/joi/article/38/5/643/7159/Types-of-Implant-Surgical-Guides-in-Dentistry-A>

15. Cdt BC, Cap IPB. Step-by-step: how to digitally plan implants and design surgical guides [Internet]. Dental Products Report. 2016 [cited 2024 Jun 7]. Available from: <https://www.dentalproductsreport.com/view/step-step-how-digitally-plan-implants-and-design-surgical-guides>

16. Zhang T, Yang B, Ge R, Zhang C, Zhang H, Wang Y. Effect of a novel ‘Scan body’ on the in vitro scanning accuracy of Full-Arch implant impressions. *Int Dent J*. 2024 Feb 1; Available from: <https://www.sciencedirect.com/science/article/pii/S002065392400039X>
17. Marques S, Ribeiro P, Falcão C, Lemos BF, Ríos-Carrasco B, Ríos-Santos JV, et al. Digital Impressions in Implant Dentistry: A Literature review. *Int J Environ Res Public Health*. 2021 Jan 24;18(3):1020. Available from: <https://www.ncbi.nlm.nih.gov/pmc/articles/PMC7908474/>
18. Pachiou A, Zervou E, Tsirogiannis P, Sykaras N, Tortopidis D, Kourtis S. Characteristics of intraoral scan bodies and their influence on impression accuracy: A systematic review. *J Esthet Restor Dent*. 2023 Jun 28;35(8):1205–17. Available from: <https://pubmed.ncbi.nlm.nih.gov/37381677/>
19. Chankhore P, Khubchandani SR, Reche A, Paul P. Prosthetic Design Factors Influencing Peri-Implant Disease: A Comprehensive review. *Curēus* [Internet]. 2023 Nov 13; Available from: [https://www.researchgate.net/publication/375602772\\_Prosthetic\\_Design\\_Factors\\_Influencing\\_Peri-Implant\\_Disease\\_A\\_Comprehensive\\_Review](https://www.researchgate.net/publication/375602772_Prosthetic_Design_Factors_Influencing_Peri-Implant_Disease_A_Comprehensive_Review)
20. Argenti H. What are dental implant crowns made of? [Internet]. *Cleveland Implant*. 2022 [cited 2024 Jun 8]. Available from: <https://clevelandimplant.com/dental-implant-blog/what-are-dental-implant-crowns-made-of/>
21. Jakovac M. *Protokol*. Zagreb: Stega tisak; 2023. 720p.
22. Patient Compliance/recall | FOR.org. [cited 2024 Jun 10]. Available from: [https://www.for.org/en/treat/treatment-guidelines/edentulous/aftercare/post-treatment-complications-and-management/patient-compliancerecall?active\\_tid=468](https://www.for.org/en/treat/treatment-guidelines/edentulous/aftercare/post-treatment-complications-and-management/patient-compliancerecall?active_tid=468)
23. A protocol for follow-up visits post-implant placement. *Perio Implant Advisory*. 2012 [cited 2024 Jun 10]. Available from: <https://www.perioimplantadvisory.com/clinical-tips/periodontal-complications/article/16412188/a-protocol-for-follow-up-visits-post-implant-placement>
24. Alkindi S, Hamdoon Z, Aziz AM. Effect of different impression coping and scan body designs on the accuracy of conventional versus digital implant impressions: An in vitro study. *J Dent*. 2024 May 1;105045. Available from: <https://pubmed.ncbi.nlm.nih.gov/38714241>

25. Corsalini M, Barile G, Ranieri F, Morea E, Corsalini T, Capodiferro S, et al. Comparison between Conventional and Digital Workflow in Implant Prosthetic Rehabilitation: A Randomized Controlled Trial. *J Funct Biomater*. 2024 May 31;15(6):149. Available from: [https://www.researchgate.net/publication/381062688\\_Comparison\\_between\\_Conventional\\_and\\_Digital\\_Workflow\\_in\\_Implant\\_Prosthetic\\_Rehabilitation\\_A\\_Randomized\\_Controlled\\_Trial](https://www.researchgate.net/publication/381062688_Comparison_between_Conventional_and_Digital_Workflow_in_Implant_Prosthetic_Rehabilitation_A_Randomized_Controlled_Trial)
26. Elgarba BM, Fontenele RC, Tarce M, Jacobs R. Artificial intelligence serving pre-surgical digital implant planning: A scoping review. *J Dent*. 2024 Feb 1;104862. Available from: <https://pubmed.ncbi.nlm.nih.gov/38336018/>

## **7.BIOGRAPHY**



Frano Tarle was born on April 3rd, 2000, in Zagreb, where he finished elementary school “Josip Juraj Strossmayer” and secondary education in Classical Gymnasium. In 2018, he enrolled in the School of Dental Medicine, University of Zagreb. During his studies he assisted in a private dental clinic.

In 2022 he participated at congress “Sinergija znanosti i kliničkog rada” with the project “Crosslinking density of experimental dental composites with copper-doped mesoporous bioactive nanospheres”.