

Relapse after orthodontic treatment

Jelić, Iva

Master's thesis / Diplomski rad

2024

Degree Grantor / Ustanova koja je dodijelila akademski / stručni stupanj: **University of Zagreb, School of Dental Medicine / Sveučilište u Zagrebu, Stomatološki fakultet**

Permanent link / Trajna poveznica: <https://um.nsk.hr/um:nbn:hr:127:408277>

Rights / Prava: [In copyright](#) / [Zaštićeno autorskim pravom.](#)

Download date / Datum preuzimanja: **2025-03-14**



Repository / Repozitorij:

[University of Zagreb School of Dental Medicine
Repository](#)





University of Zagreb
School of Dental Medicine

Iva Jelić

RELAPSE AFTER ORTHODONTIC TREATMENT

GRADUATE THESIS

Zagreb, 2024.

The work was carried out at: Department of Orthodontics, School of Dental Medicine, University of Zagreb.

Thesis mentor: prof.dr.sc. Sandra Anić Milošević, Department of Orthodontics, School of Dental Medicine, University of Zagreb.

English language proofreader: Anđela Kraljević, Professor of English Language

Croatian language proofreader: Zoran Priselac, Professor of Croatian Language and Literature

Thesis contains: __28__pages
 __0__tables
 __3__pictures

The work is the author's own work, which is completely independently written with an indication of the sources of other authors and documents used in the work. Unless it isn't otherwise stated, all illustrations (tables, pictures, etc.) in the paper are the original contribution of the post-graduate author specialist work. The author is responsible for obtaining permission to use illustrations that are not his original contribution, as well as for all possible consequences that may arise due to the illegality downloading of illustrations, i.e. failure to state their origin.

I would like to dedicate this thesis to my parents; Mislav and Mateja, my brother Petar, my grandparents and Rita. Thank you for your support, guidance and love throughout my life. I am forever grateful to have you as my role models.

I am eternally grateful to have my best friends Ana, Mila, Megi and Lucija on this journey right beside me. Thank you for your kindness, encouragement and patience for the past fifteen years.

Last but not least, I would like to thank my „Sekići“. Without you I wouldn't have been able to pull it through these past six years. A big thank you for all the memories, laughs, the ups and downs and everything we've been through.

Thank you for believing in me, I am very blessed to have you.

I completed this thesis with the guidance of my mentor prof.dr.sc. Sandra Anić Milošević. I am incredibly grateful for your help and guidance throughout my education.

„Our greatest glory is not in never falling, but in rising every time we fall“ - Confucius

RELAPSE AFTER ORTHODONTIC TREATMENT

Summary

After the orthodontic treatment teeth are in a very unstable position and are prone to return to their primary occlusion. This occurrence is called relapse and is one of the biggest problems in orthodontics. As a multifactorial cause, which can happen due to the changes of the periodontal ligament, occlusion adjustments, and soft tissue forces, the real cause of relapse is yet to be defined. To prevent this movement, different retention methods have been clinically conducted in the form of fixed and removable retention. Fixed retention in the form of metal wires which are bonded to the anterior teeth on the lingual or palatal side. As for removable retentive appliances, the patient is the one who manages the appliance. It is crucial to inform patients about relapse and its prevention. Relapse is unpredictable so it is important to treat every patient as if they were at a high risk of relapse.

Key words: relapse, retention, orthodontics, orthodontic treatment

RECIDIV NAKON ORTODONTSKE TERAPIJE

Sažetak

Nakon ortodontske terapije zubi se nalaze u vrlo nestabilnom položaju te su skloni vraćanju u primarnu okluziju. Ova pojava naziva se recidiv i jedan je od najvećih problema u ortodontiji. Smatra se da je recidiv uzrokovan raznim čimbenicima kao što su promjena periodontalnog ligamenta, prilagodba okluzije i sile mekih tkiva. Kako bi se spriječio recidiv, potrebno je primijeniti fiksne i mobilne metode retencije. Fiksna retencija dolazi u obliku metalne žice koja se kompozitom povezuje na lingualni ili palatinalni dio anteriornog segmenta gornje ili donje čeljusti. Kod mobilnih retencijskih naprava bitno je upozoriti pacijenta na rizik od recidiva jer je pacijentova suradnja ključna. S obzirom na nepredvidljivost recidiva, svakog bi se pacijenta trebalo liječiti kao da postoji visoki rizik već spomenutog recidiva.

Ključne riječi: recidiv, retencija, ortodontcija, ortodontska terapija

TABLE OF CONTENTS

| | |
|---|-----------|
| <i>1. INTRODUCTION</i> | <i>1</i> |
| <i>2. RELAPSE</i> | <i>4</i> |
| <i>3. RETENTION</i> | <i>9</i> |
| 3.1. Fixed retention..... | 10 |
| 3.2. Removable retention | 13 |
| 3.3. Additional retention methods | 16 |
| 3.4. Retentive period..... | 17 |
| <i>4. DISCUSSION</i> | <i>18</i> |
| <i>5. CONCLUSION</i> | <i>22</i> |
| <i>6. LITERATURE</i> | <i>24</i> |
| <i>7. BIOGRAPHY</i> | <i>27</i> |

Abbreviations

PDL- periodontal ligament

OTM- orthodontic tooth movement

IPR- interproximal reduction

1.INTRODUCTION

Orthodontics is a specialty field in dentistry which is focused on correcting malocclusions, intermaxillar and dentoalveolar deformities. Incorrect teeth position and orthodontic anomalies can be the source of many problems; unpleasant esthetic components, disorders of some oral functions such as biting, swallowing or chewing and increased caries, trauma and periodontal disease tendency.

Orthodontic treatment usually begins in childhood with removable appliances and can continue into adulthood in the form of fixed orthodontic appliances or aligners. Fixed orthodontic treatment consists of brackets which are bonded to the teeth and removable metal wires which are changed by the orthodontist every four to six weeks. Removable orthodontic treatment is performed by removable monomaxilar or bimaxilar appliances which are usually patient managed.

Based on the malocclusion, functional or aesthetic problem, treatment can last up to several months or up to a few years. In that period teeth go through different phases of movement. Orthodontic tooth movement (OTM) is a mechanically induced process used to treat malocclusion, misalignment, or incorrect relation between the teeth of the two dental arches (1). In orthodontic treatment, tooth movement is the key factor in achieving correct teeth alignment. Both biological and biomechanical systems are essential in regulating the pace of tooth movement, influencing whether it accelerates or decelerates (2). When a tooth undergoes mechanical loading, it experiences both tension and compression (3). Bone resorption takes place on the compression side, meantime bone formation occurs on the tension side. After the orthodontic treatment runs its course, a new bone and occlusion are formed.

This doesn't conclude the treatment nor stabilizes the newly formed occlusion, it only marks the beginning of the next treatment phase which is retention. This phase is very important because it is the key factor for relapse prevention, which brings the teeth to its original maloccluding position. It can undermine the long-term success of orthodontic treatment and diminish patient satisfaction, making it a critical area of focus in orthodontic research and clinical practice. The prevalence of relapse varies widely depending on different factors, such as the type of malocclusion, treatment modalities, and patient compliance with retention protocols. The etiology is multifactorial, including biological, mechanical, and behavioral components. The implications of relapse extend beyond aesthetic concerns.

Relapse can lead to functional problems such as improper bite, difficulty in swallowing, chewing and talking. Understanding the predictors of relapse and developing effective strategies to prevent it are paramount for enhancing the long-term success of orthodontic treatment. By understanding the etiology, causes and clinical experience with ongoing research, orthodontists can develop more effective strategies to minimize relapse and ensure the maintenance of the desired outcome. Orthodontic relapse is the major issue in modern orthodontics and its prevention is what makes the orthodontic treatment successful.

The general aim of this review thesis is to present relapse after orthodontic treatment and the possibilities of its prevention and the possibilities of rightful and successful retention.

2. RELAPSE

To keep a good and functional orthodontic treatment outcome, a stable occlusion and tooth position must be ensured, and sometimes even overcorrected. The achievement of aesthetic and, functional occlusion should not mark the end of the orthodontic intervention (4). The succession rate of orthodontic treatment can be expressed by the relationship between the progress achieved by treatment and the severity of post treatment relapse. One of the major issues in orthodontics is relapse of the primary issues after treatment. Relapse refers to the loss of stability of orthodontic outcome and describes the tendency of teeth to revert to their original position before treatment (5).

After years of thorough work and research, Riedel published the rules which explain the origin of relapse (6):

- Teeth which have been moved tend to return to their original position because of the occlusal relations between the upper and lower jaw and the disharmonious growth post orthodontic treatment.
- Eliminating the cause of malocclusion.
- Hypercorrection of malocclusion as the safety factor for relapse.
- Stabilization of occlusion is an important factor in maintaining teeth in the correct position. In the therapy of sagittal interjaw relations, it is necessary to establish a strong tuberculofissure intercuspidation.
- Bone and soft tissue should be given time to reorganize around the teeth in the new position.
- Incisors placed perpendicular to the base of the mandible reduce the risk of relapse.
- Corrections made during growth and development are less prone to relapse.
- The longer is the orthodontic tooth movement, the smaller the chance of relapse.
- Shape of the mandibular arch can't be changed by orthodontic treatment.
- Some therapeutically treated anomalies require life-long retention.

Based on its characteristics, relapse can be partial or complete, and in terms of extent it can involve one or more structures. For example, the relapse of tooth rotations covers only dental structures, class II relapse includes dentoalveolar structures, and mandibular prognathism relapse consists of only skeletal structures.

The etiology of relapse is multifactorial and it includes the periodontal ligament (PDL), gingiva, occlusal factors, soft tissue pressure and skeletal growth. PDL and gingiva go under remodeling as they adjust to new tooth positions so this process is gradual and incomplete. Until these tissues have stabilized, they have a tendency to manipulate their way back to the original position. The elastic fibers, dento-gingival and interdental fibers take the longest to adjust to their new position, sometimes up to 8 months (7). This can be seen after corrections of rotated teeth and closure of extraction spaces. Teeth that have the greatest tendency to relapse are lower lateral incisors, canines and second premolars. Therefore, the teeth need to be held in the newly adapted position long enough for the fibers to adapt.

The muscles of mastication and facial muscles adapt to the new tooth formation during treatment. Sometimes these muscles may exert forces that drive the teeth back to their primary position once the treatment is complete. It is recommended to position the teeth within a zone of soft tissue equilibrium, balancing the forces exerted by the tongue from the lingual side and the cheeks from the labial side. This way each tooth is located in the „neural zone“ where equal forces are provided from every side. The further the teeth are from this zone, the more unstable they are. This way we could try and prevent relapse by ensuring a neural zone stability. This is very important when it comes to mandibular incisors, if they are very proclined or retroclined, there is a higher chance of relapse. In younger patients it is easier for the muscular system to adapt, so the possibility of relapse is moderate. This rule doesn't apply if there is a lingual or labial parafunction. In case of a speech, airway parafunction or a bad habit it is necessary to correct it. Tongue protrusion, lip biting, thumb sucking or open mouth breathing can contribute to relapse.

Unstable occlusion with early occlusal contacts causes tooth movement and increases the risk of relapse. With premature occlusal contacts, the patient moves the mandible to a „more stable“ position, and which is incorrect and characterized by an irregular distribution of occlusal forces. An inadequate relationship between the upper and lower incisors clears the way for relapse since there isn't a force which prevents the extrusion of the upper teeth.

As a safe method of relapse prevention, it is crucial to ensure the six keys to normal occlusion (8), which are;

- Molar relationship; the distal surface of the distobuccal cusp of the upper first permanent molar should be in occlusion with the mesial surface of the mesiobuccal cusp of the lower second molar.
- Crown angulation (mesiodistal tip); the gingival part of the long axis of the crown is distal to the incisal part of the axis. The extent of the angulation varies according to the tooth type.
- Crown inclination (labio-lingual and bucco-lingual torque); the incisors are at a sufficient angulation to prevent overeruption. The lingual tip of the upper posterior tip is constant and similar from canine to second premolar and increased in the molars. The lingual tip of the lower posterior teeth increases progressively from the canines to the molar.
- Absence of rotations.
- Tight contacts, no interdental spaces.
- Flat curve of Spee.

It has been shown that the intercanine region, especially the lower, is very sensitive to soft tissue changes (9). The labial and lingual pressure have a significant role on the mandibular anterior segment and should be protected wisely from orthodontic relapse. Natural growth and development, particularly in younger patients whose structures continue to change after treatment bring a high risk of relapse. This can lead to alterations in occlusion and alignment.

The precision of the initial orthodontic plan and treatment plays an important role when it comes to relapse. Improper correction of malocclusion, teeth alignment and interjaw relations also has a role in long-term stability. The prevention of relapse includes several strategies; removable and fixed retentive appliances, duration of retention and patient cooperation. The use of removable and fixed retentive strategies is the primary method for relapse prevention. Both methods will be detailly covered and explained in the upcoming chapters.

The established knowledge of the causes and risks of relapse is the base for prevention improvement. Future preventive ways of relapse are slowly paving their way to the finish line of posttreatment stabilization. In theory, relapse doesn't happen to every single patient, so predicting which patients will experience posttreatment changes is challenging. It is important to approach every patient with the consideration that they may experience relapse, as a result

life-long retention is recommended. The orthodontists role is to explain what is relapse, its nature and how unpredictable it is.

3. RETENTION

Establishing a newly formed tooth formation results in unsteady periodontal fibers and not fully adapted bone. In this phase, teeth tend to return to their initial status. This stabilization period allows the reorganization of periodontal fibers, bone remodeling, and adaptation of the neuromuscular system to the new tooth positions.

Before implementing the appropriate retention, the orthodontist must take into account the patient's primary malocclusion, oral habits and hygiene, and the remaining growth that may emerge. Retention can be in the form of a removable appliance, as a fixed metal wire permanently bonded to teeth, or a combination of both. The choice between removable or fixed retention depends on the specific orthodontic correction achieved and patient preferences. Removable Hawley-type appliances, vacuum-formed retainers, bonded wires, and their modifications are most commonly provided (10).

For the retention to be successful it must be applied for a certain period of time. There is an uncertainty on the optimal duration of the length of the retention phase. Research has shown that regeneration of the periodontal apparatus may take up to twelve months to sufficiently support the tooth in its new position (11). Despite advances in treatment methods and retention strategies, maintaining the achieved alignment remains challenging.

3.1. Fixed retention

Nowadays, fixed retention is frequently used after orthodontic treatment. It is a metal wire bonded by flowable composite on the lingual side on the lower jaw, and on the palatal side of the upper jaw. It can be bonded in the upper and lower anterior segments, but it is intentionally excluded in the maxilla because it could disrupt occlusion (4). Its main role is to maintain the posttreatment position of the incisors and canines, preventing rotations, spacings, distemas, and other physiological movement caused by skeletal growth.

The most commonly used type is the flexible stranded wire, which can be cylindrical or flattened (4). It can be made from steel or chromium-containing alloys (4). Fixed retention should be flexible, but not elastic, to allow the physiological movement of the tooth but to still be provide retention and preservation of the PDL. On the other hand, fixed retainers can

sometimes cause undesirable incisor movement. This can occur if the wire is active at bonding, deformed, or overly flexible, potentially deforming the area it covers.

Fixed retainers are used in cases where relapse is unavoidable and extended retention is planned. Here are some indications;

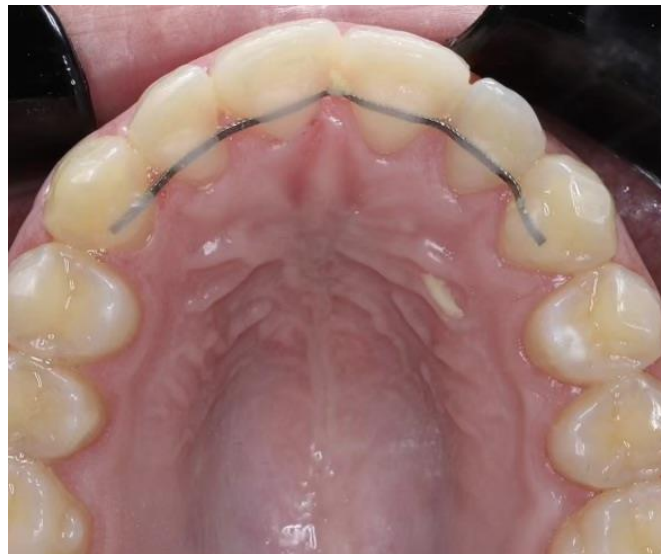- Corrected rotations or in cases where lower incisors have been proclined for more than 2 mm.
- Teeth moved out of the „neural zone“.
- Diastemas or spacing. Particularly in dentoalveolar anterior open bite, diastemas of the upper central incisors, and severely displaced teeth anywhere in the jaw.
- Impacted teeth. Individually extruded teeth, or teeth with no antagonistic tooth are most likely to relapse. In cases like this, a fixed retainer is used along with removable appliances to preserve the transverse relationship.
- Post extraction space holding for prosthesis. A fixed retainer is the best way of holding a space open for any kind of prosthesis such as an implant, crown or bridge.

When comparing all the available fixed retention materials, it seems that the retainer with the metal wire results in lower plaque accumulation, simplified oral hygiene, and may contribute to reduced gingivitis (12). Fixed retention always requires the patient's daily cooperation in the form of upkeeping their oral hygiene with mechanical teeth brushing, using interdental brushes or floss for the available area around the retention or with chemical liquids such as mouthwash. It can be used as a single form of retention or in combination with removable retentive appliances.

Fixed retention procedure

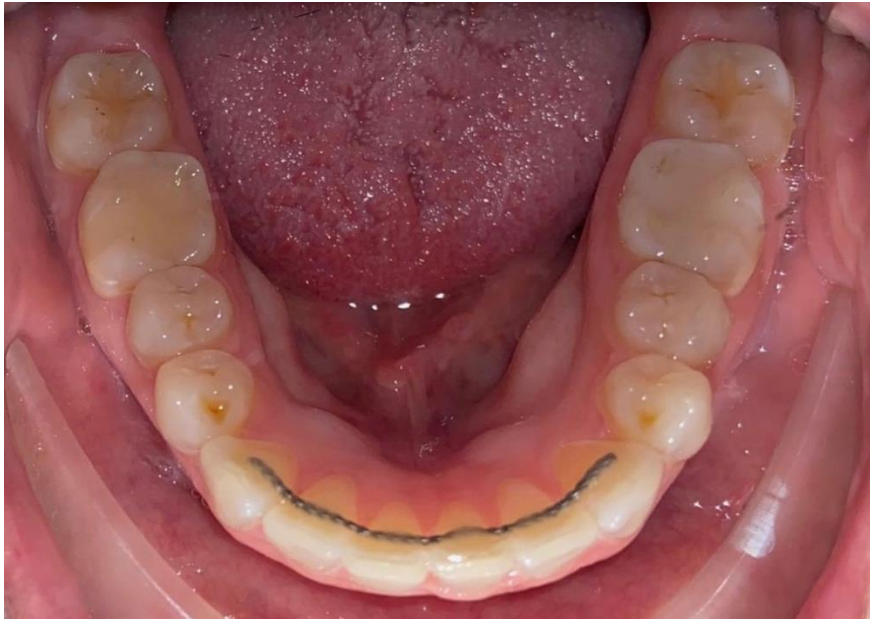
As mentioned, fixed retention comes in a form of a metal wire bonded on the lingual or palatal side of the anterior teeth. The first step is to remove plaque and any caries lesions from the lingual/palatal side where the fixed retention will be placed. Before isolating the teeth, the

metal wire is cut to the corresponding length. Forming a dry working field can be carried out by a rubber dam or cotton rolls with the help of cheek retractors. The process of composite bonding starts with applying phosphoric acid for at least thirty seconds and rinsing it thoroughly with water. Once the surface is dry, a layer of the bonding agent is applied, dried and polymerized. The next step is to bond the wire to the tooth surface with a composite material. In this step it is crucial to press the wire firmly to the surface to ensure a stable connection between the two. While bonding, it is advised to apply composite to each tooth individually and light cure each area for about thirty to sixty seconds. This way the procedure is more precise. The wire can be pressed against the tooth surface by a soft flexible wire or dental floss which are tied interdentally from the opposite side. After the procedure is complete, it is important to check the occlusion and remove any excess material. Polishing as a final step provides a smooth finish and more comfort for the patient.



Picture 1. Fixed retention on the palatal side of the maxillary anterior region.

Taken with permission of prof.dr.sc. Sandra Anić Milošević.



Picture 2. Fixed retention on the lingual side of the mandibular anterior region.

Taken with permission of prof.dr.sc. Sandra Anić Milošević

3.2. Removable retention

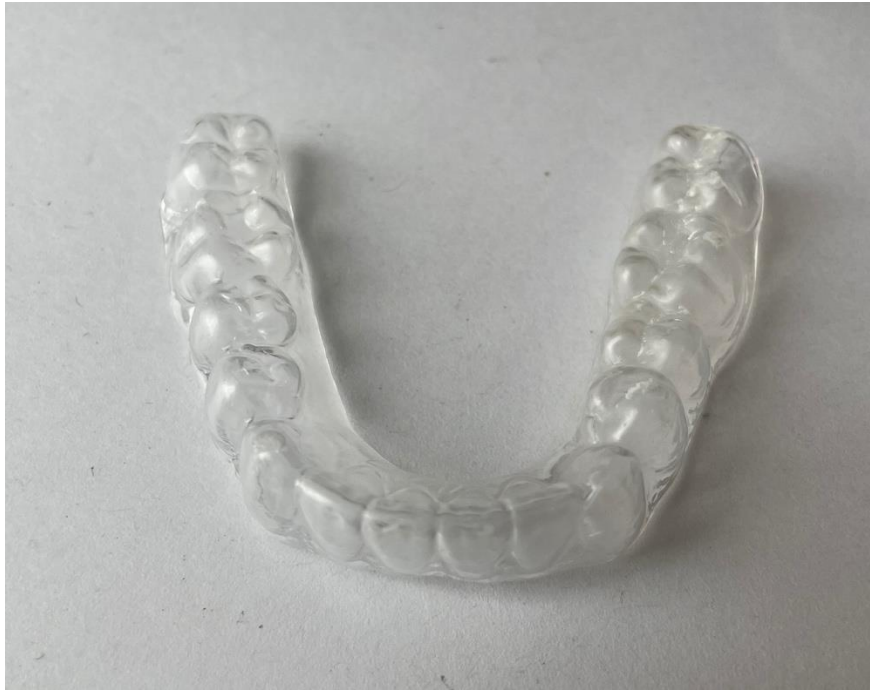Removable retention is commonly used in the retention phase in the form of removable appliances. These appliances cover the entire dental region, unlike fixed retainers that only cover a portion. There are multiple types of removable retention appliances, but nowadays, one of the popular options is the Hawley retainer which is a monomaxilar acrylic appliance consisting of a labial metal archwire, metal clasps and a palatal or lingual acrylic base. The invisible thermoplastic/vacuum-formed (Essix) retainer is the most aesthetically pleasing appliance which is made of thermoplastic sheet. Made from a one millimeter thick sheet of polyethylene terephthalate glycol copolymer, following the manufacturer's instructions, heated in a vacuum machine, shaped and trimmed according to the patient's working cast (13). In some ways they can be more beneficial than fixed retention because they are only worn overnight and the hygiene maintenance is easier but they require patient cooperation and are easily misplaced.

Hawley retainer

Popular for its durability and adjustability, it has been a staple in orthodontics for decades. There are a few modified types, but their main role is to stabilize and maintain the teeth position in all dimensions except vertical. The acrylic plate fits tightly on the roof of the mouth or along the inside of the lower teeth. The metal wires extend across the front of the teeth, securing the retainer in place. These two components can withstand daily wear making the appliance a long-lasting option for many cases. One of the key advantages of the Hawley retainer is its adjustability. If necessary, the orthodontist can make minor adjustments to the metal wires to ensure a precise fit. The design allows easy removal and thorough cleaning and maintenance to prevent plaque and bacteria accumulation. Because of the visibility of the metal wires and some discomfort, the Hawley retainer might not be the first choice when it comes to patients. Initially, it is worn full-time for the first couple of months, gradually transitioning to nighttime use. The duration of wear is always individual and depends on the primary type of malocclusion.

Essix retainer

This removable appliance covers the entire dental area besides the third molars (if there are any). In the recent decade, their use has become more popular in clinical practice. Because of their partial elasticity, they allow physiological movement and enable better establishment of occlusal contacts. They provide comfort, effectiveness, and aesthetic appearance, making them a preferred option for many patients. Their wear time always depends on the type of primary malocclusion, but some specialists prescribe full-time wear for the first six months and after that only nightly. Regular cleaning with non-abrasive products such as a soft brush and tooth paste, or denture cleaning products is essential to prevent plaque build up and maintain hygiene.



Picture 3. Mandibular invisible thermoplastic/vacuum-formed (Essix) retainer.

Taken with permission of prof.dr.sc. Sandra Anić Milošević.

Removable retention procedure

When it comes to invisible thermoplastic/vacuum-formed or Essix retainer there are two ways to make it. The digital procedure by using the intraoral scanner and a computer, or the traditional way by taking an anatomical impression and pouring the model of the impression. Creating the retainer by an impression usually takes several steps. The material for the anatomical impression is usually alginate or silicone material. After the correct impression, the anatomical model is poured from dental plaster.

Once the gypsum is dried to a solid state, the model is taken out of the impression and checked out for any mistakes or deformities. A clear sheet of thermoplastic material, usually made from polyethylene terephthalate glycol copolymer, 1 mm thickness is the most used material for Essix retainers. By heating the sheet in a vacuum-forming machine, the material becomes soft and adaptable. Stretching the material over the dental model creates an individual mold. By trimming the excess material and polishing the sharp edges a clear removable retentive device

is formed. The borders of the appliance should cover the gingiva no more than three mm. The device should fit the patient accordingly and comfortably.

While wearing the retainer, acidic drinks or sweets shouldn't be consumed. Because it adheres to the tooth, sugar, and acid could easily get trapped in the in-between space and corrode the enamel. It is important to show each patient how to take the appliance off and to advise them on proper appliance hygiene.

3.3. Additional retention methods

Besides removable and fixed retention methods, there are some other procedures that could serve as retention when it comes to preventing relapse. Sometimes, orthodontists may opt for a more complex retentive procedure such as supracrestal circumferential fibrotomy or interproximal reduction (IPR).

Fibrotomy

Several methods have been utilized to reduce rotational relapse, including early correction, overrotation, and long-term retention. However, supracrestal fibrotomy is regarded as the most effective (14). This procedure implies insertion of a surgical scalpel into the gingival sulcus and separation of the epithel and the transseptal fibers. By isolating the rotated tooth, relapse tendency is reduced. It is advised to perform the procedure one or two months before removing the fixed orthodontic appliance.

Interproximal reduction (IPR)

IPR commonly referred to as stripping, is a standard orthodontic procedure used to decrease the mesiodistal width of teeth, thereby promoting a balanced distribution of space within dental arches (15). Indications are mild or moderate crowdings, correcting the curve of Spee, elimination of black gingival triangles and stabilization of retention. The most frequently used techniques are air-rotor stripping, abrasive metal strips, and diamond-coated stripping disks.

3.4. Retentive period

The retention phase, which marks the conclusion of orthodontic treatment, aims to preserve the teeth in the desired positions following the completion of OTM. It is the crucial step for a successful and long-lasting orthodontic treatment outcome. Relapse doesn't always occur, but each patient is treated as there is a definite chance of relapse. The common forms of retention are a lingually fixed wire on the lower anterior region and the Essix removable retainer in both jaws (16).

Most orthodontists prescribe life-long fixed and removable forms of retention, while others suggest the length of the retention phase should be twice as long as the orthodontic treatment.

4. DISCUSSION

When it comes to orthodontic treatment, nowadays the real problem is how to prevent relapse and how to provide proper retention. During treatment, periodontal fibers break and the alveolar bone remodels which forms a new support environment for the teeth. These tissues stretch and remodel to accommodate tooth movement. Once the orthodontic appliance is removed from the patient's mouth, that does not indicate that the treatment is over, it only means that the new teeth schedule is very unstable and a form of anchorage should be provided.

The patient is entering the next phase of treatment which is the retention phase. In this phase, it is crucial to follow the orthodontist's rules on how to provide correct retentive measures so the treatment outcome can be successful. Despite significant advancements in orthodontic techniques and materials, relapse remains a common issue affecting both the functional, aesthetic, and physiological outcomes of the treatment. Understanding the complexities and the multifactorial nature of this problem is crucial to developing effective strategies of relapse prevention.

Rotation anomalies have the highest risk of relapse, even if the treatment outcome is satisfactory relapse still might occur. Compression from the soft tissues or the lingual side in the area of the lower incisors and skeletal growth are the main causes of mandibular incisor relapse.

The most used forms of retention are either fixed retentive metal wires, removable Essix retainers or a combination of both. Fixed retention is mostly limited to a certain region because of the tooth morphology, occlusion, function, and comfort. Fixed retentive metal wires are lingually or palatally bonded by composite to the anterior region. It has been proven clinically that the teeth with the highest possibility of retention are the mandibular incisors.

The changes on this region could be the result of relapse or physiological movement. This is why the lingually fixed orthodontic wire should be flexible, but not elastic so it could allow the physiological movement which occurs naturally with age, skeletal growth, bone loss and oral habits. Fixed retainers can lead to unwanted incisor movement. This issue may emerge if the wire is in an active state, deformed or overly flexible during bonding. When it comes to maxillary incisors, they are usually avoided when considering fixed retention as it may intrude into occlusion and mastication.

Removable retentive appliances require complete patient cooperation and consistency regarding application and maintenance (17), which leads to a higher possibility of relapse if the patient isn't wearing the appliance accordingly. The risk of caries may increase only if the patient isn't providing the according oral and removable appliance hygiene. There should always be an emphasis on upkeeping hygiene since the appliances are prone to collect oral bacteria and microorganisms from the area (box where the retainer is stored when it isn't worn).

Physiological tooth movement is a normal factor that follows each individual through life, even if that individual went through orthodontic treatment. Lifetime dental adjustments and alterations in dental relationships are common knowledge, even among individuals who maintain good oral health (18). For instance, mandibular growth can alter the occlusion and alignment achieved during treatment. Understanding these growth patterns is essential for planning retentive treatment, especially in adolescent patients. Long-term monitoring may be required to monitor the changes associated with growth.

Every retentive appliance should be made out of flexible material to enable physiological movement but to keep the teeth in the appropriate position. For a long time, craniofacial growth post orthodontic treatment has been connected to orthodontic relapse, but according to new research, there is no connection between the rotation of the mandible and relapse of mandibular incisors (19).

Interproximal reduction is a technique that harmonizes the available arch space to prevent crowding. Therefore, this procedure acts as a viable alternative to teeth extraction, as it significantly reduces treatment duration while maintaining the transverse dimension of the dental arch and the anterior inclination of the lower incisors (20). As a result, there could appear consequences such as hypersensitivity, irritation of the pulp, increased plaque formation, and caries risk in the stripped interdental areas.

Circumferential fiberotomy can be performed by surgical scalpel or a laser for reduction of relapse after orthodontic treatment. This procedure may reduce the relapse risk by releasing the tension of the periodontal fibers when it comes to severely rotated teeth. Several studies have shown results of long-term stability post circumferential fiberotomy of surgically severed teeth (21). However, it is important to clinically evaluate the angle of rotation for a successful treatment outcome.

As a final stage of treatment, some might say that the retention phase is the most important. Before selecting a retention method for a patient, it is crucial to consider the malocclusion and any remaining skeletal growth. Each retentive period is appointed individually, and its success depends on the physiological movement, oral habits, and patient cooperation. Despite numerous studies on the stability of dental arches after orthodontic therapy, the results and conclusions they present aren't consistent (22).

There is no strict rule when it comes to the duration of retention. When it comes to removable appliances, full-time wear is usually recommended for the first three to six months post-treatment to allow PDL and bone stabilization. After that initial period, patients are typically advised to wear retainers nightly. Fixed retainers can be left bonded lingually for several years or even life-long. Some orthodontists claim that the retentive period should be as twice as long as the orthodontic treatment, and others consider it a life-long obligation.

Maintaining oral hygiene with fixed or removable retention appliances requires a dedicated approach. Patients must be educated on the increased risk of plaque and bacteria accumulation and the potential risk for certain complications such as gingivitis, periodontitis and caries. With effective daily brushing, flossing, and professional cleaning, patients can maintain optimal dental health while using retentive appliances. When it comes to fixed retention, it is advised to use a soft regular or electric toothbrush at least twice a day with the help of interdental brushes for the area where the retentive wire is fixed. It is crucial to keep the interdental places near the gingiva as clean as possible to prevent bacteria formation.

Removable retentive devices tend to accumulate bacteria after a week of use. To prevent bacterial growth it is advised to brush them gently with a soft toothbrush after every use and store them in a dry container. By following these guidelines, patients can ensure the longevity of their retentive devices and preserve the results of their orthodontic treatment. Orthodontists should provide their patients with detailed instructions on oral hygiene maintenance during treatment to reduce the therapy's negative side effects (23).

5. CONCLUSION

Teeth have a high tendency to return to their original position after the orthodontic treatment. This phenomenon is called relapse and it's considered to be a multifactorial cause. The PDL, gingiva, growth, age, physiological movement, occlusal, and habitual factors all have a role when it comes to relapse. There is always a risk of relapse, unfortunately, it isn't preventable but we can try to avoid it with certain measures. The correct and the most effective way of preventing relapse is yet to be defined, but the most promising are retentive measures. With fixed, removable or a combination of both, we provide retention to each patient right after orthodontic treatment. Fixed retention is less demanding because it's bonded to the teeth, lingually or palatal to the anterior region of the maxillar or mandibular teeth. It doesn't cover the complete dental space so it is advisable to combine it with a removable retentive advice such as a Hawley or an Essix retainer. When it comes to removable appliances, it is very important to make the patient aware of the importance of their cooperation. If the patient doesn't respect the rules of retention, relapse will happen.

6. LITERATURE

1. Grgurevic L, Novak R, Salai G, Trkulja V, Hamzic LF, Popovic VZ, et al. Identification of bone morphogenetic protein 4 in the saliva after the placement of fixed orthodontic appliance. *Prog Orthod.* 2021;22(1):19.
2. Ferguson DJ, Wilcko MT. Tooth Movement Mechanobiology: Toward a Unifying Concept. In: *Biology of Orthodontic Tooth Movement*. Cham: Springer International Publishing; 2016. p. 13–44.
3. Ubuzima P, Nshimiyimana E, Mukeshimana C, Mazimpaka P, Mugabo E, Mbyayingabo D, et al. Exploring biological mechanisms in orthodontic tooth movement: Bridging the gap between basic research experiments and clinical applications – A comprehensive review. *Annals of Anatomy - Anatomischer Anzeiger.* 2024;255:152286.
4. Lyros I, Tsolakis IA, Maroulakos MP, Fora E, Lykogeorgos T, Dalampira M, et al. Orthodontic Retainers—A Critical Review. *Children.* 2023;10(2):230.
5. Chacón-Moreno A, Ramírez-Mejía MJ, Zorrilla-Mattos AC. Recidiva y movimiento dental involuntario después del tratamiento de ortodoncia en personas con retenedores fijos: Una revisión. *Revista Científica Odontológica.* 2022;10(3):e116.
6. Moyers RE. *Handbook of orthodontics*. Chicago, London, Boca Roton; Year book medic. 1988.
7. Littlewood S, Kandasamy S, Huang G. Retention and relapse in clinical practice. *Aust Dent J.* 2017;62(S1):51–7.
8. Andrews LF. The six keys to normal occlusion. *Am J Orthod.* 1972;62(3):296–309.
9. Klaus K, Xirouchaki F, Ruf S. 3D-analysis of unwanted tooth movements despite bonded orthodontic retainers: a pilot study. *BMC Oral Health.* 2020;20(1):308.
10. Andriekute A, Vasiliauskas A, Sidlauskas A. A survey of protocols and trends in orthodontic retention. *Prog Orthod.* 2017;18(1):31.
11. Reitan K. Clinical and histologic observations on tooth movement during and after orthodontic treatment. *Am J Orthod.* 1967;53(10):721–45.
12. Årtun J, Spadafora AT, Shapiro PA, McNeill RW, Chapko MK. Hygiene status associated with different types of bonded, orthodontic canine-to-canine retainers. *J Clin Periodontol.* 1987;14(2):89–94.
13. Vaida LL, Bud ES, Halitchi LG, Cavalu S, Todor BI, Negrutiu BM, et al. The Behavior of Two Types of Upper Removable Retainers—Our Clinical Experience. *Children.* 2020;7(12):295.

14. Jahanbin A, Ramazanzadeh B, Ahrari F, Forouzanfar A, Beidokhti M. Effectiveness of Er:YAG laser-aided fiberotomy and low-level laser therapy in alleviating relapse of rotated incisors. *American Journal of Orthodontics and Dentofacial Orthopedics*. 2014;146(5):565–72.
15. Serbanoiu DC, Vartolomei AC, Ghiga DV, Pop SI, Panainte I, Moldovan M, et al. Comparative Evaluation of Dental Enamel Microhardness Following Various Methods of Interproximal Reduction: A Vickers Hardness Tester Investigation. *Biomedicines*. 2024;12(5):1132.
16. Andriekute A, Vasiliauskas A, Sidlauskas A. A survey of protocols and trends in orthodontic retention. *Prog Orthod*. 2017;18(1):31.
17. Mollov ND, Lindauer SJ, Best AM, Shroff B, Tufekci E. Patient attitudes toward retention and perceptions of treatment success. *Angle Orthod*. 2010;80(4):656–61.
18. Nanda RS, Nanda SK. Considerations of dentofacial growth in long-term retention and stability: Is active retention needed? *American Journal of Orthodontics and Dentofacial Orthopedics*. 1992;101(4):297–302.
19. Le Y, Li F, Wu S, Li M, Zhu C, Wan Q. Influence of differences in mandibular incisor inclination on skeletal stability after orthognathic surgery in patients with skeletal class III malocclusion. *J Stomatol Oral Maxillofac Surg*. 2024;125(4):101747.
20. Lapenaite E, Lopatiene K. Interproximal enamel reduction as a part of orthodontic treatment. *Stomatologija*. 2014;16(1):19–24.
21. Al-Jasser R, Al-Subaie M, Al-Jasser N, Al-Rasheed A. Rotational relapse of anterior teeth following orthodontic treatment and circumferential supracrestal fiberotomy. *Saudi Dent J*. 2020;32(6):293–9.
22. Ispitivanje dugoročne stabilnosti zubnih lukova nakon završetka ortodontske terapije [Internet]. Available from: <https://urn.nsk.hr/urn:nbn:hr:127:287483>
23. Čalušić Šarac M, Anić Milošević S, Matošić Ž, Lapter Varga M. Oral Hygiene Behavior of Croatian Adolescents during Fixed Orthodontic Treatment: A Cross-sectional Study. *Acta Stomatol Croat*. 2021;55(4):359–66.

7.BIOGRAPHY

Iva Jelić was born on 28th September 1999. in Zagreb, Croatia. She started her education at Josip Juraj Strossmayer primary school and continued her high school studies at the XVI. Gymnasium. During high school, she spent a year living abroad in Orlando, Florida, USA. Throughout her school years she was an active volleyball player with three national championships and a few golden medals in international tournaments.

In 2018, Iva enrolled in the School of Dental Medicine, University of Zagreb. During university, she was an active member and lecturer of the „Student Symposium of Dental Medicine“ in 2023. and 2024, Prosthodontic and Orthodontic student section. In addition to her academic career, Iva has been a research volunteer at the Center for Translational and Clinical Research, Department of Proteomics, School of Medicine, and a clinic volunteer at several departments of KBC Zagreb. Throughout dental school, she assisted in several dental practices and at the Policlinic Arena Dental. Her fields of interest are orthodontics, periodontics, and prosthodontics.