

Excision and pathohistological diagnosis of atypical peripheral ossifying fibroma - Case report

Burazin, Iva

Master's thesis / Diplomski rad

2024

Degree Grantor / Ustanova koja je dodijelila akademski / stručni stupanj: **University of Zagreb, School of Dental Medicine / Sveučilište u Zagrebu, Stomatološki fakultet**

Permanent link / Trajna poveznica: <https://um.nsk.hr/um:nbn:hr:127:615424>

Rights / Prava: [In copyright](#) / [Zaštićeno autorskim pravom.](#)

Download date / Datum preuzimanja: **2025-02-28**



Repository / Repozitorij:

[University of Zagreb School of Dental Medicine
Repository](#)





University of Zagreb
School of Dental Medicine

Iva Burazin

**EXCISION AND PATHOHISTOLOGICAL
DIAGNOSIS OF ATYPICAL PERIPHERAL
OSSIFYING FIBROMA - CASE REPORT**

GRADUATE THESIS

Zagreb, 2024.

The work was carried out at: Department of Oral Surgery, School of Dental Medicine, University of Zagreb

Thesis mentor: dr. sc. Tomislav Katanec, Department of Oral Surgery, School of Dental Medicine, University of Zagreb

English language proofreader: Ena Čurić, MA in English Language and Croatian Language

Croatian language proofreader: Ena Čurić, MA in English Language and Croatian Language

The manuscript contains: 37 pages

0 tables

8 pictures

The paper is an author's own work, which is completely independently written with an indication of the sources of other authors and documents used in the paper. Unless otherwise stated, all illustrations (tables, pictures, etc.) in the paper are the original contribution of the author of the thesis. The author is responsible for obtaining permission for the use of illustrations that are not their original contribution, as well as for any possible consequences that may arise due to unauthorized downloading of illustrations or failure to indicate their origin.

Proclamation or Dedication or Thanks

I want to thank my mentor, dr. sc. Tomislav Katanec for his help in preparing my graduate thesis. Furthermore, I want to thank all the professors and colleagues at the university who have guided me and taught me over the years.

Most of all, I want to thank my family, without your love and support I wouldn't be where I am now.

EXCISION AND PATHOHISTOLOGICAL DIAGNOSIS OF ATYPICAL PERIPHERAL OSSIFYING FIBROMA

Summary

Peripheral ossifying fibroma (POF) is a benign, reactive growth that appears on the gingiva, often triggered by local irritants such as dental plaque, tartar, or dental devices. This thesis aims to explore the clinical and histological features of POF, understand its etiology, and review various treatment options. A retrospective study was conducted on patients diagnosed with POF to collect data on demographics, lesion characteristics, and recurrence rates. The tissue composition of the lesions was analyzed through pathohistological examinations. A comparative context for the findings was also provided through a literature review. POF primarily impacts the anterior maxilla, and according to the research, there is a female predilection. Typically, the lesions exhibit a proliferation of fibroblastic cells, as well as areas of calcification and ossification. This is frequently accompanied by chronic inflammation and occasional ulceration. The high recurrence rate observed confirms the necessity of complete surgical excision and the removal of local irritants to reduce the risk of recurrence. Early detection and management of recurring lesions requires consistent follow-up.

Key words: Peripheral ossifying fibroma (POF); local irritants; surgical excision

EKCIZIJA I PATOHISTOLOŠKA DIJAGNOSTIKA ATIPIČNOG PERIFERNOG OSIFICIRAJUĆEG FIBROMA

Sažetak

Periferni osificirajući fibrom (POF) je benigna, reaktivna izraslina koja se pojavljuje na gingivi, često izazvana lokalnim iritansima poput zubnog plaka, zubnog kamenca ili zubnih naprava. Ovaj rad ima za cilj istražiti kliničke i histološke značajke POF-a, razumjeti njegovu etiologiju i pregledati različite mogućnosti liječenja. Provedena je retrospektivna studija na pacijentima kojima je dijagnosticiran POF kako bi se prikupili podaci o demografskim karakteristikama, karakteristikama lezija i stopama recidiva. Sastav tkiva lezija analiziran je histopatološkim pretragama. Usporedni kontekst za nalaze također je osiguran pregledom literature. POF primarno utječe na prednju maksilu, a prema istraživanjima, postoji ženska predispozicija. Tipično, lezije pokazuju proliferaciju fibroblastičnih stanica, kao i područja kalcifikacije i osifikacije. To je često popraćeno kroničnom upalom i povremenim ulceracijama. Uočena visoka stopa recidiva potvrđuje nužnost potpune kirurške ekscizije i uklanjanja lokalnih iritansa kako bi se smanjio rizik od recidiva. Rano otkrivanje i liječenje ponavljajućih lezija zahtijeva dosljedno praćenje.

Ključne riječi: Periferni osificirajući fibrom (POF); lokalni iritansi; kirurška ekscizija

TABLE OF CONTENTS

1. INTRODUCTION.....	1
1.1 Benign odontogenic tumors.....	3
1.1.1 Epithelial odontogenic tumors.....	3
1.1.2. Mixed odontogenic tumors.....	5
1.1.3. Mesenchymal odontogenic tumors.....	8
1.2 Benign non-odontogenic tumors.....	9
1.2.1 Maxillofacial tumors.....	9
1.2.2 Bone and Cartilaginous Tumors.....	11
1.2.3 Giant cell lesions.....	13
1.3. Central and peripheral ossifying fibroma.....	15
1.3.1 Central ossifying fibroma.....	15
1.3.2 Peripheral ossifying fibroma.....	16
2. CASE REPORT.....	17
3. DISCUSSION.....	23
4. CONCLUSION.....	29
5. LITERATURE.....	31
6. BIOGRAPHY.....	36

List of abbreviations

WHO - World Health Organization
SOT - squamous odontogenic tumor
AOT - adenomatoid odontogenic tumor
CEOT - calcifying epithelial odontogenic tumor
AF - ameloblastic fibroma
POT - primordial odontogenic tumor
OF - odontogenic fibroma
OM - odontogenic myxoma
NSAIDs - nonsteroidal anti-inflammatory drugs
OC - osteochondroma
TMJ - temporomandibular joint
CGCL - central giant cell lesion
POF - peripheral ossifying fibroma
PG - pyogenic granuloma
PGCG - peripheral giant cell granuloma

1. INTRODUCTION

The oral cavity is a host to various types of lesions. Those lesions can be benign and reactive in nature. They are derived from a variety of tissue types, including odontogenic (tooth-forming) and non-odontogenic tissues(1). It is essential for dental and medical professionals to be familiar with these lesions in order to ensure the best patient outcomes, effective management, and accurate diagnosis. Benign odontogenic lesions are derived from the remnants of tooth-forming tissues and originate exclusively in the maxilla or mandible. On the contrary, non-odontogenic benign lesions originate from variety of tissues in the oral cavity that are not involved in tooth development. Those tumors can develop anywhere else compared to the zone of the head and neck and frequently start in non-tooth-bearing facial bones(1). Reactive lesions in the mouth are frequently induced by some trauma or chronic irritation. Although these lesions are non-neoplastic, they may show serious proliferative activity. Common reactive lesions involve peripheral giant cell granuloma, pyogenic granuloma, and peripheral ossifying fibroma (POF)(2). This thesis aims to investigate the histological and clinical characteristics of peripheral ossifying fibroma (POF), a reactive, benign growth that typically affects the gingiva. This research involves understanding the etiology of POF, discussing over potential treatments, and using pathohistological tests to examine the tissue composition of the lesions. The thesis also wants to highlight the demographics, lesion characteristics, and recurrence rates from a retrospective study, as well as to provide a comparative context for the findings through a review of the literature. Finally, it emphasizes the significance of early detection and consistent follow-up to effectively manage recurring lesions. A specific aim of this thesis is to describe and analyze a unique case of a 70-year-old man with POF, which is atypical since POF normally affects women in their twenties and usually affects the anterior maxilla. This case involved a mass in the posterior part of the mandible, challenging the common demographic and locational patterns of POF. The detailed analyses of this case, including the patient's medical history, diagnostic procedure, surgical treatment, and follow-up, aims to contribute to a broader understanding of POF, its variability, and potential predisposing factors such as improper occlusion of dental prosthetics.

1.1 Benign odontogenic tumors

Jaw tumors, both non-odontogenic and odontogenic, can be benign or malignant neoplasms. Odontogenic tumors originate in dental tissue and can present in the mandible and maxilla. Metastasis is uncommon in these tumors but local aggressiveness is more common. On the other hand, non-odontogenic tumors that originate from epithelium or mesenchyme are not related to dental tissue and can come from locations other than the head and neck. Some of these tumors are not very clinically significant and usually only require normal monitoring or local resection(1).

Only 2-3% of oral and maxillofacial pathological samples contain odontogenic tumors from dental tissue. They form during odontogenesis, which involves the organ of enamel, dental papilla, and follicle. The ectoderm produces the organ of enamel, dental papilla, and follicle. Odontogenic tumors interact with odontogenic epithelium and mesenchyme and are subdivided by tissue origin. The 2005 WHO classification of odontogenic tumors covers epidemiology, etiology, clinical picture, pathohistology, genetics, and prognosis, unlike the previous one, which only covered the histology(1).

1.1.1 Epithelial odontogenic tumors

Ameloblastoma

One of the most prevalent odontogenic tumors, ameloblastoma, is derived from differentiated cells of the enamel epithelium called ameloblasts. The mandibular molar region and angle are the most common locations, with the mandible having ten times higher prevalence than the maxilla. The tuberosity area is often a site of manifestation if it occurs in the maxillary area. This tumor is usually found in people from thirty up to sixty years of age. Unlike cysts, which usually cause edema on only one side of the jaw, ameloblastoma causes whole thickness bone edema when it first manifests. Ameloblastomas frequently enlarge and impact the complete ascending ramus of the mandible, resulting in facial asymmetry and bone deformity due to their typically asymptomatic and gradual growth process. Ameloblastoma, a benign odontogenic tumor, is exceedingly

recurrent; malignant forms with lymphatic and hematogenous metastases have been documented in extremely rare instances. The manifestation of pain and the acceleration of tumor growth are indicative of the ameloblastoma's malignant transformation. Ameloblastoma is histologically categorized into four types according to the WHO classification: solid/multicystic (91 percent), unicystic (6 percent), extraosseous (2 percent), and desmoplastic type (1 percent) (3). In clinical presentation, ameloblastomas usually show non-specific symptoms, most commonly a painless swelling in the jaw area. If there is pain, it is typically caused by bleeding into the nearby soft tissue. The majority of ameloblastomas are unintentionally found during radiographs that are taken for other purposes. Differential diagnosis should exclude ameloblastoma from keratocyst, although keratocyst often expands rather than resorbs the surrounding tooth roots. Since the incidence of recurrence is very high, around 60%, the treatment option is enucleation with resection into healthy bone. (4)

Squamous odontogenic tumor

It is a tumor of epithelial origin of unknown etiology. It is very uncommon. In the maxilla or mandible, the tumor usually manifests as a localized gingival swelling or extraosseous mass with potential tooth movement, pain, and gingival erythema (1). Typical age when this tumor appears is about forty. Equally, it affects men and women. Usually occurring close to the neck of tooth roots, the lesion has a distinct border and a crescent form (5). Histologically, SOTs consist of rounded or well-differentiated squamous epithelium surrounded by ovoid islands of fibrous stroma with calcified material present on particular islands (1). The tumor usually does not show aggressive behavior, although they may manifest as numerous lesions that cause expansion of cortical bone. The treatment option is surgical excision.

Adenomatoid odontogenic tumor

An adenomatoid odontogenic tumor is a non-cancerous growth that originates from epithelial tissue. It represents 2 to 7% of odontogenic tumors in total. Usually manifests a slow but advanced growth (1). AOTs are diagnosed in individuals starting from age 5 up to 30, with the

majority of cases manifesting in their twenties. Males are not as frequently impacted as females. The anterior maxilla is frequently more affected than the mandible and frequently corresponds to the crowns of impacted teeth. The follicular AOT is a precisely defined unilocular lesion that looks circumferentially on radiographs, typically surrounding the impacted tooth's crown. In contrast, the extrafollicular type is characterized by a unique unilocular radiolucency that is situated above, between, or on top of an unerupted tooth's roots (5). Therapy involves local excision. Recurrences of this tumor are infrequent (1).

Calcifying epithelial odontogenic tumor

Calcifying epithelial odontogenic belongs to tumors of epithelial origin and is not very common. It usually grows slow but can be locally aggressive (3). About 1% of all odontogenic tumors are calcifying epithelial odontogenic tumors, comprising individuals between 20 to 60 years old, with an average age of almost 40. There is no preference based on gender. Six percent or more of CEOT instances occur in extraosseous places, with the majority occurring intraosseously. Intraosseous tumors impact mandible 2 times more than maxilla. Although they can arise anywhere, these tumors typically appear in the premolar/molar region. The anterior gingiva is where peripheral lesions are typically detected. On the radiograph, it is usually viewed as dark transparency of the bone which can contain some translucent parts that look like amyloids (3).

1.1.2 Mixed epithelial and mesenchymal odontogenic tumors

Ameloblastic fibroma

Ameloblastic fibroma (AF) is a potentially destructive mixed non-malignant odontogenic tumor. As opposed to the hamartomas ameloblastic fibro-odontoma and odontoma, AF is a true neoplasm made up of filaments of the epithelium and odontogenic ectomesenchyme. It generally does not contain hard dental tissues, with the exception of cases such as ameloblastic fibrodentinoma, which do contain dentin. It is usually seen in posterior part of mandible in first two decades of

life. It manifests as a unilocular or multilocular radiolucency on the radiograph. Conservative excision is advised, in spite of the 33.3% recurrence rate (1).

Odontoma

Odontomas are the most prevalent kind of odontogenic tumors. They are considered benign hamartomas rather than actual tumors and typically exhibit a non-aggressive clinical behavior (1). Benign tumors known as odontomas are caused by changes in mesenchymal and epithelial odontogenic cells, which are responsible for the synthesis of cementum, dentin, and enamel. They are classified into two categories: complex forms and compound forms, depending on the arrangement of dental tissue. Research has looked into potential connections with infections, trauma, odontoblastic hyperactivity, and genetic anomalies, yet the exact cause is still unknown. The delayed eruption of permanent teeth is typically the reason behind the discovery of 75% of these tumors before the second decade of life. These tumors are usually asymptomatic (6). Compound odontomas are typically found between tooth's roots or around the crown of impacted teeth and show many little teeth in one focal point on radiography. On the other hand, complex odontomas present as opaque masses in the same locations as the compound ones. Early-stage lesions are characterized by focal areas of opacity and radiolucency, which indicate early dentin and enamel calcification. According to histological findings, the cementum, dentin, and enamel will appear normal. There is also evident "ghost cell keratinization" in the cells of some odontomas that generate enamel (5).

Dentinogenic ghost cell tumor

In the past, dentinogenic ghost cell tumor was considered a firm variant of the calcifying odontogenic cyst but now it is recognized as a locally invasive tumor. It is made up of mature connective tissue stroma with islands of epithelial cells resembling ameloblastomas, dysplastic dentin, and ghost cells. It manifests as an intraosseous or extraosseous mass of firm or soft tissue that induces bone resorption or tooth displacement. It is usually asymptomatic. On the radiograph, it

is seen as radiolucent or combined radiopaque/radiolucent lesion that is sharply outlined. It is characterized histologically by the presence of dysplastic dentin and phantom cells. Recurrence is rare if proper excision is performed(1).

Primordial odontogenic tumor

Primordial odontogenic tumor (POT) is rarely found, benign tumor that originates from both mesenchymal and epithelial tissues. On radiographs, POT appears as a lesion with sharply defined borders, either with multiple compartments or a single compartment. It is usually seen the area surrounding an unerupted tooth's crown. This tumor presents as asymptomatic bone enlargement, root resorption, and buccal or lingual cortical growth. POTs are composed of fibrous tissue that ranges from loose to cellular, with areas resembling dental papillae. These regions are entirely covered in a cuboidal-to-columnar epithelium that is similar to the enamel organ's internal epithelium. The tumor appears microscopically as a solid, pallid, slippery nodule that is typically encapsulated (7).

Odontogenic myxoma

Odontogenic myxoma (OM) is a relatively common form of odontogenic tumor, comprising approximately 3 to 20% of these lesions. Even though OM is benign, it has a tendency to be locally invasive. Although it is likely less aggressive than an ameloblastoma, OM can still result in significant growth and potentially affect the cranium base if left untreated. It is classified as the second or third most prevalent odontogenic tumor. Molar area of the mandible is a place where OM is usually found. They typically manifest between the second and fourth decade of life, and there is no gender preference (1). It is often discovered incidentally during routine dental exams using panoramic X-rays. These X-rays typically reveal a clearly defined, honeycomb-like area of reduced opacity (radiolucency) on the bone, often near a tooth that has already erupted. The lesion appears unremarkable, with loose mesenchymal fibrous tissue that lacks atypia. It is composed of round, spindle-shaped, stellate, and eosinophilic cytoplasmic process cells that are arranged rand-

only inside a mucoid or myxoid stroma. This histology resembles that of the dental papilla of a growing tooth as well as hyperplastic dental follicles. In order to avoid misdiagnosis, clinical correlation is essential (1). Teeth in the tumorous region may become displaced and their roots may undergo resorption. Multilocular tumors need extra resection of the surrounding bone due to a 60% likelihood of recurrence with patient monitoring for five years. Aggressive recurrence may occur following the tumor excision due to the likelihood of malignant transformation, indicating a highly malignant transformation to myxosarcoma with predominant connective tissue cells (3).

1.1.3. Mesenchymal odontogenic tumors

Odontogenic fibroma

A rare benign mesenchymal tumor called an odontogenic fibroma (OF) can arise from a dental follicle, periodontal ligament, or dental papilla (8). This type of lesion is defined by World Health Organization as a rare growth made up of fibrous collagenous tissue mixed with different amounts of odontogenic epithelium (9). There have been two different histological variants defined: epithelial rich (previously referred to as complex or WHO type) and epithelial poor (formerly known as simple type) (1). The location of their appearance determines whether they are intraosseous or central, or extraosseous if peripheral (10). Their manifestation on radiograph is either unilocular or multilocular and they have the potential to induce cortical bone expansion (1,11). Since the aggressive behavior of this tumor is very rare, curettage and enucleation is the therapy of choice (1).

Cementoblastoma

Cementoblastoma is an unusual benign tumor of cementoblasts that is connected to a tooth root and microscopically resembles an osteoblastoma. It is closely related to a tooth's root, usually mesiobuccal root of the lower 1st molar, which remains vital. It is usually discovered in the mandible but can also appear in the maxilla, particularly in the posterior areas rather than the anterior. It does not have a preference for gender and commonly appears in individuals who are in their

second or third decade of life, usually before the age of 25 (5). Symptoms include pain and varying degrees of cortical enlargement (1). On radiographs, this tumor appears as an opaque lesion replacing the tooth's root. It is typically encircled by a thick, homogeneous ring that is radiolucent and continuous with the tumor advancing front and periodontal ligament gap. The literature has detailed a number of therapeutic options, the most popular of which is surgical enucleation of the lesion in conjunction with the extraction of the connected tooth (5).

1.2 Benign non-odontogenic tumors

Non-odontogenic tumors arise from tissues such as fibrous tissue, bone, and vascular structures that are unrelated to the development of teeth. Accurate diagnosis and treatment of these tumors require a multidisciplinary approach due to their diverse clinical behaviors and histological patterns. It is essential to understand the differences between odontogenic and non-odontogenic tumors in order to correctly diagnose and select a course of treatment. Using radiographs, histology, and clinical presentation, we may create the best possible strategy for a patient with a jaw tumor (1).

1.2.1. Maxillofacial tumors

Chondroma

Chondroma is a benign cartilaginous tumor the origin of which is unclear. Especially in relation to other skeletal sites, chondromas are quite uncommon in the jaw. Typical presentation of a chondroma is a painless, gradually increasing swelling. Most craniofacial complex disorders start in the ethmoid sinuses and nasal septum. Maxillary chondromas are more frequently found in the anterior region, whereas chondromas of the mandible are often situated in the body and symphysis regions but can also be found in condyle or coronoid processes. Chondromas impact males and females equally, usually before the age of fifty. The chondroma commonly shows up on radiography as an asymmetrical radiolucent region with possible calcification foci (5).

Osteoma

Osteoma is a non-cancerous growth that develops gradually. They are composed of mature bone that resembles normal bone but has more bony material and less marrow. The location where osteoma often appears are frontal and ethmoid sinuses. Small lesions are typically asymptomatic and often discovered incidentally on radiograph. These growths tend to appear most often in people in their thirties and forties. It is only necessary to follow-up on them through X-ray since those lesions do not have a tendency to grow. On the contrary, paranasal osteomas can result in a range of symptoms, such as invasion of the orbit or brain. Exophthalmos, double vision, and optic nerve pressure that results in vision loss can all be caused by tumors close to the orbit. These growths can press against the frontal lobe of the brain, erode the cranial fossa wall, and create holes in the dura at various points. X-rays usually show a solid, ivory-like mass with clearly outlined edges. Paranasal osteomas are twice as commonly found in males than females, and they are rarely found in flat or long and short tubular bones (12).

Osteoid osteoma

An osteoid osteoma, a benign tumor found in the outer layer (cortex) of long bones, is relatively common. It ranks as the third most frequent benign bone tumor, making up about 10-14% of benign bone tumors and 2-3% of all bone tumors. Discomfort during the night is the usual clinical manifestation. It primarily impacts males who are below the age of 30. It can be observed as a radiolucent nidus that is smaller than 2 cm in diameter and is surrounded by reactive osteosclerosis. NSAIDs are used as the initial treatment because tumors frequently regress spontaneously within two to six years. However, surgical intervention becomes necessary if medical therapy fails to eliminate the pain (13).

Osteoblastoma

Uncommon primary lesion, osteoblastoma makes up for less than 1% of all primary bone tumors. In contrast to osteoid osteoma, osteoblastoma typically shows a diameter larger than 1.5 cm. Jaw

bone is not very frequent location for this lesion, vertebrae and long bones are much more affected. Usually, jaw involvement affects the mandible's and maxilla's posterior tooth-bearing areas. Approximately 10% to 12% of typical osteoblastomas are observed in the maxillofacial skeleton, with the mandible being the most commonly involved bone. The second decade is the most prevalent period for lesions, with ninety percent occurring before the age of thirty. With an approximate ratio of 2:1, males are more commonly affected than females. Severe pain is often seen in osteoid osteoma and can also be a characteristic of osteoblastoma. Localized swelling may occur together with pain or independently. NSAIDs and other analgesics frequently relieve the symptoms of osteoid osteoma, whereas this effect is less probable in the case of osteoblastoma. Lesions are well-defined and exhibit a lytic to mixed lucent-opaque pattern on the radiograph. Calcified central tumor mass may be encircled by small radiolucency. Osteoblastoma may lack perilesional bone sclerosis, which is a regular characteristic of osteoid osteoma (4).

1.2.2. Bone and cartilaginous tumors

Desmoplastic fibroma

Desmoplastic fibroma is a benign, locally aggressive lesion of bone of unknown cause. It is the bony counterpart of fibromatosis at both extragnathic and gnathic sites. Although it usually affects the pelvis and long bones, the tumor can occasionally affect the jaws. Patients under the age of 30, with a mean age of 14, are typically affected. Men and women are equally impacted. More often than the maxilla, the mandible is impacted, particularly the body - ramus area. Lesions are often asymptomatic and progress slowly but can eventually induce swelling of the jaw. Radiographically it can manifest as unilocular or multilocular lesions with well or poorly defined borders. Cortical perforation and root resorption may occur (4).

Fibrous dysplasia

Fibrous dysplasia (FD) is a non-odontogenic bone disease characterized by the benign fibrous tissue that replaces bone. It is related to genetics. FD affects either one bone (monostotic) or several bones (polyostotic) in the skeleton by replacing healthy bone with benign fibrous tissue. Up to 80% of cases of monostotic fibrous dysplasia are far more common than those of polyostotic type (4). The long bones are where FD most frequently manifests, then the base of the skull, the ribs, and the jaws (maxilla more than mandible). In the jaw is more common the polyostotic type. The alpha-subunit of a signal transducing G-protein (Gs-alpha) is encoded by the GNAS I gene, which is the cause of most instances (1). The differentiation and proliferation of the fibroblasts and osteoblasts that make up these lesions may eventually be impacted by this genetic change (4). Monostotic has no gender predisposition unlike polyostotic which occurs 3 times more in the female population (1). The growth of fibrous dysplasia in the jaw is slow and gradual and causes no pain initially. It often starts up as swelling on one side of the jaw. As it progresses, it can lead to noticeable facial asymmetry, which may be the first concern for patients. While it usually maintains the shape of the dental arch, it can sometimes displace teeth, cause a misalignment of the bite, and hinder the eruption of teeth. The appearance on X-rays varies, ranging from a solid, opaque mass to a more translucent lesion. In some cases, it may appear as a "ground-glass" pattern due to changes in bone density. Fibrous dysplasia can also appear as either single or multiple cavities on X-rays, particularly in long bones. On radiograph, fibrous dysplasia has weakly defined margins which seem to merge into surrounding normal bone. The stroma of fibrous connective tissue in fibrous dysplasia is mildly to moderately cellular and contains foci of irregularly formed immature bone trabeculae (4).

Osteochondroma

Osteochondroma (OC) is defined as a benign tumor with an osteo-cartilaginous exostosis and a cartilage-capped protrusion originating from the bone cortex. It is one of the most prevalent benign tumors of the axial skeleton, despite the fact that it rarely affects the face bones. When OC appears in the temporomandibular joint it often grows slowly and progressively enlarges the con-

dyle. Often, this growth causes malocclusion, restricted mouth opening, TMJ problems, and facial asymmetry. Both osseous and cartilaginous tissues form OC histologically. On radiography, it usually shows up as an exophytic protrusion from the condylar head and a unilaterally expanded condyle (14).

Cemento-osseous dysplasia

One of the common benign fibro-osseous lesions, cemento-osseous dysplasia (COD), usually affects the mandible. These self-limiting dysplastic lesions are not neoplasms and they usually reach 1.5 cm in size. Periapical, focal, and florid are the three categories into which COD is divided according to where the lesion is located in the jaw. Periapical COD usually appears in the anterior mandible, focal COD is found in a single quadrant of the posterior mandible, and florid COD involves multiple quadrants of the jaw. Many patients are asymptomatic and are diagnosed during regular dental exams. However, some may experience some kind of discomfort or show cortical bone erosion on radiographic images. According to Su et al., 70% of COD cases are closely associated with the tooth apex (15). Pathohistologically, COD typically occurs in periodontal ligament tissue, related to the apical foramen, and shows proliferation of cementum-like tissues. The presence or absence of symptoms influences treatment planning: asymptomatic patients usually do not require surgery, while symptomatic patients might undergo surgical intervention (16).

1.2.3 Giant cell lesions

Central giant cell granuloma

The central giant cell granuloma is a benign but potentially aggressive multiplication of fibroblasts and multinucleated giant cells that induces reactive bone growth and osteolysis. (CGCG). CGCG can exist as a separate lesion in the jaw or a progression of the same disease process that affects the long bones. People under the age of thirty and children are most frequently diagnosed with CGCG of the jaws. Compared to the maxilla, the mandible is typically more involved, and

the posterior part of the mandible is more involved than the anterior portion of the jaws. A fibrous connective tissue stroma with spindle-shaped fibroblast cells is commonly present in the lesion, along with hemorrhage regions, hemosiderin deposits, macrophages, lymphocytes, granulocytes, and plasma cells. Histologically, a brown tumor associated with hyperparathyroidism cannot be distinguished from the CGCG, so serum parathyroid hormone level is indicated to rule out primary or secondary causes of parathyroid dysfunction (1). CGCG usually results in jaw expanding or swelling without any pain. Although cortical plates are weakened, it is rare for them to break through and extend into soft tissues. Radiographic characteristics of CGCG include non-corticated, multilocular or, less commonly, unilocular radiolucency of bone. The margins of the lesion are usually clearly defined and sometimes appear scalloped in shape. In the differential diagnosis it is important to exclude multilocular ameloblastoma (5).

Peripheral giant cell granuloma

One of the most frequent growths on the gingiva is a reactive, non-neoplastic lesion called peripheral giant cell granuloma, sometimes referred to as giant cell epulis (3,17). It usually manifests as a red or reddish-blue nodular mass with a narrow base which is up to 2 cm in size (3,17). Giant cell epulis is usually caused by some local irritations due to bad fillings, inadequately constructed bridges or crowns and residual roots, but on the other hand can also be found in the area of deep pockets or in the toothless ridge area (3). Peripheral giant cell granuloma can appear at any age and in almost 52-60% cases women are affected. Sometimes the underlying bone resorption can be seen. Microscopically, large cells are visible with many nuclei surrounded by plump, ovoid, spindle-shaped mesenchymal cells. The treatment includes local excision to the underlying bone. Since there is a possibility of recurrence in 10-18% of cases, it is very important to remove any irritation that persists (17).

Cherubism

Cherubism is an unusual hereditary disorder recognized by symmetrical expansion of the mandible due to giant cell lesions. The typical age range for diagnosing cherubism is during the childhood, between 14 months and 4 years of age. It was initially recorded in 1933 and demonstrates an autosomal dominant inheritance pattern. Mandibular involvement is more common, but the process may extend into the anterior and inferior orbits and both jaws may be impacted. Condyles stay intact with this condition. The globes may be moved upwards when the maxillary contribution to the orbital floor is involved, producing scleral appearance and the “looking-up-to-heaven” element. Radiograph shows bilateral multilocular radiolucencies with cortical expansion, early tooth exfoliation, and a “soap bubble” appearance. Although the histological appearance is identical to that of a central giant cell lesion, hemosiderin deposits, stromal fibrosis, and collagen deposits resembling perivascular cuffs can help in distinguishing between them. Treatment is usually not required, only in case of severe dysfunction, because the lesions tend to regress spontaneously once the patient approaches skeletal maturity (1).

1.3 Central and peripheral ossifying fibroma

1.3.1 Central ossifying fibroma

A fibro-osseous lesion known as central ossifying fibroma (OF) occurs when normal bone is replaced by fibrous tissue and varying degrees of calcified structures that mimic cementum or bone. The stage and maturity of the lesion determine the degree of calcification. Although the precise etiology of OF is unknown, it is thought to be caused by pluripotent mesenchymal cells found in the periodontal ligament, which have the ability to generate the cementum and bone-like substance that is characteristic of OF. Genetic mutations and trauma have both been proposed as possible triggers. OF primarily affects women between the ages of 20 and 40, with a focus on the premolar-molar region of the lower jaw. Small OF lesions are typically asymptomatic when they are clinically detected by chance during standard radiography. Bigger lesions may exhibit paresthesia, exfoliation, swelling, pain, or pus discharge. As OF matures, radiographical appearances

might range from fully radiolucent to mixed radiolucent-radiopaque to fully radiopaque. Early-stage OF lesions may be mistaken for other conditions like periapical tooth pathology or central giant cell granuloma, while more mature lesions need differentiation from mixed jawbone lesions such as fibrous dysplasia and calcifying epithelial odontogenic tumors. The diagnosis is made through histological examination, which shows calcifications inside a hypercellular fibrous stroma. Surgical intervention, depending on the size, location, and type of the lesion, usually include curettage, enucleation, or more radical excision (18).

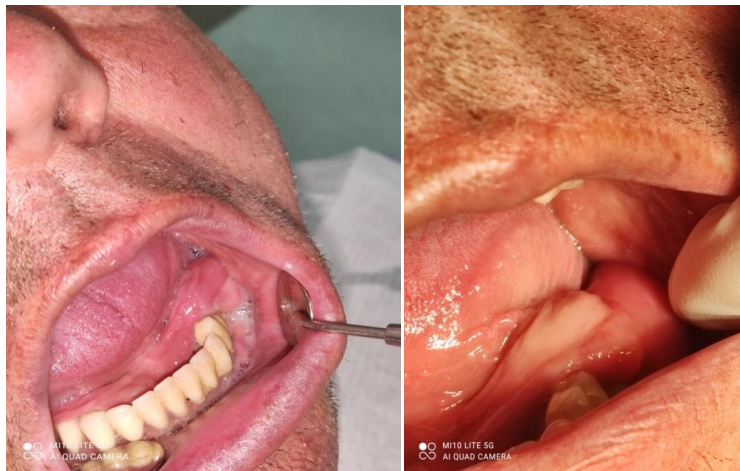
1.3.2 Peripheral ossifying fibroma

Peripheral ossifying fibroma is a gingival fibroma that demonstrates calcification or ossification regions. It is also known under different names such as peripheral cementifying fibroma, calcifying or ossifying fibrous epulis, and peripheral fibroma with calcification (19). It usually affects the female population more often, around the age of 20 and can appear anywhere in the oral cavity, in regions such as lips, alveolar crest, palate, floor of the mouth, etc. (19,20). The clinical

manifestation of this non-neoplastic lesion is a hard nodule, less than 2 cm in size, that does not show any pain and grows slowly (21). The color varies from pink to red with often, but not always, ulcerated surface (17). Irritating factors like trauma, bacteria, calculus, plaque, defective restorations, and dental appliances can all cause these lesions. It makes up to 9% of all gingival growths and is usually observed as a growth on the interdental papilla (19). Histologically, the connective tissue stroma contains a highly cellular mass of proliferating fibroblasts mixed with fibrillar tissue together with some dystrophic calcifications and large and small bone trabeculae (19). Due to similarities with some other conditions such as peripheral giant cell granuloma or pyogenic granuloma, both the clinical and histological diagnosis is very complex (22). Peripheral ossifying fibroma was considered a lesion that developed primarily from pyogenic granuloma that undergoes fibrous maturation and calcification, but not all the peripheral ossifying fibromas are developed in that manner (17). Overall, peripheral ossifying fibromas, which often arise from the interdental papilla, are localized, reactive, non-neoplastic tumor-like growths of the soft tissue (22).

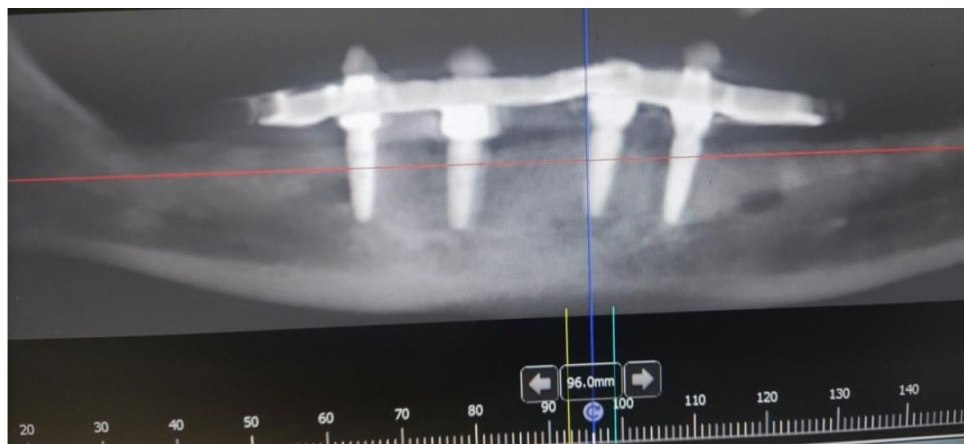2. CASE REPORT

A 70-year-old man came to the Oral Surgery Department at the University of Zagreb with a large fibrous growth in the back part of his left jaw (Picture 1). He had recently received two acrylic bridges supported by four implants, which were placed six months prior to noticing the jaw swelling. According to the patient, the swelling started about three months prior to seeking medical attention. Despite this, there were no signs of infection or abnormal bone changes around the implants on the panoramic X-ray or CBCT scan (Picture 2). The lesion showed no ulcerations on its smooth surface and was firmly connected to sublingual area with a wide base, measuring 3.5×2 cm. The differential diagnosis considered during the clinical examination included peripheral giant-cell fibroma, irritation fibromatosis, peripheral ossifying or non-ossifying fibroma, and the possibility of a malignant mass. The final diagnosis depended on the results of the ongoing pathohistological examinations. Ultimately, a decision was made to completely remove the mass (Picture 3). During the surgery, it was found that the mass was connected to a nearby artery in the left sublingual area. A resorbable 4/0 thread was used to tie off the artery, and the entire mass was successfully excised (Picture 4). The wound was closed with non-resorbable 4/0 silk stitches, primarily towards the sublingual area, allowing other parts of the incision to heal naturally (Picture 5 and 6). The bleeding sites were treated with electrocauterization to achieve proper hemostasis. Local anesthesia was used throughout the excision procedure. Seven days after the surgery, a clinical and medical assessment as well as suture removal were performed (Picture 7).

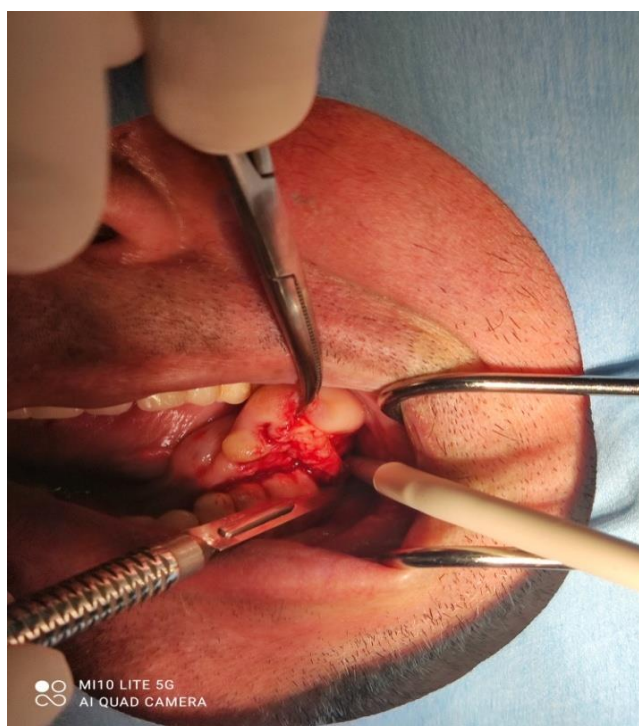


Picture 1. Appearance of the mass during the first visit

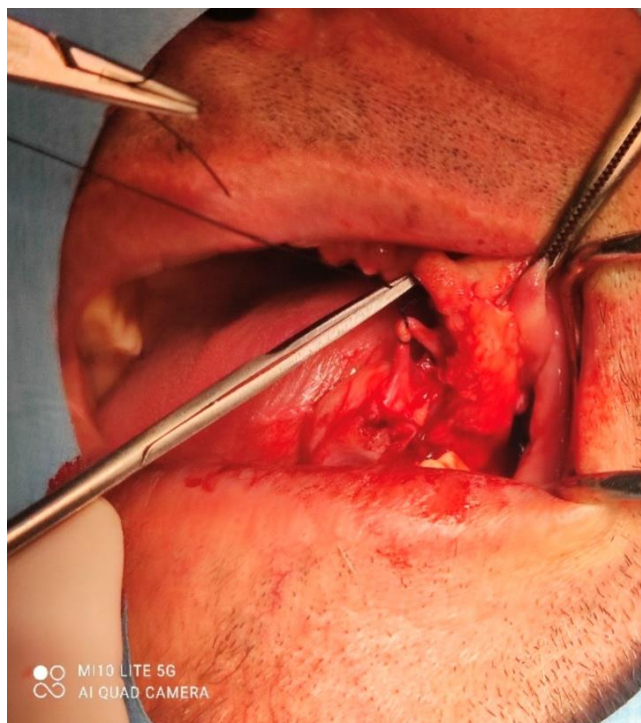Taken with the permission of the author: dr.sc. Tomislav Katanec



Picture 2. Orthopantomogram of the mandible of the patient
Taken with the permission of the author: dr.sc. Tomislav Katanec

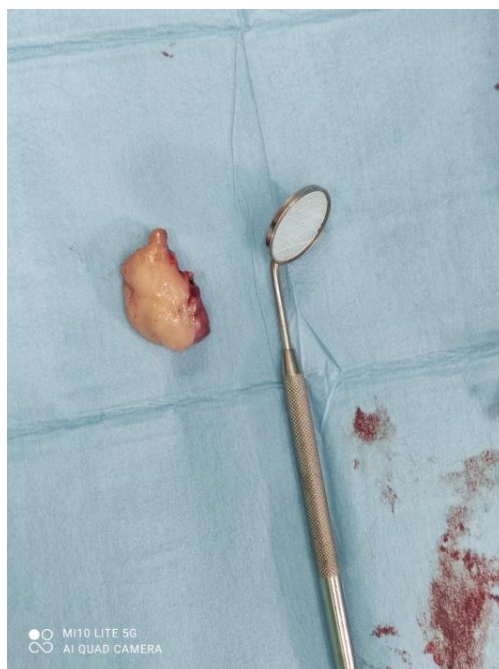


Picture 3. Mass removal
Taken with the permission of the author: dr.sc. Tomislav Katanec



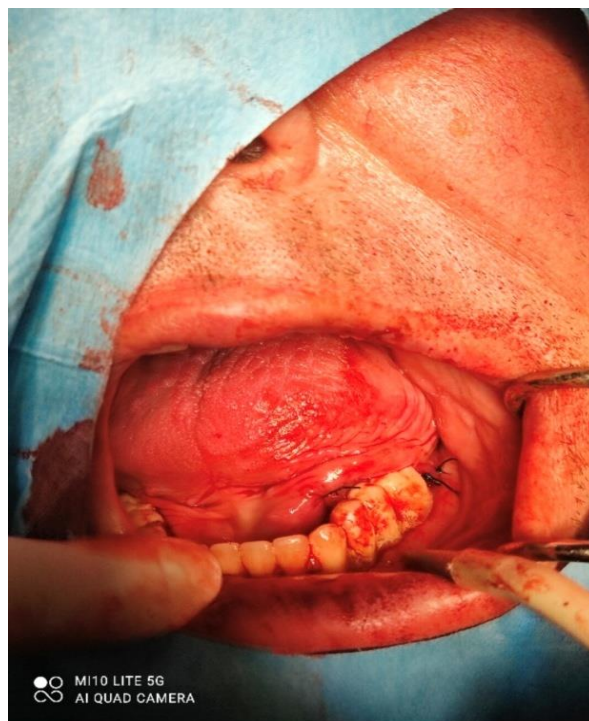
Picture 4. Ligation of the artery

Taken with the permission of the author: dr.sc. Tomislav Katanec

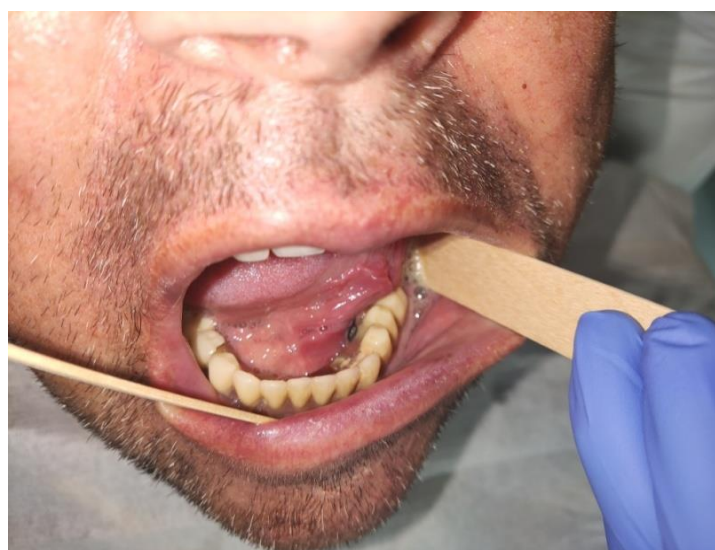

Picture 5. Size of the mass

Taken with the permission of the author: dr.sc. Tomislav Katanec

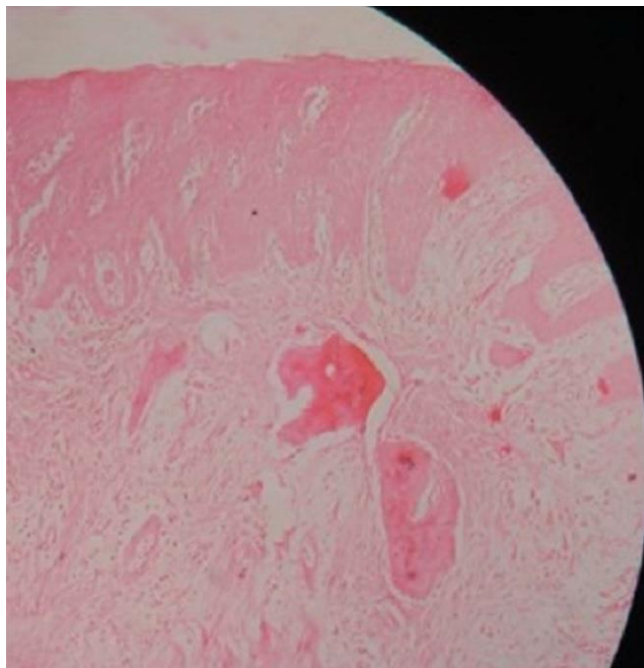


Picture 6. Condition immediately after suturing
Taken with the permission of the author: dr.sc. Tomislav Katanec



Picture 7. Suture removal seven days after the surgery
Taken with the permission of the author: dr.sc. Tomislav Katanec

The mass was sent for pathohistological (PHD) analyses, which revealed a reactively transformed multilayered epithelium beneath it, along with a significant mononuclear linear inflammatory infiltrate. Components of lichen were absent. Within the dense fiber stroma, fragments that resembled cemento-osseous lacunae were discovered. In the center of the sample, there was a small region containing gigantocellular cells and hemosiderin clusters. Unexpectedly, a tiny salivary gland with enlarged functioning ducts and multiplied intra- and interlobular tissue was discovered in the sample. A portion of the mucocele wall was also present around the sample's periphery (Picture 8).



Picture 8. Histological finding of the preparation at 4× magnification

Taken with the permission of the author: dr.sc. Tomislav Katanec

3. DISCUSSION

Peripheral ossifying fibroma (POF) is known under several other names, such as peripheral cementifying fibroma, calcifying or ossifying fibroid epulis, and peripheral fibroma with calcification. It accounts for about 3.1% of all tumors in the mouth and 9.6% of lesions found on the gums (19). Both genders are affected but in females it occurs more frequently, which is usually connected with their hormones that are deemed a predisposing factor (23). Although the precise pathogenesis of this lesion is still unknown, it is believed that the source is periodontal ligament because POS occurs only in gingiva, and the gingiva and the periodontal ligament are close to one another, with some lesions containing oxytalan fibers in their mineralized matrix (24). The cause of POF is often linked to local irritants such as poorly fitting dentures, buildup of plaque and calculus, or changes in the patient's occlusion. Whenever gingiva is injured or irritated by something else, like a foreign body, the proliferation of mature fibrous connective tissue occurs. Moreover, any form of irritation can stimulate changes in the connective tissue, leading to abnormal calcification or even formation of bone tissue (25). Peripheral ossifying fibroma is a reactive lesion that arises from the gingival connective tissue (26), while on the other hand central ossifying fibroma arises from bone and represents neoplasm with autonomous growth (27) that causes bone expansion and remodeling (28). Gardner first used the definition "peripheral ossifying fibroma" to describe a reactive lesion that is not an extraosseous part of central ossifying fibroma. (26) Peripheral ossifying fibroma usually appears in people in their twenties and thirties (29) and the female population is more prone to developing it (30). Only a small percentage is found in the older population (31). In the clinical picture, POF usually manifests as a single nodular mass of solid consistency, with color ranging from red to pink, with a broad base connected to underlying mucosa the color of which stays unchanged (21). Predilection site is the maxillary arch, especially the incisor area (17). The usual size of the mass found in the literature is around 2 cm, (21) but there was also a case in which Poon described an enormous POF measuring 9 cm (32).

Childers described a case of a 54-year-old African American man having an asymptomatic mass measuring 4.5 x 3 x 3 cm, covered by normal mucosa, not ulcerated, and exhibiting isolated foci of acute inflammation around teeth that had periodontal disease. The tumor protruded from the alveolar mucosa and was palpably hard and movable. The patient had numerous cavities, poor

oral hygiene, and generalized advanced periodontitis. According to the patient's medical history, he was currently not receiving medical attention, had no known health issues, and was not taking any drugs. The biopsy sample was sent to pathohistological analysis. The diagnosis of the lesion was POF. During a seven-month follow-up period, the patient showed successful recovery and no signs of recurrence (33). Compared to the ones reported in the literature, where POF is often defined as a mass of 2 cm in size, there is also another interesting case of a large POF measuring 9 cm (17).

Gulati described a patient, a 56-year-old woman, who complained about six months of inflamed gums around her upper front teeth, which made it difficult for her to eat and close her mouth. A single gingival mass measuring 3.5 cm × 4 cm × 3 cm was discovered during a dental exam. The mass was situated between upper canines covering the entire ridge of the jawbone with buccopalatal extension. The mass had well-defined edges, an ulcerated overlying mucosa and was reddish in color. It was also pedunculated. Panoramic imaging did not reveal any pathology. The mass was removed with 940-nanometer diode laser. The pathology report described a fibrous tissue base with scattered areas of osteoid tissue, including both mature lamellar and immature woven bone. There were also a few areas with increased growth of blood vessel lining cells and inflammatory cells. Together, these findings confirmed the diagnosis of peripheral ossifying fibroma (POF) (34).

Godinho documented the case of a 50-year-old woman who initially had a red-purple mass on gingiva near her upper first molar, measuring about 3 cm in diameter. The surface of the mass was smooth, but was bleeding upon touch, and it was initially diagnosed as a pyogenic granuloma. Three years later, the patient returned to clinic with complaints of increased size of the lesion and difficulty eating. The new examination revealed a smooth, lobular, firm nodule that was pink in color, was not bleeding, and was about 5 cm long, extending to the back of the upper jaw. After removing the tumor, histological examination confirmed it was a peripheral ossifying fibroma. The presence of calcified material, maturation of fibrous tissue, and reduced blood vessels compared to the initial lesion after three years suggested that the pyogenic granuloma had progressed into a peripheral ossifying fibroma (35).

Prasad suggested that the peripheral ossifying fibroma (POF) could have originated initially as a pyogenic granuloma (PG). Over time, as the lesion matured, it underwent ossification, resulting in the formation of bone-like material within the tissue. The progression of the same spectrum of pathosis is demonstrated by these two lesions (36).

Ogbureke documented a 44-year-old Caucasian man who had been experiencing swelling in his right posterior mandible for three months as a result of a dental implant procedure. A $45 \times 25 \times 15$ mm smooth, lobular mass was observed on gingiva of his right posterior mandible, and there was minor swelling on the outside of his face in the affected area. A panoramic X-ray showed two implants near the mass, with no other significant findings. The examination of the biopsy specimen revealed characteristics of both peripheral giant cell granuloma (PGCG) and peripheral ossifying fibroma (POF), indicating the presence of a hybrid lesion. This case challenges the distinction between PGCG and POF, as it exhibits characteristics of both conditions in nearly equal proportions. The classification of this hybrid lesion remains under debate, as it is uncertain whether it functions differently from both individual entities. It is advisable to describe more cases with pathohistological features resembling the lesion in this case in order to gain better understanding of the origin of such lesions (37).

Gaouzi presented the case of a 42-year-old woman with a large mass in the left anterior and posterior region of the mandible. The mass measured 6×4 cm in diameter. The patient did not experience any significant symptoms except for gradual increase in size of gingival mass for more than two years. Excision of the whole mass was performed and sent to pathohistological analysis that confirmed POF, which was previously misdiagnosed as peripheral myxoma. Due to the fact that a small biopsy sample might not accurately represent the nature of the lesion, the final diagnosis depends on the microscopic examination of the entire excised lesion (38).

This also represents a case report showing that POF can grow more than 2 cm than what is normally represented in literature (21).

Rallan et al. reported on a case involving a 12-year-old boy who visited the Pediatric Dentistry Department due to swollen gums around his upper front teeth. He had noticed the swelling in

creasing in size over the past month. The patient was otherwise healthy with no significant medical history. Upon intraoral examination, a smooth oval-shaped mass was observed on the palate near his upper front teeth. This mass was causing discomfort and was interfering with the boy's bite. It measured approximately 2×2 cm, appeared red, and felt firm to the touch. It was well-circumscribed. The lesion was asymptomatic and did not show any clinical evidence of ulceration. Excision of the mass was performed and sent to pathohistological analyses. Their conclusion was, based on pathohistological evaluation, that the mass is a reactive lesion of connective tissue. The patient was monitored for six months following the surgery. No signs of the lesion's recurrence were observed (39).

Agarwal et al. described a case of a 68-year-old woman, whose main complaint was a growth of soft tissue on the left side of the palate. Over time the lesion grew, starting from little nodule up to its current size. Patient did not have any significant medical or personal history. On the left side of the palate, close to the cemento-enamel junction of 26, there was a glossy, oval-shaped pink swelling. It reached the buccolingual surface of the left maxillary molars 23 to 27 anteroposteriorly, 1 cm lateral to the palate midline. The growth was non-fluctuant, pedunculated, painless, smooth and firm to rubbery in texture. Its temperature remained consistent as it grew, and there were no signs of discharge. The lesion had no impact on occlusion and measured approximately 3.5 cm mesiodistally and 2.5 cm buccopalatally. Histological findings confirmed the diagnosis of POF. Following the excision, the lesion healed very well, with no complications during the routine follow-up (40).

Nadimpalli and Kadakampally presented a case of a 23-year-old female patient with swelling in the right lower back teeth region. She said that two years ago, she had a swelling in the same location that was removed. One week ago, the swelling returned, this time larger, along with mild pain. No extraoral swelling was observed. During the intraoral exam, a small swelling measuring $6 \text{ mm} \times 5 \text{ mm}$ was found on the lingual side between the lower right first and second premolars. It appeared reddish-pink with a rough surface and clear edges. It was firm and fibrous to touch.

Histological results confirmed the diagnosis of POF (41). Since there is a possibility of 8-20% of recurrence of the lesion, early diagnosis and conservative management are essential because if left

untreated, those lesions can become even more destructive in time (42). Moreover, POF commonly affects women in their twenties, with lesions most frequently arising on the gingiva, in front of the molars, and in the maxilla. However, our case involved a 70-year-old man who had a mass in the posterior part of the mandible, which is unusual in comparison to the typical locations and gender predisposition (43).

4. CONCLUSION

We presented a case of a 70-year-old man whose histopathological results confirmed POF in the left mandible, on the lingual side. This case is interesting since the POF usually occurs in the anterior part of maxilla and it more often affects women in their twenties. Our patient did not have properly aligned occlusion on his 3-month-old acrylic bridges that could also be a predisposing factor which led to POF. The development of POF may be associated with elevated levels of parathyroid hormone, according to findings of the complete blood count. Following the surgical removal of the growth, the area healed very well. Currently, there are no indications of recurrence, and the occlusion of the existing bridges is properly aligned.

5. LITERATURE

1. Andersson L, Kahnberg KE, Pogrel A. Oral and maxillofacial surgery. 1st ed. Wiley; 2012. 1249 p.
2. Purushothaman A, Chavan NV, Sahana NS, Jayaram C, Shiragur SS, Kulkarni M. Reactive lesions of oral cavity. *J Oral Med Oral Surg Oral Pathol Oral Radiol*. 2023;9(3):175-182.
3. Lukšić I, et al. Maksilofacijalna kirurgija. Zagreb: Naklada Ljevak; 2019. 297 p.
4. Kreppel M, Zöller J. Ameloblastoma-Clinical, radiological, and therapeutic findings. *Oral Dis*. 2018;24(1):63-6.
5. Regezi JA, Sciubba J, Jordan RCK. Oral Pathology. 7th ed. Philadelphia (USA): Saunders; 2015. 496 p.
6. Thistle BL, Muela CD, Nevárez RM, Ríos BV, Nevárez RA. Aspectos descriptivos del odontoma: revisión de la literatura. *Rev. Odont. Mex*. 2016; 20(4): 272-76.
7. Sun Q, Lee JS, Kim O, et al. Primordial odontogenic tumor: a case report and literature review. *Diagn Pathol*. 2019;14:92.
8. Baser B, Kingler A, Mitra GV, Roy MT. Giant odontogenic fibroma of maxilla. *Ann Maxillofac Surg*. 2014; 4(2):211-4.
9. Thompson L. World Health Organization classification of tumours: pathology and genetics of head and neck tumours. *Ear Nose Throat J*. 2006;85(2):74.
10. Raubenheimer EJ, Noffke CE. Central odontogenic fibroma-like tumors, hypodontia, and enamel dysplasia: review of the literature and report of a case. *Oral Surg Oral Med Oral Pathol Oral Radiol Endod*. 2002;94(1):74-7.
11. Daniels JS. Central odontogenic fibroma of mandible: a case report and review of the literature. *Oral Surg Oral Med Oral Pathol Oral Radiol Endod*. 2004;98(3):295-300.
12. Greenspan A. Benign bone-forming lesions: osteoma, osteoid osteoma, and osteoblastoma. Clinical, imaging, pathologic, and differential considerations. *Skeletal Radiol*. 1993;22(7):485-500.
13. Tepelenis K, Skandalakis GP, Papathanakos G, Kefala MA, Kitsouli A, Barbouti A, Osteoid Osteoma: An Updated Review of Epidemiology, Pathogenesis, Clinical Presentation, Radiological Features, and Treatment Option. *In Vivo*. 2021;35(4):1929-38.
14. More CB, Gupta S. Osteochondroma of mandibular condyle: A clinic-radiographic correlation. *J Nat Sci Biol Med*. 2013;4(2):465-8.

15. Su L, Weathers DR, Waldron CA. Distinguishing features of focal cemento-osseous dysplasia and cemento-ossifying fibromas. II. A clinical and radiologic spectrum of 316 cases. *Oral Surg Oral Med Oral Pathol Oral Radiol Endod.* 1997;84(5):540-9.
16. Nam I, Ryu J, Shin SH, Kim YD, Lee JY. Cemento-osseous dysplasia: clinical presentation and symptoms. *J Korean Assoc Oral Maxillofac Surg.* 2022;48(2):79-84.
17. Neville BW, Damm DD, Allen CM, Bouquot JE. *Oral and Maxillofacial Pathology.* Philadelphia(USA): WB Saunders. 1995; 376 p.
18. Nilesh K, Punde P, Patil NS, Gautam A. Central ossifying fibroma of mandible. *BMJ Case Rep.* 2020;13(12)
19. Bhasin M, Bhasin V, Bhasin A. Peripheral ossifying fibroma. *Case Rep Dent.* 2013;2013:497234.
20. Maturana-Ramírez A, Adorno-Farías D, Reyes-Rojas M, Farías-Vergara M, Aitken-Saavedra J. A retrospective analysis of reactive hyperplastic lesions of the oral cavity: study of 1149 cases diagnosed between 2000 and 2011, Chile. *Acta Odontol Latinoam.* 2015;28(2):103-7.
21. Buchner A, Hansen LS. The histomorphologic spectrum of peripheral ossifying fibroma. *Oral Surg Oral Med Oral Pathol.* 1987;63(4):452-61.
22. Pal S, Hegde S, Ajila V. The varying clinical presentations of peripheral ossifying fibroma: A report of three cases. *Revista Odonto Ciencia.* 2011; 27(3):251-55.
23. Kenney JN, Kaugars GE, Abbey LM. Comparison between the peripheral ossifying fibroma and peripheral odontogenic fibroma. *J Oral Maxillofac Surg.* 1989;47(4):378-82.
24. Kumar SK, Ram S, Jorgensen MG, Shuler CF, Sedghizadeh PP. Multicentric peripheral ossifying fibroma. *J Oral Sci.* 2006;48(4):239-43.
25. Miller CS, Henry RG, Damm DD. Proliferative mass found in the gingiva. *J Am Dent Assoc.* 1990;121(4):559-60.
26. Gardner DG. The peripheral odontogenic fibroma: an attempt at clarification. *Oral Surg Oral Med Oral Pathol.* 1982;54(1):40-8.
27. Waldron CA. Fibro-osseous lesions of the jaws. *J Oral Maxillofac Surg.* 1993;51(8):828-35.
28. Eversole LR, Leider AS, Nelson K. Ossifying fibroma: a clinicopathologic study of sixty-four cases. *Oral Surg Oral Med Oral Pathol.* 1985;60(5):505-11.

29. Bodner L, Dayan D. Growth potential of peripheral ossifying fibroma. *J Clin Periodontol.* 1987;14(9):551-4.
30. Cuisia ZE, Brannon RB. Peripheral ossifying fibroma--a clinical evaluation of 134 pediatric cases. *Pediatr Dent.* 2001;23(3):245-8.
31. Effiom OA, Adeyemo WL, Soyele OO. Focal Reactive lesions of the Gingiva: An Analysis of 314 cases at a tertiary Health Institution in Nigeria. *Niger Med J.* 2011;52(1):35-40.
32. Poon CK, Kwan PC, Chao SY. Giant peripheral ossifying fibroma of the maxilla: report of a case. *J Oral Maxillofac Surg.* 1995;53(6):695-8.
33. Childers EL, Morton I, Fryer CE, Shokrani B. Giant peripheral ossifying fibroma: a case report and clinicopathologic review of 10 cases from the literature. *Head Neck Pathol.* 2013;7(4):356-60.
34. Gulati R, Khetarpal S, Ratre MS, Solanki M. Management of massive peripheral ossifying fibroma using diode laser. *J Indian Soc Periodontol.* 2019;23(2):177-180.
35. Godinho GV, Silva CA, Noronha BR, Silva EJ, Volpato LE. Peripheral Ossifying Fibroma Evolved From Pyogenic Granuloma. *Cureus.* 2022;14(1):e20904.
36. Prasad S, Reddy SB, Patil SR, Kalburgi NB, Puranik RS. Peripheral ossifying fibroma and pyogenic granuloma. Are they interrelated? *N Y State Dent J.* 2008;74(2):50-2.
37. Ogbureke EI, Vigneswaran N, Seals M, Frey G, Johnson CD, Ogbureke KU. A peripheral giant cell granuloma with extensive osseous metaplasia or a hybrid peripheral giant cell granuloma-peripheral ossifying fibroma: a case report. *J Med Case Rep.* 2015;9:14.
38. El Gaouzi R, Benjelloun L, El Ouazzani H, Cherradi N, Chbicheb S. A giant peripheral ossifying fibroma of the mandible: A rare case report. *Int J Surg Case Rep.* 2024;114:109161.
39. Rallan M, Pathivada L, Rallan NS, Grover N. Peripheral ossifying fibroma. *BMJ Case Rep.* 2013;2013:bcr2013009010.
40. Agarwal P, Chug A, Kumar S, Jain K. Palatal peripheral ossifying fibroma: A rare occurrence. *Int J Health Sci (Qassim).* 2019;13(4):63-66.
41. Nadimpalli H, Kadakampally D. Recurrent peripheral ossifying fibroma: Case report. *Dent Med Probl.* 2018;55(1):83-86.
42. Buduneli E, Buduneli N, Unal T. Long-term follow-up of peripheral ossifying fibroma: report of three cases. *Periodontal Clin Investig.* 2001;23(1):11-14.

43. Marx RE, Stern D. Oral and maxillofacial pathology: a rationale for diagnosis and management. Chicago: Quintessence Pub Co; 2003.

6. BIOGRAPHY

Iva Burazin was born on September 14th, 1998 in Zagreb where she finished elementary school “Petar Zrinski” and secondary education in XVI. Gymnasium. She enrolled at the School of Dental Medicine in Zagreb in 2017. During her studies, she assisted in a few dental clinics and participated in various congresses. In 2024, she was an active member of the 7th Symposium of Dental Medicine Students where she presented the Esthetic Analysis and Digital Smile Design workshop.