

Prosthodontically Driven Dental Implant Therapy - Chairside Protocol

Slana, Pia

Master's thesis / Diplomski rad

2024

Degree Grantor / Ustanova koja je dodijelila akademski / stručni stupanj: **University of Zagreb, School of Dental Medicine / Sveučilište u Zagrebu, Stomatološki fakultet**

Permanent link / Trajna poveznica: <https://um.nsk.hr/um:nbn:hr:127:426875>

Rights / Prava: [Attribution 4.0 International](#)/[Imenovanje 4.0 međunarodna](#)

Download date / Datum preuzimanja: **2024-07-24**



Repository / Repozitorij:

[University of Zagreb School of Dental Medicine
Repository](#)





University of Zagreb
School of Dental Medicine

Pia Slana

**PROSTHODONTICALLY DRIVEN
DENTAL IMPLANT THERAPY –
CHAIRSIDE PROTOCOL**

GRADUATE THESIS

Zagreb, 2024

The thesis was carried out at: Department of Fixed Prosthodontics, School of Dental Medicine, University of Zagreb

Thesis mentor: Assoc. Prof. Joško Viskiće, PHD, DMD, Department of Fixed Prosthodontics, School of Dental Medicine, University of Zagreb

English language proofreader: Klemen Jelinčić Boeta, PhD, translator and writer

Croatian language proofreader: Ana Jelinić, prof. of Croatian language and literature

The manuscript contains: 45 pages

1 table

0 pictures

The paper is an author's own work, which is completely independently written with an indication of the sources of other authors and documents used in the paper. Unless otherwise stated, all illustrations (tables, pictures, etc.) in the paper are the original contribution of the author of the thesis. The author is responsible for obtaining permission for the use of illustrations that are not his original contribution, as well as for any possible consequences that may arise due to unauthorized downloading of illustrations or failure to indicate their origin.

Acknowledgements

I would like to thank my mentor, Assoc. Prof. Joško Viskić, PHD, DMD, for his assistance, patience and guidance throughout writing my thesis.

My deepest gratitude goes to my family. My beloved parents, I am grateful for your unwavering belief in me, your support, and the opportunity and luxury you have provided me with to pursue my studies. Thank you for teaching me the values of perseverance and self-worth and for always encouraging me to believe in my abilities. Your guidance has shaped me into the person I am today.

To my dear brother Ian, thank you for setting an exceptional example and reminding me that I am never alone by consistently providing me with unwavering support. I am deeply thankful for your presence in my life.

I would like to extend my appreciation to my university friends who have journeyed with me through these past six years of hard work and dedication. Your friendship has been invaluable, making this journey enjoyable and memorable.

Last but not least, to my dear Žan, thank you for always being there for me.

PROSTHODONTICALLY DRIVEN DENTAL IMPLANT THERAPY – CHAIRSIDE PROTOCOL

Summary

With increased demand for aesthetics and the evolution of digital technology in dentistry, a new concept of implant therapy was introduced, called the prosthodontically-driven implant therapy. This new approach focuses on the final restoration and employs a backward planning strategy to allow for design and material selection prior to dental implant surgery. The use of digital technologies, including intraoral scanners and cone beam computed tomography (CBCT), has provided dentists with three-dimensional data that allows for the virtual modelling of anatomical structures. This information is then used to determine the optimal implant position with the aid of virtual implant planning software. The use of a surgical guide facilitates the transfer of this position into the patient's mouth, leading to more precise implant placement and improved outcomes. Following successful implantation, final restoration production can be carried out in a chairside manner with the aid of computer-aided design (CAD) and computer-aided manufacturing (CAM) systems. This approach reduces treatment time and streamlines the workflow while also improving communication with patients through the visualization of the future prosthetic restoration, enhancing motivation and compliance.

Keywords: digital dentistry; digital workflow; chairside protocol; guided implant placement; surgical guide; CAD/CAM; implant-supported restoration; zirconium oxide ceramics; lithium disilicate; speed sintering

PROTETSKI VOĐENA IMPLANTOPROTETSKA TERAPIJA – CHAIRSIDE PROTOKOL

Sažetak

S porastom potražnje za estetikom i razvojem digitalne tehnologije u stomatologiji, uveden je novi koncept implantološke terapije, nazvan protetski vođena implantoprotetska terapija. Novi pristup fokusira se na konačnu restauraciju i primjenjuje strategiju planiranja unatrag kako bi se omogućio dizajn i odabir materijala prije kirurškog zahvata ugradnje implantata. Korištenje digitalne tehnologije, uključujući intraoralne skenere i konusno snimanje računalnom tomografijom (CBCT), olakšalo je stomatolozima prikupljanje trodimenzionalnih podataka koji omogućuju virtualno modeliranje anatomskih struktura. Dobivene informacije se potom koriste za određivanje optimalnog položaja implantata uz pomoć softvera za virtualno planiranje postavljanja implantata. Upotreba kirurške šablone omogućuje prijenos tog položaja u usta pacijenta, što dovodi do preciznije ugradnje implantata i boljih ishoda. Nakon uspješne ugradnje implantata, konačna restauracija može se izraditi u jednom terminu uz pomoć sustava za računalno potpomognuto projektiranje (CAD) i računalno potpomognutu proizvodnju (CAM). Ovaj pristup smanjuje vrijeme liječenja i pojednostavljuje radni tijek, istodobno poboljšavajući komunikaciju s pacijentima kroz vizualizaciju buduće protetske restauracije, čime se povećava motivacija i suradnja pacijenata.

Ključne riječi: digitalna stomatologija; digitalni tijek rada; chairside protokol; vođena implantacija; kirurška šablona; CAD/CAM; restauracija podržana implantatima; cirkonij oksidna keramika; brzo sinteriranje

Table of Contents

1. INTRODUCTION.....	1
1.1. The aim of thesis	2
2. EVOLUTION OF DENTAL IMPLANTS.....	3
2.1. History and concept of implant placement	4
2.2. Osseointegration	4
2.3 Implant properties.....	5
2.3.1. Materials	5
2.3.2. Shapes and dimensions	5
2.3.3. Components	6
3. PROSTHODONTICALLY DRIVEN DENTAL IMPLANT THERAPY	8
3.1. Intraoral and extraoral scanning.....	9
3.2. Digital wax-up.....	10
3.2.1. Digital smile design – DSD	10
3.3. CBCT.....	11
3.4. Virtual implant planning	11
3.5. Surgical guide design	12
3.6. Surgical guide production	13
3.6.1. 3-D printing	13
3.6.2. Milling.....	14
3.7. Guided surgical implant placement.....	14
4. CHAIRSIDE PROTOCOL FOR IMPLANT-SUPPORTED RESTORATION.....	16
4.1. Digital impression.....	17
4.1.1. Scan body	18
4.2. Chairside CAD-processing	19
4.2.1. Computer-Aided Design software	19
4.2.2. Virtual design	20
4.3. Chairside CAM-processing	20

4.3.1. Milling machine	21
4.4. Materials for chairside CAD/CAM restorations	22
4.4.1. Infiltrated ceramics	23
4.4.2. Silicate ceramics	24
4.4.3. Oxide or polycrystalline ceramics	24
4.5. Post-processing of final restoration	26
4.5.1. Sintering.....	26
4.5.2. Surface treatments	27
4.6. Prosthodontic rehabilitation – cementation or screw-retained fixed prosthesis	28
5. DISCUSSION.....	30
6. CONCLUSION	35
7. LITERATURE	37
8. BIOGRAPHY.....	44

List of abbreviations:

CBCT – cone-beam computer tomography

3-D – three-dimensional

2-D – two-dimensional

CAD – computer-aided design

CAM – computer-aided manufacturing

DSD – digital smile design

CT – computer tomography

DICOM – digital imaging and communications in medicine

STL – standard tessellation language

SLA - stereolithography

DLP – digital light processing

SLS – selective laser sintering

UV - ultraviolet

CNC – computer numerical control

PEEK – polyether-ether-ketone

CEREC – chair-side economical restoration of aesthetic ceramic

Y-TZP – yttrium-stabilized zirconia polycrystals in tetragonal phase

3Y – 3 mol % yttria

4Y – 4 mol % yttria

5Y – 5 mol % yttria

1. INTRODUCTION

Dental implantology is one of the treatment options for replacement of missing teeth. It has made a great impact on patient's quality of life, improving functional, anatomical as well as aesthetic demands. It is considered an integral part of dentistry, with long-term success owing to its biocompatibility and longevity (1,2). With the goal of delivering a basis for future prosthodontic restoration placement, it has many advantages, such as maintenance of the remaining alveolar bone, stabilization of occlusion, normal occlusal loading with increased masticatory efficiency, and better phonetics, which makes it superior in comparison to other forms of prosthodontic rehabilitation (3). Major developments in the field of dental implantology have made it accessible not only to specialists but also to other dental practitioners with different levels of skills and expertise. With the use of digital technologies, operator mistakes and unwanted consequences, such as drilling through the bone, damage to nerves and blood vessels, injury to neighboring teeth, and perforation of the maxillary sinus can be minimized (4).

The concept of prosthodontically driven dental implant therapy with the help of modern digital technologies points out a fundamental shift. The focus is now directed on definitive prosthodontic results, not on the placement of dental implants. This approach makes it much more accurate when planning and executing surgical implant placement, providing all the requirements for future prosthetic restoration to be placed where it is needed, regardless of the anatomical and physiological characteristics of the implantation site (3).

Digitalization has enabled the manufacturing of final implant-supported dental prostheses without the use of a dental laboratory. This provides great benefits by reducing the patient's clinical visits and making the technical fabrication process much faster (5).

1.1. The aim of thesis

In my thesis, I intend to evaluate and present all the steps of prosthetically guided implant surgery in terms of planning, fabrication, and delivery of fixed implant-supported prosthetic restorations. By examining the advancements in dental implantology, I aim to demonstrate how these developments have led to more predictable outcomes. Additionally, I will discuss the materials that are suitable for chairside processing. The primary objective is to present these steps without the requirement for a dental laboratory, while simultaneously providing patients with high-quality care in a more efficient manner.

2. EVOLUTION OF DENTAL IMPLANTS

2.1. History and concept of implant placement

The use of dental implants to replace missing teeth was first discovered many years ago. Ancient Egyptians in 2500 BC and later Mayan nations were the first civilizations to use different methods and materials for replacing teeth in distinct forms. Over the years, there were many attempts to develop techniques and materials, but the modern and advanced method was discovered hundreds of centuries later. The only part that remained constant over time was a precise and detailed patient examination to provide the best possible solutions for their main complaint – the replacement of missing teeth with a long-term success (1,6).

In 1978, Dr. P. Brånemark presented a conventional protocol for dental implant therapy with two-phase threaded implants made of titanium, which were screwed with fixtures in his patients. It was observed that the titanium implant surface bonded with the bone, which brought a new theory called osseointegration. This protocol, presented by dr. Brånemark was based on the belief that in order to achieve successful osseointegration, a dental implant can only be placed at least six months after the tooth was extracted at the implantation side for the purpose of the healing period to take place. Nowadays, evidence exhibits that dental implants can be placed at different time periods following tooth extraction with similar outcomes comparing early placement to delayed one. However, the latter may still offer a slightly increased survival rate in some cases (6–8).

Within the last 30 years, implant placement has been considered the preferred method of tooth replacement due to its predictability, reliability and long-term success. Following the development of zirconium implants, it has shown an improved degree of osseointegration and response of soft tissue over titanium as the material of choice. With advances in technology, appropriate 3-D imaging techniques have been developed. CBCT or Cone Beam Computed Tomography uses 3-D images from different planes for the purpose of planning and positioning dental implants, leading to precise delivery of implants and, consequently, better prognosis (6).

2.2. Osseointegration

In contemporary dentistry, substantial advancements have been achieved in the restoration of lost teeth with dental implants. This progress can be attributed to enhancements in diagnosing, planning, and execution of implantation procedures, as well as advancements in materials and their structural modifications to improve long-term success rates. Among these factors, osseointegration remains the cornerstone in determining the success of dental implants, as it refers to “the direct structural and functional connection between living bone tissue and the

surface of the load-bearing, endosseous implant at the light microscopic level". This term was first introduced by Dr. Brånemark, and numerous attempts have been made to define it, but none have taken into account the quality of newly formed bone (9).

The healing of dental implant installation in the early phase plays an important role in long-term success. The entire osseointegration process begins with primary stability immediately after implantation. From the start, the surface of the implant is mechanically fixated by contacting the bony walls of the implant bed. After some time, secondary stability starts building up with the formation of new bone around the implant surface. This bonding is biological, compared to the primary stability, which is purely mechanical. In the transition period, approximately 3-4 weeks after implant placement, a decrease in stability of the implant is expected due to the loss of primary stability. This gradually increases with the apposition of trabecular and cortical bone, with the latter taking more time because it needs to be resorbed first. A good ratio between the cortical and trabecular bone is desirable at the site where the implant is planned to be placed (10).

2.3 Implant properties

2.3.1. Materials

Titanium has long been considered the standard material for dental implants due to its durability and biocompatibility. It is commonly used in its pure form, known as commercially pure titanium, or in combination with other metals. The most commonly used titanium alloy in medical applications is Ti-6Al-4V, which is a combination of titanium, aluminium, and vanadium. This alloy has excellent mechanical properties and is widely used in the medical field. However, with the increasing demand for aesthetic implants, zirconium implants have also been introduced as a viable alternative. Zirconium implants have a better soft tissue response; they are more biocompatible and present with a natural-looking appearance compared to titanium dental implants; therefore, they are increasingly being used in aesthetic dentistry. Their main disadvantage is fracture in the early stages of implant healing, which is a critical factor to consider before they can replace titanium (11,12).

2.3.2. Shapes and dimensions

Implants come in three different shapes which are cylindrical, conical and hybrid designs. Depending on manufacturers, implants have different modifications of shape and dimensions

(13,14). Additionally, they can have V-shaped or square threads. Each design achieves different levels of primary stability, the best being with conical and hybrid shapes. The conical ones are anchored by compression of the bone in vertical and lateral directions. They present multiple advantages, such as easy use, reduced order of drillings, low level of surgical trauma and decrease in healing time, which makes them very popular to use (14,15). As they might present superior properties for implantation, shape by itself has shown there is no effect on implant survival (15).

Macro-design of dental implants is also defined with different lengths and diameters. There is still no clear classification to categorize implants with different lengths and diameters, defining if they are accepted as long or short and narrow or wide. It is proposed that based on the length, short ones are defined by less than 15 mm and long ones more than that, whereas the diameter can range from less than 2.5 mm, classifying them as mini-implants, and up to 5 mm and more are classified as wide ones (14,16). Depending on the condition and dimensions of the bone where implantation is going to be performed, the dental implant macro-design is chosen individually for the patient with respect to the biomechanical loading (13,14). Biomechanics are taken into account at the planning phase of the treatment to ensure that the bone surrounding the implant is not over-loaded. This is achieved by the assessment of bone properties, which will ensure better long-term results (13).

2.3.3. Components

Dental implants can be classified based on the number of components. They can be defined as one-piece or two-piece dental implants. The latter has a separated implant body and abutment screw, whereas one-piece has these two elements combined together. The implant body is screwed into the bone and provides anchorage, while the abutment screw serves as the connection between the implant and abutment or final prosthetic restoration (3).

At the beginning of dental implantology, two-piece implants were introduced first. This concept was designed for surgical procedures done in two steps. In the first surgical procedure, a flap was raised, followed by implant placement into the bone and repositioning the flap over the implant to allow healing. After that period, in the second surgical procedure, a new flap was raised, and the abutment screw was retained to the implant, which later allowed prosthetic restoration placement.

For simplification, the design was modified by introducing a one-piece dental implant. This increased the efficiency of treatment and the comfort of the patient. The one-piece implant

design has a combined implant body and abutment screw, which reduces surgical time, but also provides other advantages, such as decreased microorganism colonization due to the absence of microgaps, as presented in two-piece implant systems (17).

3. PROSTHODONTICALLY DRIVEN DENTAL IMPLANT THERAPY

In addition to conventional implant planning, advancements in digital implantology and prosthodontics rely heavily on extensive diagnostics and detailed 3-D planning. This evolution in radiographic modalities with the incorporation of computer software has provided the ability to observe and interpret structures exactly as they would be seen in reality. This is necessary to ensure that both the patient's and dentist's expectations are met and the desired outcome is achieved. In the past, planning was limited by 2-D radiographic imaging. Lack of technology provided incomplete information regarding bone features; therefore, inadequate data about future implantation sites could be attained, which greatly impacted clinical outcomes. With the use of three-dimensional radiographically acquired data, planning has become much simpler and more accurate, allowing for the prediction of prosthetic outcomes virtually before the final position of the dental implant is determined. The obtained 3-D imaging data are required not only for virtual implant planning but also for computer-aided design (CAD) and computer-aided manufacturing (CAM) of the surgical implant guide. This results in a more prosthodontically driven coordination of implant positioning. Based on these features, planning is defined as backward planning because everything will be adjusted to the final prosthodontic restoration. One of the significant benefits of digital planning is that it allows patients to actively participate in the visualization of their final treatment outcome, as they are able to view the final result prior to the completion of treatment. This increases patients' reassurance, which helps in the elimination of incorrect expectations and further disappointment of patients, from which dentists greatly benefit (18–21).

3.1. Intraoral and extraoral scanning

The first step in 3-D planning involves obtaining the data from the patient's mouth. It can be performed using conventional impression taking or digitally with intraoral scanning. This transfers information to the dental model. Nowadays, an increasing number of dentists prefer the digital method not only because it presents with less discomfort for the patient but also because it provides equal if not better dimensional accuracy due to the lack of impression material used, and therefore, no risk of material deformation is presented. If the conventional method is used, the models that are produced must be scanned extraorally to obtain the data in digital form. This method is time-consuming because it includes additional steps and, consequently, additional costs before digitalizing the model. The impression must be sent to the dental laboratory, where the dental technician scans the physical model and acquires a virtual

one. It must be taken into account that every extra step that needs to be done will decrease the precision of the final restoration or accuracy in the planning phase owing to human error (22). Intraoral scanning is a technique for capturing direct optical impressions of dental and gingival surfaces. The intraoral scanner projects a light source onto the area to be scanned, and imaging sensors capture the surfaces. The surfaces are then processed using scanning software to produce 3-D models (23).

3.2. Digital wax-up

After obtaining a digital model of the patient's teeth and surrounding structures, dental technicians or dentists can design future restorations using a digital wax-up. It is a technique that substitutes the traditional wax-up performed on the plaster model. Its purpose is to select the ideal treatment option based on functional, occlusal, and aesthetic criteria and consequently enhance communication between the dentist and patient (24).

3.2.1. Digital smile design – DSD

With the increase in aesthetic demands, patients' main priority became how their smile looks. Smile influences social interactions with non-verbal communication. Therefore, due to advancements in digital dentistry, digital smile design is a software that is used to analyze and create the best possible aesthetic solution for every individual patient. The software analyses patients' photographs to get the best relationships between teeth, gingiva, lips, facial lines and smiles. Facial features are the most important factors for planning aesthetic re-design of the smile, which are symmetry, profile and proportions of the face and facial structures. It is used in multiple dentistry branches, such as orthodontics, periodontology, and orthognathic surgery and therefore is also indispensable in backward planning for prosthodontically driven dental implant therapy (25). There are multiple digital smile design software packages, but they all follow the same basic procedure. After obtaining high-quality photographs, reference lines are drawn on digital photos. The dentogingival analysis defines the desired curve of the smile, which can be influenced by the incisal edges of the maxillary anterior teeth. Depending on aesthetic requirements, changes are made with the help of a digital ruler, which needs to be calibrated by measuring the width of the central incisors. After completion of the digital design, the patient is presented with the final outcome in 2-D on the computer. It can also be used to produce a physical 3-D wax-up if the patient wants to see the final results in their mouth. Wax-

up can be performed in a conventional way or with the use of a digital mock-up design, followed by production using a CAD-CAM system to print or mill it (26).

3.3. CBCT

Cone-beam computed tomography (CBCT) is a digital volume tomography device that employs an X-ray tube and an imaging detector to capture and reconstruct the patient's anatomy in three dimensions. The X-ray tube is positioned on one side of the patient, while the imaging detector is placed on the other side. The latter measures attenuated X-rays while both rotate around the head of the patient. The resulting image data were provided in digital form, thereby reconstructing the captured anatomy in three dimensions. The use of CBCT has become prevalent in implant dentistry, especially because of its accuracy and reduced exposure to radiation compared to traditional computed tomography (CT) methods (27).

In daily dental offices, radiographic imaging has become an indispensable tool for diagnosis and treatment planning. In implant dentistry, CBCT is a prerequisite for proper diagnosing and surgical planning because of its ability to obtain detailed and extensive image data of the maxillofacial region in 3-D. In addition to its superiority in 3-D details, it also offers the potential for planning and designing surgical guides for implant placement and further prosthetic rehabilitation in conjunction with computer-aided design (CAD) and computer-aided manufacturing (CAM) techniques. CBCT alone presents with limited spatial and contrast solutions; therefore, it needs to be combined with digital models of teeth obtained with digital intraoral scanning. When this is done, the result is the creation of a computer-generated dental patient on which we can virtually place the implant (28,29).

3.4. Virtual implant planning

Computer-generated dental patient is made with the help of virtual implant planning software. It reproduces important anatomical structures and positions, such as the dentition and alveolar ridge (28). The amount of detail for precise planning elevates treatment success by eliminating surgical risks and placing implants in the exact position (30). To acquire a virtual model, CBCT and intraoral imaging data were combined (28). CBCT provides three-dimensional data in DICOM format, while STL data is from an intraoral scan or extraoral scanning of the plaster model (18). Considering the positioning of dental implants for prosthodontically driven virtual planning, implants are not designed to be placed where we have sufficient bone, but it takes into consideration the ideal fabrication position for future restoration. Therefore, after precise

design, software planning can adapt and produce surgical implant guides based on virtual patients using manufacturing and printing tools (31).

3.5. Surgical guide design

Complications of implant placement surgery are usually a consequence of iatrogenic damage. They are caused by incorrect diagnosis, treatment plan, surgical method, and implant placement (32). Due to the ageing of the population, demand for dental implants is increasing rapidly, pointing out the necessary improvements in surgical precision, therefore increasing the success rate and reduction of trauma from surgery to the minimum (33). To overcome these challenges, surgical guides were introduced. They are described as surgical templates, which help the clinician to angulate and place the dental implant in the foreseeable position. To secure a high success rate of surgical procedure execution, it is necessary to use the CBCT radiographic method, 3-D implant planning software and software for the design and production of surgical guide (32). There are multiple planning systems for designing surgical guides. Based on the software that is used, the aforementioned guide can be designed individually by a software operator, or data can be sent to the designing and production centers, where they plan and produce it. Designing surgical guides individually can be much more convenient for the operator. In terms of adaptability, the user can define the direction of insertion by eliminating undercut areas, which are automatically faded out or blocked out virtually. This is followed by selection of surfaces the guide will bear with additional fixation by use of fixation screws, design of the sleeves, the thickness of the material and tolerance between teeth and the guide. All these features have an influence on the accuracy of dental implantation (20,33).

According to the type of support, surgical guides are defined as bone-supported, tooth-supported, mucosa-supported and whichever combination. The best one is tooth-supported bilaterally due to its high retention and stability provided by anchorage on dental hard tissues, but it can only be used in patients who have teeth present mesially and distally to the implantation area. Overall accuracy decreases with decreased number of teeth, so other types of support guides are usually used in combination with fixation screws to avoid displacement during surgery.

The design of the sleeves provides assistance for drilling the hole, indicating the direction, depth and angle for the implant. They are defined as open or closed sleeves. Ideally, closed sleeves are used, but if the implant is planned in the posterior area, the appropriate one is the open type for easier manipulation during implantation due to the limited opening of the mouth and

decreased space between dental arches. For the preparation of the implant hole, the drill should be centrally positioned and parallel to the sleeves' wall. Additionally, implant accuracy is also influenced by the material of the sleeves. They can be made of metal or plastic, with the latter providing lower deviations in angle, depth and placement (33).

After finalizing the design, software displays the virtual model with the surgical guide, which is then exported in STL format for manufacturing in the dental office (20).

3.6. Surgical guide production

A virtually planned surgical guide provides a direct connection between the treatment plan and surgery by transferring an accurate plan to the implantation site (32). They can be produced by an additive method, known as 3-D printing, or by a subtractive method, called CAD/CAM milling. The degree of accuracy between these two approaches continues to be a subject of discussion. However, at present, they have exhibited comparable levels of precision (33,34).

3.6.1. 3-D printing

With advances in technology, 3-D printing has gained considerable popularity in dentistry as well. It has a wide range of applications, from surgical guide production to the fabrication of a framework for dental prosthetic reconstruction (35). This technique is increasingly applied because of its many advantages, including a reduction in surgical time and an increase in successful outcomes (36).

As previously mentioned, 3-D printing is an additive manufacturing process that operates by layering the material, resulting in the formation of an object. This is commonly described as a rapid prototyping technique. There are multiple 3-D printing modalities available with the use of different materials. The most commonly used technologies for the production of implant surgical guides are stereolithography (SLA), digital light processing (DLP) and selective laser sintering (SLS) (35).

Stereolithography is a high-cost technology in which a machine with a vat uses a laser to scan and build one layer of material at a time. The laser is attached to top part of the vat and it moves in cross-sections for 1 mm. After every layer, the platform descends and the process is repeated. The desired surgical guide is made from a light-cured photopolymer resin. When the object is completed, it is not fully polymerized; therefore, it is post-processed in a UV light-curing unit to harden completely (32,35).

Digital light processing is another technique that uses light-cured resin. While the processing is quite similar, the main difference between DLP and SLA is that the latter can produce 3-D objects with a higher resolution but is, therefore, much slower (35,37).

The third commonly used method is selective laser sintering, which uses sintered powder obtained from a heated polymer with high melting points for the production of an object. This material is heated just below the melting temperature, transforming it into a powder, which is then fused using a scanning laser. This forms an evenly spread layer, and the process is repeated until the object is finished. The biggest advantage of this method is that polymers used in SLS processing are heat-resistant, which allows them to be sterilized in an autoclave (35).

3.6.2. Milling

Another accepted method for surgical guide production is milling, which is described as a subtractive method. Compared to the 3-D printing technique, it provides equivalent accuracy in terms of implant positioning (38). In terms of surgical guide deformation, milling is superior to 3-D printing because the material does not change its structure during production, making it more stable (34,39).

The subtractive method is described as a technique for the production of a desired objects that removes the material from the initial block. Milling involves the removal of material by cutting with a component of the milling machine, which may either rotate around the material block or remain stationary while the material block rotates around it, resulting in grinding. With technological developments, control of the process comes from the computer, which dictates the movement of the machine to produce an accurate and precise surgical guide from a virtually planned geometry. This technology combines computer software directly with the milling machine and is called computer numerical control (CNC) (40).

3.7. Guided surgical implant placement

After precise implant planning and surgical guide production, guided surgery for implant placement is performed. Owing to its numerous benefits, this surgical approach has received increased attention in recent years (4). Nevertheless, despite its enticing potential, the use of this method is significantly constrained in individuals with inadequate bone density and uneven alveolar ridges (41).

Prior to surgery, accurate positioning of the surgical guide in the mouth must be verified. The planned surgical placement is secured only if the guide fits precisely into the mouth. There are

two approaches to accessing the bone surface where the implant is placed. The flap can either be reflected, or the clinician can use the flapless technique, where the tissue is perforated without elevation of the periosteum (18). There are multiple advantages to the flapless approach, considering less pain and swelling postoperatively and also a reduction in surgery duration (42,43).

Unlike conventional or freehand implant positioning, guided surgery can be performed using either a partially or fully navigated technique. In partially guided implant surgery, a surgical guide is used in the first stage of implantation, considering the underlying morphology of the bone for the purpose of positioning and direction of the implant, which strictly follows the prosthetic plan. The remaining implant placement is performed free-hand. Guides have different designs depending on their purpose. They can be used for initial bone cutting and reshaping to open the bone where the implant will be placed or for complete adjustment of the bone to fully regulate the implant in its entire length. In the fully guided approach, the surgical guide is fabricated with restrictions to achieve a completely prosthodontically driven treatment plan (43). These restrictions are applied through metal sleeves incorporated in the surgical template, which dictate the angulation and depth of the implant-bone relationship (44). Bone reshaping and remodeling, along with implant placement, are fully controlled by a predetermined virtual plan (43).

Fully guided dental implant surgery, widely regarded as the most precise method for placing implants, may nonetheless result in deviations from the intended position owing to errors in processing virtual imaging data, inaccurate design and guide production, instability of the template during surgery, and potential errors on the part of the clinician. All these issues only serve to amplify the inaccuracies stemming from the initial mistake that arises (44).

After the implant is placed, depending on the treatment plan, the flap can be sutured together for the healing period to begin, or in case of immediate loading, an immediate prosthetic restoration can be positioned (18).

4. CHAIRSIDE PROTOCOL FOR IMPLANT-SUPPORTED RESTORATION

The current revolution in dental technology extends beyond digitalized approaches in implant dentistry to encompass other areas, such as the computer-aided design (CAD) and computer-aided manufacturing (CAM) of future implant-supported restorations. The process of taking impressions and subsequently designing and producing prosthetic restorations differs significantly from conventional or analog methods. Intraoral scanning is utilized to capture digital data, which is then employed in the CAD-CAM system instead of relying on traditional waxing and casting techniques for the production of restorations. These advancements in digitalization enable clinicians to design and produce prosthetic restorations, benefiting in faster treatment, shorter patient visits in the dental office, decreased patient discomfort and increased predictability (45). Additionally, there may be minimal or no need for final restoration adjustments, such as polishing and grinding, in contrast to conventional methods for indirect restoration production (46). The biggest drawback of digital workflow, which results in the slower adoption of technological advancements in dental offices, is the initial purchasing and managing expenses, as well as the gradual learning curve (45).

To ensure the desired result of a digital implant rehabilitation approach, it is necessary to employ monolithic CAD-CAM-managed restorations along with prefabricated abutments that are based on previous prosthodontically-driven backward planning. Using this streamlined chairside protocol, the dentist sidesteps the need for the dental laboratory in the production of the restoration, thereby ensuring the efficient creation of the restoration with specific materials that offer benefits with this technique (47).

Following a successful implant surgery, the dentist must obtain a digital impression, which is later utilized in CAD-CAM processing to create the implant crown. Materials used in that manner are zirconia, lithium disilicate, or hybrid ceramics. To address the physical limitations of zirconia when restoring teeth in the aesthetic area, a minor porcelain layering of the material outline is applied. Subsequently, any necessary post-processing is carried out, and the final restoration is placed to rehabilitate the patient's missing teeth (47,48).

4.1. Digital impression

After successful implantation, a second digital impression is taken with the use of an intraoral scanner. It captures peri-implant mucosa as well as adjacent teeth. This is followed by the insertion of the implant scan body and scanning of the implant position. Acquiring precise intraoral scanning data is crucial for the fit of the fixed prosthesis. If the implant position is transferred inaccurately, the result can be ill-fitted for final restoration. This can cause

complications, both biological and mechanical. Obtaining a digital impression of the opposite arch in the quadrant where restoration will be undertaken is essential for the purpose of occlusion registration and determination of the color (47,49,50).

The precision of acquiring an implant intraoral scan depends on multiple factors, including a selection of implant scan body, implant depth and angulation, operator obtaining digital impression and the intraoral scanner itself (51,52).

4.1.1. Scan body

Scan body serves as a cylindrical device that transfers the three-dimensional position of a dental implant from the patient's mouth to the computer-aided design (CAD) software. It is composed of three distinct parts: the upper component is called the scan region; the middle component is known as the body, and the apical portion is called the base. Compared to laboratory scan bodies, those used by dentists for direct intraoral scanning are much smaller due to the limited space in the mouth and the need to be tightened into the implant by hand. The main component for digital registration of implant orientation and angulation is the scan region. The implant's anti-rotational translation has been facilitated by incorporating a special geometry bevel feature in the scan bodies' region, which presents a flat surface on a cylindrical design. The accuracy of intraoral scanning is significantly impacted by the orientation of the flat surface. In order to achieve the highest level of precision, it is recommended to position the bevel feature lingually (50–52). Digital workflows in dentistry require maintaining the integrity of scan bodies. Altering the shape of the device may compromise the accuracy of superimposition when comparing intraoral scans with the best-fit shape stored in a computer-aided design (CAD) program's library. Therefore, it is recommended to preserve the original shape of the scan body, and if a dentist faces space limitations, to choose the appropriate scan body with suitable characteristics concerning form and dimension (52). Based on the dimensions, wider scan bodies can be used when there is more interproximal space available. The same can be said for the height of the scan body. If the neighboring teeth are higher, the scan body can be taller or longer. In the event of a complete absence of teeth, shorter ones may be more easily detected through intraoral scanning (50).

Scan bodies are offered in different materials, such as metal, polyether-ether-ketone (PEEK) polymer or plastic. While plastic and PEEK materials are often chosen for their ease of use, they are not without their drawbacks. In particular, issues like deformation and wear can arise from sterilization, screw tightening, or even the patient biting on the device. These challenges

can limit their usefulness in certain applications. In addition, these materials lack radiopacity when compared to metal, which renders it unfeasible to assess the accurate placement of the scan body on a radiographic examination when the implant is situated at the level of the bone (52).

4.2. Chairside CAD-processing

The primary objective of implementing chairside protocol was to finish the dental restoration in a single dental appointment while eliminating the need for a dental laboratory. Approximately four decades ago, Dentsply Sirona's CEREC system was utilized for the initial chairside treatment. CEREC is an abbreviation for chair-side economical restoration of aesthetic ceramics or, in short, ceramic reconstruction. It was the first CAD/CAM system presented for commercial use. Today, the most popular system besides CEREC is Planmeca from Planmeca Oy. There are multiple other manufacturers, but only these two offer the full range of equipment for complete chairside digital workflow. Although the application of these systems was originally restricted to the fabrication of inlays, onlays, and crowns, advancements in ceramic materials with increased strength and the development of prosthetic solutions, such as implants, have eliminated such limitations. Consequently, various types of restorations, including implant-supported crowns, can now be produced without any restrictions. The range of restorations that can be fabricated using chairside systems is contingent upon factors such as the dimensions of the material block and milling machine, as well as the characteristics of the specific material being utilized (53).

4.2.1. Computer-Aided Design software

After successful digitization of oral structures with intraoral scanning, digital image data is introduced to CAD software for the purpose of designing final implant-supported restoration. The primary benefit of the chairside protocol is that it enables the dentist to obtain a digital impression immediately upon scanning, thereby facilitating visualization and analysis, as well as the possibility of making corrections if necessary.

Different CAD/CAM systems utilize various software applications, depending on their intended use and type. The reason behind that is time constraint. Therefore, the materials for chairside workflow are likewise restricted. These systems may also employ specific file formats. In cases where the same system is used for scanning and designing, the file format may be system-

specific. Alternatively, a general 3-D file format known as STL may be used when the CAD software does not accept the format of the scanned image (53,54).

4.2.2. Virtual design

Design of restoration can be proposed directly by CAD software based on particular tooth shapes and neighboring structures, such as teeth around the implant and in the opposing arch. The designs are stored in digital libraries, which contain a variety of forms and appearances that closely resemble natural teeth. In light of the increasing availability of designing tools, dental restoration software has become more user-friendly, enabling the automation of various steps. This method is typically more effective in situations where only a single tooth needs to be restored. Following the final computer-generated design, data is stored virtually on a selected server. Compared to conventional approaches, digital scanning data is stored in a manner that does not require any physical space for archiving (53,54).

4.3. Chairside CAM-processing

To produce final restorations in a chairside manner, an intraoral scanner, design software, and a milling device are required in the office. In the final stage of CAD/CAM manufacturing, the production of computer-designed restorations is accomplished through the utilization of a milling machine. This is followed by additional refinement steps, including sintering, staining, and glazing. These procedures are essential for the creation of high-quality dental restorations. To date, Sirona and Planmeca have been among the foremost providers of complete equipment for chairside CAD/CAM systems (54,55).

Milling is a subtractive production technique for dental restorations that entails shaping large blocks of various materials into the desired form. This process is controlled by computer numerical control (CNC) technology, which directs the milling machine's cutting tools to produce a physical representation of the designed restoration with precision (55). The most commonly employed material for chairside milling is zirconia, which can be processed using two different types of CAD/CAM systems: hard milling of fully sintered blocks or soft milling of partially sintered blocks. As the name indicates, fully sintered zirconia blocks are denser and harder, making them more challenging and costly to mill due to the increased milling time of approximately 45 to 55 minutes for single-unit restoration and rapid tool wear, requiring the replacement of milling burs with each restoration production. Moreover, the utilization of hard milling could potentially undermine the clinical longevity of zirconia restorations. This is due

to the fact that the process generates heat on the surface during milling, which may initiate an undesirable transformation from the tetragonal to the monoclinic phase. In light of these difficulties, it is recommended to use soft milling for partially sintered zirconia to avoid creating unwanted imperfections and cracks in the final restoration (56,57).

4.3.1. Milling machine

Digital file data of the final restoration is transmitted to the milling machine, which then fabricates it. Milling is a subtractive manufacturing process that creates the previously designed restoration shape from materials which can be pre-sintered or sintered. To achieve this, the milling machine moves along distinct trails, which can be classified as 3-, 4-, or 5-axis milling methods. In the subtractive fabrication process, the material's strength is at its peak. However, there are some downsides to this method, including significant material waste and potential alterations to the surface quality due to the constraints of milling burs' size limitations. The consequence of this situation is that the thinnest section of the restoration will be excessively milled if it is lesser in size than the smallest cutting bur, which will result in a loose fitting. Restoration is milled either with diamond or carbide burs. In general, diamond burs are utilized for hard milling of silicate or glass ceramic restorations, while carbide burs are reserved for zirconia restorations, which are commonly milled from a pre-sintered monolithic block, presenting with softer composition. The terms 'grinding' and 'milling' are applied to clarify the distinction between carbide and diamond burs. 'Grinding' refers specifically to the use of carbide bur, while 'milling' is associated with the utilization of diamond burs. This process can be carried out in dry or wet conditions, depending on the choice of material (54,55,58,59).

Milling devices may vary in terms of their configurations, such as the number of milling axes, including those with 3, 4, and 5 axes. The selection of the appropriate milling machine for dental restoration is contingent upon the configuration of the milling axes, which is determined by the design of the restoration. The 3-axis device moves the milling burs in three directions, represented as X, Y, and Z axes, and is capable of rotating the material block by 180 degrees during milling. On the other hand, the 4-axis device operates similarly to the 3-axis device, with the additional feature of rotating the tension bridge around the X-axis, which saves material and reduces the time needed for milling. For the production of more complex restorations, a milling device with more milling axes is required. For that purpose, a 5-axis milling device is used, which in addition to the features of a 4-axis unit, has the ability to rotate the milling spindle around the Y-axis. This configuration allows for the generation of more precise restorations by

enabling the milling of undercuts in all directions. The 5-axis milling machine proves to be a valuable tool due to its ability to generate complex screw-retained implant crowns (54,55).

4.4. Materials for chairside CAD/CAM restorations

Although the primary benefit of chairside CAD/CAM indirect restorations is the ability to produce them without involving a dental laboratory, there are also several factors that limit the size or span of these restorations. Moreover, it restricts the use of various materials, as not all of them are suitable for processing in this manner. Specifically, materials such as acrylic, composite resins, and different ceramics can be used. Acrylics are typically reserved for temporary restorations and are therefore not applicable to the chairside protocol, which aims to provide the final restoration in a single dental appointment. It is crucial to consider each individual situation, including both aesthetic and functional indications when selecting materials to ensure the clinical durability of the restoration (53).

Restoring teeth with implant-supported restorations requires selecting the appropriate materials based on the location of the missing teeth. For the anterior region, materials with higher aesthetic properties are used, while in the posterior area, those with higher functional properties are chosen. Ceramic-based materials are commonly used to fulfil both aesthetic and functional demands while simultaneously exhibiting good biocompatibility. A variety of ceramics can be employed with chairside CAD/CAM systems. To ensure the correct selection of ceramics for specific teeth rehabilitation, they can be categorized based on their compositions. There are three groups classified as infiltrated ceramics, which are also called hybrid ceramics, silicate ceramics, and oxide or polycrystalline ceramics (58,60).

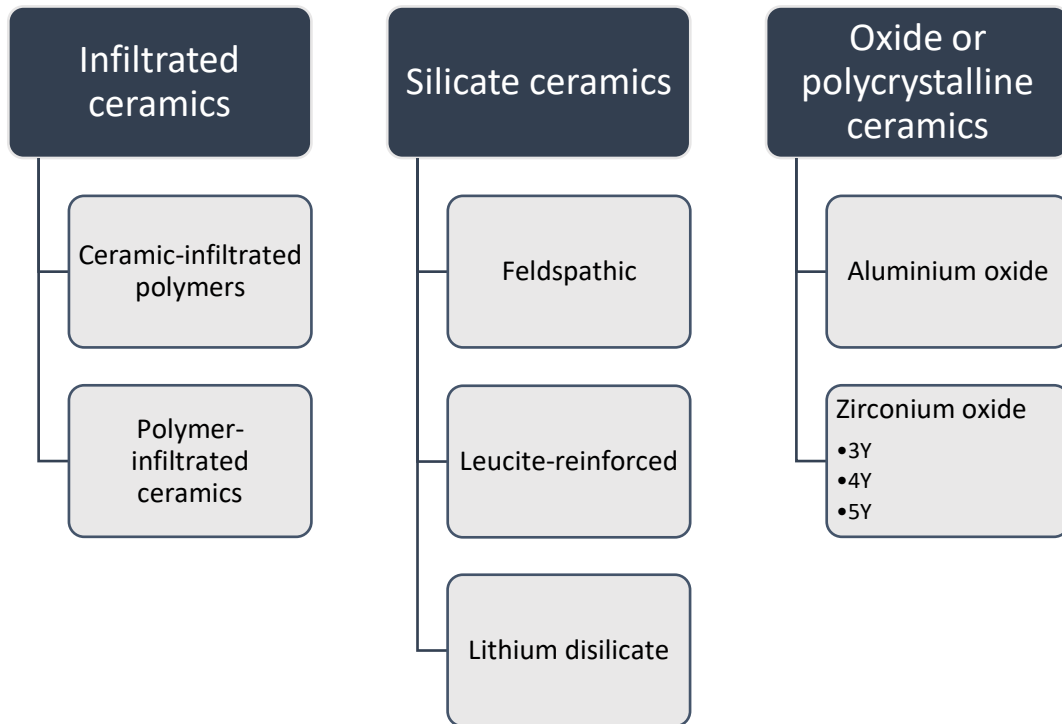


Figure 1: Classification of CAD/CAM ceramics (58)

4.4.1. Infiltrated ceramics

Infiltrated or hybrid ceramics are a relatively new class of materials that exhibit improved toughness and resistance to cracking compared to composite resins. With the integration of ceramics, these materials present enhanced aesthetic properties as well. There are two primary types of hybrid ceramics: ceramic-infiltrated polymers, in which composite resin is combined with ceramic filler particles, and polymer-infiltrated ceramics, in which ceramics predominate and are infiltrated by composite resin. The emphasized properties of hybrid ceramics include ease of milling without the need for post-processing of the produced restoration, increased resistance to bending, and increased load-bearing capacity. The use of two types of hybrid ceramics in restoration requires different bonding strategies for successful bonding. For polymer-infiltrated ceramics, the surface of the ceramic needs to be etched with 5% hydrofluoric acid for one minute, followed by the application of a coupling agent, which is silane. In contrast, ceramic-infiltrated polymers necessitate abrasion pretreatment with aluminum-oxide particles, which is then followed by the application of silane. The mechanical properties of this material are currently inferior to those of conventional ceramic restorations. Polymer-infiltrated ceramics display superior wear resistance compared to ceramic-infiltrated polymers. Due to their inferior characteristics, they are indicated only for veneers, inlays, and

onlays, and in some cases, polymer-infiltrated ceramics can be used for single crowns (54,58,61).

4.4.2. Silicate ceramics

Silica-based ceramics are commonly classified into three types: feldspathic, leucite-reinforced, and lithium disilicate ceramic. These ceramics possess a glassy matrix that gives them a translucent quality, making them an ideal material for restoring teeth in the aesthetic anterior region. Among the three types, feldspathic ceramics exhibit the best optical properties; however, this also makes them the weakest. To address this issue, leucite-reinforced ceramics were developed by reinforcing the matrix with leucite, which improves the strength of the material. Although these ceramics maintain excellent optical properties and are suitable for use in the aesthetic zone, they have only minimally improved strength compared to feldspathic porcelain, making them unsuitable for load-bearing areas. Lithium disilicate ceramics, on the other hand, offer an optimal combination of strength and optical properties, making them a better option for restorations in both the aesthetic and functional regions of the mouth (58).

Lithium disilicate ceramic blocks exhibit a crystalline phase, which consists of lithium disilicate and orthophosphate. These components are contributing to the material's enhanced strength. During the manufacturing process of the final restoration using milling, the blocks are processed in wet conditions in a precrystallized phase. Lithium disilicate ceramic blocks are dyed purple to facilitate their distinction from other materials and to prevent their inadvertent mixing. To crystallize the material, it undergoes sintering in a sintering furnace, followed by polishing and the final application of stain and glaze. The intention behind the material not being fully crystallized is to make milling easier by processing it in the 'softer state', which consequently reduces wear on the cutting components of the milling machine. Lately, modified forms of lithium disilicate ceramic blocks have become available that are fully crystallized, eliminating the need for additional post-processing of the material (58,61).

4.4.3. Oxide or polycrystalline ceramics

Zirconia or zirconium dioxide are extremely compact polycrystalline metal oxide-based ceramic blocks with exceptional mechanical properties. Additionally, it exhibits remarkable biocompatibility. The absence of a glassy matrix in this particular type of ceramic makes it aesthetically inferior to other varieties of ceramics (58,61). Zirconia possesses the unique characteristic of undergoing structural transformations in response to variations in temperature,

earning it the designation of a polymorphous and allotropic material. Specifically, it has the capacity to present in three distinct forms, referred to as monoclinic, tetragonal, and cubic. The monoclinic form is the most stable and is presented at room temperature. Each of these phases is accompanied by distinct physical and chemical properties. The most often used zirconia is in tetragonal and cubic phases (61,62). Following the sintering process and subsequent cooling to room temperature, zirconium crystals may spontaneously change their form from a tetragonal to a monoclinic phase. This transformation is irreversible. Simultaneously, the material experiences a volume expansion of up to 5%, resulting in the production of high compression stress, a phenomenon known as transformational toughening. This transformation toughening process is highly beneficial for prosthetics, as it enables zirconia to impede or slow the progression of micro-cracks and material breakages (61).

When discussing oxide ceramics, zirconia used in dentistry is often stabilized with oxides, primarily yttrium. This results in increased strength, making yttrium-stabilized zirconia polycrystals in the tetragonal phase (Y-TZP) the most commonly used option (62). To further classify the material, it can be categorized based on the mol percentage of yttrium oxide incorporated into it. Specifically, there are three most commonly used options: zirconia with 3, 4, or 5 mol % yttrium oxide. Each of these categories has distinct physical and mechanical properties that differ from one another. Zirconium with 3 mol % yttria (3Y-TZP) was the first material to be introduced, boasting the highest level of opaqueness and strength. In pursuit of a more aesthetic appearance with increased translucency, the next generation introduced was zirconium with 5 mol % yttria (5Y-TZP). This material exhibited higher translucency, but its mechanical strength diminished after mechanical loading, resulting in decreased fracture strength. To address this issue, it was proposed to decrease the yttrium content to 4 mol % and introduce 4Y-TZP. This generation of zirconia possesses stable tetragonal and cubic ratios of zirconium oxide polycrystals, with strength and translucency being well-balanced. Consequently, it can be utilized as a single-unit or long-span implant-supported fixed prosthetic restoration material in a monolithic form, suitable for both anterior and posterior regions. Nowadays, the use of monolithic restorations is often linked with multilayered technology, which incorporates varying percentages of yttrium into the material blocks. Essentially, this technique results in a natural tooth color appearance by blending different color pigments with similar flexural strength found in dentin and enamel layers, creating a seamless transition between these layers. To mimic the aesthetics of natural teeth, 3 mol % yttria-stabilized zirconia is utilized as the core, while the superficial layers contain a higher concentration of yttria to enhance the overall aesthetic appeal (53,60,62,63).

4.5. Post-processing of final restoration

4.5.1. Sintering

Due to the significantly easier milling of the softer, pre-sintered zirconium material, an additional step involving sintering is necessary. Sintering is a heating process that necessitates the use of a furnace capable of attaining a temperature of up to 1500°C. This process is employed to enhance the density and, subsequently, the strength of dental ceramics by heating the material to a temperature slightly below its melting point. Nevertheless, this approach requires an additional 6-8 hours of firing, cooling, and dwelling to attain optimal density. Consequently, the treatment duration is extended. Furthermore, it is crucial to take into account that partially sintered zirconia blocks must be milled to be 25% larger than the actual size of the final restoration to account for the shrinkage that occurs during the sintering process. Due to the extended time required for post-processing of partially sintered restorations, this method was unsuitable for chairside protocol as it necessitates more than a single visit from the patient. Therefore, advancements in sintering were achieved through the utilization of induction furnaces, which expedite the sintering process to a mere 10-minute duration, thereby enabling the implementation of a high-speed sintering protocol. The contrast between conventional and induction furnaces lies in the fact that the latter employs electromagnetic induction to accelerate the heat generation process or alter the magnetic field to pass an electric current through the object, whereas the conventional furnace operates at a much slower pace by generating heat through an electric current that must first pass through a resistor before heating the furnace's surroundings. Owing to the low thermal conductivity of zirconia materials, heat requires a considerable amount of time to traverse from the material's surface to its interior. In order to accomplish delivery of final restoration in a single dental appointment, it is suggested to employ sintering techniques that are more rapid than conventional ones, such as speed or high-speed sintering (56,64–66).

The process of speed sintering employs a modified conventional furnace characterized by a reduced heating chamber size. Consequently, this method achieves a faster sintering temperature of approximately 40–70°C per minute. Typically, this process takes between 30 and 120 minutes, allowing for the completion of the procedure during a single visit. This feature makes it well-suited for chairside protocols. Recently, a further reduction in sintering time from a few hours to approximately 10 min has become possible owing to the introduction of a high-speed sintering protocol that utilizes the aforementioned induction furnace. Although newer

sintering techniques are advantageous, they have some drawbacks. Specifically, they reduce the density and translucency of yttrium-stabilized zirconia without affecting its flexural strength. In addition to impacting the sintering time, shorter cooling and dwelling durations can influence the final outcome of restorations, including the inadequate elimination of residual pores, which subsequently reduces translucency. These residual pores and defects are more apparent with high-speed sintering, although they can also be observed in speed sintering. Thus, although conventional sintering is a significantly longer process, it is nonetheless the most effective method for achieving optimal outcomes, resulting in sintered restorations that exhibit better optical properties (57).

4.5.2. Surface treatments

Prior to completing prosthodontic rehabilitation in the patient's mouth, the restoration is examined to ensure that it fits perfectly and aligns with the patient's occlusion. If any corrections are necessary, the dentist will grind the material from the restoration at points where there are high and undesirable contacts in the occlusion. This is a widely accepted practice when working with zirconia restorations despite the ongoing advancements in CAD/CAM systems. All these restoration manipulations are part of the surface treatment, as well as subsequent polishing and glazing. Polishing is a technique used to eliminate surface imperfections by cutting in rotary motion, with the aim of creating a smooth surface. This is followed by glazing, which requires additional energy and time. A layer of ceramic glaze is applied to the surface of the dental restoration, and then sintered to produce a thin, translucent protective layer that imitates the appearance of natural teeth. To achieve this, feldspathic glass ceramic is commonly used because it is aesthetically pleasing. As the clinician adjusts the dental restoration, both the mechanical properties and the surface morphology of the ceramic material also undergo alterations, thus necessitating further polishing and glazing, as previously mentioned. If this is not carried out, the durability and practicality of these restorations are compromised. The accumulation of biofilm will be exacerbated, as well as occlusal wear of antagonistic natural teeth due to rough surfaces, and fracture of the restoration. Also changes in optical features are detected (67,68).

While it is much easier with glass ceramics to eliminate these defects of the restoration surface at least to some level, yttrium-stabilized zirconia ceramics do not possess this advantage. This can be attributed to their polycrystalline structure without the presence of glass particles. Thus, the objective of finishing, polishing and glazing is not to eradicate these imperfections, but

rather to fill them with glass ceramic material, thereby reducing its consequences (68). Monolithic zirconia restorations typically exhibit wear behavior as they age, which can render the restoration more abrasive. This necessitates the consideration of the most appropriate surface treatment in order to prevent exacerbating the present circumstances. Although surface finish with any treatment causes abrasiveness to progress, it is still recommended that polishing is used. Glazing initially serves to protect zirconia; however, over time, it leads to increased abrasiveness due to ageing (69).

4.6. Prosthodontic rehabilitation – cementation or screw-retained fixed prosthesis

In the concluding phase of prosthodontic rehabilitation, two methods are available for securing an implant-supported prosthesis: screw retention or cementation. As there is no definitive guideline to determine which approach is more suitable for which patient, the choice typically depends on the unique circumstances of each case and the dentist's personal inclination.

The decision-making process is influenced by numerous factors, such as aesthetics, occlusion control, available interocclusal space and the possibility of recovery in case of biological or technical complications. While aesthetics alone does not affect crown retention, it is often a consideration due to the presence of a screw hole required for screw retention. Even though cementation-retained design can improve aesthetics, the retention alone is then completely dependent on the height and conicity of the implant abutment. Therefore, the direction of the implant determines the retention technique that will be used. Some dentists prefer cementation over screw retention for occlusal purposes, as it allows for easier avoidance of unstable occlusal contacts. Both types of retention have their advantages and disadvantages, with the primary concern being the long-term success of the implant-supported restoration and surrounding tissues with the chance of retrievability. A major risk factor that needs to be taken into account is peri-implantitis and the possibility of managing such a condition. With cementation, there is a high risk of excess cement building up towards the gingival sulcus, which can initiate the inflammatory response of tissues in the peri-implant area, progressing to the development of peri-implant disease. Therefore, it is essential to place restoration margins at the same level or slightly above the tissue level to prevent cement from entering peri-implant tissues. This is a precautionary measure that may also influence the aesthetic appearance of the restoration in the mouth, potentially rendering it appear unnatural. If proper preventive measures are not considered during the process of cementation, there is a significant risk of losing

osseointegration, which can lead to the rejection of the implant in extreme cases. This can occur either in a few months or in a few years and is most accurately diagnosed when the implant-supported crown is removed, as it may not be visible on radiographs due to its thin layer, even with radio-opaque cements containing zinc. For this reason, screw-retention may be a more favourable option as it can easily be removed and reattached without damaging the restoration. While this method is more technically demanding and presents other issues, such as the loosening of the abutment screw, causing damage to the restoration, it is easier to maintain overall (70–72).

5. DISCUSSION

The objective of this paper was to assess and present the subsequent steps of prosthetically guided implant therapy, encompassing planning, fabrication, and delivery of fixed implant-supported restorations. The purpose was to exhibit the advancements in this field that yield superior patient outcomes and enhanced clinician efficiency. Consequently, the study investigated suitable materials for delivering final implant-supported prostheses in a chairside manner, without the need for a dental laboratory, while maintaining the same level of quality. The investigation included a review of the latest available literature to showcase the progress made in this area of care.

Schubert et al. (18) indicated that digital implant planning offers several advantages, including prosthodontically driven backward planning and guided implant surgery. In order to work with high precision, it is essential to have knowledge about the parameters that may affect the final outcome. These factors include 3-D data quality, rational implant position planning, and surgical guide production precision, as well as the dentist's knowledge and skills. Appropriate measures should be taken to ensure accurate data, such as avoiding patient movements by following the correct radiographic procedure and using a radiographic template or prosthesis scan if the patient has radiopaque restorations, which can cause artefacts in CBCT scans. While this may involve an extra step in data acquisition, it provides the clinician with more accurate information, which enhances the overall precision of the procedure. In terms of STL data obtained from intraoral scanners, they are considered to be as precise as conventional impressions and later extraoral scanning of small areas. For larger restorations, conventional impression techniques may still be recommended, but this is more applicable in fixed prosthodontics due to the need for maximum accuracy rather than for surgical guide planning. Therefore, the acquired DICOM and STL data for digital implant planning and surgical guide production are generally precise enough not to require further alteration in the implant planning process (18,23).

The accuracy of surgical guide production is largely determined by the type of computer-aided manufacturing (CAM) technology employed. The production process can be carried out using either additive or subtractive methods. In general, subtractive milling is considered to be more precise than 3-D printing. Despite the use of different techniques, both methods exhibit some deviations. While it would be optimal to have no variations, there is a certain level of tolerance built into the production process, and some deviations in accuracy are therefore deemed acceptable. Consequently, a safety margin of 2 millimeters around the implants is taken into

account when assessing the production precision of the surgical guide. While subtractive milling is more time-consuming and expensive, it is still the preferred method as it reduces the need for subsequent corrections and ultimately saves time and money, providing patients with better clinical outcomes (18,39,42).

Cortes (45) distinguished between conventional and digital methods of acquiring impressions and fabricating restorations. Conventional techniques are replaced by intraoral scanning and the production of restorations using a CAD-CAM system, which does not involve the use of a dental laboratory. The digital approach offers several advantages, including reduced treatment and appointment times, increased patient comfort, and elimination of the need for physical dental models. Additionally, digitalization enables the superimposition of 3-D data, which serves as an important tool for communication with patients and helps to manage their expectations more effectively. The main drawbacks of the digital approach are the cost of equipment and the time required to learn and adapt to it fully. Nevertheless, the digital method demonstrates superior accuracy and precision compared to the conventional approach for CAD-CAM single crowns or short-span fixed bridges. However, the precision of the digital method is also influenced by the clinical skills and knowledge of the dentist.

In the field of digital dentistry, Sulaiman (58) emphasized the importance of possessing a thorough comprehension of material properties and identifying those suitable for CAD-CAM processing. This knowledge is crucial in ensuring optimal results for all patients. Digital dentistry utilizes two distinct types of processing: subtractive and additive manufacturing. With the variety of materials that can be used in digital processing, chairside protocol typically restricts these materials to ceramics only. There are multiple variations of ceramics, and it is essential to determine which teeth are being replaced, as this will dictate the appropriate selection of ceramics. For this reason, subtractive manufacturing is typically employed, as 3-D printing of ceramics is more complex due to the high melting temperature, which can result in the formation of cracks during cooling. Additionally, the porosity of ceramics is increased during processing, further complicating 3-D printing. Zirconia and lithium disilicate are the most popular materials used in chairside processing. Although they share certain similarities, they should be selected based on individual clinical cases. Zirconia, as an oxide ceramic, is renowned for its exceptional strength and durability. Despite its mechanical properties, its aesthetics is subpar. Efforts have been made to increase the translucency of the material by reducing its alumina content and increasing yttria content, resulting in improved aesthetics, but

at the expense of strength. Lithium disilicate, on the other hand, is a silicate ceramic that contains glass, making it more translucent and visually appealing. Ultimately, clinicians must consider the specific teeth being replaced and the desired properties in that area. It is crucial to evaluate each patient's unique situation, taking into account the preferences of both the patient and the dentist's knowledge and experience (58,61).

Digital technology has significantly impacted the field of dentistry, providing numerous benefits. For instance, it has increased the precision and long-term results of dental implant therapy. As a result, technology has made it possible for dentists with different levels of skills and experience to achieve similar results as specialists. One of the advantages of digital workflow is the ability to acquire virtual patients through intraoral scans and CBCT imaging data. This renders the diagnosis and planning of implant positioning significantly more straightforward, as all details are displayed precisely as they exist in reality. Furthermore, if this process is carried out accurately, all subsequent steps will be as precise as the first, eliminating human error. Overall, digital implant dentistry offers more predictable outcomes compared to conventional methods. The primary disadvantage that dentists aim to minimize is the significant amount of time required for prosthetic rehabilitation, as it involves working closely with a dental laboratory. In the conventional approach, implant-supported restoration planning and subsequently restoring missing teeth with dental prosthesis necessitates the use of a patient's mouth model. To obtain these models, dentists rely on dental laboratories, which causes a considerable amount of time to be lost. This situation not only affects dentists but also impacts patients. The complete digital workflow is beneficial in that it mitigates various complications and drawbacks associated with the conventional approach. Specifically, it eliminates the discomfort experienced during impression taking, reduces the likelihood of impression material deformation, and consequently minimizes the need for additional steps in the production process. Furthermore, it eliminates the need for a dental laboratory and the subsequent delay in the delivery of the final restoration (73).

However, as a result of digitalization in dentistry, clinicians should be mindful of certain limitations when implementing a fully digital workflow. One of the most significant challenges is the lack of a single protocol that dentists can learn and apply in every situation. Additionally, the market currently offers multiple systems, and due to their high costs, it can be difficult for dentists to determine which one is most suitable for their needs. Furthermore, the rapid advancements in technology and materials used in dentistry can make it challenging for dentists

to keep up with the latest developments, which can be a significant barrier to the adoption of digitalization in many dental offices.

6. CONCLUSION

The concept of prosthodontically-driven dental implant therapy involves the placement of dental implants based on the desired final prosthetic restoration. This approach benefits both patients and dentists, as it allows clinicians with varying levels of experience and skill to achieve optimal and predictable outcomes.

With the focus on final results, the treatment planning process is reversed, introducing backward planning. The use of advanced diagnostic and design tools leads to improved outcomes that are more predictable and controlled, allowing patients to better understand and comply with the treatment process.

Additionally, chairside processing allows delivery of the final restoration on the same day, which eliminates the need for a dental laboratory, reducing treatment time and making the overall treatment more cost-effective.

7. LITERATURE

1. Block MS. Dental Implants: The Last 100 Years. *Journal of Oral and Maxillofacial Surgery*. 2018;76(1):11–26.
2. Alghamdi A, Al-Motari K, Sundar C, Jansen JA, Alghamdi H. Dental implants treatment: Clinical indications. In: *Dental Implants and Bone Grafts: Materials and Biological Issues*. Elsevier; 2019. p. 23–42.
3. Resnik R. *Misch's Contemporary Implant Dentistry*. 2020. 2–19 p.
4. Karami D, Alborzinia HR, Amid R, Kadkhodazadeh M, Yousefi N, Badakhshan S. In-Office Guided Implant Placement for Prosthetically Driven Implant Surgery. *Craniomaxillofac Trauma Reconstr*. 2017;10(3):246–54.
5. Joda T, Brägger U. Complete digital workflow for the production of implant-supported single-unit monolithic crowns. *Clin Oral Implants Res*. 2014;25(11):1304–6.
6. Magdalene Arun D, Nandini D. The History of Dental Implants-A Sequential Review. *IOSR Journal of Dental and Medical Sciences (IOSR-JDMS)*. 2021;20(2):38–40.
7. Bassir SH, El Kholy K, Chen CY, Lee KH, Intini G. Outcome of early dental implant placement versus other dental implant placement protocols: A systematic review and meta-analysis. *J Periodontol*. 2019;90(5):493–506.
8. Patel R, Ucer C, Wright S, Khan RS. Differences in Dental Implant Survival between Immediate vs. Delayed Placement: A Systematic Review and Meta-Analysis. *Dentistry Journal*. 2023;11(9):218.
9. Pandey C, Rokaya D, Bhattarai BP. Contemporary Concepts in Osseointegration of Dental Implants: A Review. *Biomed Res Int*. 2022;2022:1-11
10. Bosshardt DD, Chappuis V, Buser D. Osseointegration of titanium, titanium alloy and zirconia dental implants: current knowledge and open questions. *Periodontology 2000*. Blackwell Munksgaard; 2017;73(1):22–40.
11. Hanawa T. Zirconia versus titanium in dentistry: A review. *Dental Materials Journal*. Japanese Society for Dental Materials and Devices. 2020;39(1):24–36.
12. Sivaraman K, Chopra A, Narayan AI, Balakrishnan D. Is zirconia a viable alternative to titanium for oral implant? A critical review. Vol. 62, *Journal of Prosthodontic Research*. Elsevier Ltd; 2018;62(2):121–33.
13. Borie E, Orsi IA, De Araujo CPR. The influence of the connection, length and diameter of an implant on bone biomechanics. *Acta Odontol Scand*. 2015;73(5):321–9.
14. Heimes D, Becker P, Pabst A, Smeets R, Kraus A, Hartmann A, et al. How does dental implant macrogeometry affect primary implant stability? A narrative review. *Int J Implant Dent*. 2023;9(1):1-11.

15. Alshehri M, Alshehri F. Influence of Implant Shape (Tapered vs Cylindrical) on the Survival of Dental Implants Placed in the Posterior Maxilla: A Systematic Review. *Implant Dentistry*. Lippincott Williams and Wilkins; 2016;25(6):855–60.
16. Al-Johany SS, Al Amri MD, Alsaeed S, Alalola B. Dental Implant Length and Diameter: A Proposed Classification Scheme. *Journal of Prosthodontics*. 2017;26(3):252–60.
17. Pedro J, De J, Limírio O, Aparecido C, Lemos A, Marcela J, et al. A clinical comparison of 1-piece versus 2-piece implants: A systematic review and meta-analysis. *The Journal of Prosthetic Dentistry* [Internet]. 2020;124(4):439–45.
18. Schubert O, Schweiger J, Stimmelmayer M, Nold E, Güth JF. Digital implant planning and guided implant surgery – workflow and reliability. *Br Dent J*. 2019;226(2):101–8.
19. Monsour PA, Dudhia R. Implant radiography and radiology. *Australian Dental Journal*. 2008;53(s1):S11–25.
20. Kernen F, Kramer J, Wanner L, Wismeijer D, Nelson K, Flügge T. A review of virtual planning software for guided implant surgery - Data import and visualization, drill guide design and manufacturing. *BMC Oral Health*. BioMed Central Ltd; 2020;20(1):251.
21. Rinaldi M, Esposti A, Mottola A, Ganz SD. Computer-Assisted Implant Surgery. In: *Computer-Guided Applications for Dental Implants, Bone Grafting, and Reconstructive Surgery*. Elsevier eBooks. 2016;96–123.
22. Culp L, Wong NY, Misch CE. Digital Technology in Implant Dentistry. In: *Dental Implant Prosthetics*. Elsevier Inc.; 2015;700–23.
23. Mangano F, Gandolfi A, Luongo G, Logozzo S. Intraoral scanners in dentistry: A review of the current literature. *BMC Oral Health*. 2017;17(1):149.
24. Chisnoiu AM, Staicu AC, Kui A, Chisnoiu RM, Iacob S, Flueraşu M, et al. Smile Design and Treatment Planning—Conventional versus Digital—A Pilot Study. *J Pers Med*. 2023;13(7):1028.
25. Thomas P, Krishnamoorthi D, Mohan J, Raju R, Rajajayam S, Venkatesan S. Digital smile design. *J Pharm Bioallied Sci*. 2022;14(5):43.
26. Jafri Z, Ahmad N, Sawai M, Sultan N, Bhardwaj A. Digital Smile Design-An innovative tool in aesthetic dentistry. *J Oral Biol Craniofac Res*. 2020;10(2):194–8.
27. Kaasalainen T, Ekholm M, Siiskonen T, Kortensniemi M. Dental cone beam CT: An updated review. *Physica Medica*. Associazione Italiana di Fisica Medica; 2021;88:193–217.
28. Morton D, Phasuk K, Polido WD, Lin WS. Consideration for Contemporary Implant Surgery. *Dental Clinics of North America*. W.B. Saunders; 2019;63(2):309–29.

29. Jacobs R, Salmon B, Codari M, Hassan B, Bornstein MM. Cone beam computed tomography in implant dentistry: Recommendations for clinical use. *BMC Oral Health*. 2018;18(1):88.
30. Bayrakdar SK, Orhan K, Bayrakdar IS, Bilgir E, Ezhov M, Gusarev M, et al. A deep learning approach for dental implant planning in cone-beam computed tomography images. *BMC Med Imaging*. 2021;21(1):86.
31. Greenberg A. Advanced dental implant placement techniques. *J Istanbul Univ Fac Dent*. 2017;51(3 Suppl 1):S76-S89.
32. Ramasamy M, Giri, Raja R, Subramonian, Karthik, Narendrakumar R. Implant surgical guides: From the past to the present. *Journal of Pharmacy and Bioallied Sciences*. 2013;5:98-102.
33. Shi Y, Wang J, Ma C, Shen J, Dong X, Lin D. A systematic review of the accuracy of digital surgical guides for dental implantation. *Int J Implant Dent*. 2023;9(1):38.
34. Mukai S, Mukai E, Santos-Junior JA, Shibli JA, Faveri M, Giro G. Assessment of the reproducibility and precision of milling and 3D printing surgical guides. *BMC Oral Health*. 2021;21(1):1.
35. Dawood A, Marti BM, Sauret-Jackson V, Darwood A. 3D printing in dentistry. *Br Dent J*. 2015;219(11):521–9.
36. Tack P, Victor J, Gemmel P, Annemans L. 3D-printing techniques in a medical setting: A systematic literature review. *BioMedical Engineering Online*. BioMed Central Ltd.; 2016;15(1):115.
37. Chen X, Xu L, Wang W, Li X, Sun Y, Politis C. Computer-aided design and manufacturing of surgical templates and their clinical applications: a review. *Expert Review of Medical Devices*. Taylor and Francis Ltd; 2016;13(9):853–64.
38. Henprasert P, Dawson D V., El-Kerdani T, Song X, Couso-Queiruga E, Holloway JA. Comparison of the Accuracy of Implant Position Using Surgical Guides Fabricated by Additive and Subtractive Techniques. *Journal of Prosthodontics*. 2020;29(6):534–41.
39. Lo Russo L, Guida L, Mariani P, Ronsivalle V, Gallo C, Cicciù M, et al. Effect of Fabrication Technology on the Accuracy of Surgical Guides for Dental-Implant Surgery. *Bioengineering*. 2023;10(7):875.
40. Vasques MT, Urbano GS, Gialain IO, Lima JF, Andretti F, Kimura RN, et al. Computer-Aided Manufacturing (CAM). In: *Digital Dentistry [Internet]*. John Wiley & Sons, Ltd; 2022. p. 55–78. Available from: <https://onlinelibrary.wiley.com/doi/abs/10.1002/9781119852025.ch3>

41. Ku JK, Lee J, Lee HJ, Yun PY, Kim YK. Accuracy of dental implant placement with computer-guided surgery: a retrospective cohort study. *BMC Oral Health*. 2022;22(1):8.
42. Nulty A. A literature review on prosthetically designed guided implant placement and the factors influencing dental implant success. *Br Dent J*. 2024;236(3):169–80.
43. Romandini M, Ruales-Carrera E, Sadilina S, Hämmerle CHF, Sanz M. Minimal invasiveness at dental implant placement: A systematic review with meta-analyses on flapless fully guided surgery. *Periodontology 2000*. John Wiley and Sons Inc; 2023;91(1):89–112.
44. Smitkarn P, Subbalekha K, Mattheos N, Pimkhaokham A. The accuracy of single-tooth implants placed using fully digital-guided surgery and freehand implant surgery. *J Clin Periodontol*. 2019;46(9):949–57.
45. Cortes ARG. Digital versus Conventional Workflow in Oral Rehabilitations: Current Status. *Applied Sciences (Switzerland)*. MDPI; 2022;12(8):3710.
46. Joda T, Ferrari M, Gallucci GO, Wittneben JG, Brägger U. Digital technology in fixed implant prosthodontics. *Periodontology 2000*. Blackwell Munksgaard; 2017;73(1):178–92.
47. Joda T, Ferrari M. Chairside protocol for posterior single-unit implant restorations in a complete digital workflow. *Journal of Osseointegration*. 2018;10(2):33–6.
48. Michelinakis G, Apostolakis D, Kamposiora P, Papavasiliou G, Özcan M. The direct digital workflow in fixed implant prosthodontics: a narrative review. *BMC Oral Health*. BioMed Central Ltd; 2021;21(1):37.
49. Joda T, Brägger U. Complete digital workflow for the production of implant-supported single-unit monolithic crowns. *Clin Oral Implants Res*. 2014;25(11):1304–6.
50. Mizumoto RM, Yilmaz B. Intraoral scan bodies in implant dentistry: A systematic review. *Journal of Prosthetic Dentistry*. Mosby Inc.; 2018;120(3): 343–52.
51. Gómez-Polo M, Álvarez F, Ortega R, Gómez-Polo C, Barmak AB, Kois JC, et al. Influence of the implant scan body bevel location, implant angulation and position on intraoral scanning accuracy: An in vitro study. *J Dent*. 2022;121:104122.
52. Gracis S, Appiani A, Noè G. Digital workflow in implant prosthodontics: The critical aspects for reliable accuracy. *Journal of Esthetic and Restorative Dentistry*. John Wiley and Sons Inc; 2023;35(1):250–61.
53. Blatz MB, Conejo J. The Current State of Chairside Digital Dentistry and Materials. *Dental Clinics of North America*. W.B. Saunders; 2019;63(2):175–97.

54. Watanabe H, Fellows C, An H. Digital Technologies for Restorative Dentistry. Vol. 66, Dental Clinics of North America. W.B. Saunders; 2022;66(4):567–90.
55. Alghazzawi TF. Advancements in CAD/CAM technology: Options for practical implementation. Vol. 60, Journal of Prosthodontic Research. Elsevier Ltd; 2016;60(2):72–84.
56. Al-Haj Husain N, Özcan M, Dydyk N, Joda T. Conventional, Speed Sintering and High-Speed Sintering of Zirconia: A Systematic Review of the Current Status of Applications in Dentistry with a Focus on Precision, Mechanical and Optical Parameters. Journal of Clinical Medicine. MDPI; 2022;11(16):4892.
57. Alshahrani AM, Lim CH, Wolff MS, Janal MN, Zhang Y. Current speed sintering and high-speed sintering protocols compromise the translucency but not strength of yttria-stabilized zirconia. Dental Materials. 2024;40(4):664-73.
58. Sulaiman TA. Materials in digital dentistry—A review. Journal of Esthetic and Restorative Dentistry. 2020;32(2):171–81.
59. Pilecco RO, Machry RV, Baldi A, Tribst JPM, Sarkis-Onofre R, Valandro LF, et al. Influence of CAD-CAM milling strategies on the outcome of indirect restorations: A scoping review. Journal of Prosthetic Dentistry. Elsevier Inc.; 2024;131(5):811.e1-10.
60. Attia MA, Radwan M, Blunt L, Eng D, Bills P, Tawfik A, et al. Effect of different sintering protocols on the fracture strength of 3-unit monolithic gradient zirconia fixed partial dentures: An in vitro study. Journal of prosthetic dentistry. 2023;130(6):908.e1–8.
61. Marchesi G, Piloni AC, Nicolini V, Turco G, Di Lenarda R. Chairside CAD/CAM materials: Current trends of clinical uses. Biology. MDPI; 2021;10(11):1170.
62. Talibi M, Kaur K, Parmar H. Do you know your ceramics? Part 5: zirconia. Br Dent J. 2022;232(5):311–6.
63. Cevik P, Schimmel M, Yilmaz B. New generation CAD-CAM materials for implant-supported definitive frameworks fabricated by using subtractive technologies. BioMed Research International. Hindawi Limited; 2022;2022:3074182.
64. Al Hamad KQ, Al-Rashdan RB, Al-Rashdan BA, Baba NZ. Effect of Milling Protocols on Trueness and Precision of Ceramic Crowns. Journal of Prosthodontics. 2021;30(2):171–6.
65. Lubauer J, Schuenemann FH, Belli R, Lohbauer U. Speed-sintering and the mechanical properties of 3–5 mol% Y₂O₃-stabilized zirconias. Odontology. 2023;111(4):883–90.

66. Liu H, Inokoshi M, Xu K, Tonprasong W, Minakuchi S, Van Meerbeek B, et al. Does speed-sintering affect the optical and mechanical properties of yttria-stabilized zirconia? A systematic review and meta-analysis of in-vitro studies. *Japanese Dental Science Review*. Elsevier Ltd; 2023;59:312–28.
67. Zhang J, Deng S, Zhao Y, Zhu liqing, Gao S. Research progress on the wear of teeth antagonist caused by different dental ceramics after surface treatments. *Tribology International*. Elsevier Ltd; 2024;194:109478.
68. da Rosa LS, Pilecco RO, Sarkis-Onofre R, Kantorski KZ, Valandro LF, Rocha Pereira GK. Should finishing, polishing or glazing be performed after grinding YSZ ceramics? A systematic review and meta-analysis. *Journal of the Mechanical Behavior of Biomedical Materials*. Elsevier Ltd; 2023;138:105654.
69. Badarneh A, Eun Choi JJ, Lyons K, Porter G, Waddell N, Chun Li K. The effect of aging on the wear performance of monolithic zirconia. *Dental Materials*. 2022;38(5):e136–46.
70. Jivraj S. Screw versus cemented implant restorations: The decision-making process. *Journal of Dental Implants*. 2018;8(1):9-19.
71. Tribst JPM, de Jager N, Dal Piva AMO, Kleverlaan CJ, Feilzer A. Effect of crown retention systems and loading direction on the stress magnitude of posterior implant-supported restorations: A 3D-FEA. *Heliyon*. 2024;10(6):e28129.
72. Wittneben JG, Joda T, Weber HP, Brägger U. Screw retained vs. cement retained implant-supported fixed dental prosthesis. Vol. 73, *Periodontology 2000*. Blackwell Munksgaard; 2017;73(1):141–51.
73. Chio A, Mak A. The Digital Workflow in Implant Dentistry. In: *Practical Procedures in Implant Dentistry* [Internet]. 2021. p. 335–49. Available from: <https://doi.org/10.1002/9781119399186.ch34>

Pia Slana was born on July 12, 1996, in Ljubljana. Upon completing her primary education, she attended high school at Gimnazija Šiška's sport program. Throughout her high-school years, she actively participated in football. Before she concluded her active participation, she was part of the youth national football team of Slovenia. Following this, she pursued education at the Medical School of the University of Ljubljana. After her first year of study in Ljubljana, she applied and was accepted in the English program at the School of Dental Medicine in Zagreb. During her final years of study, she assisted at a dental office in Ljubljana in the summer months.