

# A multidisciplinary approach in the planing of complex oral rehabilitation

---

**Ebadollahi Novin, Mohsen**

**Master's thesis / Diplomski rad**

**2024**

*Degree Grantor / Ustanova koja je dodijelila akademski / stručni stupanj:* **University of Zagreb, School of Dental Medicine / Sveučilište u Zagrebu, Stomatološki fakultet**

*Permanent link / Trajna poveznica:* <https://um.nsk.hr/um:nbn:hr:127:286182>

*Rights / Prava:* [Attribution-NonCommercial-NoDerivatives 4.0 International/Imenovanje-Nekomercijalno-Bez prerada 4.0 međunarodna](#)

*Download date / Datum preuzimanja:* **2024-07-11**



*Repository / Repozitorij:*

[University of Zagreb School of Dental Medicine Repository](#)





University of Zagreb  
School of Dental Medicine

Mohsen Ebadollahi Novin

**A MULTIDISCIPLINARY APPROACH IN THE  
PLANING OF COMPLEX ORAL  
REHABILITATION**

GRADUATE THESIS

Zagreb, 2024

The work was carried out at the Department of Removable prosthodontics, School of Dental Medicine, University of Zagreb.

Thesis mentor: Assoc. Prof. Dr. Ivica Pelivan, PhD, DMD

English language proof-reader: Iva Varga, English language and literature teacher

Croatian language proof-reader: Ozana Valent, Translator/Court interpreter

Date of thesis defence: 17/6/2024

The composition of the Commission for the defence of the thesis:

1. Associate Professor Ivica Pelivan
2. Associate Professor Eva Klarić
3. Associate Professor Samir Čimić

Paper contains:

47 pages

5 tables

1 figure

1 CD

The work is the author's own work, which is completely independently written with an indication of the sources of other authors and documents used in the work. Unless it is not otherwise stated, all illustrations (tables, pictures, etc.) in the paper are the original contribution of the post-graduate author's specialist work. The author is responsible for obtaining permission to use illustrations that are not his original contribution, as well as for all possible consequences that may arise due to the illegal downloading of illustrations, i.e. failure to state their source.

## **Dedication**

I extend my sincere gratitude to my mentor Professor Ivica Pelivan for his invaluable guidance and steadfast support during the preparation of the thesis. I am indebted to him for the insightful lessons I gained during the clinical year, and I highly value the experience.

My sincerest and most heartfelt appreciation extends to my dear parents, who have been my most significant source of inspiration throughout my degree and life. Without their unwavering support and love, I would not be the person I am today. Their selflessness and dedication to my success have been invaluable, and I am thankful to God for blessing me with such incredible parents. I will always strive to make them proud. I would also like to thank my partner Fatemeh for the unwavering support she gave me while I was writing this thesis and during the last year of dental school.

In addition, I would like to extend my gratitude to my friends Saman, Pia, Sanja and the professors at the University of Zagreb School of Dental Medicine, who have played a crucial role in my journey as a dentistry student.

## **SUMMARY**

### **A MULTIDISCIPLINARY APPROACH IN THE PLANNING OF COMPLEX ORAL REHABILITATION**

Oral rehabilitation is an intricate process that frequently necessitates a multidisciplinary strategy to treat a patient effectively. Conducting thorough initial consultations, diagnostics, and managing patient expectations while simultaneously grappling with time and cost management is paramount to devising the optimal treatment plan. If the patient requires only prosthodontic work, a prosthodontist can execute the plan. However, more frequently, a multidisciplinary approach and a step-by-step treatment plan are necessary before the prosthodontist delivers the final prosthodontic work. This procedure can be lengthy and costly, and it is essential to inform the patient of all aspects of the treatment. Effective communication and understanding among different specialties are crucial to implementing the patient's treatment plan in the most appropriate manner possible. Any confusion or disagreement can lead to patient dissatisfaction and serious legal and clinical repercussions. This thesis examines various prosthodontic approaches for treating complex oral rehabilitation patients and explores the roles that other healthcare professionals and specialists within dentistry, including orthodontists, periodontists, endodontists, and general dental practitioners, can play in the multidisciplinary treatment process.

**Keywords:** multidisciplinary, complex oral rehabilitation, prosthodontics

## **SAŽETAK**

### **MULTIDISCIPLINARNI PRISTUP U PLANIRANJU KOMPLEKSNE ORALNE REHABILITACIJE**

Oralna rehabilitacija složen je proces koji često zahtijeva multidisciplinarni pristup za učinkovito liječenje pacijenta. Provođenje temeljitih početnih konzultacija i dijagnostike i upravljanje očekivanjima pacijenta te istovremeno upravljanje vremenom i troškovima od ključne je važnosti za izradu optimalnog plana liječenja. Ako je pacijentu potreban samo protetski rad, plan može izvršiti protetičar. Međutim, češće su potrebni multidisciplinarni pristup i detaljan plan liječenja prije nego što protetičar isporuči konačan protetski rad. Taj postupak može biti dugotrajan i skup, stoga je bitno obavijestiti pacijenta o svim aspektima liječenja. Učinkovita komunikacija i razumijevanje među različitim specijalnostima ključni su za provedbu plana liječenja pacijenta na najprimjereniji način. Bilo kakve nejasnoće ili neslaganja mogu dovesti do nezadovoljstva pacijenta i ozbiljnih pravnih i kliničkih posljedica. U ovome se radu sagledavaju različiti protetski pristupi u liječenju pacijenata kojima je potrebna kompleksna oralna rehabilitacija i istražuju se uloge koje drugi zdravstveni stručnjaci i specijalisti u području stomatologije, uključujući ortodonte, parodontologe, endodonte i opće stomatologe, mogu imati u ovom multidisciplinarnom procesu liječenja.

**Ključne riječi:** multidisciplinarni, kompleksna oralna rehabilitacija, protetika

# INDEX

<b>1. INTRODUCTION</b> -----	<b>1</b>
<b>2. COMPLEX CASES TREATMENT PLANNING</b> -----	<b>3</b>
2.1 Initial phase-----	4
2.2 Customisation-----	4
2.3 Managing patient expectations-----	5
2.4 Time management-----	5
2.5 The clinical outcome should neither fall short of nor exceed the existing problem----	6
2.6 Classification of prosthodontic treatments-----	6
2.7 Stages of prosthodontic treatment and their sequential processes-----	8
2.8 Point of no return in prosthodontic treatments-----	8
2.9 Diagnostics-----	9
2.10 Approaches in clinical examination-----	9
<b>3. PRE-PROSTHETIC PHASE</b> -----	<b>11</b>
3.1 General Dental Practitioner-----	12
3.2 Pre-prosthetic Endodontics and Restorative-----	13
3.3 Pre-Prosthetic Periodontics-----	13
3.3.1 Periodontal assessment in oral rehabilitation-----	13
3.3.2 Periodontal treatment modelling sequence-----	14
3.3.3 Regenerative methods and bone grafting-----	15
3.4 Pre-Prosthetic Orthodontics-----	16
3.4.1 Orthodontic treatment in oral rehabilitation-----	16
<b>4. PROSTHETIC PHASE</b> -----	<b>18</b>
4.1 Identification of Patient Needs-----	19
4.2 Correction of Existing Disease-----	19
4.3 Restoration of Function-----	19
4.4 Improvement of Appearance-----	20
4.5 Occlusion in Full Mouth Rehabilitation according to Vertical Dimension of Occlusion (VDO) -----	20
4.6 Confirmative and Re-organised Occlusion-----	20

4.7 Occlusion Concepts during Eccentric Movements-----	21
4.8 Prosthetic Phase Treatment Modalities for Oral Rehabilitation-----	22
4.8.1 Fixed prosthodontics-----	22
4.8.1.1 Minimally invasiveness concept in fixed prosthodontics-----	22
4.8.1.2 Pre-treatment with CAD/CAM polymers-----	23
4.8.1.3 All-ceramic anterior veneers in complex oral rehabilitation-----	24
4.8.1.4 Design options for interproximal extension of anterior veneers--	24
4.8.1.5 All-ceramic occlusal onlays posterior region-----	24
4.8.2 Implant-supported prosthesis-----	25
4.8.3 Partial removable dental prosthesis-----	27
4.8.4 Complete removable dentures-----	29
4.8.4.1 Conventional compared to digital techniques-----	30
<b>5. COMMITMENT TO POST-TREATMENT CARE-----</b>	<b>31</b>
5.1 Post-treatment education for patient and commitments of the clinician-----	32
5.2 Patient adherence and specialized maintenance programs -----	33
5.3 Clinicians recommended protocol for checking fixed prosthesis-----	33
5.4 Clinicians recommended protocol for checking removable partial denture-----	34
5.5 Clinicians recommended protocol for checking complete denture-----	35
<b>6. DISCUSSION-----</b>	<b>36</b>
6.1 Limitations of Multidisciplinary approach-----	38
6.2 Effectiveness of various treatment options-----	39
6.3 Post-treatment care-----	40
<b>7. CONCLUSION-----</b>	<b>41</b>
<b>8. LITERATURE -----</b>	<b>43</b>
<b>9. AUTHOR'S BIOGRAPHY-----</b>	<b>46</b>



## List of abbreviations

<b>RDP</b>	Removable dental prostheses
<b>FDP</b>	Fixed dental prostheses
<b>CAL</b>	Clinical attachment loss
<b>BOP</b>	Bleeding on probing
<b>PI</b>	Plaque index
<b>GDP</b>	General dental practitioner
<b>BMP</b>	Bone morphogenetic protein
<b>VDO</b>	Vertical dimension of occlusion
<b>CAD</b>	Computer-aided design
<b>CAM</b>	Computer-aided manufacturing
<b>PMMA</b>	Polymethyl methacrylate
<b>CTX</b>	C-terminal cross-linking telopeptide
<b>CBCT</b>	Cone beam computed tomography
<b>3D</b>	Three dimensional
<b>CAT</b>	Computerized axial tomography
<b>STL</b>	Stereolithographic file

## **1. INTRODUCTION**

The term “rehabilitate” denotes the restoration of a previous state or capacity. Optimum oral health, functional efficacy, masticatory mechanisms and aesthetics is restored as part of oral rehabilitation and this can include restoring a single tooth, a number of teeth or also finding the best solutions for the replacement of missing teeth in order to rehabilitate oral cavity (1). Occlusion plays a crucial role in this intricate system and should be carefully taken into account in connection with all the relevant disciplines and factors (2). It intersects with pre-prosthetic procedures such as orthodontics and periodontics as well as prosthetic phase of the therapy. In order to achieve consistent outcomes in the long term, the decision-making process for complex clinical cases necessitates the involvement of multiple specialists (3).

The persistent challenges posed by deteriorating dentition, characterized by heavily restored teeth, ill-fitting prostheses, and periodontal disease, are often exacerbated by bone loss and subsequent mandibular changes, impacting patients’ comfort and oral health-related quality of life. While traditional dentures contribute to further bone resorption, implant-retained prostheses offer significant improvements in terms of physical discomfort, psychological well-being, and functional limitations. Recognized as a physical handicap by the World Health Organization, edentulism can lead to profound functional and aesthetic impairments, underscoring the importance of preserving teeth whenever possible and resorting to dental implants for hopeless or missing teeth. Thus, a comprehensive evaluation with a multidisciplinary approach is essential for developing tailored treatment plans aligned with patients’ long-term expectations (3). This paper will aim to examine the diverse strategies and modalities for complex oral rehabilitation treatment planning, including the sequence of treatments that may involve pre-prosthetic and prosthetic phases, as well as post-treatment care for patients following their treatments.

**2. COMPLEX CASES TREATMENT PLANNING**

The prosthodontic planning for complex instances necessitates substantial time and dedication and demands expert knowledge, proficiency, abilities, dedication, accessibility, endurance, and enthusiasm.

When devising a plan, prosthodontists must take into consideration the subsequent aspects:

1. Deliberate and assess all the processes that need to be executed in accordance with their distinct and general reasoning and consecutive arrangement.
2. Keep in mind that for intricate prosthodontic scenarios, the comprehensive strategy development endeavour is also intricate because all the clinical, laboratory, and surgical stages must be multiplied by the quantity of procedures essential to effectively restore the patient.
3. Acknowledge that frequently they must formulate additional treatment alternatives for every clinical instance, contingent on factors that need to be evaluated in advance such as the primary concern; the time and financial constraints; and the patient's desire, levels of comprehension and dedication, character, and anticipations (4).

## **2.1 Initial phase**

The most crucial phase of the prosthodontic procedure is the initial diagnostic planning stage. It is crucial because it marks the start and development of the entire restoration venture.

During the initial phase, the clinical situation needs to be meticulously evaluated and a customized treatment plan needs to be developed. This can be a challenging task, especially in complex cases that require a significant amount of data and clinical findings to be carefully collected, analysed, and synthesized (4).

## **2.2 Customization**

An accurate diagnosis and preliminary treatment prognosis are essential for formulating tailored treatment strategies. It is imperative to personalize each strategy according to the distinct requirements of the patient and to communicate it comprehensively to them. If viable, the treatment strategy should encompass a compilation of particulars delineating the precise clinical and technical steps in the sequence in which they will be executed (4).

The anticipation of a patient's dedication, the length of treatment, and a thorough summary of the planned procedures need to be integrated into the treatment strategy. This acts as a valuable and essential documented guide for the patient to refer to repeatedly. Through this method, patients can

avoid missing appointments or providing incorrect details regarding the procedures. Moreover, it protects both the practitioner and the dental facility, as patients might hold the practitioner or other staff liable for any misinterpretations or lapses in memory (4).

### **2.3 Managing patient expectations**

Anticipations represent an individual's projections of their wishes, necessities, and ambitions for the future. Within the medical field, patient anticipations are intertwined with potential results that can trigger psychological and physiological alterations. These anticipations are often depicted as cyclical and longitudinal processes, culminating in a final accelerating phenomenon involving stages of comprehension, anticipation formulation, outcome, and post-outcome cognitive processing. Concerning anticipations, patients might perceive the restoration of a single frontal tooth with equal significance and emotional resonance as a comprehensive mouth rehabilitation. However, it is crucial to acknowledge that this scenario can sometimes pose a challenge for us. Hence, we must remain mindful of the situation and handle it with kindness and assertiveness, all while exhibiting gentleness and empathy towards our patient's needs, aspirations, and volition (4). We always have to strive to communicate with patients regarding the realities of their conditions, encompassing the limitations imposed by the clinical environment, financial constraints, and time constraints. It proves valuable and informative to tactfully elucidate to patients the clinical significance and tangible indicators of their subjective symptoms, without causing offense. This approach aids in making their expectations as realistic as possible. Often, patients' expectations diverge from the objective clinical facts. To optimize outcomes, it is essential to thoroughly explain the foundational structure of the treatment plan and its anticipated progression from the outset, taking the required time to ensure clarity (4).

### **2.4 Time management**

Numerous professionals often cite lack of time as a reason for not allocating adequate time to the critical initial visit and associated treatment explanations. This oversight can prove to be a significant error, potentially requiring rectification later on. Depending on the expected duration and complexity of the prosthodontic treatment, it is imperative to be prepared to invest a substantial amount of time initially, and possibly again at later stages of the treatment process. Attentively listening to patients' concerns and inquiries is crucial, as is explaining the rationale behind current

and future procedures, including factors influencing potential fluctuations in complexity and pace (4).

### **2.5 The clinical outcome should neither fall short of nor exceed the existing problem**

The ethical benchmark of care and professional discernment stipulate that within the realms of medicine and dental medicine, the clinical outcome ought to surpass the initial condition; otherwise, the treatment could be deemed futile or ineffective. It is imperative that our interventions improve the patient's condition. If, in your professional judgment, it is determined that the treatment will not achieve this, then the option of no treatment should be contemplated. To put this differently, you should suggest to the patient foregoing a restorative intervention because it might not enhance their condition, or could potentially exacerbate or complicate it. This determination may be influenced by various factors, encompassing psychological, physical, clinical, and prosthodontic considerations (4).

### **2.6 Classification of prosthodontic treatments**

Prosthodontics clinical situations present three situation and treatment options. There are important parameters that needs to be noted in these situations (Table 1).

- A) Disease: refers to the existence or lack of one or more infectious oral illnesses. In the presence of disease, prosthodontic treatment will be postponed or restricted because the condition must be treated before the restoration process can be completed.
- B) Collaborative efforts: the necessity for involvement by additional specialists during prosthodontic rehabilitation to enhance clinical outcomes and/or address specific pathological conditions (4).

Table 1. Prosthodontic cases according to whether the patient has any disease and whether there is a need for multidisciplinary approach (4).

1	Cases with no disease and no requirement for multidisciplinary approach
2	Cases with no disease but with requirement for multidisciplinary approach
3	Cases with disease and requirement for multidisciplinary approach

Based on academic and clinical experience, there are only three mathematical possibilities for prosthodontic treatment types, corresponding to the three primary rehabilitative options. These two essential variables create the three possible outcomes (4).

**Class I: comprehensive restorative rehabilitations**

In this category, the patient does not have any diseases, with the sole concern being a prosthodontic issue. This classification encompasses patients free from viral or bacterial infections (4). Consequently, for the patients in this group, only prosthodontists are required, and collaboration with other specialists is unnecessary (Table 2).

**Class II: multidisciplinary improving rehabilitations**

In this classification, patients do not have any viral or bacterial infectious diseases. However, collaboration with other specialists, such as an orthodontist, maxillofacial surgeon, oral surgeon, and/or periodontist, is necessary (4). Working with these specialists is crucial to achieve optimal function and aesthetics in the restoration, thereby improving the likelihood of a predictable and stable result (Table 3).

**Class III: multidisciplinary healing rehabilitations**

In the third category, covering all prosthetic rehabilitations involving oral cavities affected by one or more bacterial and/or viral oral diseases, collaboration with specialists becomes crucial (4). These experts play a vital role in healing, preserving, and restoring dental and oral structures through periodontics, endodontics, oral surgery, and maxillofacial therapies (Table 4).

Table 2. Class 1 - Comprehensive restorative rehabilitations. (4)

Phase 1	Diagnostic, consultation and planning
Phase 2	Restorative, prosthodontic
Phase 3	Post-treatment care and maintenance



Table 3. Class 2: Multidisciplinary improving rehabilitations (4).

Phase 1	Diagnostic, consultation, planning
Phase 2	Part1: Collaboration for improving and initial prosthodontic work
Phase 2	Part 2: Restorative and prosthodontic work
Phase 3	Post-treatment care and maintenance

Table 4. Class 3: Multidisciplinary healing rehabilitations (4).

Phase 1	Diagnostic, consultation, planning
Phase 2	Part1: Collaboration for healing and initial prosthodontic work
Phase 2	Part 2: Restorative and prosthodontic work
Phase 3	Post-treatment care and maintenance

### **2.7 Stages of prosthodontic treatment and their sequential processes**

The outlined prosthodontic treatments usually involve distinct working phases, often simplified into two procedural steps.

Class I: Comprehensive Restorative Rehabilitations: After the initial diagnostic and treatment planning phase (Phase I), there is a restorative phase (Phase II), covering the entire prosthetic treatment process. This is followed by the final phase (Phase III), focusing on post-treatment care and maintenance (4).

### **2.8 Point of no return in prosthodontic treatments**

Each prosthodontic procedure has a critical point of no return that separates Phases I and II. This point, once reached, cannot be reversed. The threshold between Phase I and II is reached when a specific and predictable treatment outcome is achieved. Initiating patient treatment and changing their initial condition marks this point. However, crossing this point may have legal implications (4).

## 2.9 Diagnostics

During the initial phase of treatment, the dentist conducts a thorough evaluation of the patient's oral health and prosthodontic needs. This evaluation is conducted both objectively and subjectively, with the purpose of creating a personalized treatment plan. Once the patient has fully understood and accepted the plan and provided informed consent, the rehabilitation process can begin (4). Several key steps are taken during Phase I to arrive at an accurate diagnosis, and these steps are typically carried out in a specific order based on established protocols (Table 1.5).

Table 5. Stages of the procedure in phase 1 (4).

1	Initial patient questionnaire
2	First visit and interview
3	Analog/digital diagnostic casts
4	Analog/digital diagnostic wax-ups
5	Mock up provisional
6	Other specialist consultations

## 2.10 Approaches to Clinical Examination

Typically, two methods of assessing the patient's condition can be employed:

(1) Examining a particular condition or region (2) Comprehensive examination methodology.

1. Examining a particular condition or region:

This approach involves a form of analysis where the dentist zeroes in on a particular aspect or scenario, along with the issues related to it. Dental students and recent graduates often focus their attention on a specific aspect, usually linked to the patient's main concern or expectations when planning their initial cases. Relying solely on recommendations from this type of examination may negatively impact the treatment's final outcome, as it offers only a limited perspective of the patient's overall health. This methodology typically addresses a specific issue within a particular specialty, without considering potential complications that may arise in other areas of expertise. Consequently, crucial elements related to additional challenges are not incorporated into the overall treatment strategy (5).

2. Comprehensive examination methodology:

The comprehensive examination methodology takes into account the patient's overall well-being, encompassing all areas of expertise and related issues. The treatment strategy derived from this approach considers the patient's complete condition, ensuring no aspect of their care is overlooked. This method helps prevent the omission of critical details in the patient's care plan.

As previously noted, a thorough clinical assessment should precede specific examinations. Employing this approach allows the dentist to address all aspects of the patient's needs, without neglecting important considerations in other domains. To ensure the development of a comprehensive treatment plan, it is essential to first establish a broad treatment framework, which can then be tailored to address specific concerns. In essence, while both examination methods can be utilized clinically, a thorough understanding of the patient's overall health is essential before focusing on treating a particular issue (5).

**3. PRE-PROSTHETIC PHASE**

### **3.1 General Dental Practitioner (GDP)**

Oral rehabilitation generally begins when a patient visits their general dentist for a routine check-up or to address a specific issue or concern. This usually happens when the patient is experiencing pain, difficulty chewing, or has an aesthetic concern that they bring to the dentist's attention.

As a GDP, one has significant responsibilities. These obligations encompass the prompt identification and diagnosis of oral health issues, the promotion of oral health, the provision of education, and the delivery of care and services (6).

GDP's role during complex oral rehabilitation procedures is multifaceted and crucial for successful treatment outcomes, these roles include:

- a) Comprehensive medical, medications and allergy history
  
- b) Comprehensive Assessment and Diagnosis
  - Thoroughly evaluating a patient's oral health by examining their teeth, gums, and other supporting structures is essential. This assessment should also identify complex dental issues like tooth decay, periodontal disease, misaligned teeth, and missing teeth. To aid in the diagnostic process, various tools such as X-rays, intraoral cameras, and diagnostic models can be utilized.
  - General dental practitioners often serve as the initial healthcare provider to identify oral lesions. Given this, it is essential that dentists adopt a preventive approach and have thorough examination of the oral cavity rather than a curative one (6).
  
- c) Treatment Planning and Coordination
  - Collaborating with experts from various fields (e.g. prosthodontists, periodontists, and oral surgeons) to create individualised course of action that cater to the unique patient needs.
  
- d) Patient Education
  - Providing guidance and support to patients during the rehabilitation process, addressing their concerns and answering their questions.

### **3.2 Pre-prosthetic Endodontics and Restorative**

In the initial stage of oral rehabilitation treatment of a patient, the endodontist and restorative specialist play a critical role in saving teeth with a poor prognosis. Without proper endodontics and restorative care, these teeth may not be salvageable. Endodontic therapy combined with appropriate restoration often presents a practical and cost-effective solution for preserving function in the majority of cases. Conversely, dental implants serve as a suitable alternative in specific situations where the prognosis is unfavourable. It is crucial to make every effort to preserve naturally occurring teeth whenever feasible, taking into account factors such as favourable restorability, adequate bone quality, aesthetic considerations, and patient preferences. Typically, teeth with an intact coronal structure, an adequate root length, and healthy surrounding bone are preferred candidates for conventional endodontic treatment, especially when the patient values aesthetic outcomes (7).

Regarding the cases in which carrying out endodontic treatment is advisable, quite a few studies have shown that it is advisable to carry out endodontic therapy prior to periodontics treatments. This will also help in healing of the periodontium post-periodontal treatments (4).

However, in cases where a tooth is deemed irreparable, extraction followed by immediate or delayed implant placement is the recommended course of action (7).

### **3.3 Pre-prosthetic Periodontics**

The health of the periodontium is of absolute importance in the diagnosis and planning of complex oral rehabilitation cases. Without adequate periodontal health, oral rehabilitation treatments, such as crowns, bridges, and dental implants, may be compromised. The periodontium is made up of several components, which include the root, alveolar bone, gingiva, cementum and periodontal ligament. The most common periodontal diseases which worldwide affects significant number of population includes gingivitis and periodontitis. Gingival recession can also be mentioned as part of the periodontal diseases; however, it is actually not a disease, but can be a consequence of lack of proper oral hygiene and also functional overloading (8).

#### **3.3.1 Periodontal assessment in oral rehabilitation:**

In order to establish the correct approach and treatment planning for patients on an individual basis; the practitioner must have a good understanding of the patient's periodontal health in order to make

the planning. Establishing a periodontal condition involves more than simply evaluating the depths of every periodontal pocket. Periodontitis, mainly an area specific condition, requires assessing each individual tooth and corresponding site for measuring the depth of every pocket and every recession to be able to calculate the clinical attachment loss (CAL). Additionally, it is essential to record the bleeding on probing (BOP) and the plaque index (PI) at these locations (8).

### **3.3.2 Periodontal treatment modelling sequence**

Gingivitis and periodontitis are primarily caused by bacteria, which means that their treatment must have an anti-infectious focus. The removal or reduction of the infection typically stems most importantly by mechanical removal of plaque and bacteria from the root, teeth surfaces and also from the gingival soft tissue. Complete elimination of plaque, regardless of whether it is supragingival or subgingival, is unattainable. The objective is to establish homeostasis between resident bacteria and the host (8).

#### **Phase 0**

The initial stage primarily involves assessing the patient's systemic health and collecting comprehensive data to establish a preliminary diagnosis. Professional removal of plaque and calculus supragingivally, as well as instructing the patient on effective plaque control will also be done during phase 0 and this can quickly improve the patient's oral health. This approach can motivate and encourage a cooperative patient to participate in and complete the comprehensive treatment program (8).

#### **Phase 1**

The approach to therapy can vary in the initial stage. In some situations, a procedure known as closed root planning, which may or may not involve the administration of medications, is carried out. However, in other cases, the treatment process may proceed directly to surgery, which is the phase 2 of treatment (8).

#### **Phase 2**

After completing Phase 1, it is essential to perform a re-evaluation. If the therapeutic approach outcome is deemed unsatisfactory, root surfaces can be retreated. However, if the pockets depths did not improve and there are problems such as furcation involvement, surgical approach is indicated (8).

### Phase 3

Following the completion of therapies, whether it be non-surgical or surgical, follow-up examinations are conducted two to three months later. If the treatment is considered effective, the patient is scheduled for routine check-ups. However, if any particular area shows signs of issues, it must be re-treated either through non-surgical or surgical means (8).

#### **3.3.3 Regenerative Methods and Bone Grafting:**

Periodontists, as a key component of complex oral rehabilitation cases, must collaborate with other specialists involved in the patient's oral rehabilitation and, whenever possible, through their diagnosis and planning, provide a healthier and stronger periodontal structure for future prosthodontic work. Alternatively, if a tooth diagnosis is deemed hopeless, they must ensure that there is enough alveolar bone ridge for future implant or removable prosthesis placement for the patient. The true regeneration of all periodontal structures, i.e. new cementum, periodontal ligament and alveolar bone, is the main goal of today's various periodontal therapies (8).

The process of selecting treatment materials and methods for Regenerative Therapy comprises: (8)

- A) Closed or open root planning to promote regeneration without including any extra materials
- B) Utilization of bone and materials that replace bone to aid in the regeneration process
- C) Use of membranes
- D) Incorporation of growth factors and matrix proteins to stimulate cell growth and differentiation

Closed or open root planning to promote regeneration without additional materials:

After carrying out extensive root planning and particularly after undergoing open therapy for two- and three-wall defects, it is possible to achieve a considerable increase in alveolar bone, provided the individual adheres to an exceptionally strict oral hygiene routine (8).

Utilization of bone and materials that replace bone to aid in the regeneration process:

Autogenous bone from a healthy patient is the best substance for enhancing bone formation, as it is variously osteoinductive. Donor site that could be potentially favourable for autogenous bone include edentulous arch segments and the chin (8).



Allogeneic bone replacement materials are available in large quantities in the market and have been shown to be osteoconductive, potentially also osteoinductive. Xenogenic and alloplastic bone replacement materials are specifically osteoconductive and do not provide significantly better results than optimum open root cleaning/planning (8).

Use of membranes:

The function of the membrane was to prevent healing through the process of “repair” by creating a long junctional epithelium. The aim of the physical barrier is to obstruct the fast downward growth of epithelial cells and the contact between the root surface and gingival connective tissue, allowing the periodontium to have enough time for regeneration (8).

Incorporation of growth factors and matrix proteins to stimulate cell growth and differentiation:

Several substances, such as growth factors and proteins like amelogenin and “bone morphogenetic protein” (BMP), are either currently available for clinical use or will become available in the near future. These substances include matrix proteins like amelogenin and emdogain, as well as blood platelet growth factor (8).

### **3.4 Pre-prosthetic Orthodontics in oral rehabilitation**

Dentists often encounter adult patients seeking to enhance their appearance, unaware of the complexities underlying their dental issues. Smile imperfections stem from various factors, such as untreated malocclusions, tooth loss, periodontal issues, occlusal changes, and dental erosion. Traditional treatment involves preparing damaged teeth and prosthetic restoration, often sacrificing healthy tissue. However, adhesive techniques now offer minimally invasive approaches, preserving biological tissue, restoring vertical dimension, and occlusal morphology. Preliminary orthodontic treatment can address dental incongruities and irregularities, reducing the need for compromised solutions. In adult orthodontics, the treatment focuses on dentoalveolar issues, as skeletal discrepancies require surgical correction due to growth cessation (9).

#### **3.4.1 Orthodontic treatment in oral rehabilitation**

From a prosthetic treatment perspective, preliminary orthodontic preparation aims to minimize spacing and align teeth within a single area, typically in posterior regions, thereby reducing

restoration size and allowing for a minimally invasive treatment plan with less invasive preparation, preserving the patient's natural dentition. Optimal therapeutic devices for complex root movements should achieve desired results efficiently, ensure aesthetics, offer comfort, minimize discomfort, and facilitate hygiene maintenance. Clear aligners are often favoured for their customizable technology, providing precise three-dimensional control suitable for most cases. In cases of significant palatal deficiency, dental alignment may be preceded by dental-alveolar expansion using devices exerting gentle, consistent force (9).

Treatment steps are as follows:

1 Diagnostic Wax-Up: This step allows the clinician to visualize the final position of the teeth and occlusion (9). This aids in multidisciplinary communication and planning for the right timing of the required treatments for the patient (9).

2 Mock-Up Creation: Based on the diagnostic wax-up, composite mock-up will directly be created in the mouth to accurately simulate functional and aesthetic aspects of the restoration, considering individual anatomical and functional parameters. Treatment interventions are determined based on the degree of vertical dimension loss, guiding choices between direct and indirect restorations or conventional fixed prosthesis (9).

3 Orthodontic Set-Up: This step involves performing orthodontic set-up to realize the approved mock-up by altering the tooth alignment with consideration for pre-prosthetic planning. (9) Aligners are designed to optimize tooth positions, minimizing the need for aggressive preparations by aligning the teeth underlying the mock-up (9).

4 Orthodontic Treatment: While undergoing orthodontic adjustments, the preliminary provisional alignment achieved through the mock-up may no longer align accurately, necessitating modifications in alignment (9). Teeth are moved without removing the mock-up, maintaining aesthetic benefits gained at the beginning of treatment (9).

5 Prosthetic Finalization: Once the orthodontic treatment has finished, teeth alignment is optimized, and the morphology of the mock-up is reworked to accommodate tooth movement. The clinician proceeds with definitive reconstruction, ensuring the chosen technique reproduces the desired aesthetic and functional outcomes (9).

**4. PROSTHETIC PHASE**

Once a patient is indicated and also keen to undergo oral rehabilitation, the general dental practitioner can refer them to a prosthodontist. Prosthodontists devise extensive treatment plans that often involve a mix of periodontal procedures, endodontics, orthodontics, restorative treatments such as crowns, bridges, implants, and removable prostheses, with the aim of restoring oral functionality, aesthetics, and stable occlusion. To ensure optimal dental care, it is crucial to ensure the right sequence of treatment planning as a continuing part of comprehensive dental care program (10).

#### **4.1 Identification of patient needs**

Effective treatment planning depends on accurately identifying the patient's needs. Dentists should avoid imposing an 'ideal' treatment plan on the patient and instead tailor the plan to their specific needs. Presenting multiple treatment options with their respective pros and cons is crucial. If the dentist fails to present the available treatment options, it may be considered as legal negligence. The goals of treatment are to correct existing conditions, prevent future conditions, restore function, and enhance appearance (10).

#### **4.2 Correction of Existing Disease**

Effective management of active diseases involves identifying and eliminating root causes and enhancing treatment factors. For instance, providing oral hygiene advice can reduce plaque, a precursor to dental caries, and decrease the likelihood of further tooth decay. Additionally, these recommendations can improve gum health, resulting in stronger tissue that is less susceptible to infection. For patients with extensive tooth decay, additional preventive measures may be needed, such as using mouthwash, high-fluoride toothpaste, and assessing dietary habits (10).

#### **4.3 Restoration of Function**

During the examination, the evaluation of functional capabilities is performed. If there are any issues with chewing or speaking, treatment suggestions may be offered to help improve them. Before undertaking fixed prosthodontic treatment, it may be necessary to reposition the mandible through occlusal reshaping. Additionally, teeth may be repositioned to better locations using orthodontic methods before replacing the missing teeth (10).

#### **4.4 Improvement of Appearance**

Aesthetics can play a significant role during the oral rehabilitation process and may serve as the primary motivator for patients to begin their treatment. Quite often, patients pursue dental treatments because they are not satisfied with their smile and appearance. Dental practitioners should cultivate proficiency in this domain and be ready to evaluate the aesthetics of the patient's teeth attentively while also attentively considering the patient's perspectives. If the current appearance significantly deviates from socially accepted norms, it is important to discuss the possibility and constraints of corrective measures with the patient. Ensuring dental health in the long run should not be jeopardized by imprudent efforts to enhance appearance (10).

#### **4.5 Occlusion in full mouth rehabilitation according to vertical dimension of occlusion (VDO)**

Category-1: The patient exhibits severe wear, resulting in vertical dimension of occlusion (VDO) to be less. Specifically, the speaking space is more than 1 mm and the interocclusal space is greater than 4 mm. This has led to a loss of facial contour and the corners of the mouth drooping. To address this issue, all of the teeth in one arch must be prepared in one visit, which will help to minimize the increase in VDO and improve aesthetic control (11).

Category-2: The patient has experienced excessive wear without significant loss of VDO. However, there is available space. The patient may have a history of bruxism or paroral habits, but VDO is preserved through continuous eruption. If there was a difficulty in achieving upper retention and resistance form due to smaller crown height, gingivoplasty would be necessary (11).

Category-3: The patient has experienced excessive wear without a significant loss of VDO, but there is limited space available. Centric relation and centric occlusion are closely related, with a minimum speaking distance of 1 millimetre and an interocclusal distance of 2 to 3 millimetres. For successful restorative material placement, the vertical dimension must be established. This can be achieved through restorative, orthodontic and surgical repositioning of segments (11).

#### **4.6 Confirmative and re-organised occlusion**

Restorative therapy typically encompasses two approaches: the confirmatory method, which is generally advised, or the reorganized method. The confirmatory approach entails reconstructing occlusion based on the current intercuspal position, which could be attained once minimal rehabilitative therapy is necessary. Conversely, the reorganized approach establishes a new

occlusal scheme centered on a suitable condylar position, which corresponds to the centric relation position. In cases where the existing intercuspation relation needs to be modified and is not suitable, the patient's occlusion may be reorganized (11).

#### **4.7 Occlusion concepts during eccentric movements**

Depending on the approach and the treatment modalities which are deemed to be necessary and acceptable to the patient, the occlusion of the patient has to be planned for the oral rehabilitation procedure. For instance, a patient with removable prosthesis will be required to have bilaterally balanced articulation, while a patient with periodontal problem will benefit from having a unilaterally balanced articulation than mutually protected articulation.

a) **Bilaterally Balanced Articulation:**

To achieve optimal dental stability in complete denture construction, it is essential to have the maximum number of teeth in full contact during both maximum intercuspation and all excursive positions. The nonworking contact in the denture fabrication process helps prevent it from being dislodged (10).

b) **Unilaterally Balanced Articulation (Group Function):**

During group function, the lateral movement involves contact between all the posterior teeth on the working side. However, lack of contact exists until the mandible has reached centric relation on the medioretrusive side. This could prove advantageous in scenarios where, for example, the canine's periodontal support is weakened. During functional movement, the occlusal force on the working side is spread across the periodontal surface area of all teeth in the quadrant, while at the same time, the posterior teeth remain without contact on the non-working side. Posterior teeth have no contact during protrusion (10).

c) **Mutually Protected Articulation (canine guided):**

When performing lateral movements, on the non-working side, contact does not exist between the teeth, however, there is only the contact between the teeth on the working side, specifically between the laterotrusive canines (10).

## **4.8 Prosthetic phase treatment modalities for oral rehabilitation**

Treatment modalities for oral rehabilitation in prosthodontics encompass a wide range of interventions aimed at restoring oral functionality, aesthetics and overall life quality for patients with complex dental needs.

### **4.8.1 Fixed Prosthodontics**

Fixed dental prostheses and crowns that are metal-based are currently regarded as the best method for achieving successful clinical outcomes and longevity (12). Nevertheless, the substantial removal of tooth structure in these treatments is a major disadvantage.

Fixed prosthodontics treatment modalities have experienced significant advancements lately, driven by three major developments.

- a) There has been a noticeable shift towards minimally invasive procedures facilitated by the integration of adhesive techniques with restorative materials that closely resemble the appearance of natural teeth (12).
- b) Advancements in treatment protocols have enabled a more conservative method to the removal of healthy tooth structure. This involves careful planning through the creation of a wax-up, which serves as a blueprint for tooth preparation procedures (12).
- c) The emergence of digital technology has transformed the field by providing valuable 3D analysis of data, communication and diagnostics. This enhances treatment planning precision and being able to produce it again to the same standards. Furthermore, it streamlines fabrication procedures through computer-aided design/manufacturing (CAD/CAM) processes (12).

#### **4.8.1.1 Minimally invasive concept in fixed prosthodontics**

Preserving as much tooth structure as feasible while carrying out various therapeutic interventions has long been one of the most significant challenges in the field of dentistry. Retrospective clinical studies have demonstrated that the survivability of vital pulps during a 15-year span was 81.2% in metal-ceramic single crowns and only 66.2% in FDP abutment restorations. The primary analysis of teeth preparations with various preparation techniques revealed that full crown preparations in both posterior as well as anterior segments would remove 72% of the clinical crown. In contrast, all-ceramic anterior veneer preparations involve varying degrees of tooth structure removal,

ranging from 7% for partial veneers to 30% for extended veneers. Occlusal onlays with proximal extensions typically remove approximately 32% of the tooth structure (12).

In recent years, less invasive methods have become a method of preference and choice in fixed prosthetic treatments. Research and studies on all-ceramic partial coverage crowns have shown low to no endodontic complications over 7 to 12.6-year observation periods, differing from metal-ceramic full coverage crowns. Regarding veneers, endodontic issue incidence was only 2.51% after a 20-year follow-up span, indicating that less invasive methods may benefit treated teeth (12). As a result, there has been a trend towards less invasive fixed prosthodontics, with more nuanced prosthetic concepts developing over time.

#### **4.8.1.2 Pre-treatment with CAD/CAM polymers**

Pre-treatment with occlusal splints is crucial in structured prosthetic rehabilitations, establishing a stable condylar position and evaluating the adoption of the intended vertical dimension. However, traditional positional splints face limitations due to patient reluctance during daytime wear, attributed to aesthetic and phonetic concerns. They are typically designed for single-jaw use, posing challenges in bimaxillary treatments and may not accurately simulate the occlusal plane of the subsequent restoration. Nevertheless, they remain the preferred choice for alleviation of pain and functional rehabilitation (12).

CAD/CAM-milled polymers offer innovative alternatives in facilitating the treatment of complex oral rehabilitations. Crafted based on diagnostic wax-ups, these splints closely replicate the definitive restoration both functionally and aesthetically. Removable full contour splints allow conservative interventions such as restorative, periodontal and surgical treatments without compromising the newly defined aesthetic and functional equilibrium (12).

Another pre-treatment option involves applying polymethyl methacrylate (PMMA) repositioning onlays and veneers, bonded to compromised teeth or existing restorations. These can be made conventionally or using CAD/CAM technology. PMMA, with higher edge stability compared to ceramics, can be milled into thin layers up to 0.3 mm, serving as additive restorations with no need for preparation of teeth. But, this method is complex, as it is very difficult to manipulate PMMA restorations intraorally, they have limited reversibility, and are costly. Despite this, due to their identical contours to the intended restoration and permanent insertion, patients can consume food while having them, facilitating a realistic period of evaluation (12).



#### **4.8.1.3 All-ceramic anterior veneers in complex oral rehabilitation**

Inspired by the favourable clinical outcomes over an extended period, the application of all-ceramic veneers has broadened to reconsider previous limitations, thereby unlocking novel areas of application. The success of veneer restoration depends on the preservation of enamel, which requires a mainly additive approach in design. This is because veneer preparation, provisionalisation, and adhesive bonding are more challenging than full coverage crown preparation with cementations that are conventional. Today, veneers are also used for restoring dental biomechanics, improving function, and masking discoloured teeth. Preferred material for replacing the enamel that has been lost is silicate ceramic because it is very similar in property to enamel (12).

#### **4.8.1.4 Design options for interproximal extension of anterior veneers**

In the medium wrap design, the height and width of the tooth are kept, with the height determined by the defined width-to-height ratio (12).

In cases of periodontal compromise, the long wrap design may be combined with a horizontal insertion axis, reducing the requirement for substantial coronal tooth structure preparation. This design is particularly favourable in addressing strong discoloration, diastemas, correction of midline, black triangles, and extensive fillings. Additionally, for veneers near crowns, the long wrap design is the method of choice as it facilitates the execution of the contact zone between the adjacent restorations in ceramics (12).

#### **4.8.1.5 All-ceramic occlusal onlays posterior region**

In a clinical study that spanned over 12 years, silicate ceramic onlays demonstrated durable outcomes and proved effective for addressing extensive tooth structure defects. Another study with a 12.6-year observation period reported failure rates for vital teeth to be 20.9%, while the rates for endodontically-treated teeth were significantly higher at 39% (12).

Adhesive only ceramic occlusal onlays have proven their reliability as the option of choice for the posterior region. Considering the significant changes in occlusal contour that can occur due to tooth wear, occlusal onlays made of high-strength glass ceramics that are bonded with adhesive are a superior option to conventional full crowns, which involve twice the level of invasiveness (12).

All-ceramic onlays are a practical treatment choice that allows for a defect-oriented preparation and eliminates the need for an invasive retentive design. They are a suitable option for avoiding conventional methods. The supragingival preparation margins of occlusal onlays provide several advantages, including better control during preparation, reduced loss of dental hard tissue, and less traumatic interference with the marginal gingiva. Additionally, they make it easier to take conventional and digital impressions, provide more available enamel for bonding, and allow for much better controlled adhesive cementation, possibly under a rubber dam (12).

#### **4.8.2 Implant-Supported Prostheses**

Dental implant is made of alloplastic material and serves the purpose of providing support and retention for a fixed or removable prostheses. Dental implants are a remarkable innovation in contemporary dentistry, significantly transforming the domain of oral rehabilitation for individuals with complex dental needs. Undertaking oral rehabilitation with dental implants commences with a thorough evaluation and individualized treatment planning. This entails employing diagnostic imaging to assess the bone and to establish the patient's specific requirements and objectives. After the dental implant placement surgery, there is an associated healing period during which the implants successfully fuse with the bone tissue through the process of osseointegration. Evidence indicates that implants have significantly enhanced the stability and retention of conventional dentures, thereby allowing patients to experience improved chewing and speaking abilities. Tooth loss, especially in the front, affects aesthetics and oral health quality. A cross-sectional study of 95 patients showed high satisfaction with implant-supported restorations' aesthetics and function, even a decade post-implantation (13).

##### Treatment planning

###### a) Oral examination

A comprehensive oral examination is essential. All of the teeth must be examined for hygiene, mobility and caries, alongside the healthiness of surrounding soft tissues. Pocket depths are measured, and edentulous spaces evaluated for ridge size, interarch relationships, and interocclusal space. Periodontal disease or lost teeth due to it does not preclude implant placement. Patient medical history determines suitability, considering conditions affecting healing like leukaemia, radiation therapy, bisphosphonate therapy, autoimmune diseases or poorly controlled diabetes.

Extensive consultation may be needed for autoimmune diseases due to steroid use hindering healing. Tests like serum C-terminal cross-linking telopeptide of type 1 collagen (CTX) is indicated for patients who have had more than 3 years exposure to oral bisphosphonates or having the use of high dose intravenous bisphosphonates to assess suitability for implant placement. Patients must be physically able to undergo procedures, with considerations for conditions like muscular dystrophy or psychological disorders. Tobacco use may increase failure rates but is not a strict contraindication. Controlled diseases requiring precautions may not exclude implants; for example, cardiac conditions may need premedication but do not necessarily prevent implant use. Medications like anticoagulants should be monitored pre-surgery (14).

b) Imaging

Periapical radiographs offer the most detailed information for assessing the condition of the remaining teeth, including bone height and trabeculation (14).

The panoramic radiograph offers a comprehensive view of the maxilla and mandible, revealing essential details such as ridge height, the position of the mandibular canal and mental foramen, trabecular bone pattern, and cortical bone thickness (14).

Cone beam computed tomography (CBCT), a form of computerized axial tomography (CAT), is a vital tool in preoperative planning for dental implant surgery. The advantages of CBCT scans include their non-invasive nature and capacity to deliver important information about the bone structure, location of nerves, sinuses, and adjacent teeth to the surgeon. This data can be utilized by computer programs and companies to develop custom surgical guides. Custom surgical guides result in safer and more predictable outcomes, which ultimately lead to optimal restorative results. (14) A precisely placed dental implant is crucial for achieving an aesthetically pleasing restoration.

c) Diagnostic casts

Diagnostic casts on a semi-adjustable articulator are essential for fixed prosthodontic treatment planning, especially for dental implants. These casts allow for a three-dimensional evaluation of the space between the residual ridge's crest, the opposing dentition's occlusal surface, as well as the faciolingual position of the implant. Typically, 7 millimeters is the minimum mesiodistal and vertical space required for implants and crowns (14). Diagnostic wax-ups and surgical splint fabrication are also facilitated by the casts.

d) Bone evaluation in the intended site of implant

Quality and quantity of the bone of the receptor site plays a significant role in determining whether a site is appropriate for implant placement or not (14).

The standard guideline for the width of bone is 6 millimeters, which permits the insertion of a dental implant with a diameter of 4 millimeters and 1 millimeter of bone on the facial and lingual surfaces. Ideally, the vertical height of bone should be at least 10 millimeters to allow for the placement of a dental implant that is 10 millimeters long, which has demonstrated better success rates compared to implants shorter than 10 millimeters (14).

Classification of bone quality is the following:

1. Almost the entire jaw is homogenous cortical bone (the dense bone has reduced vascularity and recovers more slowly postoperatively) (14).
2. A thick layer of cortical bone surrounding a core of cancellous bone with a dense trabecular pattern (provides good dental implant anchorage) (14).
3. A thin layer of cortical bone surrounding a core of cancellous bone with a dense trabecular pattern (provides good dental implant anchorage) (14).
4. A thin layer of cortical bone surrounding a core of cancellous bone with a low-density trabecular pattern (provides poor implant anchorage unless the opposite cortical plate is also engaged by the dental implant) (14).

e) Determination of ideal implant positioning

It is crucial to ensure dental implants are not placed less than 2 mm, with a preference for 3 mm, from a natural tooth or another implant. Closer proximity between implants can negatively impact the vitality of interimplant bone and soft tissue. Additionally, implants that converge coronally or are positioned too closely may pose challenges during prosthesis attachment screw placement or removal. When replacing posterior teeth, implants should be positioned to ensure that access holes for prosthesis attachment screws align with the central fossa of the teeth. Implants should ideally be vertical or slightly inclined towards the mesial aspect, as accessing an implant with a distal inclination can prove challenging (14).

### **4.8.3 Partial Removable Dental Prosthesis**

The demand for managing partially edentulous cases is expected to rise due to the increasing prevalence of an aging population retaining more teeth, leading to continued high usage of

removable partial dentures. Some patients, unable to pursue implant care, opt for a removable partial denture over a prosthesis supported entirely by implants, contributing to increased use of removable partial dentures. The provision of strategically placed implants should consider their potential usefulness for a future fixed implant prosthesis (15).

Recently, the production of PRDPs has been transformed by the use of digital techniques.

The process involves a series of steps:

A. Scanning

- Alginate impression material used for primary impressions, poured into diagnostic casts.
- Case evaluation and PRDP design planning done from diagnostic casts, abutment teeth preparations planned simultaneously.
- One preparation of teeth is done, arches of the patient will be scanned intraorally or extraorally:
- Scanning intraorally eliminates need for physical impression, requires 3-17 minutes for multiple arch scans, effective in Kennedy class III cases.
- In Kennedy class I and II cases, intraoral scanning may not capture mucosal extension accurately.
- Rubber-based materials for impression can be the alternative for the final impression taking modality, which are then scanned directly with an extraoral digital scanner or made into master casts and then scanned. In general, bench top scanning of the cast models achieves comparable accuracy regardless of the type of dental stone used.
- Stone models and impressions that are scanned extraorally provide appropriate precision.
- Scanner then creates stereolithographic file (STL) of the master casts and sends it to the software for designing (16).

B. Designing

- Utilization of a digital survey tool facilitates automatic determination of the path of insertion.
- The software assesses undercut depth and parallelism, rotating the cast three-dimensionally for optimal tilt in path of insertion, subsequently generating an automated survey line.
- Digital blocking of undesirable undercuts and identification of sites for retentive clasp tip placement.

- Virtual wax layers applied on relief areas like the rugae, followed by creation and addition of meshwork patterns, major connectors, and rests.
- Three-dimensional drawing of clasp systems and arms, with adjustment and smoothing of framework thickness.
- Drawing of connectors, clasps, rests, and finish lines.
- Designing of a sprue for casting.
- The entire design process typically takes approximately 30 minutes for each framework.

### C. Fabrication

The production machine receives the design file. The frameworks are constructed by using direct or indirect manufacturing processes (16).

#### **4.8.4 Complete Removable Dentures**

In the context of public health, complete denture prosthodontics is a cost-effective and widely applicable treatment option that is commonly used (17).

Implant-supported or implant-retained prostheses may not be suitable for some individuals due to factors such as economic limitations, systemic conditions that make surgery inadvisable, poor oral hygiene, lack of appropriate quality and quantity of bone, or previous chemotherapy or radiation therapy of the head and neck, therefore complete removable dentures can be a good alternative (18). In today's era of digitalization and modern advancements, dentures can now be fabricated digitally in their entirety. Utilizing digital techniques during complete removable dentures production has several advantages during stages of the laboratory, but the downside is that it is impossible to use optical cameras to determine the depth of oral mucosa. As a result, conventional impression techniques are still necessary for this prosthetic procedure (19).

Two methods can be differentiated when it comes to the digital fabrication of full prosthetic devices and other components:

- a) Subtractive or milling technique using CAD/CAM
- b) Additive or 3D printing technique (18)

#### **4.8.4.1 Conventional compared to Digital techniques:**

Patients often express a preference for digital complete dentures over conventional ones, largely due to much shorter therapeutic timeline, which only require 2 appointments in the digital technique, whereas the conventional requires five. However, patients expressed significantly more satisfaction with conventional dentures compared to digital ones overall. Among digital options, patients preferred milled dentures compared to 3D printed versions (18). This preference is partially due to the need for a thicker base in printed dentures (minimum 2.5 mm) compared to milled and conventional ones (1.4 mm), leading to enhanced comfort while speaking. Milled and conventional dentures also offer advantages in terms of tooth material, with harder resin providing better colour stability and resemblance to natural teeth, as well as easier maintenance. Additionally, conventional dentures allow for easier adjustment of tooth angulation, particularly in the anterior region, while milled dentures present challenges in individual tooth angulation due to being milled from a single piece. Patients also appreciate the better stability of conventional dentures, as it showed a better peripheral seal and much better occlusal contacts than the ones produced digitally (18).

**5. COMMITMENT TO POST-TREATMENT CARE**



Once the treatment has finished, the post-treatment follow-ups are equally as significant in order to make sure the longevity of the treatment. It is important to clearly outline and communicate the maintenance required in Phase III to patients. This information should be included in a written treatment plan that the patient signs. Teaching the best practice should start at the beginning of any prosthodontics program. In order to guarantee patient cooperation and prevent potential future problems, it is essential to thoroughly, respectfully, accurately, and consistently convey the criteria of Phase III. Informing the patient from the outset that maintaining their new prosthesis and overall oral health is essential for their long-term well-being is important. This explanation should be given in the presence of a witness for professionalism. There is a mutual relationship between the dental office's recall practices, the patient's goodwill and commitment, and the patient's ability to follow the prosthodontist's post-treatment maintenance advice effectively (Figure 4.1) (4).

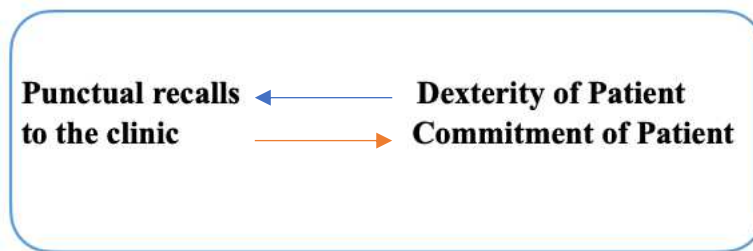


Figure 1. Post-treatment maintenance (4).

### **5.1 Post-treatment education for patients and commitments of the clinicians**

Informing patients about post-treatment care and follow-up is essential. It is important to explain the significance and details of these concepts clearly. Maintaining an ongoing dialogue with patients throughout their treatment is vital. Efforts should focus on changing their attitudes using evidence-based approaches.

Patients should be gently, yet persuasively, informed that a structured plan for dental cleaning and management is both reasonable and beneficial. This understanding should be established before they sign the treatment plan. Additionally, it is important to emphasize that adhering to the post-treatment care plan can prevent future complications, reduce the likelihood of additional procedures, and ensure the longevity of their prosthetic work.

Clinicians should avoid making patients feel that their lives are being intruded upon or that their habits and behaviours are being controlled. Instead, they should use their intelligence, persuasive

skills, and good judgment, incorporating humour when suitable, to convince patients that the advice given is for their well-being. Moreover, clinicians can provide educational materials, such as brochures or videos, to reinforce the importance of post-treatment care. Regular follow-up appointments can also be scheduled to monitor progress and address any concerns promptly.

Creating a supportive and empathetic environment in the dental office can help build trust and encourage patients to commit to their post-treatment care plan. By demonstrating a genuine interest in their overall health and well-being, clinicians can foster a positive relationship with patients, making it more likely that they will adhere to the recommended maintenance and care guidelines (4).

## **5.2 Patient Adherence and Specialized Maintenance Programs**

Research does not indicate a correlation between patient adherence and factors like age, gender, ethnicity, or cognitive ability. However, it is frequently observed in practical application that certain patients fail to follow post-treatment maintenance schedules as prescribed. Many patients neglect their maintenance check-ups after receiving prosthodontic treatments, which frequently results in a recurrence of the initial issues that necessitated their visit to the dental clinic. To address this issue, patients with lower levels of adherence should be scheduled for more frequent clinical check-ups. Implementing a “holding program” can serve both educational and motivational purposes, encouraging better maintenance habits. This approach should be undertaken with sensitivity, and obtaining the patient’s written and signed consent on the treatment plan is essential. Improving communication with patients is vital. Avoid language, tone, or gestures that might be perceived as condescending or punitive. Maintain empathy and sensitivity, using examples of issues faced by patients who neglected their oral health. Explain in a kind and gentle manner that your primary aim is to provide them with the best care possible (4).

## **5.3 Clinicians recommended protocol for checking fixed prosthesis**

It is generally recommended to evaluate the patients’ oral hygiene in the days and weeks after receiving a prosthesis. By doing so, we can ensure that they are following the instructions provided and maintaining good oral hygiene practices. You must also evaluate the recently provided prosthesis to ensure it appears and feels secure and operates effectively as intended.

During examination clinician must check for:

1. Existence of plaque/calculus
2. If probing depth is severe around abutments or any tooth
3. Bleeding on probing
4. Caries
5. Checking for mobility, decementation, implant screw loosening
6. Checking colour of prosthesis
7. Checking for cracks
8. Checking whether patient has any occlusion problems
9. Checking if the interproximal contacts are maintained (4)

#### **5.4 Clinicians recommended protocol for checking removable partial denture**

Once treatment is finished, the patient has to be seen after 24 hours. Then, the patient has to be seen after 1<sup>st</sup> week and 2<sup>nd</sup> week. Once the 2<sup>nd</sup> week appointment is done, the patient will have to be seen when required or they ask to be seen by the clinician.

Clinicians must always consider the patients' feedbacks regarding whether their prosthesis is functioning well for them or not, and if they want any ailments to be done.

During examination, the clinician must check for:

1. Facial and Physical examinations:
  - a. Appearance of the face of the patient
  - b. Whether the patient has a problem with gagging
  - c. Phonetics of the patient
  - d. Position of the lower and upper lips.
  - h. Vertical dimension of occlusion
2. Mandibular and maxillary teeth mobility checks
3. Stability of components of the framework of the prosthesis
4. Occlusal contact checks.
5. Checking for food impaction under the prosthesis
6. Checking for trauma of soft tissues (4)

### **5.5 Clinicians recommended protocol for checking complete denture**

Once treatment is finished, the patient has to be seen after 24 hours. Then, the patient has to be seen after 1<sup>st</sup> week and 2<sup>nd</sup> week. Once the 2<sup>nd</sup> week appointment is done, the patient will have to be seen when it required or they ask to be seen by the clinician.

During examination clinician must check for:

#### 1. Physical

- a. Whether the patient has developed any physical conditions
- b. Whether the patient has suffered significant weight loss

#### 2. Facial and physical examination:

- a. Whether patient has any complaints
- b. Appearance of the face of the patient
- c. Whether patient has parafunctions
- d. Support of lower and upper lips
- e. Colour of teeth and how much they are displayed
- f. Patients phonetics
- g. Vertical dimension of occlusion of patient

#### 3. Intraoral examination:

- a. Gagging
- b. Sore areas and ulcerations
- c. Burning sensation (palate)
- d. Bleeding
- e. Pathological lesion, lumps and bumps
- f. Fungal infections under the denture.
- g. Palatal, retromolar pad and peripheral border seals
- h. Whether patient has any issues swallowing
- i. Food impaction under prosthesis
- j. Checking the midline
- k. Retention, stability and support of the denture
- l. Saliva level check (4)

**6. DISCUSSION**

Oral rehabilitation is a multifaceted process that necessitates a customised approach based on the unique circumstances and needs of each patient. From the moment a patient enters a dental office, it is the primary responsibility of the clinician to establish a rapport of trust and understanding with the patient. It is crucial to address any urgent matters before proceeding with other aspects of complex oral rehabilitation. However, regrettably, it has become increasingly common in dental practices around the world for clinicians to prioritize the business aspects of dentistry over patient care. While it is comprehensible that clinicians must make a living from their practice, it is equally crucial for healthcare professionals to prioritize the duty of care towards their patients. Consequently, when devising treatment plans for complex cases that may involve considerable financial investments from the patient, it is imperative to present them with all available treatment options and the associated costs, as well as our own recommendations, enabling the patient to make an informed decision regarding their oral rehabilitation treatment plan.

The first and foremost step is using a comprehensive examination methodology. It is absolutely crucial to use this method over the second method of examination, which is the examination of particular condition or region. I would argue that prosthodontist should not use this method practically in no case of complex oral rehabilitation. It could be understandable, if, for instance, the patient attends for periodontal treatment and the periodontist must focus on one region for the treatment, but a prosthodontist must have a holistic view ensuring no critical detail is omitted from the treatment plan. Once the diagnosis is done, the patient will be classified into one of the 3 classes, and in each they have to take different routes of treatments. Class 1 patients encompass patients free from viral or bacterial infections. Consequently, for patients in this group, only prosthodontists are required, and collaboration with other specialists is unnecessary (4). In class 2, patients do not have any viral or bacterial infectious diseases. However, collaboration with other specialists, such as an orthodontist, maxillofacial surgeon, oral surgeon, and/or periodontist, is necessary (4). In class 3, all prosthetic rehabilitations involve oral cavities affected by one or more bacterial and/or viral oral diseases, and collaboration with specialists becomes crucial (4).

## 6.1 Limitations of Multidisciplinary approach

As discussed previously, complex prosthodontic cases require a very well-structured plan which can bring about quite a few limitations and complications along the way which could lead to failure. Some of these limitations are the following:

1. The adoption of a multidisciplinary approach in healthcare settings may engender discordant viewpoints among different specialities, potentially impeding the treatment timeline and posing challenges for patients. Consequently, it is imperative for healthcare practitioners to institute well-defined communication channels and procedural guidelines within multidisciplinary teams, aiming to adeptly address conflicting perspectives and facilitate prompt treatment delivery to patients. Through such measures, healthcare professionals can collaboratively navigate complexities and uphold patient-centered care, thereby optimizing treatment outcomes and ensuring timely interventions in prosthodontic rehabilitation cases of heightened intricacy.

2. As discussed, there are several steps and possibly several specialities involved in order to individualise and customise the best possible treatment plan for the patient. However, achieving optimal treatment outcomes through a multidisciplinary approach is not always feasible or practical. Ideally, each aspect of dental care would be conducted by a specialist in that particular field, ensuring the highest quality of treatment for the patient. However, this approach may present challenges from the patient's perspective, particularly in terms of cost. For example, a treatment plan that necessitates interventions from multiple specialists, such as root canal treatments by an endodontist, periodontal therapy by a periodontist, and orthodontic alignment prior to prosthodontic procedures, can impose significant financial burden on the patient. As a result, many patients may be deterred from pursuing such comprehensive treatment plans due to financial constraints.

3. Research findings indicate a notable disparity in the survivability of dental prostheses based on whether they were obtained through insurance coverage or private dental offices. Specifically, prostheses covered by insurance exhibited a median survival of 2 years, contrasting starkly with the 17-year median survival observed for those acquired through private dental channels. (21) This disparity underscores socioeconomic discrepancies in access to comprehensive oral rehabilitation,

highlighting how individuals from different social strata may not receive equivalent levels of prosthetic care.

4. The efficacy of the final treatment outcome may be compromised if any of the involved specialists fail to adhere to the established standards at any stage of their respective responsibilities. The application of a multidisciplinary approach in such cases can yield outcomes of variable nature, often contingent upon the sensitivity and precision of the techniques employed. For instance, in scenarios where a patient undergoes root canal treatments performed by an endodontist, the overall success of the treatment may be undermined if any aspect of the procedure fails to meet the requisite standards of excellence.

5. The effectiveness of a multidisciplinary approach is intricately linked to patient engagement, presenting a notable challenge. While patients may exhibit high levels of motivation at the initiation and conclusion of treatment, maintaining consistency throughout the intervening periods can prove arduous, potentially resulting in treatment abandonment or non-adherence to prescribed instructions and appointment schedules. These circumstances could significantly impact treatment outcomes. Hence, it becomes imperative to formulate strategies aimed at sustaining patient motivation and involvement throughout the entirety of the treatment continuum, particularly during the intervals between appointments and follow-up sessions.

## **6.2 Effectiveness of various treatment options**

Survey data encompassing 1703 fixed dental prostheses (FDP) and 815 removable dental prostheses (RDP) were analysed. The investigation revealed a notable disparity in the median survival rates between fixed and removable dental prostheses. Specifically, fixed dental prostheses exhibited a median survival rate of 17 years, indicating a comparatively longer longevity when compared to removable dental prostheses, which demonstrated a median survival rate of 12 years (21).

Another study with a 12.6-year observation period reported failure rates for vital teeth were reported to be 20.9%, while the rates for endodontically-treated teeth were significantly higher at 39% (12). Therefore, keeping the vitality of teeth can improve the prosthodontic prognosis as well.



Moreover, the selection of restorative materials significantly impacted the longevity of the dental restorations. Notably, all-ceramic materials exhibited the highest survivability, with a median of 20 years, followed by precious metals at 18 years, porcelain fused to metal at 15 years, and non-precious metals at 14 years (21). It is crucial to acknowledge; however, that the reliability of these findings may be compromised by the limited number of cases exceeding 10 years of usage, particularly in the context of Zirconia restorations. Thus, caution is warranted in interpreting these results as representative of broader trends. Consequently, future research endeavours should prioritize the collection of long-term follow-up data to provide a more comprehensive understanding of the survivability of Zirconia and other all-ceramic materials. Additionally, it is noteworthy that the majority of analysed all-ceramic restorations were employed as single-unit or three-unit prostheses, which inherently subjects them to lesser loads and stresses compared to larger-scale bridges and prostheses. Therefore, the extrapolation of these findings to more extensive restorations necessitates careful consideration and warrants further investigation for a more accurate assessment of their long-term performance (21).

### **6.3 Post-treatment care**

It can be argued that as much as the whole process of diagnosis, treatment planning and delivery of the prosthesis is important there is an equal significance for the maintenance part of the prosthesis. Many patients neglect oral hygiene. It has been shown that plaque index (PI) influences the survival rates of the prostheses directly. Patients who had plaque indexes 0 and 1 had median survival of 18 years for their prostheses, while patients with plaque index 2 had 14 and plaque index 3 with 11 years of survivability of their prostheses (21). This is a significant difference and shows the importance of patient compliance of oral hygiene and attending appointments for regular check-ups and professional cleaning.



The initial diagnostic planning stage is the most critical phase of the prosthodontic procedure since it marks the beginning and development of the entire restoration process (4). Personalized treatment strategies are crucial for meeting the unique needs of each patient, and it is essential to communicate these strategies clearly and comprehensively to the patient (4). We should always aim to communicate with patients about the realities of their conditions, including the restrictions imposed by the clinical environment, financial constraints, and time constraints. It is helpful and informative to explain to patients the clinical significance and practical indicators of their subjective symptoms in a tactful manner, without causing any offense. This approach assists in aligning their expectations with reality as much as possible (4). General dentists and other specialists each play their part in complex oral rehabilitation. As a general dentist, one has significant responsibilities that include promptly identifying and diagnosing oral health issues, promoting oral health, providing education, and delivering care and services (6). Endodontic therapy, when combined with an appropriate restoration, typically offers a practical and cost-effective solution for maintaining function in the majority of cases (7). The significance of a periodontist's role in the diagnosis and planning of complex oral rehabilitation cases cannot be overstated, as the health of the periodontium is paramount. If adequate periodontal health is not present, oral rehabilitation treatments, including crowns, bridges, and dental implants, may be affected negatively (8). From a prosthetic treatment perspective, preliminary orthodontic preparation aims to minimize spacing and align teeth within a single area, typically in posterior regions, thereby reducing restoration size and allowing for a minimally invasive treatment plan with less invasive preparation, preserving the patient's natural dentition (9). In the context of prosthetic treatment, preliminary orthodontic preparation focuses on confining the available space and aligning teeth in a concentrated area, primarily in the posterior teeth. By doing so, this approach ensures a smaller restoration size and allows for a minimally invasive treatment plan with minimal tooth removal, thereby preserving the patient's natural teeth (10). Once the treatment has finished, the post-treatment follow-ups are equally as significant in order to ensure the longevity of the treatment (4).

**8. LITERATURE**

1. Vivek V Nair. Complete Oral Rehabilitation - An Overview. *The Journal of Prosthetic And Implant Dentistry*. 2019; 2(2):85-91.
2. Gross MD, Gracis S, Gamborena I, Meyenberg K, Shifman A, Nissan J. *The science and art of occlusion and oral rehabilitation*. London: Quintessence Publishing; 2015.
3. Maiorana C, Andreoni D, Polacco P, Poli PP. Multidisciplinary oral rehabilitation of a severely compromised dentition. *Case Reports in Dentistry*. 2020;2020:1–7.
4. Calvani L. *Fundamentals of treatment planning : guidelines on how to develop, plan, write and deliver a prosthodontics care project*. Chicago: Quintessence Publishing Co, Inc; 2020.
5. Rodrigues A HC. *Treatment planning in restorative dentistry and implant prosthodontics*. Batavia, IL: Quintessence Publishing Co, Inc; 2020.
6. Nwoku Alagumba L. The Role of General Dental Practitioner in Oral Health. *Niger Med J*. 2010; 51(3):125-127.
7. Saad A, Al Shareef A. Endodontic therapy and restorative rehabilitation versus extraction and implant replacement. *Saudi Endod J*. 2013 ;3(3):107-13.
8. Wolf HF, Hassell TM, Rateitschak-Pluss EM, Rateitschak KH. *Color Atlas of Dental Medicine: Periodontology*. Stuttgart: Georg Thieme Verlag; 2005.
9. Foschi D, Abate A, Maspero C, Solimei L, Lanteri C, Lanteri V. Method presentation of a new integrated orthodontic-conservative approach for minimally invasive full mouth rehabilitation: Speed up therapy. *Biomedicines*. 2022 Oct 11 ;10(10):1-15.
10. Rosentiel SF, Land MF, Fujimoto J. *Contemporary Fixed Prosthodontics, Fifth Edition*. Missouri: Elsevier; 2016.

11. Sharma DrA, Sharma DrI, Kaushik DrM, Kumar DrA, Hena Dr, Chowdhury C. Various concepts of occlusion in full mouth rehabilitation: A Review. *International Journal of Applied Dental Sciences*. 2020 Jul 1;6(3):560–564.
12. Edelhoff D, Stimmelmayer M, Schweiger J, Ahlers MO, Güth J-F. Advances in materials and concepts in fixed prosthodontics: A selection of possible treatment modalities. *British Dental Journal*. 2019 May;226(10):739–748. .
13. Barve N, Bhandari J, Adhapure P, Baig N, Jadhav V, Vispute S. Full mouth rehabilitation by implant supported fixed prosthesis. *Contemporary Clinical Dentistry*. 2020;11(2):199.
14. Duong HY, Rocuzzo A, Stähli A, Salvi GE, Lang NP, Sculean A. Oral health-related quality of life of patients rehabilitated with fixed and removable implant-supported dental prostheses. *Periodontology 2000*. 2022; 88:201–237.
15. Shillingburg HT, Stone SE, Al E. *Fundamentals of fixed prosthodontics*. Hanover Park, IL: Quintessence Pub; 2012.
16. McCracken WL, Carr AB, Brown DT. *McCracken’s removable partial prosthodontics*. 13th ed. St. Louis: Elsevier; 2016.
17. Tamimi F, Almufleh B, Caron E, Alageel O. Digital removable partial dentures. *Clinical Dentistry Reviewed*. 2020 May 4;4(1):4-12.
18. Zarb GA. *Prosthodontic treatment for edentulous patients : complete dentures and implant-supported prostheses*. St. Louis, Mo.: Elsevier Mosby; 2013.
19. Dib Zakkour S, Dib Zakkour J, Guadilla Y, Montero J, Dib A. Comparative evaluation of the digital workflow and conventional method in manufacturing complete removal prostheses. *Materials*. 2023 Oct 30;16(21):2-10.

20. Bonnet G, Batisse C, Bessadet M, Nicolas E, Veyrune J-L. A new digital denture procedure: A first practitioners appraisal. BMC Oral Health. 2017 Dec ;17(1):1-5.

21. Jeon HI, Yoon JH, Jeong Hoon Kim, Kim DW, Oh N, Park YB. Standardized multi-institutional data analysis of fixed and removable prosthesis: estimation of life expectancy with regards to variable risk factors. The journal of advanced prosthodontics. 2024 Jan 1;16(2):67–70.

Mohsen Ebadollahi Novin pursued his pre-university education at Connell Sixth Form College in Manchester, United Kingdom, and later attended the University of East Anglia in Norwich, where he studied in order to obtain his Master of Pharmacy degree from 2015 to 2017. Subsequently, he pursued his dream of becoming a dentist in the European Union at the University of Zagreb in Croatia, where he studied in order to obtain his Doctor of Dental Medicine.

Throughout his academic journey, Mohsen worked as a pharmacy assistant across various locations in the United Kingdom. In his sixth year of university, he gained practical experience by working at Premium Dent, a modern dental office in Zagreb. Mohsen has a strong interest in prosthodontics and implantology and is a proponent of using advanced technologies in dentistry, such as scanners and magnification loupes. He has also attended additional courses to familiarize himself with the rules and regulations in the UK for practicing dentistry. Moreover, he has completed a Basic Life Support course to prepare himself for emergencies in the dental office.

Mohsen is fluent in English, Persian, and Turkish and has a significant understanding of the Arabic language. Additionally, he holds a Black Belt in the martial art of Aikido.