

Implant prosthetic possibilities for rehabilitation of atrophic jaws

Bokavšek, Lorena

Master's thesis / Diplomski rad

2024

Degree Grantor / Ustanova koja je dodijelila akademski / stručni stupanj: **University of Zagreb, School of Dental Medicine / Sveučilište u Zagrebu, Stomatološki fakultet**

Permanent link / Trajna poveznica: <https://um.nsk.hr/um:nbn:hr:127:201302>

Rights / Prava: [In copyright / Zaštićeno autorskim pravom.](#)

Download date / Datum preuzimanja: **2024-07-10**



Repository / Repozitorij:

[University of Zagreb School of Dental Medicine
Repository](#)





University of Zagreb
School of Dental Medicine

Lorena Bokavšek

**IMPLANT PROSTHETIC POSSIBILITIES
FOR REHABILITATION OF ATROPHIC
JAWS**

GRADUATE THESIS

Zagreb, 2024

The work was carried out at: Department of Oral surgery, School of Dental Medicine, University of Zagreb

Thesis mentor: dr.sc. Tomislav Katanec, Department of Oral surgery, School of Dental Medicine, University of Zagreb

English language proofreader: Ivana Pločkinić, MA in History and English Language and History

Croatian language proofreader: Marina Jadrić, Graduate classroom teacher with and enhanced program in Croatian language

The manuscript contains: 48 pages

0 tables

22 pictures

The paper is an author's own work, which is completely independently written with an indication of the sources of other authors and documents used in the paper. Unless otherwise stated, all illustrations (tables, pictures, etc.) in the paper are the original contribution of the author of the thesis. The author is responsible for obtaining permission for the use of illustrations that are not his original contribution, as well as for any possible consequences that may arise due to unauthorized downloading of illustrations or failure to indicate their origin.

Proclamation or Dedication or Thanks

Firstly, I want to thank my mentor dr.sc. Tomislav Katanec for helping me with his advices while writing this thesis. Also, my thanks go to all the professors I had a chance to meet during the course of my studies.

A special thanks goes to my family, thank you for your love and support.

IMPLANT PROSTHETIC POSSIBILITIES FOR REHABILITATION OF ATROPHIC JAWS

Summary

Edentulism presents a significant issue for both patients, impacting their psychophysiological well-being, and for dentists, posing challenges in planning appropriate treatments. Advances in technology, materials, and surgical methods have progressively improved individual quality of life. Given that there is no universal solution for all patients, treatment plans must be tailored to address each individual's specific needs in the most suitable manner.

Alveolar ridge atrophy, resulting from extractions, plays a crucial role in planning implant-prosthetic rehabilitation. Various techniques have been described to compensate for or correct the loss of bone structure. The most commonly used methods include bone augmentation and vestibuloplasty. Bone augmentation aims to provide sufficient bone material necessary for dental implant placement, utilizing biological materials such as bone grafts and membranes. Vestibuloplasty involves deepening the vestibular sulcus to increase the seating area for proper fit of complete and partial dentures.

The application of these techniques ensures better and more predictable outcomes for the implant-prosthetic rehabilitation of atrophic jaws.

Keywords: alveolar ridge atrophy, edentulism, bone augmentation, vestibuloplasty

IMPLANTOLOŠKE MOGUĆNOSTI SANACIJE BEZUBIH ATROFIČNIH ČELJUSTI

Sažetak

Bezubost kao stanje predstavlja značajan problem kako za pacijenta, utječući na njegove psihofiziološke aspekte, tako i za stomatologa, stvarajući izazov pri planiranju adekvatne terapije. Napretkom tehnologije i materijala, te usavršavanjem operativnih metoda, kvaliteta života pojedinca danas postaje sve bolja. S obzirom na to da ne postoji jedinstveno rješenje kojim bi se moglo pristupiti svim pacijentima, izrada plana terapije mora biti usmjerena prema pojedincu i rješavanju njegova problema na najprikladniji mogući način.

Atrofija alveolarnog gebena nastala kao posljedica ekstrakcija može igrati značajnu ulogu pri planiranju implantoprotetske rehabilitacije, stoga su opisane brojne tehnike kojima se gubitak koštane strukture može nadomjestiti, odnosno korigirati. Najčešće korištene metode koje se upotrebljavaju u tu svrhu uključuju augmentaciju kosti i vestibuloplastiku. Augmentacijom kosti nastoji se osigurati dovoljno koštanog materijala potrebnoga za ugradnju dentalnih implantata, a u tu svrhu se koriste biološki materijali kao što su koštani graftovi i membrane. Vestibuloplastika podrazumijeva produbljenje vestibularne brazde s ciljem povećanja ležišta za pravilan dosjed potpunih i djelomičnih proteza.

Primjenom ovih tehnika osiguravaju se bolji i predvidljiviji krajnji rezultati implantoprotetske sanacije atrofičnih čeljusti.

Ključne riječi: atrofija alveolarnog grebena, bezubost, augmentacija kosti, vestibuloplastika

TABLE OF CONTENTS

1. INTRODUCTION.....	2
2. ANATOMY OF ALVEOLAR PROCESS.....	4
3. RESORPTION AND ATROPHY OF ALVEOLAR RIDGE	6
4. CLASSIFICATION OF BONE DEFECTS	9
4.1. <i>Seibert classification</i>	10
4.2. <i>Lekholm and Zarb classification</i>	10
4.3. <i>Allan classification</i>	11
4.4. <i>Misch and Judy classification</i>	12
5. TECHNIQUES FOR THE PREVENTION OF RESORPTION OF THE ALVEOLAR RIDGE	13
5.1. <i>Alveolar Socket Preservation</i>	14
5.2. <i>Immediate Implantation</i>	15
6. PREPROSTHETIC SURGERY.....	16
6.1. <i>Usage of biomaterials for bone augmentation</i>	17
6.1.1. Autologous bone graft (autografts)	17
6.1.2. Allogeneic bone graft	18
6.1.3. Xenogeneic bone substitutes	19
6.1.4. Alloplastic bone substitutes	20
6.1.5. PRP/PRF	20
6.1.6 Biological membranes	21
6.2. <i>Vestibuloplasty</i>	21
6.2.1. Tissue defect methods	22
6.2.2. Open methods	23
6.2.3. Closed Methods of Vestibuloplasty	25
6.2.4. Upper jaw vestibuloplasty with secondary epithelization using PRF	25
6.2.5. Lower jaw vestibuloplasty and short implant placement	29
7. DISCUSSION.....	39
8. CONCLUSION.....	41
9. LITERATURE	43
10. BIOGRAPHY	47

List of abbreviations

RRR - reduction of residual ridge

FDBA - freeze-dried bone allografts

DFDBA - demineralized freeze-dried bone allografts

TCP - tricalcium phosphates

HA - hydroxyapatite

PRP - platelet-rich plasma

PRF - platelet-rich fibrin

GBR - guided bone regeneration

e-PTFE - Expanded polytetrafluoroethylene

1. INTRODUCTION

Throughout the course of human history, the experience of illness has been a daily occurrence. It is challenging for us, with our modern perspective, to fathom the methods our ancestors employed to address and alleviate pain using the limited resources available to them. Findings of early juvenile periodontitis, the occurrence of cavities and dental implants made of iron, date back thousands of years before the common era, so we can say that dentistry, in its primitive form, has been practiced throughout the entire history of human existence (1). With the development of science and technology, dentistry has also evolved, so today it offers numerous therapeutic solutions in all its branches, significantly improving the quality of life for individuals.

The prevalence of edentulism, particularly among the elderly, has been a persistent public health concern throughout history and continues to pose challenges today. While studies show a decreasing trend in edentulism across generations, the increasing life expectancy due to advances in medicine has led to a larger population of elderly individuals, perpetuating this widespread issue (2). Addressing the demand for dental tissue replacement has been a significant challenge for dentists. Traditional approaches using complete or partial dentures have often proven uncomfortable for patients, prompting the exploration of more effective methods. The evolution of implantology, particularly the advancement of root-shaped osseointegrated implants, has offered improved solutions that prioritize patient comfort (3). The success of treatment significantly hinges on a comprehensive and personalized treatment plan, recognizing that there is no one-size-fits-all solution. Furthermore, effective collaboration between the patient and the dental team is essential for a successful outcome.

The stomatognathic system is a complex and highly organized group of structures that form a unique functional and aesthetic unit. It consists of craniofacial bones (mandible and maxilla), teeth, masticatory muscles, the temporomandibular joint, and neurovascular elements (4). All these structures work in harmony to perform various functional tasks.

The loss of teeth disrupts the integrity of the stomatognathic system, leading to a series of problems related to physiological processes such as chewing, swallowing, and ultimately, the digestion of ingested food. Additionally, the ability of proper articulation is lost. Alongside

physiological aspects, psychological issues also arise. Individuals with compromised oral aesthetics suffer from social prejudices and often hide their mouths while speaking or laughing. Thus, it can be said that having a healthy and restored oral cavity is of utmost importance for a better quality of life.

The purpose of this thesis was to present the oral surgical possibilities for the rehabilitation of edentulous atrophic jaws by applying bone augmentation techniques, vestibuloplasty, and immediate implantation using extra-short implants.

2. ANATOMY OF ALVEOLAR PROCESS

With the eruption of teeth in the upper and lower jaws, the alveolar process develops and forms, and with their loss, it gradually disappears, therefore, we can define it as bone tissue that depends on the teeth. Within the alveolar process, we distinguish three components (5):

- true alveolar bone (lamina cribriformis),
- spongy bone, and
- compact bone.

The external compact bone consists of two plates that cover the alveolar process, within which we find spongy bone. The spongy bone separates the compact bone from the true alveolar bone along the entire alveolar process, except in the area of the alveolar ridge. Unlike cortical bone, spongy bone has lower density, greater elasticity, and a higher rate of renewal during the remodeling process. It performs the main metabolic function (6). The true alveolar bone forms an alveolar wall and is permeated with numerous small openings - Volkmann's canals, through which vessels and nerves enter and exit into the area of the periodontal ligament. In radiological interpretation, the true alveolar bone is called lamina dura. Apically to the root of the tooth, as an extension of the alveolar process, the basal bone continues, which is not subject to resorption (6,7)

3. RESORPTION AND ATROPHY OF ALVEOLAR RIDGE

Through the process of bone remodelling, existing bone is replaced with new bone, adapting its structure and shape to a new function. This process actively occurs throughout life and is regulated by the coordinated activity of osteoblasts and osteoclasts organized within bone multicellular units. Osteoblasts are the cells responsible for producing the bone matrix and its mineralization, while osteoclasts are giant multinucleated cells that cause bone resorption through proteolysis of the bone matrix (6). If an imbalance occurs between these two processes and osteoclastic activity prevails, bone resorption occurs. After extraction and the accompanying healing of bone and soft tissues, the clinical alveolar ridge is called the residual alveolar ridge (RRR) (8). The residual ridge is covered by a thin layer of cortical bone, underneath which lies spongy bone (5).

The resorption of the alveolar ridge is an irreversible process characterized by a reduction in the horizontal and vertical dimensions of the alveolar bone, occurring first in the bucco-lingual direction and then in the corono-apical direction (7). It can result from physiological changes after tooth extraction or pathological conditions such as periodontitis, osteitis, or neoplasms.

Anatomical changes within the alveolar process are an inevitable consequence of the loss of one or more teeth. With the loss of teeth, the bone loses its primary function, leading to a significant reduction in the alveolar ridge. While teeth are present in the jaws, the pressures they cause during the contraction of masticatory muscles are transmitted as tension to the bone via the periodontal membrane. This type of stress is beneficial for the alveolar bone and can even stimulate its remodeling. Without teeth, the distribution of forces changes, and the load is directed only on the bone surface, leading to its compression and consequently to resorption (8). Whether the patient wears a removable denture or not, the resorption process persists, and it is accelerated by unstable and inadequately made dentures that are not anchored on at least two implants or are not "overdentures." Resorptive changes are more pronounced in the mandible than in the maxilla, as the mandible does not have a palatal plate to bear part of the masticatory load, directing all pressure only towards the alveolar ridge (7).

The resorption of the alveolar ridge affects all edentulous areas and can be horizontal or vertical (7). Horizontal resorption involves uniform resorption of the residual ridge surface in

the apico-coronal direction, starting from the thinner alveolar wall where it occurs faster. Vertical resorption is uneven; a defect in the vertical direction forms only in one part of the ridge surface, while changes in other parts of the ridge are minimal (9). The greatest bone loss occurs on the buccal side, in the horizontal dimension, ultimately leading to narrowing of the alveolar ridge and its displacement to a more palatal or lingual position. The resorption process is most pronounced in the first six months to two years after extraction, but osteoclastic activity continues throughout life, contributing to significant bone loss (6). Atrophy is clinically manifested as uniform or uneven. Also, a combination of both can often be found in the same patient. Both forms of atrophy are usually the result of multiple extractions at different times, where less resorbed alveoli appear as protrusions, and more resorbed alveoli as depressions. Uneven atrophy represents unevenly distributed bone tissue deficiency in the area of attached gingiva, making it impossible to create an adequate denture due to the uneven surface that prevents proper fit and causes pain during mastication. In the case of uniform atrophy, the alveolar ridge atrophies without bone protrusions, usually as a result of physiological processes. The attached gingiva often follows the regression of the alveolar ridge, so with its reduction, the band of attached gingiva also decreases. In some cases, the attached gingiva retains its shape while the ridge atrophies, forming bag-like hangings on the alveolar crest. Due to irritation and parafunction, especially from mobile prosthetic replacements that do not fit adequately on the ridge, soft tissue hypertrophy can occur alongside bone atrophy (10).

Factors associated with alveolar ridge resorption can be of local or systemic origin, such as (10):

- quality, size, and shape of the residual ridge after tooth extraction,
- duration of edentulism,
- masticatory stress transmitted from the denture to the edentulous ridge.

Additionally, we distinguish systemic factors (10):

- age and gender of the patient,
- hypocalcemia, disturbed calcium and phosphate metabolism in the body,
- hormonal imbalance.

4. CLASSIFICATION OF BONE DEFECTS

When creating a treatment plan for edentulous patients, it is extremely important to have a thorough understanding of anatomical structures and to recognize bone and soft tissue defects resulting from prolonged edentulism. Over the past few decades, various classifications of the shape and degree of atrophy have been developed, which serve as a guide for clinicians in making decisions about the choice of therapy.

4.1. Seibert classification

In 1983, Seibert published a classification of residual ridge defects, dividing them into three classes. The first class indicates a horizontal bucco-lingual width defect with preserved arch height. The second class involves a vertical apico-coronal defect with normal arch width. The third class represents a combination of vertical and horizontal defects. Sufficient height and width of the residual ridge allow for the placement of dental implants and natural-looking prosthetic components, ensuring the maintenance of adequate oral hygiene (11,12).

4.2. Lekholm and Zarb classification

In 1985, Lekholm and Zarb published a classification of edentulous ridges primarily based on the assessment of bone volume through radiographic images. Alongside radiographs, histological analysis was also used to determine bone quality or density (7). Despite newer

classifications being introduced, the Lekholm and Zarb classification remains widely used in the evaluation of potential implant sites (13,14). This classification distinguishes five types of remaining alveolar bone quantity, denoted by letters A to E. Type A indicates a significantly preserved height of the alveolar ridge, allowing for the placement of standard implants up to 14 mm in length. Type E represents pronounced ridge resorption with complete absorption of the alveolar process. Types A and B retain sufficient residual ridge height for the placement of standard implants (7).

4.3. Allan classification

In the same year, Allan modified Seibert's classification by adding three types of residual ridge defects. Type A denotes apico-coronal loss of contour of the alveolar ridge, type B signifies buccolingual loss of contour of the alveolar ridge, while type C indicates combined loss in both dimensions (15).

4.4. Misch and Judy classification

In 1987, Misch and Judy introduced a newer classification of available alveolar bone volume for dental implant placement in the edentulous maxilla and mandible, dividing it into four categories (7). This classification describes the amount of residual ridge along with proposed therapeutic options for each category. Since the angle of bone inclination and crown height influence prosthetic treatment, they are also included in this classification. Two additional subcategories were added to ensure better therapeutic possibilities (7,16).

- Category A represents the state immediately after tooth extraction, where abundant bone volume suitable for implants is wider than 4 mm of all remaining lengths.
- Category B indicates that there is barely enough volume of alveolar bone. Buccolingual width is reduced to 2.5 - 5 mm, while ridge height remains approximately 10 mm. These dimensions are still adequate for implant placement. B-w or B minus width requires bone augmentation due to limited implant placement options. The buccolingual width of the ridge is 2.5 - 4 mm, while the mesiodistal is narrower than 6 mm.
- Category C describes bone that is deficient in all dimensions. C-w or C minus width occurs due to additional loss of width in Category B. Available width is reduced to less than 2.5 mm, which prevents the placement of standard implants, while height remains preserved. Further resorption and loss of height result in Category C-h or C minus height. Posterior regions of both jaws have a faster height loss rate in regard to height loss rate in the anterior regions. This category poses a significant challenge in prosthetic work, and implant placement is not possible without prior bone augmentation.
- Category D refers to severe atrophy of the alveolar ridge accompanied by partial atrophy of the basal bone. A peaked ridge is visible in the buccolingual width, making it unsuitable for implant placement without prior bone augmentation.

5. TECHNIQUES FOR THE PREVENTION OF RESORPTION OF THE ALVEOLAR RIDGE

Preserving the alveolar ridge is of paramount importance in edentulous patients for facilitating appropriate therapy, including dental implant placement and prosthetic replacement of lost teeth. Various oral surgical techniques are employed to reduce or at least slow down the resorption of the alveolar ridge, which inevitably occurs due to multiple tooth extractions. Preventing alveolar ridge resorption maintains the vertical and horizontal dimensions of the residual ridge (17). The techniques commonly used for alveolar ridge preservation include:

- **Socket preservation:** This technique involves filling the extraction socket with bone graft material immediately after tooth extraction to maintain the ridge dimensions and facilitate future implant placement.
- **Immediate implantation:** Involves placing a dental implant immediately after tooth extraction, which helps preserve the bone structure and prevents resorption (17).

The choice of technique depends on the therapeutic procedure planned and the patient's current condition.

5.1. Alveolar Socket Preservation

Alveolar socket preservation is a technique aimed at enhancing bone healing and promoting the formation of healthy bone callus after tooth extraction or alveotomy to facilitate adequate implantation. The most commonly used materials for alveolar preservation are xenogeneic, autologous, and alloplastic materials, as well as combinations thereof. This method differs from ridge augmentation, which aims to increase the volume of the bone ridge, either at the time of extraction, before, or during implant placement (17). The main advantages of the alveolar preservation technique include maintaining existing soft and hard tissue, stable ridge volume to optimize functional and aesthetic outcomes, and simplifying subsequent treatment procedures. This therapeutic procedure aims to preserve the vertical and horizontal shape of the alveolar ridge to reduce the loss of height and width of the alveolar bone (17).

5.2. Immediate Implantation

On contrary to the traditional approach of dental implant placement, which involves flap elevation as preparation for implant positioning, immediate implantation skips this step. Implants are placed immediately after tooth extraction without flap elevation, simplifying the procedure, reducing operative time, and patient discomfort (18). This technique is used when all alveolus walls are preserved and the extraction is atraumatic. This type of therapy can be performed when the extracted tooth did not have inflammatory, cystic, or tumor processes. Often, it is necessary to use one of the augmentative materials to enable adequate bone healing around the implant, especially in the cervical third. Assessing and ensuring the primary stability of the implant is crucial for successful immediate implantation. The waiting period for loading an immediately placed implant should be at least four months in the maxilla and three months in the mandible. From a biological perspective, the main advantage of immediate implantation is preserving the periosteum and suprapariosteal plexus, thereby maintaining blood flow to the alveolar bone (18).

6. PREPROSTHETIC SURGERY

Unfavorable conditions resulting from multiple tooth extractions must be addressed to enable appropriate rehabilitation of the edentulous jaw. Irregularities and loss of bone volume due to alveolar ridge resorption often hinder the adequate fabrication of prosthetic replacements and diminish the therapeutic possibilities of dental implant placement. Preprosthetic surgery is a field of oral and maxillofacial surgery aimed at restoring the stomatognathic system. It primarily involves surgical modification of the alveolar ridge and surrounding structures to ensure an appropriate anatomical environment for the seating of dental prostheses, which have to fulfill satisfactory functional and aesthetic roles (19).

With advancements in materials, technology, processing techniques, and a better understanding of oral cavity physiology, numerous possibilities have been offered to prepare the residual ridge for dental implant placement and the subsequent fabrication of prosthetic replacements.

6.1. Usage of biomaterials for bone augmentation

Bone augmentation procedures aim to stimulate or facilitate the growth of new bone in the surgical area to create adequate conditions for the placement of dental implants. For a long time, autologous bone grafts taken from donor sites within or outside the oral cavity were considered the gold standard. However, due to limitations in the availability of bone quantity, other suitable replacement materials have been sought. Replacement materials can be used alone or in combination with autologous grafts to increase the graft volume. Each replacement material must meet biocompatibility requirements and should promote the proliferation of new blood vessels, ultimately leading to the growth of new bone in the augmented area. An ideal augmentation material is one that provides biological support during healing and is gradually replaced by newly formed bone (20).

6.1.1. Autologous bone graft (autografts)

Autologous bone graft is considered as a gold standard for bone augmentation due to its ability to regenerate bone. It encompasses all three important mechanisms of bone healing: osteogenesis, osteoconduction, and osteoinduction (21).

The donor site is harvested and transferred from an intraoral or extraoral site to the deficient bone areas within the same individual, making this method the safest and most biocompatible (22). One of the most common donor sites used in autologous bone grafting is the iliac crest. It provides easy access, good quality, and an adequate quantity of available bone. However, the main drawback of choosing this therapeutic option is the additional surgical procedure, i.e., a second surgical site and postoperative rehabilitation time, and it is contraindicated in older patients and those with malignant diseases. Complications associated with harvesting the iliac crest for autotransplantation include hematoma formation, blood loss, infections, nerve and artery injuries, as well as fractures and subsequent pelvic instability (21).

In addition to the iliac crest, grafts taken from the tibia, fibula, or calvaria are also used. Intraoral donor sites do not require such complicated surgical approaches since both the donor and implantation sites are within the oral cavity. Autogenous graft collection is performed from the symphysis and mandibular ramus and maxillary tuberosity (22).

Intraoral autogenous grafts may contain cancellous or cortical bone, or they may be a combination of both. Cancellous grafts have the ability to vascularize earlier, starting around the fifth day after transplantation. Due to their porous architecture, they are initially soft, but thanks to biomechanical stimulation, they become more stable and similar to alveolar bone. On the other hand, cortical grafts have exceptional initial strength that decreases over time. Research indicates that after six months, they get even 40-50% more resorbed than alveolar bone (22).

6.1.2. Allogeneic bone graft

Allogeneic donor materials are collected from genetically non-identical individuals of the same species, namely from deceased donors. Unlike autogenous grafts, they are available in larger quantities and do not require a second surgical site. Although this type of graft undergoes multiple strict controls conducted in tissue banks, there is still a risk of developing immune reactions and transmitting infections through contaminated material. In clinical practice, allogeneic bone graft is used in various sizes and can consist of cancellous, cortical, or a combination of both types of bone. It is commonly used in alveolar ridge augmentation,

sinus augmentation, and ridge preservation after extractions. Depending on the manufacturing method, they are available on the market in the form of mineralized freeze-dried bone allografts (FDBA) and demineralized freeze-dried bone allografts (DFDBA) (22).

6.1.2.1. Freeze-Dried Bone Allografts (FDBA)

Mineralized freeze-dried bone allografts have shown high success rates in treating periodontal defects. This type of graft has been proven to have a high clinical transplantation success rate while minimizing health risks. The freezing and drying process is believed to directly influence the host's immune response by recognizing and distorting the three-dimensional presentation of human leukocyte antigens on the surface of allogeneic graft particles. FDBA possesses exceptionally good osteoinductive and mechanical properties compared to fresh or other frozen grafts. This type of graft can be used alone or in combination with autogenous grafts to increase osteogenic potential (22).

6.1.2.2. Demineralized Freeze-Dried Bone Allografts (DFDBA)

Demineralized freeze-dried bone allografts are commonly used in maxillofacial and periodontal practices for transplantation. DFDBA has an advantage over other materials due to its ability for rapid resorption and exposure to osteoinductive processes after demineralization. Research has shown that the bioactivity of this material depends on the age of the patient. Specifically, grafts collected from younger individuals exhibit greater osteogenic potential compared to those from older individuals. In studies assessing the success of the augmentation procedure, particles of DFDBA were observed near the preexisting bone, while particles located near the center of the graft did not show signs of remineralization or new bone formation (22).

6.1.3. Xenogeneic bone substitutes

Xenogeneic bone substitutes, which originate from non-human species, are most commonly of animal origins. Through commercial processing of bones, typically bovine, naturally mineralized bone without organic components is obtained. Through this processing, these

materials become biocompatible with the human recipient, although they always carry a theoretical risk of infection. Compared to artificially derived materials, they have inferior osteoconductive properties and show a high potential for resorption and replacement with new bone at recipient sites. Bovine bone is available in the form of particles and blocks and is successfully used for alveolar ridge augmentation. In addition to animal-derived sources, xenografts obtained from natural coral, of the genus *Porites*, from which coral calcium carbonate is derived, are also used. Particle sizes range from 100 to 200 micrometers, resembling the size of trabecular bone pores. They have a relatively high porosity, providing a large surface area for graft resorption and replacement with new bone. They are frequently used in periodontology due to their high success rate in treating periodontal defects (22).

6.1.4. Alloplastic bone substitutes

Alloplastic bone substitutes used in bone augmentation are synthetically produced materials. Their primary advantage is high availability compared to natural materials, with no risk of infection for the recipient and a very low rate of allergic reactions. Depending on the indication, they come in resorbable or non-resorbable forms, with varying pore sizes and levels of porosity. They typically possess osteoconductive properties without osteoinductive potential. The most commonly used alloplastic materials include tricalcium phosphates (TCP), bioactive glasses, hydroxyapatite (HA), and dicalcium phosphates (22).

6.1.5. PRP/PRF

Platelet-rich plasma (PRP) and platelet-rich fibrin (PRF) are biological materials widely used in oral surgery. They are produced by centrifuging the plasma fraction of the patient's blood, which results in a higher concentration of platelets compared to the original blood. The main advantage of these materials lies in the presence of cytokines and growth factors in platelet based preparations that support the healing process (23). PRF is commonly used after third molar extractions, in implant surgery, and in the treatment of alveolar osteitis and trismus, while PRP has broader applications in sinus floor elevation procedures, post-tooth extractions, and in patients being treated for bisphosphonate-induced osteonecrosis (23).

6.1.6 Biological membranes

The use of membranes in preprosthetic surgery is part of the guided bone regeneration (GBR) concept, one of the common bone augmentation techniques (24). The two main functions of membranes in the GBR process are mechanical - maintenance of space for bone regeneration, and physical - serving as a cellular barrier. By using biological membranes, the proliferation of osteoblasts is encouraged, and the bone site that needs regeneration is physically closed off(). Through their action, membranes create and maintain an isolated space that provides an environment conducive to the recruitment and proliferation of osteoprogenitor cells. A prerequisite for using any membrane is that it meets the criteria of biocompatibility, integrates with host tissues, has simple clinical manageability, and has the ability to close the space (25).

On the market, membranes are available as resorbable and non-resorbable membranes. The most commonly used non-resorbable material is polytetrafluoroethylene (e-PTFE). It is a chemically stable and biologically inert polymer with a porous structure (25). Their main drawback is the need for a subsequent surgical procedure to remove the material, which is why they have been largely replaced by resorbable membranes. Resorbable membranes are made from type I and III collagen and can be of porcine or bovine origin. This material has shown inferiority compared to others due to its active role in clot formation and chemotactic capability (26).

6.2. Vestibuloplasty

Resorption of the alveolar bone inevitably accompanies the reduction of the attached gingiva of the alveolar ridge. In order to address this issue and aim to increase the foundation for the fabrication of an appropriate prosthesis, vestibuloplasty is performed to deepen the vestibular sulcus (27). The therapeutic indication for the surgical procedure of vestibuloplasty involves uniform atrophy of the alveolar ridge when the muscle insertion is near the crest of the

alveolar ridge, affecting the stabilization and retention of the prosthesis (28). Operative methods can be divided into (9):

- tissue defect methods,
- open methods, and
- closed methods.

6.2.1. Tissue defect methods

The essence of tissue defect methods is to leave the submucosa without mucosa, periosteum without submucosa and mucosa, or to expose bare bone in the surgical area (9). Many authors such as Cooley, Clark, Howe, Kostečka, Vrasse, Miše and Netter present their views and clinical experiences of this method, which varies somewhat among each of them. What these authors have in common is the initial approach to the surgical procedure, namely, the incision that is horizontal with respect to the crest of the alveolar ridge. However, their methods differ in the location of the flap, which can be on the crest of the alveolar ridge, on the vestibular mucosa near the crest of the alveolar ridge, or far from it. In the mandible, the incision can also be made on the buccal or labial mucosa, just above the vestibular fornix of the lower jaw (9).

6.2.1.1. Cooley Method

The Cooley surgical procedure begins with an incision along the crest of the alveolar ridge, involving all layers of the mucosa (mucosa, submucosa, and periosteum). The preparation of the buccal and labial mucosa starts from the submucosa, while the lingual mucosa remains untouched. The edge of the vestibular mucosa is sutured to the edge of the vestibular periosteal-submucosal flap. The edge of the vestibular flap is sutured to the lingual flap of the alveolar ridge through the perforated alveolar ridge (9). Postoperatively, the bare bone of the crest and part of the vestibular and lingual surfaces of the ridge remain exposed. A gutter-like shaped device is used to cover the exposed bone, which is placed on the alveolar ridge and fixed periosteally to the skin of the vestibular and lingual flaps (9).

6.2.1.2. Clark's method

Clark's initial incision begins along the transition from attached to non attached mucosa, limited in depth just to the mucosal layer. The buccal and labial mucosa is dissected from the underlying tissue and fixed to the skin beneath the mandible using mattress sutures. The gingiva remains untouched. Caudally from the gingival margin, the submucosa is left exposed, and it heals by secondary intention (9).

6.2.1.3. Kostečka's method

Kostečka makes an incision in the buccal or labial mucosa slightly above the vestibular fornix of the mandible, following its curvature. The depth of the incision goes only through the mucosa. From the edge of the incision, the mucosa is dissected from its underlying tissue towards the alveolar ridge up to the gingival margin (9). The buccal and labial mucosa are not dissected. The submucosa is incised near the gingival margin and pushed towards the fornix. The free mucosal flap on the alveolar ridge is sutured caudally to the pushed submucosa and muscles. In the buccal and labial areas, a defect without mucosa remains. These defects can be covered using paste or gauze (9).

6.2.2. Open methods

The initiator of the open vestibuloplasty method is considered to be Kazanjian, who presented his operative techniques in 1924 and 1935. This method is also known as ridge extension. Kazanjian emphasizes the importance of the starting incision, which should be distant from the alveolar bone to preserve enough mucosa for its covering. The incision should also avoid involvement of the periosteum (9).

6.2.2.1. Open methods in the upper jaw

An incision is made on the buccal and lingual mucosa, and the mucosa is dissected from the underlying tissue to the gingival margin. Below the gingival margin, the submucosa is incised to the periosteum and pushed towards the fornix. The dissected mucosal flap is then approximated to the bone and sutured to the periosteum. The entire mucosal flap is then fixed

to the mucosa of the maxillary body using mattress sutures or attached to the facial skin using a rubber tube (9).

6.2.2.2. Open methods in the lower jaw

If the vestibule of the lower jaw is well-defined and there is sufficient movable mucosa on the alveolar ridge, the procedure for open vestibuloplasty in the lower jaw is the same as in the upper jaw. However, since the vestibule is often poorly defined and shallow, with a narrow band of attached gingiva on the alveolar ridge, the incision is made on the buccal and lingual mucosa. The submucosa is incised and pushed towards the vestibule along with the muscles and periosteum. By dissecting the submucosal and periosteal flap, the mental foramen is exposed. At this point, the clinician must assess whether the mental nerve will be compressed by the fixation and subsequently subjected to stimuli as a result of deepening the vestibule. If the mental foramen is positioned too high, it needs to be relocated lower. The mucosal flaps are fixed with a plastic tube that is sutured to the edge of the vestibular flap using mattress sutures that are not tied. The ends of the suture threads are secured with a clamp. A tampon of iodoform gauze is placed in the groove of the vestibule, between the two incisions. The purpose of this procedure is to cover any exposed bone areas and prevent premature healing, which would reduce the band of immovable mucosa on the alveolar ridge and result in a shallower vestibule (9).

6.2.3. Closed Methods of Vestibuloplasty

In 1935, Obwegeser described the closed vestibuloplasty method, which avoids postoperative tissue defects and is primarily conducted below the level of the mucosa (28).

6.2.3.1. Closed Methods in the Upper Jaw

In the midline, along the frenulum of the upper lip, a vertical incision is made that reaches the periosteum in the area of the alveolar bone and includes the lip mucosa above the alveolar bone. Curved scissors are used to enter beneath the mucosa, separating it from the submucosa. The muscles and submucosa are removed and pushed towards the vestibule. The mucosa's adherence to the alveolar ridge is secured with a plate fixed to the alveolar ridge in the premolar region on both sides. A wire is threaded through the plate and the ridge following the principle of mattress suture technique; it is introduced from the vestibular side, exits through the palatal side, and returns in the same manner to the vestibular side (9).

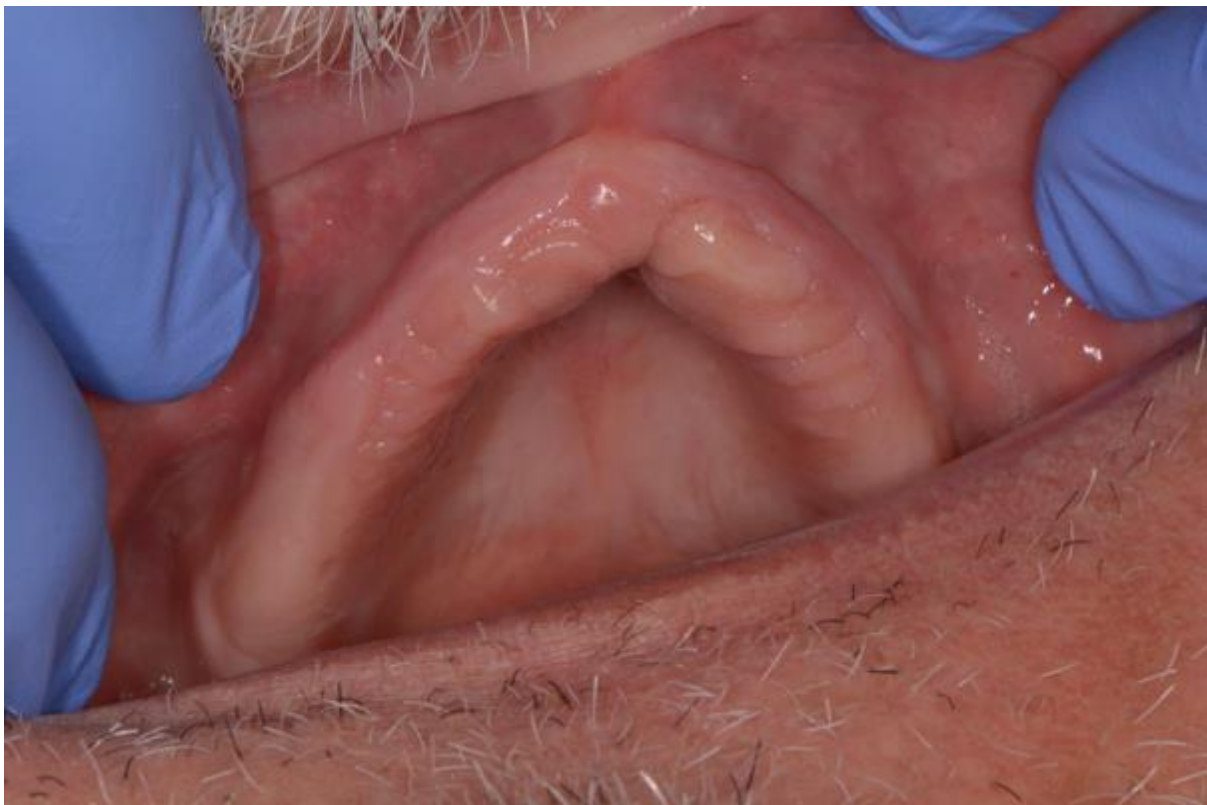6.2.3.2. Closed Methods in the Lower Jaw

In the lower jaw, three vertical incisions, each about one centimeter long, are made. The incisions are placed on the crest of the alveolar ridge, one in the midline and two on either side in the canine region. The depth of the incision reaches only the mucosa, which is then separated from the submucosa with scissors, as needed for the width of the future band of immobile mucosa. The submucosa and periosteum are pushed towards the vestibule. The prepared mucosa of the alveolar ridge is sutured with mattress stitches and fixed to the skin at the lower edge of the mandible, ensuring the extension of the mucosa on the alveolar ridge. A plastic tube is used to maintain the depth of the vestibule and is sutured to the skin of the lower edge of the mandible using mattress stitches (9).

6.2.4. Upper jaw vestibuloplasty with secondary epithelization using PRF

In the following pictures, the surgical procedure of vestibuloplasty with secondary epithelization will be described. A 70-year-old male patient with an atrophic upper jaw has

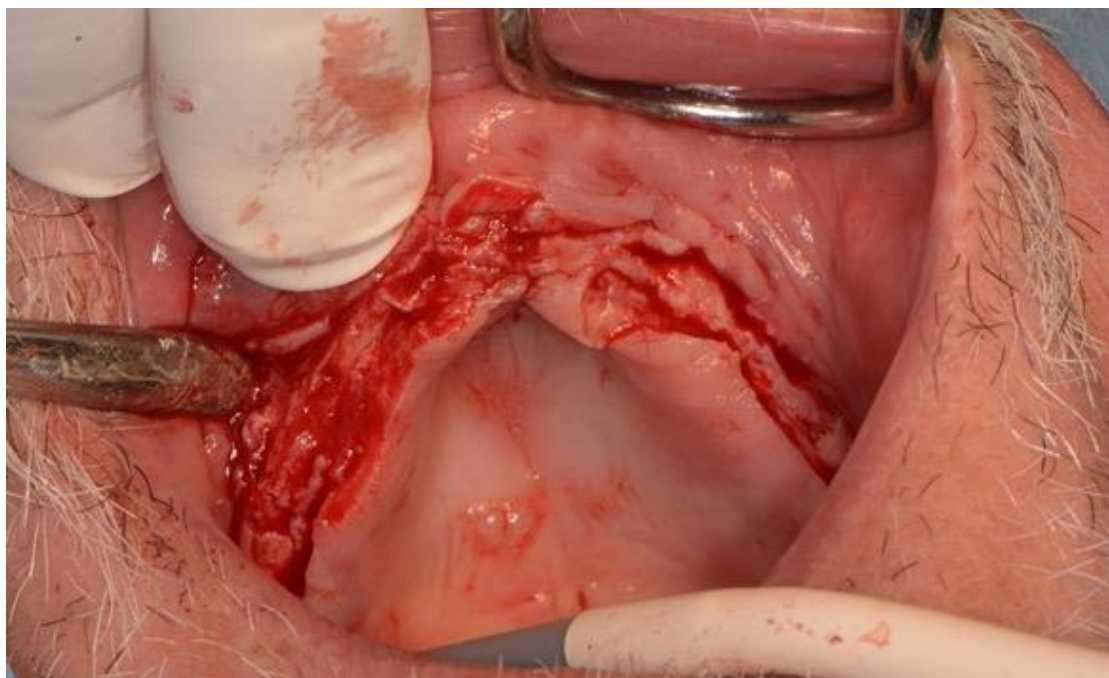
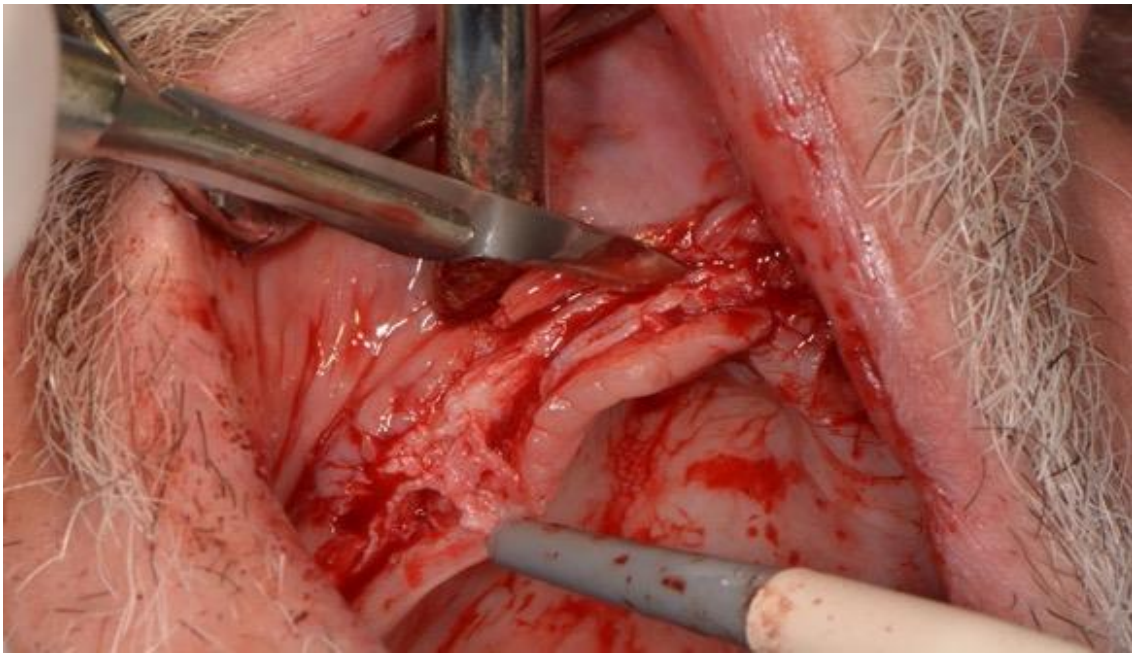
been treated at the Department of Oral Surgery. Before the surgical procedure, a thorough medical history was taken, and it was concluded that the patient is healthy and has no contraindications for this operation. The initial condition in this patient indicates uniform atrophy of the alveolar bone of the maxilla with hypertrophy of the soft tissue.



Picture 1. Uniform atrophy of the maxilla with hypertrophy of the soft tissue.

Taken with permission of the author: dr.sc. Tomislav Katanec

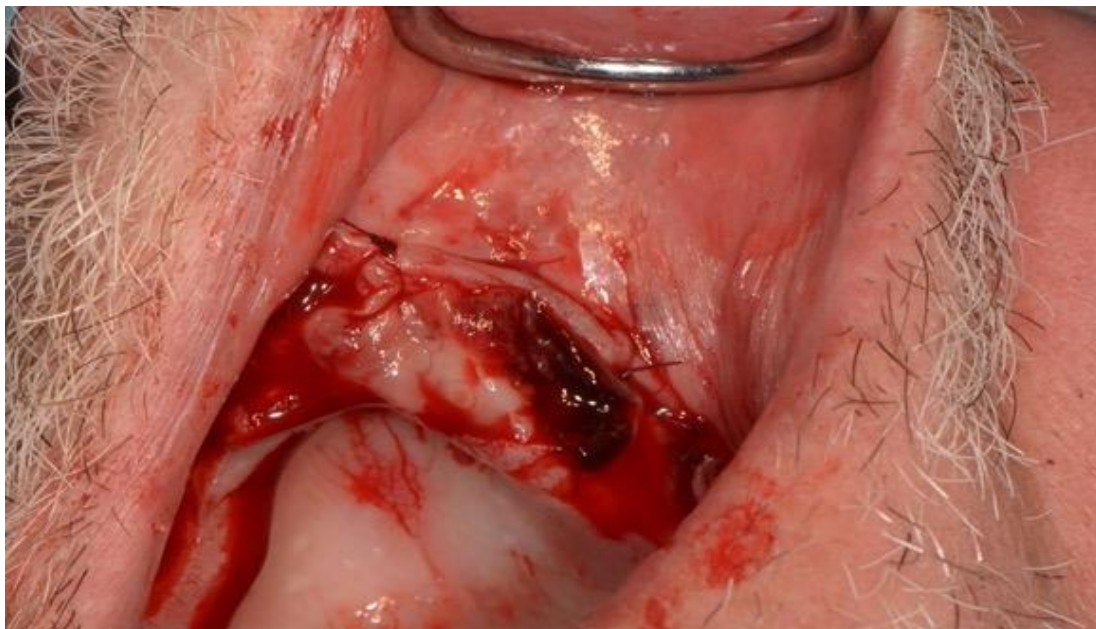
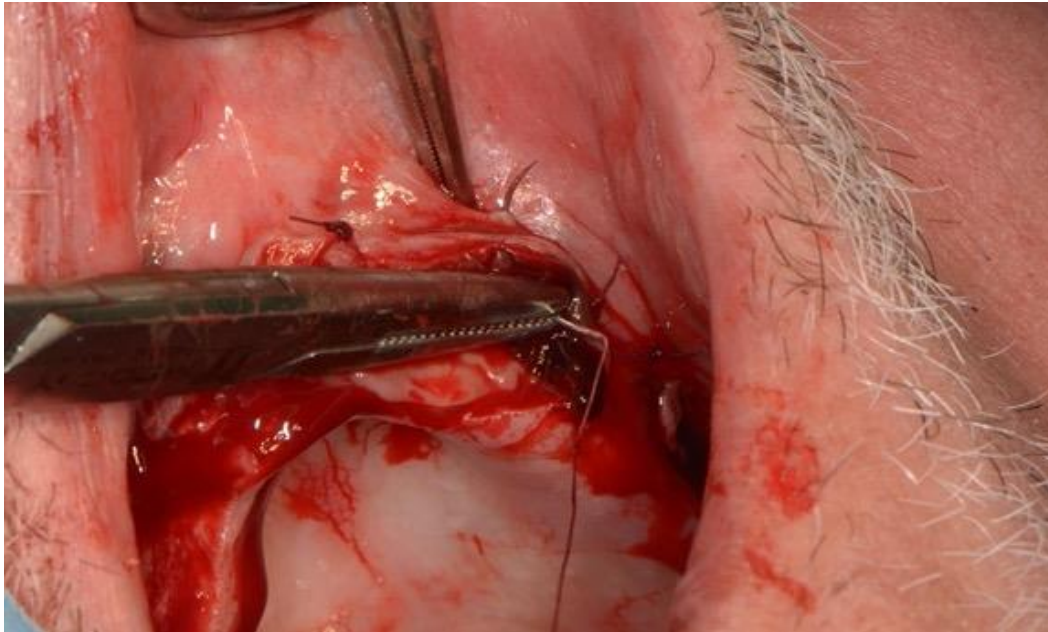
The patient was anesthetized and a wedge excision of the remaining alveolar ridge was performed.



Pictures 2 and 3. Wedge excision of the remaining alveolar ridge.

Taken with permission of the author: dr.sc. Tomislav Katanec

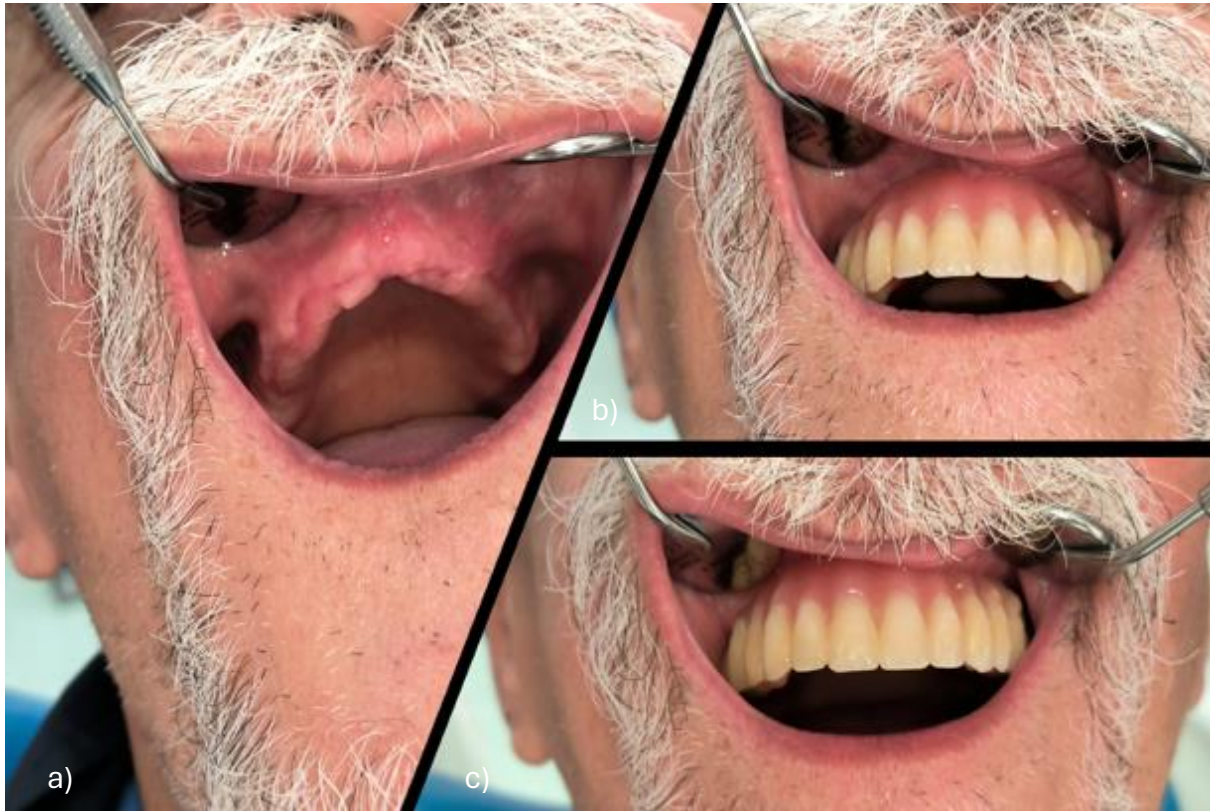
PRF clots were then fixed to the periosteum and the movable mucosa of the vestibule using resorbable sutures made of polyglycolic acid with a diameter of 6-0.



Pictures 4 and 5. Fixation of PRF clots.

Taken with permission of the author: dr.sc. Tomislav Katanec

After the successful completion of the surgical procedure and secondary epithelialization, a complete denture was made for the patient.



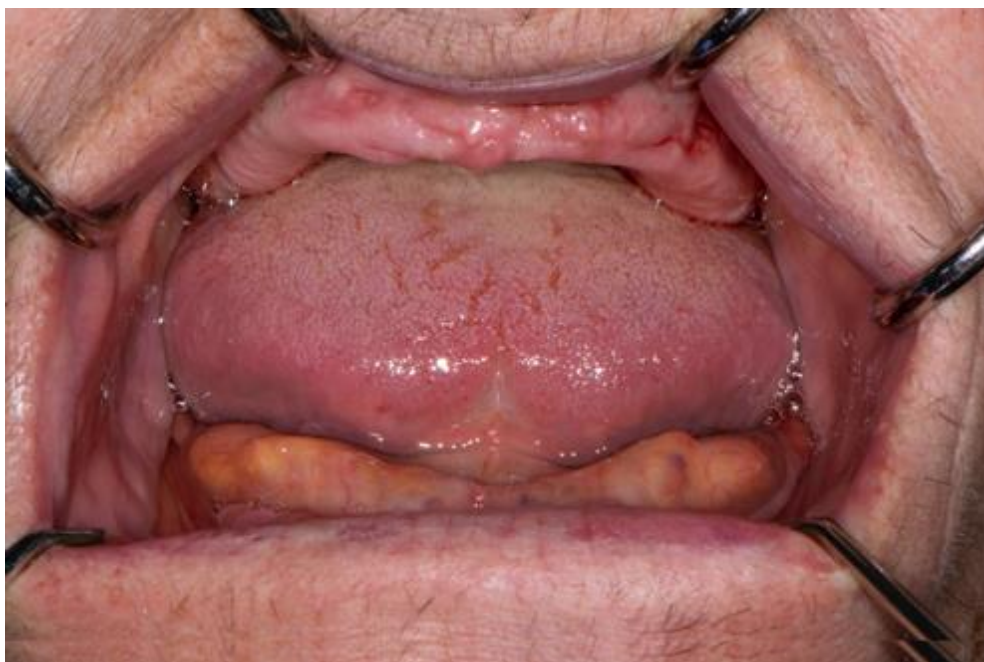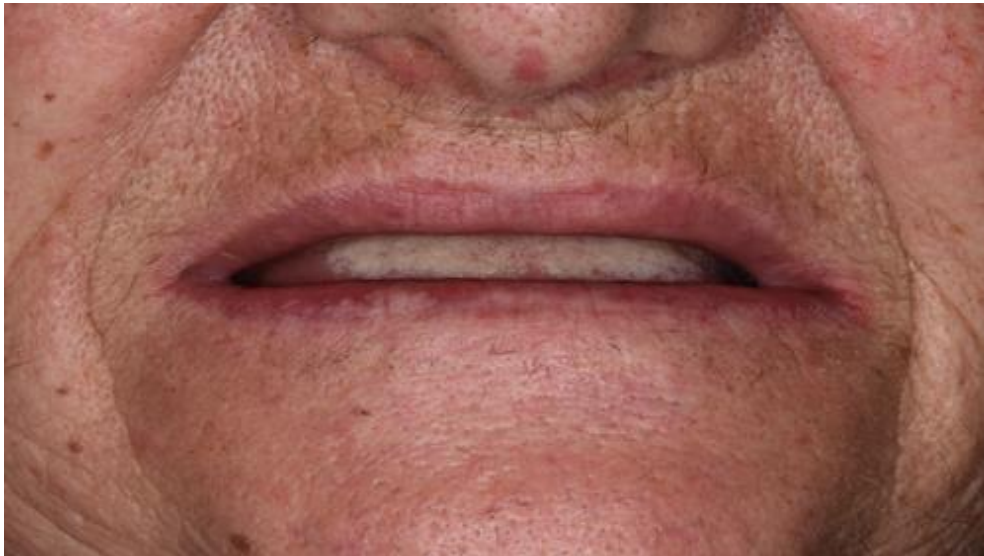Picture 6. a) Clinical presentation after surgical procedure. Successful secondary epithelialization. b) and c) new complete denture was made.

Taken with permission of the author: dr.sc. Tomislav Katanec

6.2.5. Lower jaw vestibuloplasty and short implant placement

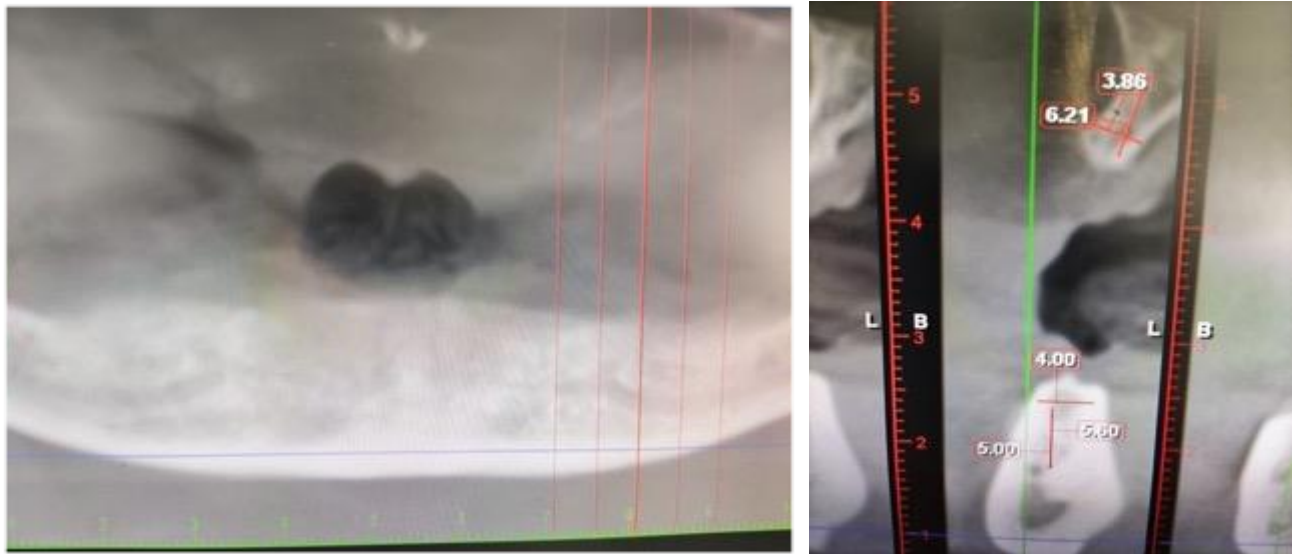The following images will depict the clinical case of a 66-year-old female patient who was treated at the Department of Oral Surgery. In this case, extra-short implants were used in addition to mandibular vestibuloplasty for the rehabilitation of the edentulous jaw.

The patient presents to the clinic with complaints of irritation of the oral mucosa caused by an ill-fitting prosthesis. Clinical examination reveals hypertrophy of the soft tissues.



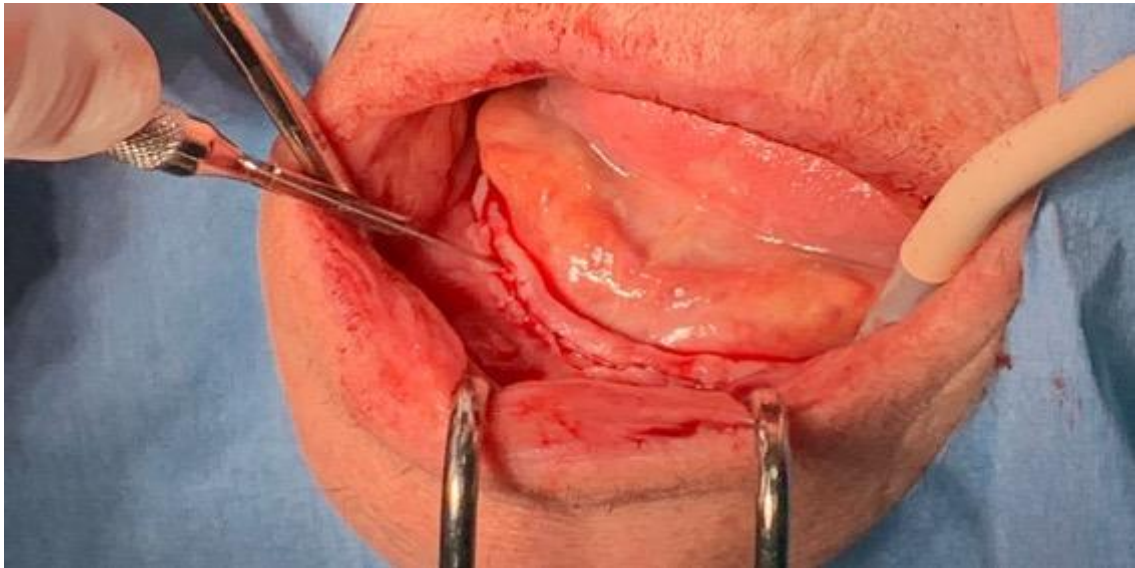Pictures 7 and 8. Clinical presentation of patient's initial state.
Taken with permission of the author: dr.sc. Tomislav Katanec

After the clinical examination, the patient was referred to perform CBCT scan. Using the scans, the height and width of the residual ridge were measured to determine suitability for implant placement.

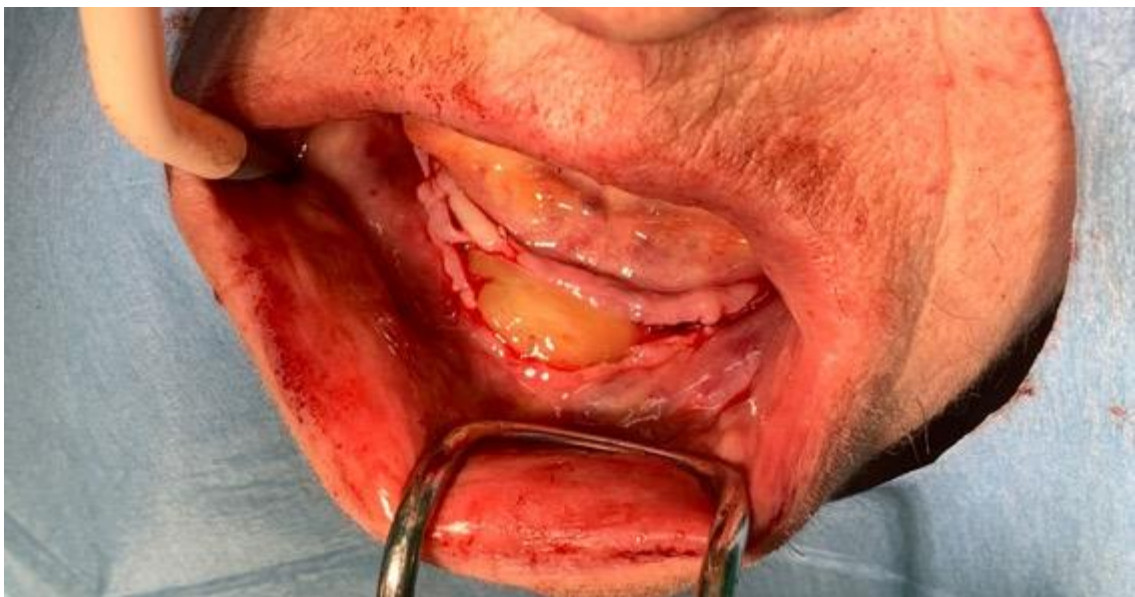

Pictures 9 and 10. CBCT scans of region 36. Taken with permission of the author:
dr.sc. Tomislav Katanec

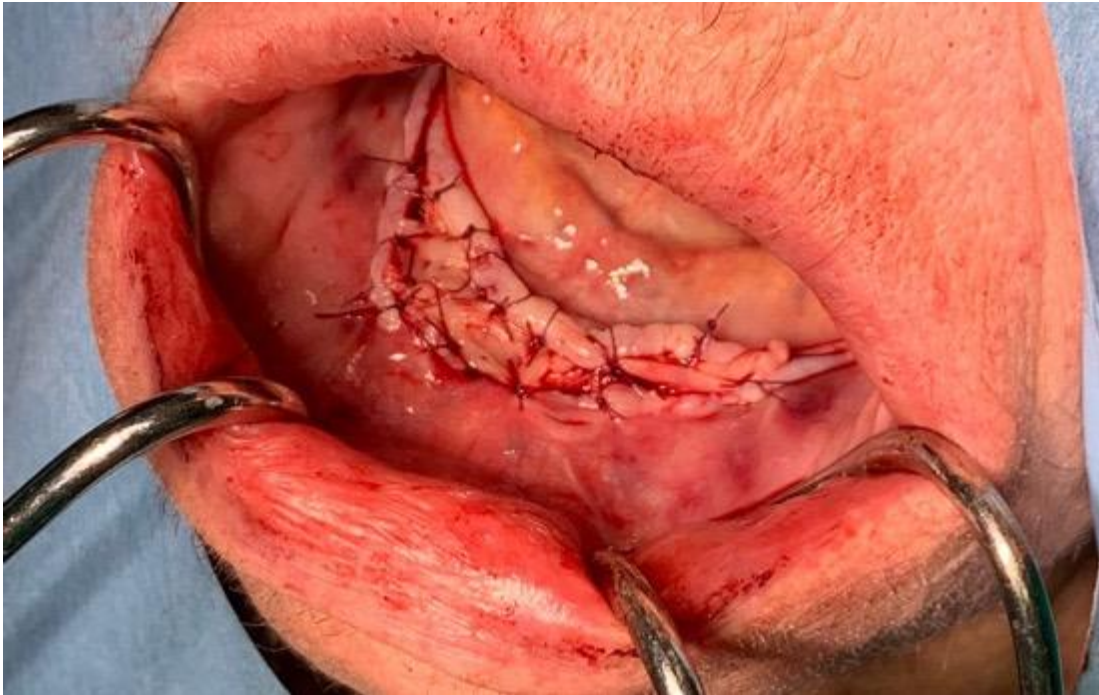After the patient was anesthetized, the first incision was made and a full-thickness flap was elevated while preserving the periosteum. Following the lifting of the flap, denivelation of the sharp ridges of RRR was performed in addition to PRF clot placement. PRF clots were fixed using resorbable sutures made of polyglycolic acid with a diameter of 6-0.



Picture 11. Incision of RRR and flap elevation.
Taken with permission of the author: dr.sc. Tomislav Katanec

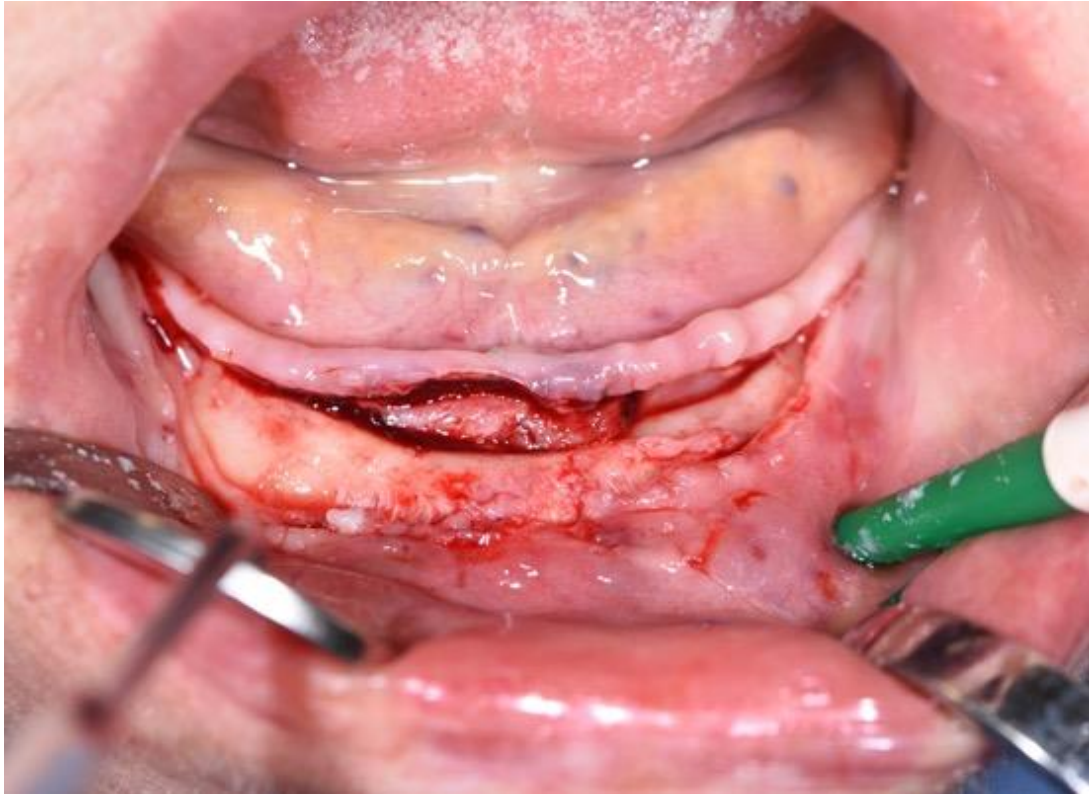

Picture 12. PRF clot placement.
Taken with permission of the author: dr.sc. Tomislav Katanec

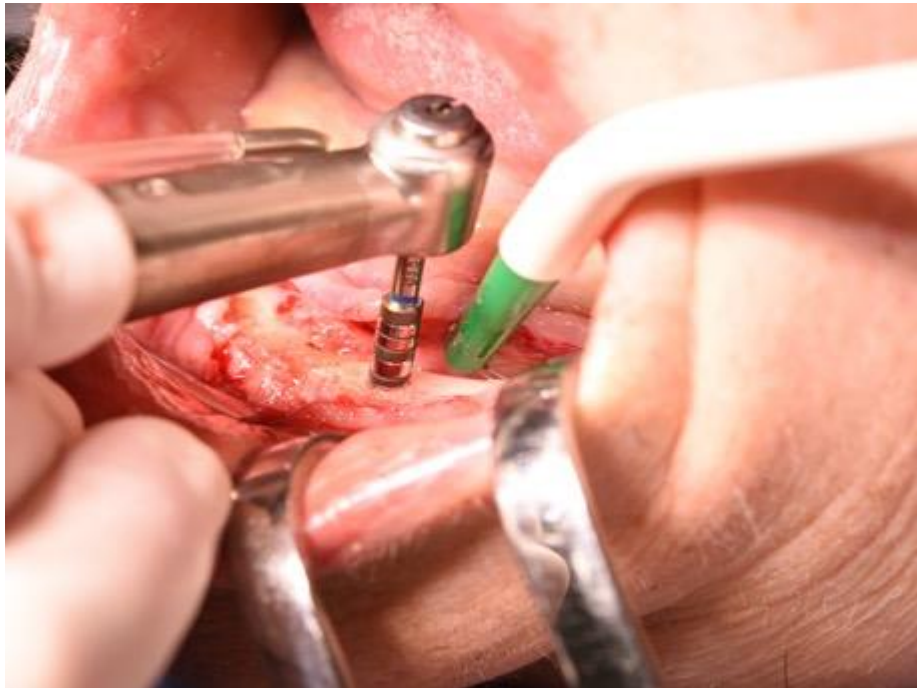


Picture 13. Fixation of PRF clots.
Taken with permission of the author: dr.sc. Tomislav Katanec

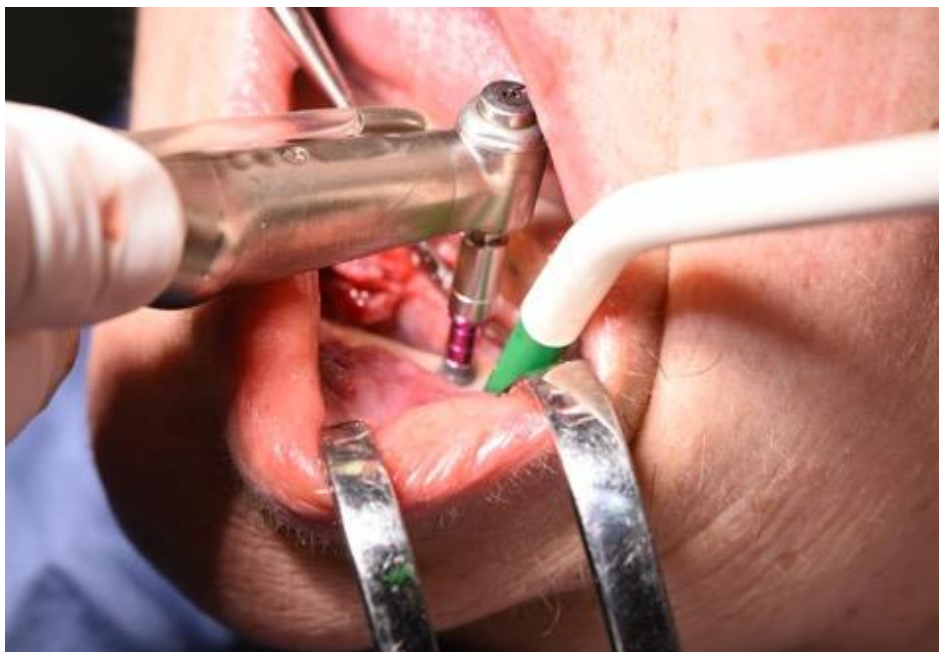The patient returned for a follow-up visit one month after the surgical procedure. Clinical examination revealed satisfactory secondary epithelialization, and the placement of extra-short implants (4,0 x 4,5 mm in diameter) was carried out.



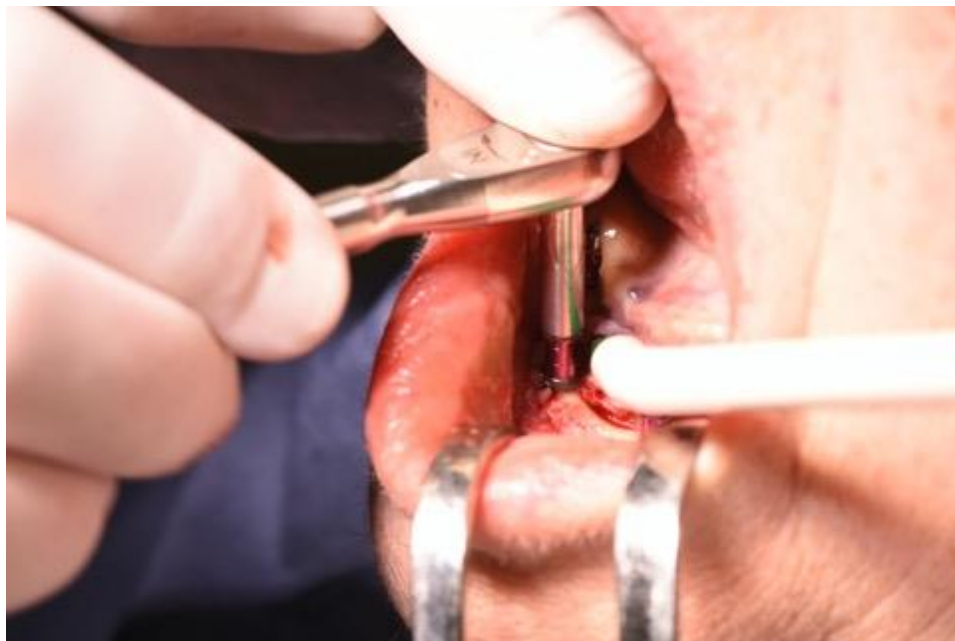Picture 14. elevation of a full-thickness flap.
Taken with permission of the author: dr.sc. Tomislav Katanec



Picture 15. final drill for implant site preparation.
Taken with permission of the author: dr.sc. Tomislav Katanec

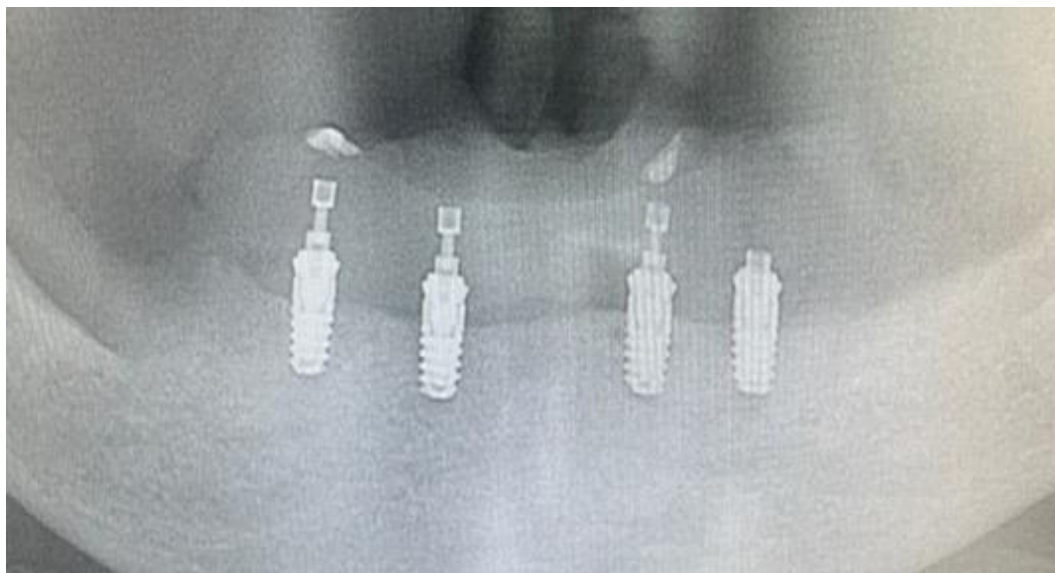


Picture 16. machine-driven implant placement.
Taken with permission of the author: dr.sc. Tomislav Katanec



Picture 17. manual tightening of the implants.

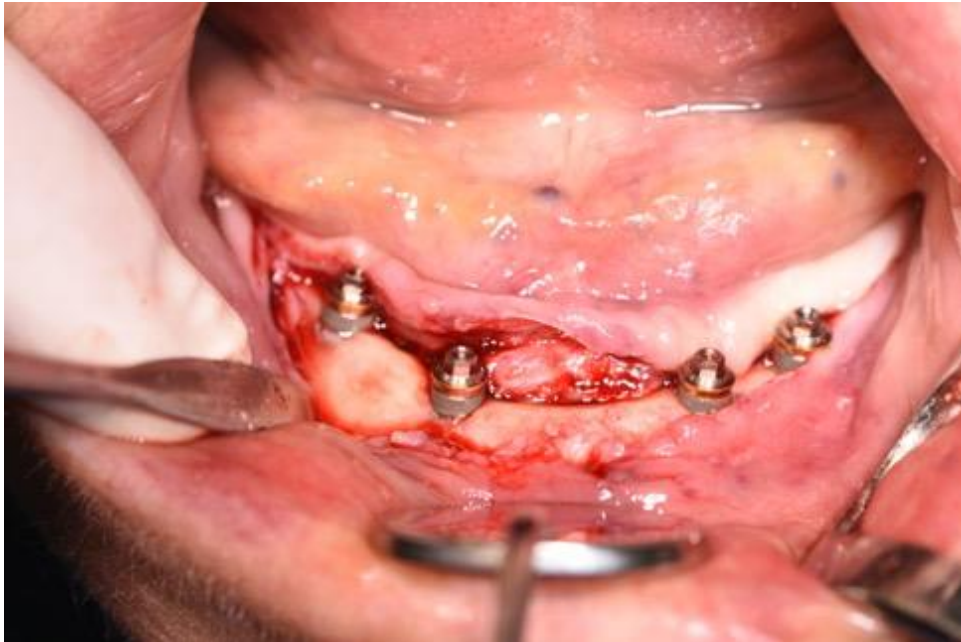Taken with permission of the author: dr.sc. Tomislav Katanec



Picture 18. Control orthopantomogram.

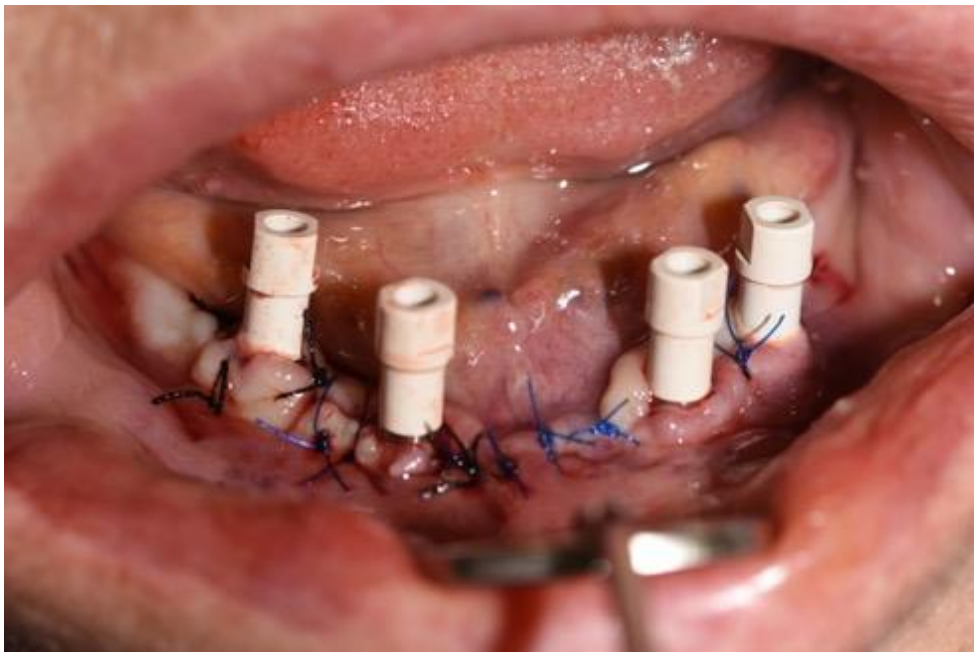
Taken with permission of the author: dr.sc. Tomislav Katanec

After implant placement, multi-unit abutments were installed and immediate scanning was performed using a scan body.



Picture 19. Multi – unit abutments.

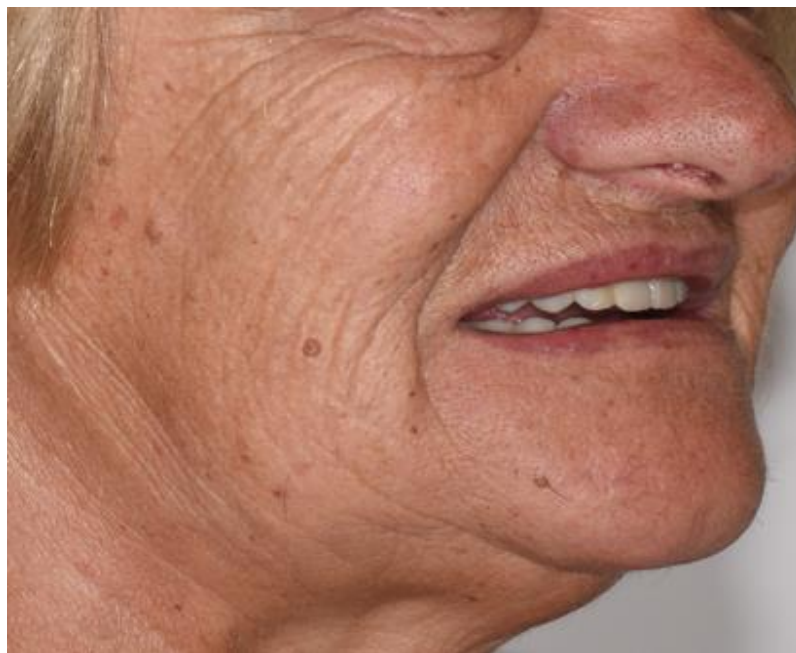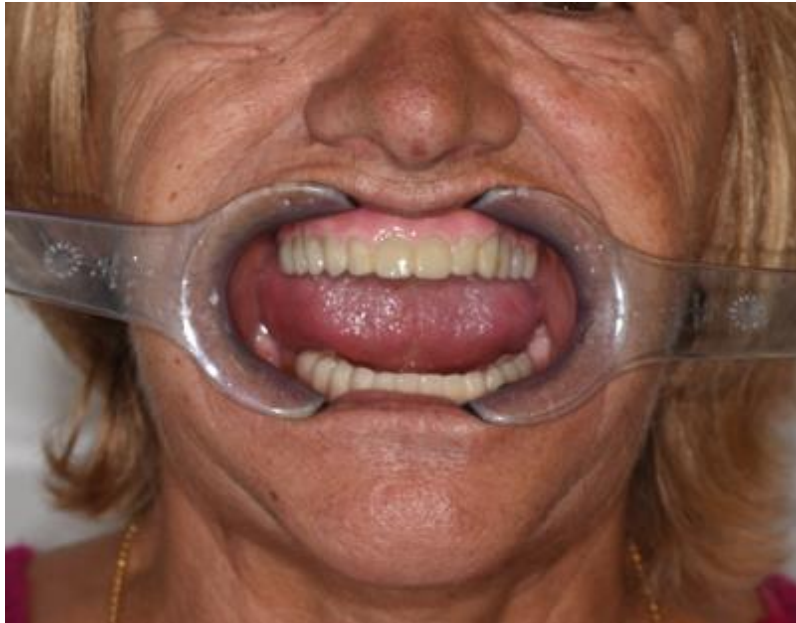Taken with permission of the author: dr.sc. Tomislav Katanec



Picture 20. Intraoral scan bodies.

Taken with permission of the author: dr.sc. Tomislav Katanec

As the final step in the treatment, complete removable dentures were fabricated for both the upper and lower jaw.



Pictures 21 and 22. End stage of implant - prosthetic rehabilitation.

Taken with permission of the author: dr.sc. Tomislav Katanec

In cases where it is no longer possible to maintain a tooth in satisfactory conditions concerning its health, function, and aesthetics, extraction is indicated (29). Every extraction triggers a cascade of events resulting in reduced height and width of the alveolar ridge, i.e., its resorption and atrophy, which is most pronounced in the first three months up to one year post-extraction. These changes cause aesthetic and functional disturbances, complicating the creation of an adequate prosthetic replacement (30).

Due to the consequences of alveolar ridge resorption after tooth extraction, a socket-filling procedure is often indicated to rehabilitate function, aesthetics, and comfort. The oral surgical technique of alveolar ridge preservation in post-extraction sockets aims to prevent resorption of the alveolar bone (31). For this purpose, the use of various graft materials is recommended, including bone substitutes such as allografts, xenografts, alloplastic materials, and autogenous bones, which must primarily meet the conditions of biocompatibility and then the properties of osteoinduction, osteoconduction, and osteointegration (22).

Various scientific studies have attempted to determine the final outcome of treatment in cases where therapeutic methods of socket preservation were used during the post-extraction period, compared to cases where no therapeutic modality was applied. The results of the analysis show the benefit of socket preservation procedures, as they can at least partially limit bone loss both horizontally and vertically. By using graft materials and biological materials, whether in combination or separately, the normal sequence of biological events leading to resorption during wound healing is disrupted (29).

Research has also shown that the use of autogenous bone does not bring significant advantages, so most clinicians who perform alveolar ridge preservation techniques opt for the use of non-autogenous materials due to their practicality, primarily to avoid a second surgical site. The simplest approach attempting to preserve the ridge is through the use of semi-permeable membranes, either resorbable or non-resorbable. However, there are not enough studies comparing all membranes to conclude which one shows the best results (32).

Although the rate of edentulous patients does not significantly decrease across generations, advances in modern oral surgical methods allow for better and more efficient treatment of these patients. The selection of a therapeutic solution is tailored to each individual patient, making the collaboration between the oral surgeon and the prosthodontist of utmost importance in the development of the treatment plan and the creation of the final prosthesis. Modern bone augmentation techniques, combined with minimally invasive use of implants and fibrin enriched with growth factors, make both removable prosthetic and implant-prosthetic therapy for both jaws significantly more predictable and the final work of higher quality.

On the other hand, a modified vestibuloplasty technique greatly contributes to soft tissue healing and the adequate development of attached mucosa, which is crucial for the proper fit of dental prostheses. This ensures that patients experience functionality and comfort during mastication and phonation.

1. Spielman A. Illustrated Encyclopedia of the History of Dentistry. 2nd ed. New York: University College of Dentistry; 2023. 480 p.
2. Cooper LF. The Current and Future Treatment of Edentulism. *J Prosthodont*. 2009;18(2):116–22.
3. Upendran A, Gupta N, Salisbury HG. Dental Mini-Implants Resource page (internet). Treasure Island (FL): StatPearls Publishing. 2023(cited May 11, 2024). Available at: <https://pubmed.ncbi.nlm.nih.gov/30020638/>
4. Buvinic S, Balanta-Melo J, Kupczik K, Vásquez W, Beato C, Toro-Ibacache V. Muscle-Bone Crosstalk in the Masticatory System: From Biomechanical to Molecular Interactions. *Front Endocrinol (Lausanne)*. 2021;11(1):121-8.
5. Čelebić A. Miniimplantati u kliničkoj praksi. 1st ed. Zagreb: Naklada slap; 2022. 264 p.
6. Herbert F. Wolf, Rateitschak KH, Edith M. Parodontologija, stomatološki atlas. 3rd ed. Zagreb: Naklada slap; 2009. 532 p.
7. Hadjidakis D, Androulakis I. Bone Remodeling. *Ann N Y Acad Sci*. 2006; 1092(1):385–96.
8. Mercier P, Lafontant R. Residual alveolar ridge atrophy: classification and influence of facial morphology. *J Prosthet Dent*. 1979;41(1):90-100.
9. Miše I. Oralna kirurgija. 3rd ed. Zagreb: Medicinska naklada; 1991. 443 p. Knezović
10. Zlatarić D, Čelebić A, Lazić B. Resorptivne promjene koštanih struktura gornje i donje čeljusti u pacijenata nositelja mobilno-protetskih nadomjestaka. *Acta Stomatol Croat*. 2002;36(2):253–59.
11. Ramachandra S, Lahori M, Jithendra K, Singhal R, Rana R. Combined soft and hard tissue augmentation for a localized alveolar ridge defect. *Contemp Clin Dent*. 2013;4(4):556-8.
12. Zakrzewski W, Dobrzynski M, Rybak Z, Szymonowicz M, Wiglusz RJ. Select- ed Nanomaterials' Application Enhanced with the Use of Stem Cells in Accel- eration of Alveolar Bone Regeneration during Augmentation Process(image on thinternet). *Nanomaterials (Basel)*. 2020;10(6):1216. Available at: 10.3390/nano10061216

13. Al-Ekrish A, Widmann G, Alfadda S. Revised, Computed Tomography–Based Lekholm and Zarb Jawbone Quality Classification. *Int J Prosthodont*. 2018; 31(4):342-45.
14. Alghamdi H. Methods to Improve Osseointegration of Dental Implants in Low Quality (Type-IV) Bone(image on the internet). *J Funct Biomater*. 2018; 9(1):7. Available from: 10.3390/jfb9010007
15. Allen E, Gainza CS, Farthing GG, Newbold DA. Improved Technique for Localized Ridge Augmentation: A Report of 21 Cases.*J Periodontol*.1985; 56(4):195-9.
16. Shebi S, Venugopalan S, Thiyaneswaran N. An Analysis of Mean Bone Availability on the Choice of Implant Width and Length. *J Long Term Eff Med Implants*. 2021;31(1):15-20.
17. Kalsi AS, Kalsi JS, Bassi S. Alveolar ridge preservation: why, when and how. *Br Dent J*. 2019;227(4):264–74.
18. Kan JYK, Rungcharassaeng K, Deflorian M, Weinstein T, Wang HL, Testori T. Immediate implant placement and provisionalization of maxillary anterior single implants. *Periodontol 2000*. 2018;77(1):197-212.
19. Devaki VN, Balu K, Ramesh SB, Arvind RJ, Venkatesan. Pre-prosthetic surgery: Mandible. *J Pharm Bioallied Sci*. 2012;4(6):414.
20. Jensen SS, Brogini N, Hjørtning-Hansen E, Schenk R, Buser D. Bone healing and graft resorption of autograft, anorganic bovine bone and beta-tricalcium phosphate. A histologic and histomorphometric study in the mandibles of minipigs. *Clin Oral Implants Res*. 2006;17(3):237-43.
21. de Azambuja Carvalho PH, Dos Santos Trento G, Moura LB, Cunha G, Gabrielli MAC, Pereira-Filho VA. Horizontal ridge augmentation using xenogenous bone graft-systematic review. *Oral Maxillofac Surg*. 2019;23(3):271- 79.
22. Sheikh Z, Sima C, Glogauer M. Bone Replacement Materials and Techniques Used for Achieving Vertical Alveolar Bone Augmentation. *Materials (Basel)*. 2015;8(6):2953–93.
23. Egierska D, Perszke M, Mazur M, Duś-Ilnicka I. Platelet-rich plasma and platelet-rich fibrin in oral surgery: A narrative review. *Dent Med Probl*. 2023;60(1):177-86.

24. Meyer C, Camponovo T, Euvrard E, Chatelain B. Les membranes en chirurgie pré-implantaire [Membranes in pre-implantation surgery]. *Rev Stomatol Chir Maxillofac.* 2012;113(4):212-30.
25. Retzepi M, Donos N. Guided Bone Regeneration: biological principle and therapeutic applications. *Clin Oral Implants Res.* 2010;21(6):567-76.
26. Rothamel D, Schwarz F, Sager M, Hertzen M, Sculean A, Becker J. Biodegradation of differently cross-linked collagen membranes: an experimental study in the rat. *Clin Oral Implants Res.* 2005;16(3):369-78.
27. Kumar JV, Chakravarthi PS, Sridhar M, Devi KN, Kattimani VS, Lingamaneni KP. Anterior Ridge Extension Using Modified Kazanjian Technique in Mandible - A Clinical Study. *J Clin Diagn Res.* 2016;10(2):21-4.
28. Vukojević K, Lukačević F, Salarić I, Pelivan I. Pretprotetska kirurgija. Sonda [Internet]. 2017;33(1):46-49.
29. Avila-Ortiz G, Elangovan S, Kramer KW, Blanchette D, Dawson DV. Effect of alveolar ridge preservation after tooth extraction: a systematic review and meta-analysis. *J Dent Res.* 2014;93(10):950-8.
30. Ten Heggeler JM, Slot DE, Van der Weijden GA. Effect of socket preservation therapies following tooth extraction in non-molar regions in humans: a systematic review. *Clin Oral Implants Res.* 2011;22(8):779-88.
31. Bassir SH, Alhareky M, Wangsrimongkol B, Jia Y, Karimbux N. Systematic Review and Meta-Analysis of Hard Tissue Outcomes of Alveolar Ridge Preservation. *Int J Oral Maxillofac Implants.* 2018;33(5):979-94.
32. Brennan PA, Schliephake H, Ghali GE, Cascarini L. *Maxillofacial surgery.* 3rd ed. London: Churchill Livingstone; 2016. 1698 p.

Lorena Bokavšek was born on June 26th, 1997 in Split, where she completed her elementary and secondary education, attending the Third Mathematical Gymnasium. She enrolled at the School of Dental Medicine in Zagreb in 2017. During her studies, she assisted in several private dental clinics. From 2018 to 2023, she was an active member of the organizational committee for the EDSA Summer Camp in Dubrovnik. She participated in numerous conferences and in 2024 served as an active member of the 7th Symposium of Dental Medicine Students by conducting a workshop on Adhesive cementation.