

Stafne's defects in two mandibles from archaeological sites in Croatia

Vodanović, Marin; Šlaus, Mario; Galić, Ivan; Marotti, Miljenko; Brkić, Hrvoje

Source / Izvornik: **International Journal of Osteoarchaeology, 2011, 21, 119 - 126**

Journal article, Published version

Rad u časopisu, Objavljena verzija rada (izdavačev PDF)

<https://doi.org/10.1002/oa.1101>

Permanent link / Trajna poveznica: <https://urn.nsk.hr/urn:nbn:hr:127:739493>

Rights / Prava: [In copyright](#) / [Zaštićeno autorskim pravom.](#)

Download date / Datum preuzimanja: **2024-08-06**



Repository / Repozitorij:

[University of Zagreb School of Dental Medicine
Repository](#)



SHORT REPORT

Stafne's Defects in Two Mandibles from Archaeological Sites in Croatia

M. VODANOVIĆ,^{a*} M. ŠLAUS,^b I. GALIĆ,^c M. MAROTTI^d AND H. BRKIĆ^a

^a Department of Dental Anthropology, School of Dental Medicine, University of Zagreb, Croatia

^b Department of Archaeology, Croatian Academy of Sciences and Arts, Zagreb, Croatia

^c Private Dental Practice, Imotski, Croatia

^d Department of Radiology, University Clinical Hospital 'Sestre Milosrdnice', Zagreb, Croatia

ABSTRACT Salivary gland inclusions in the mandible are relatively uncommon in recent as well as archaeological populations. This condition is well known to oral surgeons, but less so to anthropologists, osteologists and skeletal biologists. At present a limited number of reports pertaining to this condition in ancient populations are available in anthropological and palaeopathological literature, although scattered reports of cases in recent populations are found in dental journals. This paper analyses the prevalence of Stafne's bone defect in a large composite Croatian archaeological series ($n = 4250$ mandibles), and reports on two cases in which computerised tomography was performed, in order to draw the attention of anthropologists, osteologists and skeletal biologists to this condition when faced with differential diagnosis of odontogenic lesions, cysts and neoplasms in the area of the angle of the mandible. Copyright © 2009 John Wiley & Sons, Ltd.

Key words: Stafne's defect; lingual cortical mandibular defect; CT analysis; skeletal anomaly; non-metric trait; Croatia

Introduction

Bones and teeth are one of the most enduring physical evidences of existence of an individual after his death. They register many physiological and health changes that occur in an individual's life from birth to death. The only question is: how good is our ability to read the secrets of bones and teeth? Our ability often depends on the nature of the material available for interpretation. The reliability of our conclusions is proportional to the reliability of the available information sources. A combination of sophisticated technology devices and direct examination of dry bones and teeth in bioarchaeological investigations offers the best and most accurate answers on initial questions and doubts. Diagnosis and interpretation of

dental diseases and their analysis in a palaeodemographic framework are an indispensable part of any attempt to reconstruct past way of life from human skeletal remains (Brothwell, 1981; Iscan & Kennedy, 1989; Vodanovic *et al.*, 2005; Slaus, 2008).

Unfortunately, the importance of analysing skeletal material from recent and archaeological skeletal collections for understanding the aetiology and pathophysiology of some diseases and changes affecting bones is often underrated. There are many examples where some (pathological) changes affecting bones are discussed in clinical reports, but are rarely the subjects of anthropological research. Lingual cortical defects of the body of the mandible also known as Stafne's defects have often been a subject of clinical investigations, but there are only few papers reporting on these defects in archaeological contexts.

The first description of what today is termed lingual mandibular depression or Stafne's defect was given by Stafne (1942). He described 35 radiolucent lesions in the mandibular angle discovered on intraoral dental

* Correspondence to: Department of Dental Anthropology, School of Dental Medicine, University of Zagreb, Gundulićeva 5, HR-10000 Zagreb, Croatia.
e-mail: vodanovic@sfzg.hr

films. These posterior lingual defects are typically elliptic or rounded depressions that vary in size from 1 to 3 cm (radiographically), with the widest portion of the defects being parallel to the inferior border of the mandible. Because the defects are constant in position (inferior to the third molars) and appearance, and are not accompanied by pain, discomfort or any history of trauma, Stafne concluded that they are congenital in origin and represent a failure of normal bone deposition in an area previously occupied by cartilage. Subsequent research led Stafne to believe that such cavities may represent developmental defects. Many researchers now classify these defects as developmental anomalies resulting from pressure erosion or inclusion of a portion of the submandibular salivary gland (Choukas & Toto, 1960; Wood & Goaz, 1997; Apruzzese & Longoni, 1999).

After Stafne, many researchers and clinicians reported on the different appearances of lingual mandibular depressions, and recommended methods for their interpretation and evaluation (Reuter, 1998; Apruzzese & Longoni, 1999; Branstetter *et al.*, 1999; Katz *et al.*, 2001; de Courten *et al.*, 2002; Dorman & Pierse, 2002; Philipsen *et al.*, 2002; Drage *et al.*, 2003; Campos *et al.*, 2004; Queiroz *et al.*, 2004; Quesada-Gomez *et al.*, 2006; Segev *et al.*, 2006; Shimizu *et al.*, 2006). Although, there are many clinical reports on Stafne's bone defects there are, to our knowledge, only a few that report on the presence of this condition in skeletons deriving from archaeological contexts, Table 1 (Finnegan & Marcsik, 1980; Graham, 1980; Mann, 1990; Mann & Tsaknis, 1991; Mann & Shields, 1992; Shields, 2000; Lukacs & Rodriguez Martin, 2002; Masnicova & Benus, 2003; Jordana *et al.*, 2007).

Clinically and radiologically Stafne's defects can present diagnostic problems as they are similar in appearance to periapical lesions. This could be of particular importance to inexperienced researchers dealing with dry jaws as this misdiagnosis could lead

to false prevalences and wrong interpretations of alveolar bone defects. The differential diagnosis of Stafne's bone defects includes benign and malignant jaw lesions such as odontogenic cystic lesion, non-ossifying fibroma, fibrous dysplasia, osteomyelitis, vascular malformation, focal osteoporotic bone marrow defect, brown tumour of hyperparathyroidism, ameloblastoma, basal cell nevus syndrome, giant cell tumour or a metastasis from a primary malignant tumour (Adra *et al.*, 1980; Lam *et al.*, 1994; Prapanpoch & Langlais, 1994; Parvizi & Rout, 1997; Wood & Goaz, 1997; Segev *et al.*, 2006). Thus, in clinical circumstances, in cases in which the clinical examination and the plain film findings are not completely diagnostic, confirmatory testing with sialography, computed tomography (CT) or magnetic resonance imaging (MRI) is warranted (Branstetter *et al.*, 1999; Shimizu *et al.*, 2006; Noonan *et al.*, 2008). Except for sialography, all of these methods can also be useful for confirmation of diagnosis during examination of skeletal remains. To our knowledge, there are no reports in the anthropological literature on the CT appearance of a Stafne's bone cavity performed on human skeletal remains from archaeological contexts.

The objectives of this paper are twofold: (1) to bring Stafne's bone defect to the attention of practicing anthropologists, osteologists and skeletal biologists because they should be familiar with the range of expression, and location of cortical bone depressions and defects potentially observable in the mandible (Lukacs & Rodriguez Martin, 2002), as certain types of bone cavities mimic periapical abscesses (Anneroth *et al.*, 1990) and (2) to present and analyse for the first time in Croatian archaeological series prevalence data on Stafne's bone defect. So far, no data are available regarding the prevalence and features of this defect in the populations that inhabited modern Croatia. According to data presented in Table 1, few studies were performed on larger samples, and none on a sample that encompassed such a long period of time.

Table 1. Data on investigations of Stafne's defect in archaeological populations

Author(s), year of publication	Dating of the sample (century)	Geographic location of the sample	Sample size	Examination technique
Finnegan & Marcsik, 1980	6th–9th	Hungary	5519	M
Graham, 1980	Prehistoric	NA	1	M
Jordana <i>et al.</i> , 2007	12th	Barcelona, Spain	1	M, X
Lukacs & Rodriguez Martin, 2002	1st–14th	Canary Islands	452	M
Mann & Tsaknis, 1991	NA	China, Egypt, Mongolia, USA	6700	M, X
Mann, 1990	NA	USA	1	M, X
Masnicova & Benus, 2003	9th; 11th–12th	Slovakia	124	M
Shields, 2000	Sampled globally within the past 2000 years		7686	M

NA, not applicable; M, macroscopic examination; X, X-ray.

Table 2. Number of skeletons in the osteological collection of the Croatian Academy of Sciences and Arts

Period	Number of skeletons/number of analysed mandibles	Gender distribution subadult (<15 years)/female/male	Number of mandibles with Stafne's defect (%)
Prehistoric (Approximately 8000 BC to 5th century BC)	98/49	7/17/25	0 (0.00%)
Antique (2nd century AD to 5th century AD)	1021/875	262/315/298	1 (0.11%)
Early medieval (6th to 10th century AD)	1102/911	246/319/346	0 (0.00%)
Late Medieval (11th to 13th century AD)	1874/1561	468/546/547	1 (0.06%)
Historic (14th to 18th century AD)	976/854	256/290/308	0 (0.00%)
Total (Approximately 8000 BC to 18th century AD)	5071/4250	1239/1487/1524	2 (0.05%)

Materials and methods

The studied skeletons are part of the Osteological collection of the Croatian Academy of Sciences and Arts and are curated in Zagreb. At present, the collection consists of 5071 skeletons recovered from Croatian archaeological sites dated from the prehistoric to the historic period. The number of skeletons in the collection is shown in Table 2.

For the purpose of this study, all mandibles from the collection were examined for cortical defects. The procedure recommended by Lukacs & Rodriguez Martin (2002) was used for macroscopic description of the Stafne's defect.

As the second step in a sequential diagnostic approach, CT was performed. CT examination was performed using Syngo CT 2006G (Siemens Medical Systems, Erlangen, Germany). CT diagnostic criteria for confirmation of the previously established macroscopic diagnosis of Stafne's bone defect were:

- discontinuity in the lingual cortex,
- sharply demarcated round or oval lesion,
- position of the lesion below the mandibular canal close to the mandibular angle,
- possible erosion in the buccal cortex.

Results

Although 4250 mandibles were examined, only two exhibited defects on the lingual side that could be described as Stafne's defects (antique and late medieval sample). Numerous other periapical defects of odontogenic origin were noted in the analysed mandibles but in all of these cases there was no diagnostic doubt. The

prevalence of Stafne's defect in the antique sample is 0.11%, 1/875 (females 0.00% and males 0.34%). The prevalence of Stafne's defect in the late medieval sample is 0.06%, 1/1561 (females 0.00% and males 0.18%). The prevalence of Stafne's defect in the whole sample is 0.05%, 2/4250 (females 0.00% and males 0.13%). Descriptive summary for each Stafne's defect observed in this study are presented in Table 3 (refer to Figures 1–3).

In the individual recovered from the Antique site Zmajevac (grave No. 79; male, 45–49-years-old), the defect is unilateral and located on the left lingual side of the mandible, inferior to the second and third molar, and at a point 4.3 mm above the inferior margin of the body of the mandible (Figure 1). The margins of the defect are discrete and clearly demarcated and the floor of the depression is smooth. The shape of the defect is oval with the long axis oriented anterior–posterior. The lesion measures 11.2 mm anterior–posterior and

Table 3. Attributes of Stafne's defects in the Croatian archaeological sample

Site	Zmajevac	Korlat Sv. Jere
Specimen number	79	228
Sex	Male	Male
Age	45–49	40–44
Side	Left	Left
Length	11.2	12.8
Height	8.6	8.2
Depth	6.3	6.3
Texture	Smooth	Smooth
Position	IM2–IM3	IM2–IM3
Margins	DM	DM
Shape	Oval	Oval

All measurements are expressed in millimetres. IM2, inferior to second lower molar; IM3, inferior to third lower molar; DM, discrete and clearly demarcated margin.

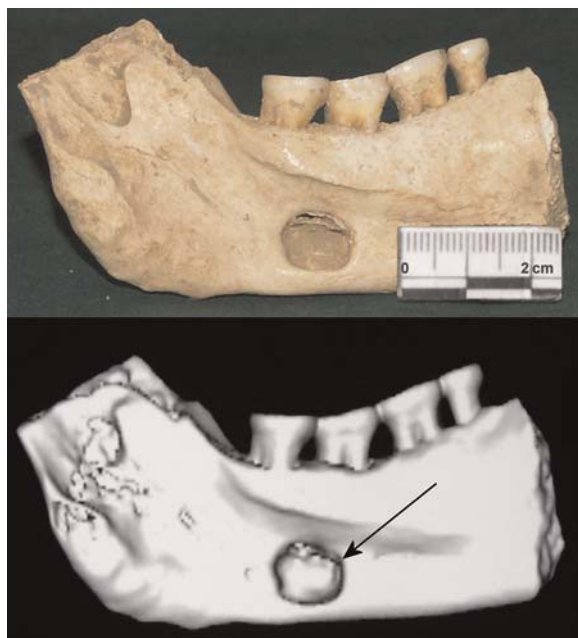

Figure 1. Expression of Stafne's defect on the specimen from Zmajevac (grave No. 79) on the left side of the mandible (photograph and three-dimensional CT volume rendering reconstructed image). This figure is available in colour online at wileyonlinelibrary.com.

8.6 mm in height. This defect is categorised as a deep lesion (6.3 mm). CT showed a well-defined lingual defect in the posterior aspect of the left side of the mandible (Figure 3). The buccal cortex was thinned and slightly expanded, but with no invasive features.

In the individual recovered from the Late Medieval site Korlat Sv. Jere (grave No. 228; male, 40–44-years-old) the defect is again unilateral and located on the left lingual side of the mandible. It displays clearly demarcated margins, and is situated inferior to third lower molar with a slight distal shift (Figure 2). The inferior margin of the defect is 3.2 mm above the inferior margin of the body of the mandible, and has an oval appearance. The defect measures 12.8 mm anterior–posterior and 6.3 mm superior–inferior, and the floor of the depression is smooth. As in previous case, this defect is categorised as a deep lesion (6.3 mm). CT scans showed a well-defined concavity of the lingual mandibular cortex. CT images of both cases displayed a characteristic opening of the defect in the lingual mandibular cortex. No associated pathological changes could be identified (Figure 3).

Discussion

Lingual mandibular bone depressions (known also as developmental salivary gland defect, Stafne's defect,

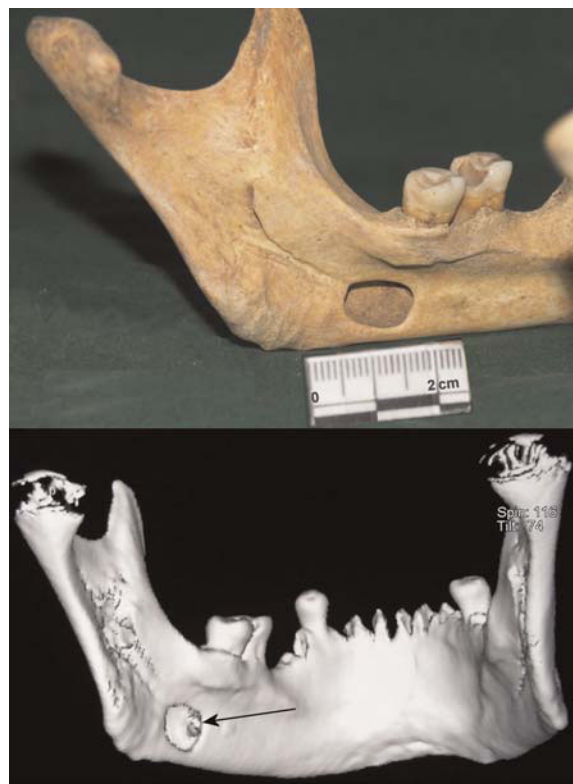

Figure 2. Expression of Stafne's defect on the specimen from Korlat Sv. Jere (grave No. 228) on the left side of the mandible (photograph and three-dimensional CT volume rendering reconstructed image). This figure is available in colour online at wileyonlinelibrary.com.

Stafne's bone cyst, static bone cavity and latent bone cyst) represent a group of concavities in the lingual surface of the mandible, where the depression is lined with an intact outer cortex. Historically, they were referred to as pseudocysts because radiographically they resemble cysts, but as no epithelial lining is present they cannot be considered true cysts. The most common location is within the submandibular gland fossa and often close to the inferior border of the mandible (Whaites, 2002; White & Pharoah, 2004). This lingual posterior variant of these depressions was first described by Stafne (1942).

The pathogenesis of these lesions is not fully understood. Surgery, biopsy and radiographic analyses revealed that the vast majority of Stafne's defects, which in osteological specimens can measure more than 3 cm in length, contain normal submandibular gland tissue, fatty tissue, muscle, lymph or vascular tissue. These findings led many researchers to conclude that Stafne's defects form in one of the four ways: (1) either during embryonic development of the mandible and contain 'entrapped' or aberrant salivary

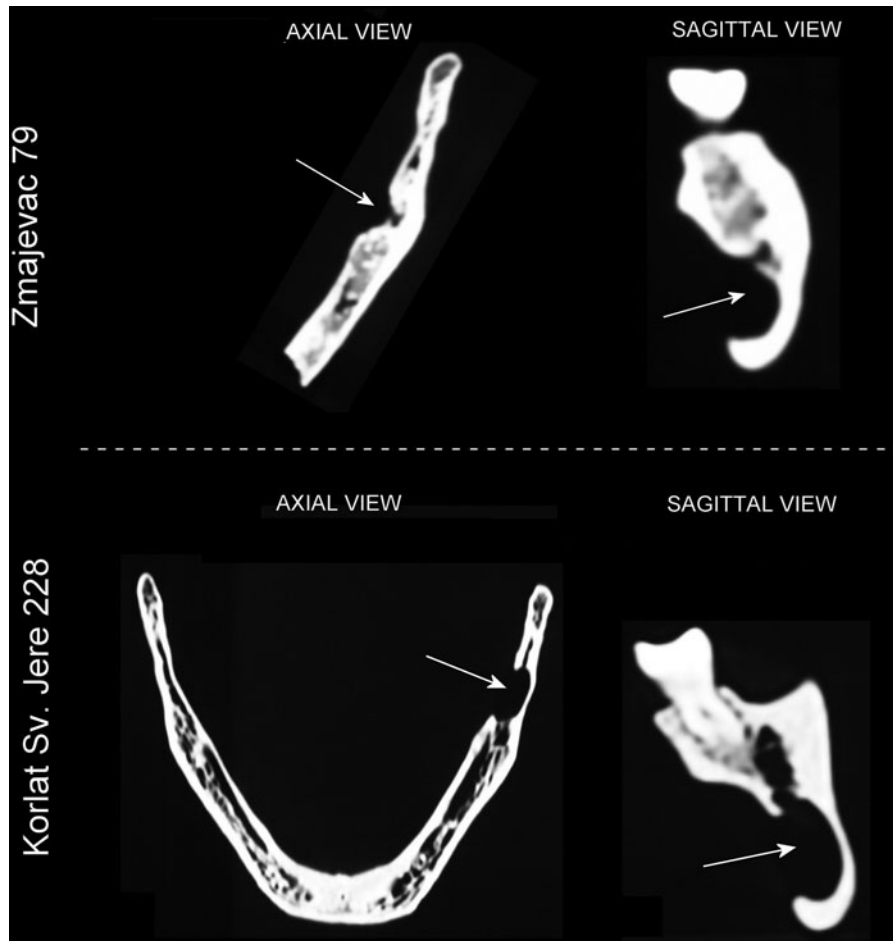


Figure 3. Multiplanar reconstructed images displaying the mandibular defects in axial and sagittal view (the Zmajevac specimen is shown above and the Korlat Sv. Jere specimen is shown below).

gland tissue; or (2) as a result of enlargement of adjacent soft tissues, especially the submandibular gland; or (3) pressure erosion by the facial artery; or (4) simple (Mendelian) inheritance (Mann & Tsaknis, 1991; Wood & Goaz, 1997; Apruzzese & Longoni, 1999; Mann & Hunt, 2005). Two of the four most popular hypotheses are that the defect is congenital, or that the defect develops later in life through pressure resorption. The first theory suggests that part of the salivary gland becomes entrapped during the development and ossification of the mandible, and the constancy of position, the uniformity of appearance, the occasional bilateral occurrence and the failure to change with time are generally considered as evidence of this hypothesis. The major objection to this hypothesis is that these defects are much more common in adults than in children; therefore, it seems probable that these lesions develop later in life, after ossification of the mandible and that CT imaging of

some of these defects reveals fat tissue and no evidence of gland (White & Pharoah, 2004). Histological studies of Harvey & Noble (1968) showed that the incremental lines of the mandible are disrupted by the defect. They also presented evidence of active resorption of bone and nearby regions of bone deposition in two cases, the typical response of bone to an expanding lesion. It thus appears that these lesions probably result from the pressure exerted by the submandibular gland in posterior defects and by the sublingual gland in anterior defects (Choukas & Toto, 1960). However, because of the great mobility of the floor of the mouth, it is quite surprising that the gland remains in close proximity to the mandible for a sufficiently long period to cause resorption. Moreover, there is no evidence of any pathologic change or enlargement of the gland in the reported cases. Some authors believe that there is compensatory hypertrophy caused by the lymphocyte infiltration and reduced secretory efficiency, which

increases with age, whereas others believe that there is a growth of the gland as part of general somatic growth. At present, however, none of these hypotheses has been unequivocally confirmed (Apruzzese & Longoni, 1999).

The appearance and location of this developmental bone defect on the radiographic images are specific and could be easily identified. Lingual mandibular bone depressions can be readily differentiated from odontogenic lesions such as cysts because the epicentre of the majority of odontogenic lesions is located above the inferior alveolar canal (Stafne's defect is located below the inferior alveolar nerve canal and anterior to the angle of the mandible, in the region of the antegonial notch and submandibular gland fossa). However, when the defect is related to the sublingual gland and appears above the canal, odontogenic lesions should be considered in differential diagnosis. The defect may increase in size with time. There are rare reports of salivary gland neoplasms developing in the soft tissue within the defect. Destruction of the well-defined cortex of the defect may indicate the presence of a neoplasm (White & Pharoah, 2004). The two Stafne's defects analysed in this study exhibit a typical appearance, leaving no space for doubts about the diagnosis. Macroscopic dry bone diagnosis was additionally confirmed by CT analysis. Axial and sagittal CT scans showed a focal cortical defect on the lingual side of the mandible without medullar bone between bottom of the defect and the buccal cortex. The buccal cortex of the mandible was maintained. In both specimens, the defect was unilocular, placed below the mandibular canal. An empty bony space located below the mandibular canal could also suggest a traumatic bone cyst (also referred to as haemorrhagic bone cyst). The traumatic bone cyst is an uncommon, unlined cavity of the jaws. Clinically, the lesion is asymptomatic in the majority of cases and is often accidentally discovered on routine radiological examination. A cyst-like void could also indicate a dentigerous cyst—an odontogenic cyst—thought to be of developmental origin—associated with the crown of an unerupted (or partially erupted) tooth. But in our cases, the molars above the lesions are fully erupted. Periapical cysts were excluded at the beginning because there were no signs of severe destruction of hard dental tissues (deep carious lesions or heavy tooth abrasion) that could cause inflammation of the pulp or pulp death and lead to the destruction of periapical bone. The carious lesion on the distal surface of the lower left first molar on the mandible from the archaeological site Korlat Sv. Jere was not deep enough to cause pathological changes of the pulp. Tooth

abrasion on teeth from site Zmajevac could be classified as moderate, and additionally all teeth had the same level of abrasion. This excludes teeth abrasion as a reason for pathological changes of pulp. But if these bone lesions were found on a living patient, where there is no possibility of direct examination of the bones and only indirect examination methods are available like radiographs, CT or MR images, differential diagnosis possibilities must be taken into account when assessing such defects. Nevertheless, definitive differential diagnosis from other lesions sometimes cannot be made without surgical exploration.

Although lingual mandibular bone depressions appear to be relatively rare, with an incidence in the modern population of about 0.10–0.48%, it is likely that many go unreported (White & Pharoah, 2004). It is considered that only those cases in which resorption of the lingual cortex was extensive had the classic radiographic appearance described by Stafne. Therefore, it is probable that these lesions are more common than published reports indicate. If this is the case, the presence of these defects may be no more than a reflection of a normal anatomic variation, producing radiographically detectable changes only in extreme cases (Apruzzese & Longoni, 1999). Lukacs & Rodriguez Martin (2002) found that among the prehistoric skeletons of Tenerife in the Canary Islands (Spain), the prevalence of lingual cortical defects was 3.32% and that males were more frequently affected than females. Masnicova & Benus (2003) studied the developmental anomalies in skeletal remains from the Great Moravia and Middle Ages Cemeteries at Devin (Slovakia). The prevalence of Stafne's bone defect in their sample was 1.2% for both sexes and 3.1% for males alone. Shields examined 7686 mandibles sampled globally within the past 2000 years and found that the global variation in the population prevalence of Stafne's bone defect ranges from 10% in the tropics to virtually 0% in most of the arctic (Shields, 2000). Finnegan & Marcsik (1980) examined archaeological sites in Hungary and found that a total sample of 5519 mandibles produced 59 (1.07%) Stafne defects. The prevalence of Stafne's defect in the sample analysed in this study is 0.05%. Although this prevalence is lower than those recorded in other studies, the size of the sample confirms the reliability of the data. Different prevalences reported in the anthropological literature suggest some population variation in defect frequency. Data on Stafne's bone defect prevalence in living populations can be influenced by different diagnostic techniques, but investigations performed on dry mandibles are not affected by this problem. The nature of the develop-

ment and growth of Stafne's defect is opposite to the nature of the development and growth of periapical lesions. Periapical lesions start to develop close to the tooth root in the middle of the jaw and expand to the outer border of the bone. Depending on the severity of the inflammatory process, and the moment of observation, the bone defect caused by odontogenic infection does not necessarily have to be visible on the outer border of the jaw. That is why radiographic methods are considered to be the most accurate way of determining the prevalence of periapical lesions. If they are not used in dry skulls, false low prevalence rates can be established. In contrast to this, Stafne's defects are considered to start at the outer border of the bone and expand inwards (Choukas & Toto, 1960). If this is true, it means that every phase of the development of the defect is easily and unmistakable visible in dry bone (Philipsen *et al.*, 2002).

The trait primarily affects middle-aged or older individuals, and is more prevalent in males than females (Lukacs & Rodriguez Martin, 2002; Mann, 2004). The highest prevalence was found in the fifth and sixth decades. A striking male predilection was recorded, with 80–90% of the cases occurring in men (Katz *et al.*, 2001; Mann, 2004). The age and sex distribution of Stafne's defects in the Croatian sample closely follow the overall patterning of the trait described by other authors.

CT analysis of Stafne's bone defects was performed by numerous authors (Reuter, 1998; Katz *et al.*, 2001; Philipsen *et al.*, 2002; Drage *et al.*, 2003; Campos *et al.*, 2004; Quesada-Gomez *et al.*, 2006; Segev *et al.*, 2006; Shimizu *et al.*, 2006). The fact that computerised tomography is more specific to bone lesions of the jaws and much less so to soft tissue have led some authors to advocate MRI as the primary diagnostic technique (Segev *et al.*, 2006). The absence of soft tissues in archaeological skeletal remains makes computerised tomography more suitable for detailed analysis of Stafne's defects. Although on dry skulls the diagnosis of Stafne's defect can be established without the use of computerised tomography, this method can provide additional data on the size and shape of the defect, and its relationship to other anatomical structures. Computerised tomography analysis of a large number of dry skulls with Stafne's bone defects can offer valuable information on aetiology and development of these defects.

Conclusion

Stafne's defect is rarely mentioned in palaeopathological literature, probably because of the low frequency

of the defect and the fragility of ancient bones. Anthropologists, osteologists and skeletal biologists should be aware of the possible presence of Stafne's bone cavity in the mandible and, when appropriate, should include it in differential diagnosis. The current consensus of opinion is that Stafne's bone defects are not regarded as pathological lesions but as an anomalous, low frequency feature of normal skeletal variation. The relatively large differences in defect prevalence suggest the usefulness of this trait as a non-metric variant in the analysis of population distance. Because of the possibility that environmental factors, including dietary and food preparation practices, may result in hypertrophy of salivary glands, further investigations are needed (Lukacs & Rodriguez Martin, 2002). CT analysis of dry bone specimens is a suitable method for the further investigation of the aetiology and biology of Stafne's bone defects. Data presented in this study are of not only anthropological but also clinical importance for researchers investigating South Slavic populations.

Acknowledgements

The authors thank Robert W. Mann, Vikki Noonan and Axel Ruprecht for their help during the preparation of this paper. This research was supported by the Ministry of Science, Education and Sports of the Republic of Croatia—grant No. 065-0650445-0423 and 101-197-0677-0670.

References

- Adra NA, Barakat N, Melhem RE. 1980. Salivary gland inclusions in the mandible: Stafne's idiopathic bone cavity. *American Journal of Roentgenology* **134**: 1082–1083.
- Anneroth G, Berglund G, Kahnberg KE. 1990. Intraosseous salivary gland tissue of the mandible mimicking a periapical lesion. *International Journal of Oral and Maxillofacial Surgery* **19**: 74–75.
- Apruzzese D, Longoni S. 1999. Stafne cyst in an anterior location. *Journal of Oral and Maxillofacial Surgery* **57**: 333–338.
- Branstetter BF, Weissman JL, Kaplan SB. 1999. Imaging of a Stafne bone cavity: what MR adds and why a new name is needed. *American Journal of Neuroradiology* **20**: 587–589.
- Brothwell DR. 1981. *Digging Up Bones: The Excavation, Treatment and Study of Human Skeletal Remains*. Oxford University Press: London.
- Campos PS, Panella J, Crusoe-Rebello IM, Azevedo RA, Pena N, Cunha T. 2004. Mandibular ramus-related

- Stafne's bone cavity. *DentoMaxilloFacial Radiology* 33: 63–66.
- Choukas NC, Toto PD. 1960. Etiology of static bone defects of the mandible. *Journal of Oral Surgery, Anesthesia, and Hospital Dental Service* 18: 16–20.
- de Courten A, Kuffer R, Samson J, Lombardi T. 2002. Anterior lingual mandibular salivary gland defect (Stafne defect) presenting as a residual cyst. *Oral Surgery, Oral Medicine, Oral Pathology, Oral Radiology, and Endodontics* 94: 460–464.
- Dorman M, Pierse D. 2002. Ectopic salivary gland tissue in the anterior mandible: a case report. *British Dental Journal* 193: 571–572.
- Drage N, Renton T, Odell E. 2003. Atypical Stafne bone cavity. *Clinical Radiology Extra* 58: 51–53.
- Finnegan M, Marcsik A. 1980. Anomaly or pathology: the Stafne defect as seen in archaeological material and modern clinical practice. *Journal of Human Evolution* 9: 19–31.
- Graham EE. 1980. A probable submandibular gland defect in a prehistoric mandible. *Oral Surgery, Oral Medicine, Oral Pathology, Oral Radiology and Endodontics* 50: 187–189.
- Harvey W, Noble H. 1968. Defects on the lingual surface of the mandible near the angle. *The British Journal of Oral Surgery* 6: 75.
- Iscan MY, Kennedy KAR. 1989. *Reconstruction of Life from the Skeleton*. Alan R. Liss, Inc.: New York.
- Jordana X, Garcia Sivoli C, Galtés I, Palacios M, Cos M, Malgosa A. 2007. Report on a Stafne defect in a man from medieval age. *Journal of Oral and Maxillofacial Surgery* 65: 556–559.
- Katz J, Chaushu G, Rotstein I. 2001. Stafne's bone cavity in the anterior mandible: a possible diagnostic challenge. *Journal of Endodontics* 27: 304–307.
- Lam EW, Ruprecht A, Dolan KD, Frank JA. 1994. Osteomyelitis of the mandible simulating a Stafne mandibular cortical defect. *Annals of Otolaryngology and Laryngology* 103: 490–494.
- Lukacs J, Rodriguez Martin C. 2002. Lingual cortical mandibular defects (Stafne's defect): an anthropological approach based on prehistoric skeletons from the Canary Islands. *International Journal of Osteoarchaeology* 12: 112–126.
- Mann RW. 1990. Incipient lingual cortical mandibular defect in a 10- to 12-year-old American Indian child. *American Journal of Roentgenology* 154: 658–659.
- Mann RW, Hunt DR. 2005. *Photographic Regional Atlas of Bone Disease: A Guide to Pathologic and Normal Variation in the Human Skeleton*. Charles C. Thomas: Springfield.
- Mann RW, Shields ED. 1992. Cavitation defects on the lingual ramus: a further expression of Stafne's defect. *Journal of Craniofacial Genetics and Developmental Biology* 12: 167–173.
- Mann RW, Tsaknis PJ. 1991. Cortical defects in the mandibular sulcus. *Oral Surgery, Oral Medicine, and Oral Pathology* 71: 514–516.
- Masnicova S, Benus R. 2003. Developmental anomalies in skeletal remains from the Great Moravia and Middle Ages Cemeteries at Devin (Slovakia). *International Journal of Osteoarchaeology* 13: 266–274.
- Noonan V, Kemp S, Gallagher G, Kabani S. 2008. Stafne defect. *Journal of the Massachusetts Dental Society* 57: 41.
- Parvizi F, Rout PG. 1997. An ossifying fibroma presenting as Stafne's idiopathic bone cavity. *DentoMaxilloFacial Radiology* 26: 361–363.
- Philipsen HP, Takata T, Reichart PA, Sato S, Sueti Y. 2002. Lingual and buccal mandibular bone depressions: a review based on 583 cases from a world-wide literature survey, including 69 new cases from Japan. *DentoMaxilloFacial Radiology* 31: 281–290.
- Prapanpoch S, Langlais RP. 1994. Lingual cortical defect of the mandible: an unusual presentation and tomographic diagnosis. *DentoMaxilloFacial Radiology* 23: 234–237.
- Queiroz LM, Rocha RS, de Medeiros KB, da Silveira EJ, Lins RD. 2004. Anterior bilateral presentation of Stafne defect: an unusual case report. *Journal of Oral and Maxillofacial Surgery* 62: 613–615.
- Quesada-Gomez C, Valmaseda-Castellon E, Berini-Ayres L, Gay-Escoda C. 2006. Stafne bone cavity: a retrospective study of 11 cases. *Medicina Oral, Patología Oral y Cirugía Bucal* 11: E277–E280.
- Reuter I. 1998. An unusual case of Stafne bone cavity with extra-osseous course of the mandibular neurovascular bundle. *DentoMaxilloFacial Radiology* 27: 189–191.
- Segev Y, Puterman M, Bodner L. 2006. Stafne bone cavity—magnetic resonance imaging. *Medicina Oral, Patología Oral y Cirugía Bucal* 11: E345–E347.
- Shields ED. 2000. Technical note: Stafne static mandibular bone defect—further expression on the buccal aspect of the ramus. *American Journal of Physical Anthropology* 111: 425–427.
- Shimizu M, Osa N, Okamura K, Yoshiura K. 2006. CT analysis of the Stafne's bone defects of the mandible. *DentoMaxilloFacial Radiology* 35: 95–102.
- Slaus M. 2008. Osteological and dental markers of health in the transition from the Late Antique to the Early Medieval period in Croatia. *American Journal of Physical Anthropology* 136: 455–469.
- Stafne E. 1942. Bone cavities situated near the angle of the mandible. *Journal of the American Dental Association* 29: 1969–1972.
- Vodanovic M, Brkic H, Slaus M, Demo Z. 2005. The frequency and distribution of caries in the mediaeval population of Bijelo Brdo in Croatia (10th–11th century). *Archives of Oral Biology* 50: 669–680.
- Whaites E. 2002. *Essentials of Dental Radiography and Radiology*. Churchill Livingstone: Edinburgh.
- White SC, Pharoah MJ. 2004. *Oral Radiology: Principles and Interpretation*. Mosby: St. Louis, London.
- Wood NK, Goaz PW. 1997. *Differential Diagnosis of Oral and Maxillofacial Lesions*. Mosby: St. Louis, London.