

Aesthetic Dental Sinergija: Zbornik sažetaka kongresa Hrvatskog društva estetske dentalne medicine i Udruženja za estetsku stomatologiju Srbije

Edited book / Urednička knjiga

Publication status / Verzija rada: **Published version / Objavljena verzija rada (izdavačev PDF)**

Publication year / Godina izdavanja: **2023**

Permanent link / Trajna poveznica: <https://urn.nsk.hr/urn:nbn:hr:127:429275>

Download date / Datum preuzimanja: **2024-11-23**



Repository / Repozitorij:

[University of Zagreb School of Dental Medicine
Repository](#)



ZBORNIK SAŽETAKA

PULP
PREMOLARS
CHECK
CLEANING
DENTAL
PREMOLAR
PROPHYLAXIS
DENTIN
ENAMEL
HEALTH
DECAY
BRIDGE
BRACES
ORTHODONTIST
TEETH
GINGIVITIS
CROWN
ORAL
PROFESSIONAL

DEMENTAL

EDUCATION

CROWN
CLEANING
ORTHODONTIST
CAD/CAM
X-RAYS
TEETH
VENEERS

CARE
ENAMEL
THIRD
DENTAL
COMPOSITES
MOLARS
BLEACHING
INCISORS
ABSCESS
EXOCAD



18.-20. 5. 2023.
OPATIJA, HRVATSKA



ad-sinergija

ISSN 2671-0595

IMPRESSUM

Zbornik sažetaka kongresa Hrvatskog društva estetske dentalne medicine i Udruženja za estetsku stomatologiju Srbije

NAKLADNIK

Hrvatsko društvo estetske dentalne medicine
Rudeška cesta 234, 10000 Zagreb, Hrvatska

UREDNICI

prof. dr. sc. Amir Ćatić

catic@sfzg.hr

prof. dr. sc. Nikša Dulčić

dulcic@sfzg.hr

dr. sc. Larisa Musić

lmusic@sfzg.hr

MARKETING I FINACIJE

Dominik Pleše, dr. med. dent.

dominik.plese7@gmail.com

MJESTO I GODINA IZDANJA

Zagreb, 2023.

TISAK

Argenta d.o.o., Zagreb

NAKLADA

700 primjeraka

ISSN 2671-0595





ORGANIZATORI

Hrvatsko društvo estetske dentalne medicine
Udruženje za estetsku stomatologiju Srbije
Hrvatska komora dentalne medicine

MJESTO ODRŽAVANJA

Centar Gervais
Ul. Nikole Tesle 5, 51410 Opatija, Hrvatska

ORGANIZACIJSKI ODBOR

Predsjednici:

izv. prof. dr. sc. Joško Viskiće
Igor Ristić, dr. med. dent.

Članovi:

Marijo Rezo, dent. teh.
izv. prof. dr. sc. Miodrag Šćepanović
Dominik Pleše, dr. med. dent.
prof. dr. sc. Amir Ćatić
Saša Bulić, dent. teh.
prof. dr. sc. Nikša Dulčić
Laslo Svoboda, dent. teh.
Bruno Jakovčić, dent. teh.
dr. sc. Larisa Musić
dr. sc. Žarko Udiljak
Petra Rajčić, univ. mag. med. dent.

ZNANSTVENI ODBOR

Predsjednik:

prof. Rade Paravina, DMD, MS, PhD

Članovi:

prof. dr. sc. Amir Ćatić
prof. dr. sc. Nikša Dulčić
izv. prof. dr. sc. Miodrag Šćepanović
izv. prof. dr. sc. Joško Viskiće
dr. sc. Larisa Musić



UVODNA RIJEČ

Poštovane kolegice i kolege,

Hrvatsko društvo estetske dentalne medicine i Udruženje za estetsku stomatologiju Srbije kao dvije vizije izvrsnosti u estetskoj dentalnoj medicini s ponosom najavljuju kongres Aesthetic Dental Sinergija. Uz suorganizaciju Hrvatske komore dentalne medicine, te uz potporu vodećih vizionarskih kompanija i najvećih sponzora u dentalnoj medicini, kongres će se održati u predivnoj Opatiji od 18. do 20. svibnja 2023., a okupit će neka od najpoznatijih svjetskih imena iz svijeta dentalne medicine. Svaki od dana kongresa ponudit će raznolike znanstvene, stručne, društvene i kulturne sadržaje. Veselimo se zajedničkom druženju u Opatiji!

Do tada, srdačan pozdrav u ime Organizacijskog odbora.

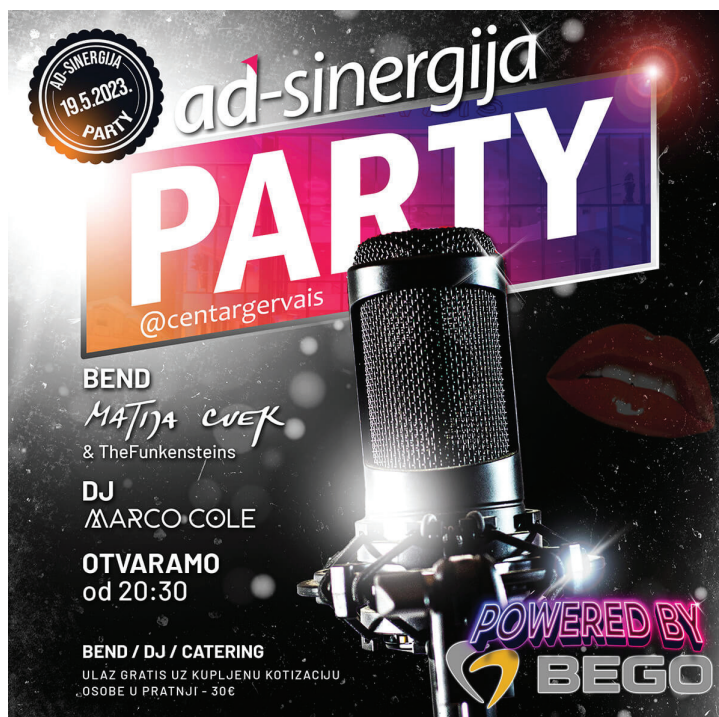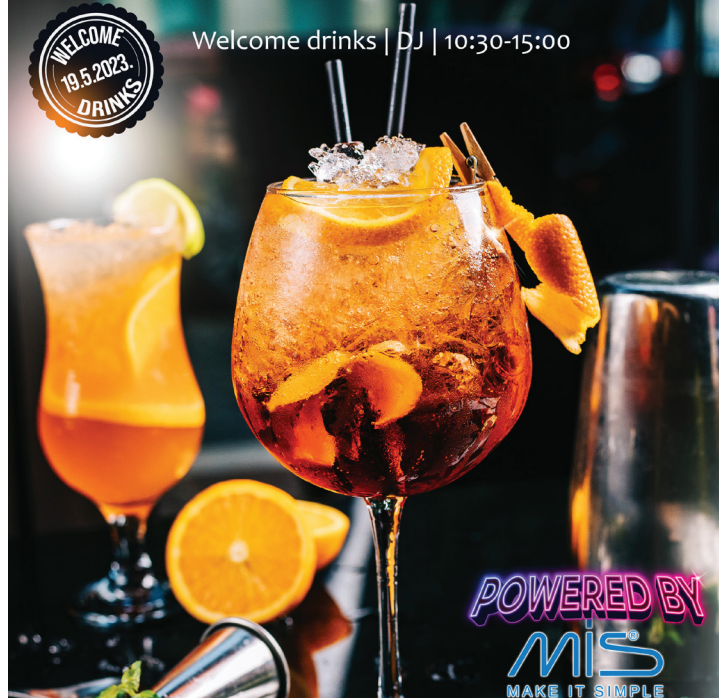Predsjednik HDEDM-a, izv.prof.dr.sc. Joško Viskiće
Predsjednik UESS-a, Igor Ristić, dr.med.dent.

SPONZORI: Bego, Dentsply Sirona, MIS Implants
Align, Botiss, Dental Grupa, Dental Solutions, GC, Ivoclar, Manodent, Novodent,
Straumann Group
3M, Aether, Denum Medical, Durr Dental, Maico, Medest, Ultradent
Bredent, Dental Tribune, DG Shape, Futura Dental, Grenke, Humed Pharma, Interdent,
Lifestyle Dentistry, Medical Intertrade, Quintessence, Renfert, Sanitaria Dental,
Shining 3D Dental, SprintRay, W&H

Četvrtak, 18. svibnja 2023.

DVORANA 1

- 14:30-15:30 Jan-Frederik GÜth
*Complex cases in dental prosthetics
- How simplification leads to higher
quality*
- 15:30-16:15 Rafael Beolchi
*New Materials and Techniques for
Imperceptible Restorations: Key
points to esthetics and Longevity*
- 16:15-16:45 PAUZA ZA KAVU
- 16:45-17:15 Danko Relić
*Smjernice za korištenje društvenih
mreža te poticanje razvoja
e-profesionalizma doktora medicine i
doktora dentalne medicine*
- 17:15-18:00 Markus Tröltzsch
Failing Implants - treatment options
- 18:00- 19:00 Luka Stojić, Igor Galić, Igor Smojver
*Digitalni alati u implantoprotetskoj
rehabilitaciji*
- 20:30-... Gala večer - Hotel Imperial
Powered by DENTSPLY SIRONA





Petak, 19. svibnja 2023.

DVORANA 1

- 09:30-10:15 Dimitar Filtchev
Prosthetic guided implantology – how the digital workflow changes our daily lives
- 10:15-11:00 Zoran Kovač
Digitalna tehnologija: učinkovit alat ili fancy igračka
- 11:00-11:45 Ivica Anić
Kad je revizija endodontskog punjenja put do funkcijsko-estetske rehabilitacije zuba?
- 11:45-12:15 PAUZA ZA KAVU
- 12:15-12:45 **SVEČANO OTVARANJE KONGRESA**
- 12:45-13:30 Davor Seifert
Rijetki-bijeli-lijepi
- 13:30-14:15 Dimitrios Spagopoulos
Aesthetics: Synthesis through different restorative materials
- 14:15-15:15 RUČAK
- 15:15-16:00 August Bruguera
Materials from a digital perspective
- 16:00-16:10 GRENKE – financiranje opreme i uređaja
- 16:10-16:55 Angie Segatto
Time and Technology- Key Success Factors in Non Surgical Soft Tissue Management Around Implants in the Esthetic Zone
- 16:55-17:40 Serhat Aslan
Basic and advanced requirements for reconstructive peri-implant therapy: Managing the dimensions of hard and soft tissues
- 17:40-18:40 Krzysztof "Kris" Chmielewski
5 things you need to know to be successful with guided surgery
- 20:30-... PARTY - Centar Gervais
Powered by BEGO

Petak, 19. svibnja 2023.

DVORANA 2

- 09:30-10:15 Josip Brusić
Team vision & digitalni pristup u estetskoj dentalnoj medicini
- 10:15-11:00 Ryo Miwa
3 magic ingredients of perfect color matching
- 11:00-11:45 Mitsutaka Fukushima
The secret behind the perfect match - Biomic stain
- 11:45-12:15 PAUZA ZA KAVU
- 12:15-12:45 **SVEČANO OTVARANJE KONGRESA**
- 12:45-13:30 Sabine Mayer
The art of layering
- 13:30-14:15 Jan Schünemann
Non Prep
- 14:15-15:15 RUČAK
- 15:15-16:15 David Geštakovski
Injekcijska tehnika – Možemo li ostvariti polikromatski izgled
Boris Filipović
Biomehanika dentalnih ljuskica
Dario Novak
Minimally invasive smile enhancement using biometrics - Composite vs. ceramic - digital approach
- 16:15-17:00 Ali Çekici
Non-Surgical Periodontal Treatment Around Teeth and Implants
- 20:30-... PARTY - Centar Gervais
Powered by BEGO



Subota, 20. svibnja 2023.

DVORANA 1

- 9:30-10:15 Mario Bosnar
Umjetnost sjedinjena u cirkonu
- 10:15-11:00 Daniele Rondoni
How to increase your aesthetic solutions and make your patients happy, with new generation zirconia in combination of digital technology
- 11:00-11:30 PAUZA ZA KAVU
- 11:30-12:15 Riccardo Ammannato
Worn Dentition? Direct and indirect adhesive management through a non invasive approach
- 12:15-13:00 Gabriella Romano
Perioestorative treatment(s): achieving optimal tissue health and aesthetics
- 13:00-13:45 Verena Nižić, Francesco Ditommaso
Gnatologija - temelj svih protetskih rehabilitacija
- 13:45-14:45 RUČAK
- 14:45-15:30 Hans-Jürgen Joit
High end restorations as concept in big labs?
- 15:30-16:15 Erhan Çömlekoğlu
Same day digital indirect restorations: Preparation to cementation
- 16:15-17:00 Frank Spitznagel
Modern All-Ceramic Prosthodontics: State of the Art of Tooth and Implant Supported Reconstructions
- 17:00-18:00 Nazariy Mykhaylyuk
Digitalization - esthetic side
- 18:00-18:45 Aleksa Marković
Implant placement and loading in the esthetic zone - Surgical considerations
- 18:45-19:00 **ZATVARANJE KONGRESA**

Subota, 20. svibnja 2023.

DVORANA 2

- 09:30-10:15 Tomaž Ivanušič
How to stand out offering additional aesthetic procedures and grow your practice?
- 10:15-11:00 Andrija Petar Bošnjak
Temelji osmijeha - što nas čini stvarno lijepima?
- 11:00-11:30 PAUZA ZA KAVU
- 11:30-12:30 Leon Lazić
Dental Laboratory Procedures in Fixed Implantology
Matej Luk
Predvidljiva estetika
Matej Vidić
Stackable guide
- 12:45-13:45 POSTER PREZENTACIJE
- 13:45-14:45 RUČAK
- 14:45-15:30 Vladimir B. Stojilković
Korekcija donje trećine lica Art Filerima



MASTERCLASS

Četvrtak, 18. svibnja 2023.

Dentex Rijeka

09:00-18:00 Sabine Mayer
(2 dana) *The art of layering*
Dentex Rijeka

Petak, 19. svibnja 2023.

DVORANA 2

09:00-12:00 Sabine Mayer
(2 dana) *The art of layering*
Dentex Rijeka

09:00-13:00 Serhat Aslan
EDUCEN, *Periodontal and peri-implant tissue
Matulji reconstruction: Fundamentals of
microsurgical tissue handling, primary
wound closure and biomaterial
management*

09:00-13:00 Erhan Çömlekoğlu
Conference *Same day digital indirect restorations:
Park 25/7, Preparation to cementation*
Dvorana 1

16:30-19:30 Mitsutaka Fukushima
Conference *Microlayering techniques for dyeing
Park 25/7, zirconia*
Dvorana 1

16:30-20:00 Ivica Anić
Conference *Kako endodontski zahvat postane
Park 25/7, lako izvediv i predvidljivog
Dvorana 2 uspjeha? ProTape Ultimate system
instrumentacije i punjenja kanala te
postendodonska opskrba*

Subota, 20. svibnja 2023.

DVORANA 2

09:00-12:00 David Geštakovski
Conference *Injekcijska tehnika*
Park 25/7,
Dvorana 1

09:00-13:00 Nazariy Mykhaylyuk
EDUCEN, *Digitalization*
Matulji

09:00-12:00 Dimitar Filtchev
Conference *The digital guide for achieving
Park 25/7, a predictable result in complex
Dvorana 2 rehabilitation*

15:45-18:45 Vladimir B. Stojiljković
Centar Gervais *Korekcija usana Art filerima*
Dvorana 2

16:30-19:30 Dejan Lisjak
Conference *Digitalni recepti*
Park 25/7,
Dvorana 1

16:30-19:30 Daniele Rondoni
EDUCEN, *441 system a new technical approach
Matulji using Zirconia Katana YML*

16:30-18:30 Siniša Drobnjak
Conference *Kako od najbolje plaćenog zaposlenika
Park 25/7, do vlasnika svoje ordinacije?*
Dvorana 2

PULP
PROPHYLAXIS
PREMOLARS
CHECK
DECAY
BRIDGE
CLEANING
BRACES
DENTAL
PREMOLAR
ENAMEL
HEALTH
CROWN
ORAL
PROFESSIONAL
ORTHODONTIST
TEETH
GINGIVITIS

DENTAL

EDUCATION

CROWN
CLEANING
ORTHODONTIST
CAD/CAM
X-RAYS
TEETH
VENEERS



CARE
ENAMEL
THIRD
DENTAL
COMPOSITES
MOLARS
BLEACHING
INCISORS
ABSCESS
EXOCAD

USMENA IZLAGANJA



WORN DENTITION? DIRECT AND INDIRECT ADHESIVE MANAGEMENT THROUGH A NON INVASIVE APPROACH

RICCARDO AMMANNATO

The main goal of this lecture is to provide, indications and protocols to diagnose and treat severe worn dentition through a new no prep hybrid and sustainable approach increasing the VDO. A direct workflow through "The Index technique", plus an indirect additive approach through partial indirect restorations in composite and/or ceramic, depending on the indications. All the step by step protocols will be addressed through images and videos in order to have a clear over view of this technique through an analog and digital workflow.

Biografija

Riccardo Ammannato graduated at Genoa University (Italy) in 1999. He has finished an internship at the Department of Operative and Restorative Dentistry, University of Zurich under the guidance of Prof. F. Lutz; studying adhesive dentistry and its applications in operative and prosthetic dentistry. He is an active Member of the European Academy Esthetic Dentistry (EAED) one of the most important and prestigious scientific academies worldwide. He is an active Member of the Italian Academy of Restorative AIC (Accademia Italiana di Odontoiatria Conservativa e Restaurativa) and the Italian Academy of Esthetic Dentistry (IAED). He is an author of articles on aesthetic adhesive and restorative dentistry and speaker in international courses and congresses. He currently practices at his office in Genoa, with multidisciplinary approach, but focusing on esthetics and restorative dentistry.

KAD JE REVIZIJA ENDODONTSKOG PUNJENJA PUT DO FUNKCIJSKO-ESTETSKE REHABILITACIJE ZUBA?

IVICA ANIĆ

U kliničkoj praksi broj uspješno izvedenih primarnih endodontskih zahvata je neprihvatljivo nizak. Posljedično, takvo stanje vodi do velikog broja neuspješnih funkcijsko-estetskih restauracija zuba u prednjem i stražnjem dijelu čeljusti. Za uspješnu endodontsku terapiju, osim znanja operatera, potrebna je i dobra tehnička opremljenost radnog mjesta. Ta potreba je još više izražena kada se mora napraviti revizija punjenja i ispraviti greške primarnog, neuspješnog zahvata. Greške se ne događaju samo na toj razini već i tijekom postendodontske opskrbe. Uporaba neprimjernih materijala ili kašnjenje sa zatvaranjem pristupnog kaviteta te infekcija punjenja, znatno komplicira i umanjuje mogućnost očuvanja zuba kao zasebne jedinice ili kao nosača većih (mostovi) ili manjih protetskih navlaka (kunice i ljuskice). Tijekom izlaganja prikazat će se brojni klinički primjeri kako donijeti odluku i kako postupiti da bi primarna endodoncija i/ili revizija punjenja mogle biti temelj funkcijsko-estetske rehabilitacije.

Biografija

Ivica Anić redoviti je profesor na Stomatološkom fakultetu Sveučilišta u Zagrebu. Objavio je preko 120 znanstvenih i stručnih radova, kongresnih priopćenja i nastavnih tekstova. Od toga, 72 rada je citirano u Current Contentsu. Glavni urednik je dva vodeća udžbenika iz karijesologije i endodoncije te koautor na jednoj knjizi o laserima u stomatologiji te tri udžbenika studija stomatologije u Hrvatskoj i BiH. Mentor je brojnih diplomskih radova te više magisterija i doktorata, te brojnih specijalizanata. Član je HLZ od 1984, aktivni je član i predstavnik zemlje pri European Society of Endodontology, od 1995. do 2002. Godine, predsjednik je Hrvatskog endodontskog društva, redoviti član Hrvatske akademije medicinskih znanosti od 1997. godine i International Association for Dental Research od 1995. godine. Predstojnik Zavoda „Endodoncija i restaurativna stomatologija“ i prodekan za znanost bio je od 2003. do 2009. godine.. Primarijus pri KBC Zagreb je postao 2005. godine.

Obnašao je funkciju pročelnika Zavoda za bolesti zubi, Klinike za stomatologiju KBC-a Zagreb od 2003. Do 2017. godine za koje vrijeme je bio nositelj programa specijalizacije iz endodoncije s restaurativnom stomatologijom. Osim endodoncije bavi se estetskom restaurativnom dentalnom medicinom, implantologijom i endodontskom kirurgijom.



BASIC AND ADVANCED REQUIREMENTS FOR RECONSTRUCTIVE PERI-IMPLANT THERAPY: MANAGING THE DIMENSIONS OF HARD AND SOFT TISSUES

SERHAT ASLAN

Nowadays, in the era of aesthetics, any treatment must be performed meticulously to maintain a natural tooth or provide successful replacement. Recent developments in the field of regeneration have enabled clinicians to perform minimally invasive, patient-friendly approaches.

Tooth retention procedures involving regenerative periodontal surgeries have been well documented over the last 20 years. Innovative techniques and sophisticated flap designs have improved the clinical outcomes and decreased patient morbidity.

However, extraction is inevitable in certain clinical conditions and then the best alternative for tooth replacement is dental implant placement. When natural dentition is combined with dental implants, treatment modalities become more complex due to anatomical differences. Optimal blood supply, gentle handling of the soft tissues, appropriate flap thickness, design and tension are key elements to achieve a successful surgical outcome. These factors deserve special attention during the surgical intervention. Despite fulfilling these critical requirements, soft and/or hard tissue deficiencies due to improper therapies or clinical conditions will create some difficult tasks for the clinician on the way to excellence. Appropriate surgical techniques bring not only the successful outcomes, but also ease proper prosthetic procedures. Therefore, healthy soft tissue interface and tooth-resembling emergence must be created by provisionalization and is of utmost importance when the aesthetic outcome is the primary concern.

In this presentation, critical elements and new perspectives of reconstructive peri-implant therapy will be discussed.

Biografija

Serhat Aslan, DDS, PhD is a graduate of Ege University, School of Dentistry, where he received his DDS degree. He attended the Periodontology Program of Graduate Study offered by the Institute of Health Sciences at Ege University and graduated with PhD degree in Periodontics. He maintains a private practice limited to periodontics, fixed prosthodontics, and implants, focusing on microsurgery, tissue regeneration, and minimally invasive surgery. Currently, he is the board member of the Turkish Society of Periodontology. Dr. Aslan is intensely involved in mono/multi-centre clinical research and development in periodontology, with special emphasis to plastic-periodontal surgery, guided bone/tissue regeneration and esthetic implant therapy.



NEW MATERIALS AND TECHNIQUES FOR IMPERCEPTIBLE RESTORATIONS: KEY POINTS TO ESTHETICS AND LONGEVITY

RAFAEL BEOLCHI

For many years, "Esthetics" in Operative Dentistry has been taught as something more artistic than scientific. Often, is left for many dentists the feeling that there's a lack of information, one that might help planning and executing cases with reliability, predictability and, why not, serenity. What this course proposes is to change the concept that Esthetics is purely artistic and empiric. Nowadays it is possible to work with emphasis in esthetic procedures in an ethical way, having in mind the patient's whole oral health, and having by our side predictability of results sustained by scientific evidence, always under the precepts of minimally invasive Dentistry. It is important to understand the patient's complaints, and also know what are the techniques and materials that we currently have available. Regarding any Esthetic rehabilitation, we must always focus on the Minimally Invasive Dentistry. For the dentist that aspire advanced esthetic procedures with dental composites, it is paramount to know deeply the properties of both composite and tooth; more specifically theirs mechanical and optical properties. From this knowledge depends not only the immediate behavior of the material, but also the reliability of a long-lasting restoration. Furthermore, only by knowing composites we will be able identify which materials would be able to reproduce even the smallest anatomical and optical details of the natural tooth.

Lecture Topics – Composites: which parameters are key for making imperceptible restorations – Understanding optical properties of both teeth and composites – Translucence and Opacity – taking your esthetic restorations to the next level. – A better approach for color selection – Perspectives on contemporary composites – Finishing and polishing: step-by-step for excellence – New technique for the placement of fast and predictable Direct Veneers: introducing the UVeneer – LED in dentistry: what is a proper curing

Learning Objectives – Master a new perspective for the placement of anterior composites – Discuss a different clinical approach to make color matching easy – Review changes in adhesion and lightcuring: new keys for short and long term success – Reduce clinical stress by improving case predictability – Learn how to simplify composite layering technique – Updates on techniques and materials for today's dentistry.

Biografija

Dr. Rafael Beolchi majored in Dentistry from the University of São Paulo, Brazil, in the year 2000. He has maintained a private practice since 2001, working mainly in aesthetic dentistry and oral rehabilitation. In 2009 he received his Master's degree on Biomaterials from the Institute of Energetic and Nuclear Research, from the same University. He teaches around the world, focusing on advanced handling of dental materials with an easy step-by-step approach that simplifies the procedure and has presented several lectures and workshops addressing those topics in North, Central & South America, Europe, Africa and Asia, in more than 50 countries. Dr. Beolchi is currently based in Portugal, where he is pursuing his second Master's degree, in Dental Medicine and acts as consultant for esthetic products and materials for the Dental industry, where he applies his clinical and scientific knowledge helping in the development of new and better dental products. He is the author of several articles in Portuguese, Spanish and English, about the topics of direct placed esthetic restorations and lightcuring, topics on which he still maintains his activity as a researcher until today. He also the author of book chapters on the same fields and collaborates on studies with several other Institutions around the world.



UMJETNOST SJEDINJENA U CIRKONU

MARIO BOSNAR

U današnje vrijeme itrijem stabiliziran cirkonijev oksid je često korišten materijal u stomatologiji posebno kada se saniraju distalni kvadranti zubnih lukova. Materijal pokazuje izvrsna mehanička svojstva te također ima sposobnost "transformiranja" malih pukotina unutar samog materijala, nastalih tijekom cikličkog naprezanja unutar strukture materijala. U anglosaksonskoj literaturi postoji izraz cirkon ili cirkonija što zamjenjuje generičko ime materijala, koji je na tržištu od 1990. godine kao proizvod švicarske tvrtke DCS. Od tada je započela dentalna evolucija ovog materijala, pomalo kontroverznog radi kohezivnih, adhezivnih i spojnih lomova. Ljepota konačnog rada, biokompatibilnost i biomimetičnost ipak prevladavaju kao imperativi u odabiru. Predavanjem će se obuhvatiti sve mogućnosti izrade konačnog rada kao i estetska rješenja u vidu internog i eksternog bojanja, cut-backa i mikro-slojevanja.

Biografija

MDT Mario Bosnar rođen u Samoboru 1971. godine. Od 1986 do 1990 pohađa Zdravstveno učilište u Zagrebu, nakon srednje škole, svoje daljnje školovanje i usavršavanje nastavlja u Njemačkoj gdje radi u raznim dentalnim laboratorijima: Dental laboratory De Polli, Dental practice Dr. Gleau, Dental laboratory Lukas, Dental practice Dr. Regensburger, Dental practice Dr. Schlaudraff 2006 godine završava školovanje i dobija titulu MDT 2009 godine vraća se u Hrvatsku i radi kao dent.tehničar u laboratoriju Naturaldent 2014 godine otvara vlastiti laboratorij Dental Studio Ceramic Art Uspješno se bavi edukacijama i obukom kolega KOL za Kuraray Noritake KOL za GC keramiku Instruktor za ICX implantate Jedan od glavnih fokusa su mu estetska rješenja i suvremeni materijali u dentalnom laboratoriju

TEMELJI OSMIJEHA – ŠTO NAS ČINI STVARNO LIJEPIMA?

ANDRIJA PETAR BOŠNJAK

Dobro je poznato da ljepota dolazi iznutra, ali čini se da je u posljednjih nekoliko godina vanjski izgled postao jedini ozbiljni element koji determinira nečiju ljepotu. U ovom predavanju pokušat ću skrenuti pažnju slušača na ono što je naoko nevidljivo, ali duboko je utkano u uspjeh svake opsežne oralne rehabilitacije, koliko god ona bila banalna, kompleksna ili rutinirana. Govorit ću o mikronutrijentima (vitaminima i mineralima) čija se uloga u homeostazi i zdravlju ljudskog organizma sve više naglašava, ali podaci o tome koliko su oni bitni za oralnu homeostazu tek se pojavljuju. Pokušat ću dati uvid u ulogu nekih mikronutrijenata u oralnom ekosistemu, ali i otkriti koji su potencijalni izvori mikronutrijenata korisnih za oralno zdravlje. Predstaviti ću nutrigenomiku, posebno područje medicine koje se bavi otkrivanjem kanala kojima polimorfizam nekih gena utječe na učinkovitost nutritivnog transporta i enzime koji mijenjaju vitamine kako bi se optimizirala njihova upotreba u metabolizmu. Na kraju ću prezentirati nekoliko slučajeva rehabilitacije koji su obuhvatili ne samo intervencije u usnoj šupljini, već i intervencije u stil života, stil prehrane i navike pojedinaca.

Biografija

Andrija Petar Bošnjak je glavni medicinski direktor Adria Dental Group koja ujedinjuje pet dentalnih klinika na području Republike Hrvatske. S više od 20 godina kliničkog iskustva na području parodontologije i dentalne implantologije i iskustvom nastavnika na nizu akademskih institucija na području Hrvatske i Bosne i Hercegovine, diplomirao je, magistrirao i doktorirao na Stomatološkom fakultetu Sveučilišta u Zagrebu. Objavio je preko 100 radova, od kojih je 28 citirano u najvišim kategorijama indeksacije. On je višestruki mentor diplomskih, magistarskih i doktorskih radova te je redovito aktivan kao recenzent u časopisima i projektima na međunarodnoj razini. Nedavno je završio edukaciju na području fitoaromaterapije, što je dodatno obogatilo njegov pristup kompleksnom problem postizanja parodontalnog, oralnog i općeg zdravlja pacijenata. Osim hrvatskog, tečno govori njemački, talijanski i engleski jezik, a komunicira i na francuskom i španjolskom.



MATERIALS FROM A DIGITAL PERSPECTIVE

AUGUST BRUGUERA

Our professional practice, much like everyday life, requires us to make decisions. We constantly come up against questions in need of answers. New developments in digital dentistry present us with many challenges, some of which we still don't have the answers to. However, there is no doubt that aesthetic dentistry continues to play an important role, and in this regard we need to continue offering satisfactory responses that meet our patients' expectations. Digitalization in the field of dentistry forces us to revise our previously developed protocols. My presentation aims to set out and evaluate all of the parameters related to restorative materials from a digital perspective. The materials may not have changed, but the way in which I perceive them most certainly has.

Biografija

Dental technician training specializing in dental prosthetics at the Ramón y Cajal School of Dental Technology in Barcelona, Spain (1983-1985). Further education in private dental laboratories in Germany (Klaus Muterthies), Italy (Mario Chiodini and Giovanni Furno) and Switzerland (Willi Geller). Honorary member of ACADEN (Asociación Científica para Defensa e Investigación de la Protesis Dental). Author of various specialist articles, which were published in Spanish and international magazines. Has held more than 500 lectures and workshops at national and international meetings and congresses in 43 countries. Member of the editorial board of "Dental Dialogue", Spanish issue. Member of the editorial board of the Brazilian magazine "Estética". Author of the textbook "Shades - a world of colours", which appeared in Spanish, English, German and Korean language. Published the textbook "Invisible, restauraciones cerámicas" together with Dr Sidney Kina, which appeared in Spanish, Portuguese, English, Italian and Japanese language. Between 1999 and 2002: worked at the University of Barcelona as a professor in the postgraduate program of Dr Tomas Escuin. 2003 "Bisturí de oro" award. Head of the dental lab and training centre "Laboratorio August Bruguera" based in Barcelona. Head of "Dental Excellence" Spain.



TEAM VISION & DIGITALNI PRISTUP U ESTETSKOJ DENTALNOJ MEDICINI

JOSIP BRUSIĆ

Team vision predstavlja osnovu sinergije u estetskoj dentalnoj medicini. Planiranje, brušenje, dizajn i gotov rad temeljne su sastavnice sinergije Team vision-a. Neraskidiva je veza ordinacije i laboratorija kroz komunikacijske kanale i faze izrade.

Biti će prikazani digitalni protokoli u ordinaciji dentalne medicine i u dentalnom laboratoriju koji se provode svakodnevno u praksi.

Što nam je potrebno za početak planiranja? Zamka uspjeha – 2D ili 3D planiranje? Koji su koraci sinergije? Koje radove možemo izraditi potpuno digitalnim pristupom?

Na ova i mnoga druga pitanja dobiti ćete odgovor tijekom predavanja uz prikaz slučajeva (naravno, niti jedan slučaj nije metal-keramika). Dio predavanja biti će rezerviran za planiranje brušenja i minimalno invazivno "brušenje by dr. Brusić" te laboratorijski protokol. Ukratko prikaz radova od ljuskice do full archa.

Biografija

Nakon završenog srednjoškolskog obrazovanja stječe diplomu dentalnog tehničara. Pohađao je studij dentalne medicine na Medicinskom fakultetu Sveučilišta u Rijeci, gdje je 1997. i diplomirao te stekao titulu doktora dentalne medicine. Nakon diplome odrađuje pripravnički staž u Domu zdravlja Rijeka. 1997. se zapošljava kao stručni suradnik za predmet Dentalna patologija na Katedri za dentalnu patologiju i dentalnu protetiku Medicinskog fakulteta Sveučilišta u Rijeci. Iste godine se zapošljava kao profesor dentalne grupe predmeta u Medicinskoj školi u Rijeci. Željan napredovanja u struci i produblivanja znanja iz dentalne medicine s ciljem poučavanja, 1997. upisuje dopunsko pedagoško psihološko obrazovanje na Filozofskom fakultetu u Rijeci i po završetku istog stječe zvanje profesora zdravstvenih predmeta. 2014. stječe izbor u zvanje profesor mentor. Dugi niz godina prenosi svoja znanja, vještine i kompetencije na mlađe generacije. Član je mnogih povjerenstava koji se bave razvojem kompetencija i nadgradnje znanja i vještina u dentalnoj medicini. Član je Hrvatske komore dentalne medicine pri kojoj aktivno sudjeluje. Od 2016. je zaposlen u Poliklinikama Rident. Interesne sfere daljnjeg usavršavanja su estetska dentalna medicina, protetika, kombinirani protetski radovi, implanto-protetika. Govori engleski i talijanski jezik.



NON-SURGICAL PERIODONTAL TREATMENT AROUND TEETH AND IMPLANTS

ALI ÇEKICI

Non-surgical periodontal treatment, also known as Phase I therapy or Initial periodontal therapy is one of the most important steps in the systematic structure of periodontal treatment approach. The philosophy behind this approach gives its potential for success in terms of resolution of periodontal inflammation and healthy periodontal tissues for longer periods. With our increased knowledge in periodontal disease pathogenesis and technological advances in our tools and devices, we have better and predictable treatment outcomes with non-surgical treatment alone.

When there's inflammatory disease symptoms around dental implants, the treatment strategies are also based on our knowledge from periodontal disease. Although it is a much challenging situation.

In this lecture, how to apply non-surgical periodontal treatment in clinical practice and the key to success will be discussed with clinical cases. The advances in our tools and devices that are used during the treatment will be overviewed.

Biografija

Assoc. Prof. Ali Çekici was born in Istanbul in 1977. He graduated from Istanbul University School of Dentistry in 2000. He received his PhD degree from Istanbul University School of Dentistry, Department of Periodontology in 2007. He has started working in the same department as a postdoctoral research fellow in 2007. He completed his two-year post-doctoral research at The Forsyth Institute in Boston, USA in 2012. He's got his tenure in 2014 and is still working as an Associate Professor at Istanbul University School of Dentistry Department of Periodontology.

He has been a board member of the Turkish Society of Periodontology since 2014, where he still serves as the general secretary. He has taken the role as the Ambassador for the EuroPerio 9 and EuroPerio10. He also serves as the EFP delegate of Turkish Society of Periodontology. He is a member of the Scientific Affairs Committee of the EFP.



5 THINGS YOU NEED TO KNOW TO BE SUCCESSFUL WITH GUIDED SURGERY

KRZYSZTOF "KRIS" CHMIELEWSKI

Guided surgery in dental treatment is more and more often recommended as a tool that increases the precision and safety of the implantation procedure.

Technology can be a great complement to the knowledge and skills of the implantologist. Success and precision, however, are highly dependent on understanding the technology and its limitations.

In the lecture, I will present the five most relevant elements that must be remembered in order for the results to be in line with expectations.

I will discuss topics related to immediate implants in the aesthetic zone, and full-arch solutions with immediate loading.

Biografija

Krzysztof Chmielewski is an international speaker in the field of implantology and bone regeneration, esthetic treatment and dental photography. He also works as a freelance photographer and filmmaker, and was involved in projects for Discovery Channel.

Kris graduated from the Medical Academy in Gdansk in 1993. He worked from 1993 to 1994 as an assistant at the Prosthetic Department of the same institution. Since 1996 he is maintaining a private dental clinic focusing on aesthetic and implantology. From 2010 to 2014 he served as the president of the Polish Academy of Esthetic Dentistry, a society of which he is also a co-founder. He is a graduate of Dr. J. Kois Centre in Seattle. He obtained his MSc degree in oral implantology from Frankfurt University. He is also a visiting lecturer at the W. Goethe University in Frankfurt in the Curriculum of Implantology and Master of Science in Oral Implantology Program. He is an ITI Fellow. He is the educational director in the Dental Photo Master online platform. He regularly presents webinars for DentalTown (USA) and DTStudyClubs platforms.



SAME DAY DIGITAL INDIRECT RESTORATIONS: PREPARATION TO CEMENTATION

ERHAN ÇÖMLEKOĞLU

Chairside single-unit indirect restoration philosophy is the game changer for dentistry. Subtractive and additive manufacturing techniques may be preferred. Recently, due to rapid progress in technology, there is a huge demand through additive manufacturing technology for permanent restorations in the dental market. In the theoretical part of the presentation digital workflow for chairside restorations, preparation principles, fundamentals of 3D-printing technology, digital occlusion and articulation for design and cementation options will be described. During the workshop all participants will scan prepared teeth and check the occlusion of the immediately 3D printed permanent restorations. A dental technician will make the digital design of the crowns during the course and the digital articulation process will be discussed on the restoration designs.

Biografija

Erhan Çömlekoğlu is a graduate of Ege University, School of Dentistry where he received his DDS degree. He attended Prosthesis Program of Graduate Study offered by Institute of Health Sciences at Ege University and graduated with Ph.D. degree at Prosthodontics. He is a Professor and resident at the Department of Prosthodontics, School of Dentistry at Ege University, İzmir, Turkey.

He completed several scientific projects supported by national and international institutions. He was honoured more than 30 national and international scientific awards. With these projects he authored more than 70 articles in peer-reviewed scientific journals in the field of adhesive and implant dentistry and established CAD/CAM restorative laboratory at the dental school.

His clinical practice is limited to Prosthodontics at the Department of Prosthodontics, School of Dentistry, Ege University. Dr. Çömlekoğlu is intensely involved in scientific research regarding adhesive dentistry and implant dentistry. His current research interest particularly covers implant-periodontium interactions and their clinical outcomes.



GNATOLOGIJA - TEMELJ SVIH PROTETSKIH REHABILITACIJA

FRANCESCO DITOMMASO

Uspostavljanje pravilnog odnosa između gornje i donje čeljusti, odnosa zuba u okluziji i artikulaciji jedan je od najzahtjevnijih koraka u svakoj protetskoj terapiji. Predavanje sadrži prikaze slučaja potpunih rekonstrukcija solo krunama (litij disilikat) kod različitih pacijenata. Timski prikaz slučajeva s gledišta zubnog tehničara i terapeuta koji obuhvaća važnost korištenja obraznog luka, individualne udlage, pravilnog podizanja vertikalne dimenzije te svi postupci od planiranja do završnog rada kroz prikaz laboratorijskih i kliničkih faza rada.

Biografija

Francesco Ditommaso is a dental technician born in Santeramo in Colle (Bari) on 24 September 1976. He graduated in 1995, at the I.P.S.I.A. "L.Santarella" Institute in Bari. From 1995 to 2004 he worked in a laboratory in Santeramo in Colle dealing with mobile, fixed and combined prostheses. In 2004 he opened his laboratory "Elleddi Odontotecnica" in Santeramo in Colle, in co-ownership with his partner. He was an ordinary member of AIOP (Italian academy of prosthetic dentistry), since 2016 general member of ESCD (European Society of Cosmetic Dentistry), in 2018 he became a certified member of ESCD, in 2021 he is appointed member of the commission for ESCD certifications, active as organizer and speaker of courses, study clubs and conferences in Italy and abroad. In 2011 he attended the annual multidisciplinary course of "Italian Dental Tech Academy" in Brindisi where he learned from well-known names such as Lanfranco Santocchi (shape and layering), Claudio Nannini (aesthetics and function), Enrico Steger (zirconia), Alberto Olivieri (mobile prosthesis), Sergio Strega (metallurgy), Michel Magne (aesthetics). He continuously invests in his knowledge attending the courses and conferences in various fields in Italy and abroad: . metal-ceramic, . metal-free, . dental morphology, . mobile prosthesis, . combined prosthesis, . implant prosthesis, . layered composite and reverse layering technique, . gnathological and sports bite Meeting and attending events and courses with Claudio Nannini, Dr. Monica Casadei, Dr. Dario D'Alessio and Dr. Nazzareno Bassetti contributed to develop a strong interest in the study of gnathology, at individual and medium values, of Prof. Rudolf Slavicek philosophy. In 2019 he was awarded for poster presentation in aesthetics and function in full mouth rehabilitation at Christmas congress in Zagreb.



BIOMEHANIKA DENTALNIH LJUSKICA

BORIS FILIPOVIĆ

Biomehanika je znanost o mehaničkim principima živih organizama, prije svega kretanja i strukture. Kombinira principe biologije, fizike i inženjeringa kako bi objasnila internu strukturu, funkciju i interakciju bioloških modela. Jedan ključni aspekt biomehanike dentalnih ljusaka je koncept okluzije, koji je uz pravilno dijagnosticiranje stanja temporomandibularnog zgloba te detektiranje eventualnih parafunkcijskih kretnji, ključan moment za postavu indikacije za izradu visoko estetskih nadomjestaka ove vrste. Pravilna okluzija ključna je za održavanje zdravlja zuba i desni te za sprječavanje problema poput trošenja zuba, osjetljivosti zuba i boli u čeljusnim zglobovima. Drugi važan aspekt biomehanike ljuskica je koncept pripreme zuba, koji se odnosi na način na koji je zub oblikovan prije postavljanja ljuskice. Pravilna priprema zuba ključna je kako bi se osiguralo učinkovito cementiranje za zub te za održavanje zdravlja zuba i okolnog tkiva. Ukratko, biomehanika pomaže u pripremi i postavi ljuskica na minimalno invazivan način koji neće oštetiti zube ili desni, analizom sila koje djeluju tijekom funkcije te adekvatnim dizajnom dentalnih ljusaka. Uz pravilnu pripremu zuba i održavanje pravilne okluzije i artikulacije moguće je dugoročno zadovoljiti visoke estetske prohtjeve pred kojima se susrećemo.

Biografija

Boris Filipović završio je Stomatološki fakultetu Sveučilišta u Zagrebu. Fokusiran na funkciju i estetiku, iskustvo je kroz godine stjecao u konzervativnoj stomatologiji, ortodontiji, protetici, implantologiji te radom u dentalnim laboratorijima. Angažmanima u eminentnim hrvatskim poliklinikama usavršio se za fiksno protetska estetska rješenja. Suradnja sa domaćim i inozemnim stručnjacima rezultirala je radom na visoko estetskim rješenjima kompleksnih implantološko-protetskih slučajeva te unaprjeđenjem poznatih metoda za imedijatno opterećenje implantata. Od 2016. radi u ordinacijama na specijaliziranim za implantoprotetiku a od 2019. kao predavač za protetska rješenja na implantološkim sustavima tvrtke ZimVie. Uz navedeno, radi kao specijalizant na Zavodu za stomatološku protetiku Stomatološkog fakulteta Sveučilišta u Zagrebu. Osim kroz radionice i predavanja u regiji, svoje vještine demonstrira i u sklopu ZimVie Instituta u Winterthuru, Švicarska.



LECTURE TITLE: PROSTHETIC GUIDED IMPLANTOLOGY – HOW THE DIGITAL WORKFLOW CHANGES OUR DAILY LIVES

DIMITAR FILTCHEV

The lecture will go through a different treatment planning protocol – a new way of digital planning. A full guided digital protocol for implant placement will be presented with a new biological concept of creating and keeping a stabile emergence profile.

Thin soft tissues lead to increased marginal bone loss compared to thick soft tissues, at implants. A new prosthetic way of increasing the biotope will be introduced to increase the soft tissue level around teeth and implants. A reliable full digital protocol for prosthetic rehabilitation will be discussed.

Topics

- Digital diagnostics and treatment planning
- Full guided digital protocol for implant placement
- Creating a stabile soft tissue profile
- Digital impressions
- CAD/CAM solutions
- Different prosthetic treatment options

Biografija

Dr. Dimitar Filtchev obtained his degree in Dental Medicine from the Faculty of Dental Medicine in Sofia, in 1998. In 2000 he was appointed Assistant Professor at the Department of Prosthetic Dentistry at the same Faculty and from 2022 is elected as a Professor at the same department. In 2003 he acquired a postgraduate specialization in Prosthetic Dentistry. In 2013 he presented his thesis and got a PhD degree. From 2007-2015 is a President of the Sofia Dental Meeting Association. Co-founder of the Implant Dental Center at the Medical University in Sofia. Specialization in Prosthodontics, Faculty of Dentistry – Munster, Germany. Participated at trainings in Prosthodontics with N.Bichacho, M.Fradeani, in Implantology-H.Salama, in Perio- A.Saadoun, M.Hurzeller, G.Zucchelli. Honorary Member of Style Italiano Group, the Bulgarian Society of Esthetic Dentistry, Bulgarian Scientific Dental Association, Affiliate of the EAED, Instructor at the Zimmer Institute Switzerland. Since 1998 he has been running a successful practice in Sofia, focused on Implantology, Esthetic and Digital Dentistry and Orthodontics. Dr. Filtchev has more than 80 publications in scientific journals, many scientific presentations, numerous participations as an keynote speaker at national and international congresses.



THE SECRET BEHIND THE PERFECT MATCH – BIOMIC STAIN

MITSUTAKA FUKUSHIMA

The lecture will focus on answering the following questions: How to use the biomic stains for the perfect match? How many times firing stains for the perfect match? How to choose the zirconia block?

Biografija

Mitsutaka Fukushima, dental technician is a world renowned ceramist from Japan. Mitsu has been working in ceramics for over 20 years in the specialty of color matching. Using internal stain techniques, his unique approach allows him to make ceramics with colours very close to natural teeth. For his first ever trip to Dubai, Mitsu is offering 15 dental technicians the exclusive opportunity to learn these skills from the master himself. He is a MPF KOL in Japan, official instructor of Aidite and Initial zr-fs worldwide colour matching trainer.

DIGITALNI ALATI U IMPLANTOPROTETSKOJ REHABILITACIJI

IGOR GALIĆ

Razvojem digitalnih tehnologija sve je veća i njihova primjena u dentalnoj medicini. Njihova preciznoat i pouzdanost izvrstan su partner prilikom rješavanja problema s kojima se susrećemo u izazovima implanto protetske rehabilitacije u estetskoj zoni. U predavanju će se govoriti o korištenju coDiganostiX-a softvera za planiranje i pozicioniranje implantata u skladu sa protetskim planom teraapije; kao i korištenje intraoralnog skenera i 3D printera.

Ključ je naravno na poštivanju protokola i timskom pristupu gdje ovi digitalni alati olakšavaju međusobnu komunikaciju između ordinacije i dentalnog laboratorija.

Biografija

Igor Galić, dent. teh. nakon završene Zubotehničke škole i obavljenog pripravničkog staža radno iskustvo stječe u više privatnih laboratorija u Virovitici i Zagrebu. Od 2006. godine otvara privatnu praksu u Zagrebu. Dodatno obrazovanje i tečajeve iz struke pohađa u zemlji i inozemstvu, od koji BEGO Academia Dental-Master level. Službeni OPL za BEGO® Semados implantate. Autor je jednog poglavlja i stručni suradnik na knjizi prof. Kraljevića „Djelomične proteze“. Objavljuje nekoliko stručnih članaka. Od 2007. – 2019. godine kao predavač sudjelovao je na više tečajeva stručnog usavršavanja za dentalne tehničare u organizaciji HKDM. Službeni je instruktor za Straumann® Dental Implant System i Straumann® LAB ACADEMY. Službeni je stručni suradnik za Ivoclar Digital. Aktivan je kroz raznovrsne radne tečajeve u Hrvatskoj i inozemstvu.



INJEKCIJSKA TEHNIKA – MOŽEMO LI OSTVARITI POLIKROMATSKI IZGLED

DAVID GEŠTAKOVSKI

Injekcijska tehnika je indirektno direktna metoda izrade kompozitnih ljuski. Navoštani model koristi se za izradu transparentnog silikonskog ključa prema kojem će se ljuske izraditi direktno u ustima. Za tu svrhu koristi se nova generacija tekućih kompozita s ojačanim mehaničkim i estetskim svojstvima. Osim sjajne površine i pravilne morfologije, odabir određene nijanse i polikromatski izgled restauracije utječe na završni estetski rezultat. U predavanju će biti objašnjeni određeni koncepti kojima se može stvoriti i simulirati polikromatski izgled ljusaka te nekoliko tehnika kojima kliničar može kombinirati različite nijanse kompozitnog materijala.

Biografija

Diplomirao je na Stomatološkom fakultetu, Sveučilište u Zagrebu. Dobitnik je dekanovih i rektorovih nagrada za uspjeh tijekom studija. Tijekom fakulteta boravio je na stranim sveučilištima (EVP), u Bratislavi (2015.), Valenciji (2016.), Stockholmu (2017.) i Strasbourgu (2018.). Osnivač je edukacijske platforme „Injectable technique by David Geštakovski“ u sklopu koje organizira online predavanja i hands-on tečajeve o injekcijskoj tehnici. Kao gostujući predavač sudjeluje na međunarodnim kongresima i edukacijskim centrima diljem svijeta. Autor je objava u Quintessence International (QI) i International Journal of Esthetic Dentistry (IJED). Član je HDEDM-a (Hrvatsko društvo estetske dentalne medicine). Radio je u Dublinu, Irskoj (3Dental), a trenutno je zaposlen u Ordinaciji Geštakovski (Zagreb, Croatia). GC je key-opinion leader.

COMPLEX CASES IN DENTAL PROSTHETICS – HOW SIMPLIFICATION LEADS TO HIGHER QUALITY

JAN-FREDERIK GÜTH

Dentistry and the entire community of dental professionals are becoming increasingly complex. In order not to lose the overview and to have enough time for the essentials, namely our patients, it makes sense to standardize i.e. simplify, individual areas of the daily routine. In no way is it a matter of generalizing procedures. On the contrary, it is a matter of making patient-specific individual therapy decisions with standardized processes with the aim of quality and predictability to meet the expectations of our rightly demanding patients. On the basis of complex clinical cases, such as implant-supported crown and bridges and other rehabilitations, this lecture will illustrate the described approach with a focus on the processes of material selection, provisionals, impression taking and cementation.

Biografija

Jan-Frederik Güth holds the position of Deputy Director of the Department of Prosthodontics at the University Hospital of the Ludwig-Maximilians University Munich. He obtained his Dr. med. dent. Degree in 2008 and his postdoctoral lecture qualification (“Habilitation”) in 2014 from the same University. In 2013 he was a visiting researcher at the University of Southern California (with Pascal Magne) and is specialized in the field of Prosthodontics (DGPro, the German Association of Prosthodontics) and Implantology (especially Implant Prosthetics; DGI). His main field of attention and research are digital impression technology and workflows, CAD/CAM, esthetics and prosthetic materials.



HOW TO STAND OUT OFFERING ADDITIONAL AESTHETIC PROCEDURES AND GROW YOUR PRACTICE?

TOMAŽ IVANUŠIČ

High power Er:YAG and Nd:YAG lasers can be used in different clinical situations including aesthetics. We will cover techniques for establishing red-white dental aesthetics like crown lengthening, gingivectomy, gingival depigmentation, bleaching, etc. Er:YAG laser can be also used for removal of full-ceramic restorations without need to cut them. Demand for aesthetic procedures are rising and more and more patients are interested in non-invasive facial rejuvenation, lips plumping and snoring reduction so we will also cover those indications.

Biografija

Dr Tomaž Ivanušič graduated from the University of Ljubljana's Faculty of Medicine in Slovenia in 2017. After graduation, he served a one-year internship, where he gained experience in different dental specialties. Already as a student, he actively participated in international congresses and events. In 2018, he was chosen to join a group of 16 prospective young dentists who attended an advanced course in aesthetic dentistry in Lisbon in Portugal. Dr Ivanušič currently practises in his private clinic in Slovenia, mostly performing endodontic, restorative and prosthodontic treatment with special focus on laser and aesthetic dentistry. He also work part-time as a researcher, lecturer and trainer.

DIGITAL WORKFLOW-HUMAN PERFORMANCE HIGH END RESTORATIONS AS CONCEPT IN BIG LABS?

HANS-JÜRGEN JOIT

From a vision to the first step. How to configure modern sequencing in daily work? Showing cases of different range, master dental technician Hans Joit will illustrate his way of communication among dentist, patient and dental technician. What are the patient's needs and how to save needless labor? Single reconstruction or large construction side - Each restoration is to be planned and converted precise in view of durability and appearance. Prearrangement and choice of materials, especially for all-ceramic cases are more important than ever today. A special focus will be put on the reproducibility of process chains. Especially in bigger lab structures defined results can be achieved by less experienced technicians using digital prototypes. Finally, one thing is like it always has been: The quality level of a dental treatment is still defined by manual skills and knowledge.

Key learning points:

- Choosing the right opacity and value for your restoration
- Controlling and matching volume color
- The workflow from start to result
- Ceramic layering extracts

Biografija

Hans-Jürgen Joit, VITA Master Dental Technician, was born in 1966 in Duesseldorf, Germany. In 1988 he obtained his dental technician apprenticeship certification, and in 2001 a master's degree. He worked in various dental labs until 2002, when he opened his own Dental lab Linie Duesseldorf Dental. In 2018 he entered in a partnership with Dental lab Zahntechnik Duesseldorf. Since 2005 referent and opinion leader for Elephant Dental, Degudent and Dentsplysirona. He is an international speaker and holds courses worldwide. He has published numerous publications in different dental magazines.



DIGITALNA TEHNOLOGIJA: UČINKOVIT ALAT ILI FANCY IGRAČKA

ZORAN KOVAČ

Glavni cilj uvođenja digitalnih tehnologija je povećati učinkovitost dentalne rehabilitacije pacijenata razvojem i implementacijom kompleksa digitalnog planiranja početnih faza liječenja, uključujući dijagnostičke metode, modeliranje i izradu prototipova protetskih nadomjestaka korištenjem moderne računalne tehnologije.

Od digitalne radiografije do digitalno printanja, od kompjuteriziranih prezentacija slučaja do CAD/CAM restauracija izrađenih u ordinaciji, i od digitalno temeljenih "kirurških vodiča" i 3D navigacije za postavljanje implantata do digitalnih otisaka, tehnologija mijenja lice stomatologije i, u nekim slučajevima, njegove kliničke ishode. Konzultacije i suradnja u timu mogu se provoditi brže i možda uz detaljnije i neposrednije informacije nego ikad prije. Štoviše, takav timski rad nije ograničen geografskim granicama.

Troškovi kupnje tehnologije mogu se isprva činiti velikim, ali ono što je danas vrhunski napredak moglo bi se sutra smatrati očekivanim standardom skrbi. Spremnost da se prihvati nova tehnologija može pomoći stomatološkim ordinacijama u njihovoj potrazi za uspjehom.

Predavanje će obuhvatiti razvoj digitalne tehnologije te kako je integrirati u postojeće protokole i specifičnosti svake pojedine ordinacije dentalne medicine.

Biografija

Zoran Kovač izvanredni je profesor na Katedri za stomatološku protetiku Fakulteta dentalne medicine Sveučilišta u Rijeci. Specijalist je stomatološke protetike. Osim u akademskom okruženju, prof. Kovač redovito predaje na domaćim i inozemnim stručnim i znanstvenim skupovima. Ko-autor je sveučilišnog udžbenika Dentalna implantologija (2021.) Autor je brojnih znanstvenih i stručnih članaka objavljenih u prestižnim časopisima. Član je HDDI, HSD, ITI i HKDM-a.

DENTAL LABORATORY PROCEDURES IN FIXED IMPLANTOLOGY

LEON LAZIĆ

I will show you the current, mostly digital, everyday workflow we have in our lab for implant restorations. Attention to precision, morphology and biologically correct restorations will be emphasised. I am hoping to give you at least one trick that will make your future prosthetic work better.

My goal is:

- teach you about emergence profiles and how to shape them
- teach you about tooth morphology and its influence on implant longevity
- give you a step by step protocol of our workflow
- warn you about what not to do, so you can avoid some major problems in
- everyday work

Biografija

2019 June- Finished middle school for dental technicians SŠFKZ in Slovenia. 2019 October- Cooperated in my first published article: Precision Comparison of Intraoral Scanning and Extraoral Scanning of Plaster Models Obtained with Impressions Taken with Different Impression Materials; Pelivan Ivica, Lazić Leon, Lazić Andrej 2021 July- Started employment at Zobotehnični Laboratorij Lazić Andrej 2022 November- Started study in University of Ljubljana, Health Sciences; dental prosthetics Held lecture in Skopje, Macedonia about Emergence profiles in laboratory.



PREDVIDLJIVA ESTETIKA

MATEJ LUK

Kako doći do visokoestetskog rješenja, pri izradi protetskih nadomjestaka, te predvidjeti estetiku i prije početka terapije. Koristenjem software-a, fotografijama i komunikacijom između ordinacije, laboratorija i pacijenta, predvidjeti konačan estetski rezultat.

Biografija

U Zagrebu, 2009. god. završava Školu za dentalne tehničare. Nakon stečenog iskustva u nekoliko laboratorija, 2013. god. otvara vlastiti laboratorij, DentalLab Matej Luk, koji je specijaliziran za fiksno-protetske estetske radove kao i slučajeve na implatatima, poput All-on-4 koncepta. Cijeli radni staž se dodatno usavršava na raznim tečajevima i kongresima u svijetu, kod predavača kao što su Shigeo Kataoka, Oliver Brix, Gerald Ubassy, Robert Zubak...

IMPLANT PLACEMENT AND LOADING IN THE ESTHETIC ZONE – SURGICAL CONSIDERATIONS

ALEKSA MARKOVIĆ

Implant placement in the esthetic zone is a complex procedure and requires a prosthetically-guided approach. The importance of prosthetic planning in the esthetic zone and communication between oral surgeons, prosthodontist and dental technicians are extremely important. Esthetic region is a zone in which there is often a conflict between patient expectations and objective opportunities. For this reason, the clinician must make important decisions about correct 3D implant positioning, the appropriate type of implant placement time, as well as the loading protocol. Immediate loading is certainly a special challenge in the aesthetic zone. The desire of patients for short treatment time can often be an aggravating circumstance in avoiding risk factors. Clinicians are often faced with the problem of implant placement into a narrow alveolar ridge in the esthetic zone. To overcome such challenging situations the use of augmentation procedures is recommended. It is frequently performed using particulate graft with guided bone regeneration or block graft augmentation. If sufficient primary implant stability and correct 3D implant position could be achieved, implants can be placed simultaneously, otherwise a two-phase approach is indicated. This lecture will show protocols necessary for adequate treatment planning, time of implant placement and loading in the esthetic zone as well as adopt skills for recommended augmentation procedures and implant placement through either a simultaneous or a staged approach that will provide a successful esthetic and functional outcome in their everyday clinical practice.

Biografija

Profesor oralne kirurgije, implantologije i stomatološke anesteziologije, Stomatološkog fakulteta, Univerziteta u Beogradu. Direktor ITI Centra Beograd i ITI Study Club Beograd. Gostujući profesor na Univerzitetu Mursija (Španija) i Sarajevu (BiH) Član je sekcije za oralnu kirurgiju i sekcije za oralnu implantologiju Srpskog liječničkog društva. Predsjednik je Sekcije za oralnu implantologiju Srpskog liječničkog društva. ITI Fellow. Autor je i koautor 50 originalnih istraživačkih radova objavljenih u domaćim i međunarodnim časopisima (29 radova objavljenih u CC časopisima) te 145 istraživačkih radova predstavljenih na domaćim i međunarodnim kongresima. Autor je i koautor 3 knjige za osnovne studije i 3 monografije.



THE ART OF LAYERING

SABINE MAYER

Nature shows us everything we need to know to create a natural restoration. In order to achieve lifelike morphology, surface, shape and color, it is very important to consciously observe, study and imitate natural teeth. Contrasts with opal and effect materials used correctly, playing with the colors and bold details then produce the desired result. Nature is our best teacher.

Course content:

In a Powerpoint, the speaker presents her workflow, her philosophy and cases of everyday laboratory work.

In the subsequent workshop:

An anterior tooth individually with dentin, effect, and opal materials, layered on a zircon framework and a monolithic anterior tooth painted with stains.

Only opal materials are used for the layered crown, as these come closest to the natural tooth enamel.

Step by step towards a morphologically correct crown shape, inspired by nature through individual processing of shape and surface.

Surface finish by hand polishing.

Biografija

Sabine Mayer is a dental technician focusing on ceramics. She had previously worked in dental laboratories in Austria and since October 2020 is working in the ACCADENT Dental Lab in Koblenz, Germany. She has had extensive training and education with world-renowned dental technicians in areas of dental ceramics and dental photography. She has published papers in Quintessenz and Dental Dialog. She is a KOL for Dentsply Sirona and a member of Atelier Dentaire International. She speaks and gives courses internationally.

3 MAGIC INGREDIENTS OF PERFECT COLOR MATCHING

RYO MIWA

The focus of this masterclass will be put on achieving a predictable lab workflow, step-by-step. As such, the learning objectives of this masterclass will be:

- 1-how to make realistic lab models;
- 2-how to take pictures with a gray card;
- 3-easy and predictable way of digital try in.

Keywords: mistakes and how to solve them; protocols; fluorescent; metamerism; digital color measuring

Biografija

Graduated in 2000 from the School of Dental Technology in Cracow, Poland. From 2000 to 2005 he was employed in DU Laboratory at the framework department in Warsaw. From 2005 to 2007 he was employed in Techdent at the ceramic department in Warsaw. From 2002 he works as an instructor and opinion leader of GC products (mainly ceramic). He has opened and is owning the Dental Laboratory Ceramist Ryo in Warsaw since 2007. Since 2013 he's been organizing the Congress Ceramists No Limits in Poland biannually. In 2009 he won 1st place at the KSTD (Polish Society of D) in the category metal free ceramic works.



DIGITALIZATION | CLINICAL PERFORMANCE

NAZARIY MYKHAYLYUK

Throughout the years proper protocols were created by top world specialists. Then, microscopes and other magnification systems were introduced into a daily practice, and now it is difficult to imagine dentistry without them. Everything seemed completed. But no... Modern dentistry moves one. We are going digital.

MAIN TOPICS: • Patient's first visit. Proper communication. • Photo/video documentation. • Digital dentistry. Scanning strategies. • Face scanning as powerful tool. • 3D design of future smile in lab. • 3D printing technologies. • Mock-up transfer. Demo for patient. • Micro invasive preparation for crowns and veneers. • Importance of magnification. Loupes and microscopes. • Fabrication of provisional restorations. • Final restorations design. • Milling machines. • 3D staining techniques. • Importance of isolation. • Bonding protocol. • Final documentation.

Biografija

Nazariy Mykhaylyuk is a specialist in the field of microscopic and digital dentistry. Works in Kyiv and Ivano-Frankivsk, Ukraine in family clinics in a team with his father and dental technician Bogdan Mykhaylyuk (M.Vision Lab-Oral Design Ukraine) and sister. Dr. Mykhaylyuk first started organising courses in 2010, after creating M.Vision Academy, and has since taught on the topics of "Tooth preparation with a microscope for full crowns", "Photo and video documentation in dentistry. Microscopic approach", "Total rehabilitation from A to Z" and "Indirect restoration - from macro to micro. MicroVision approach". He has developed preparazion kits and hand instruments in collaboration with Komet and Deppeler. He is a DentalXP expert. He has given more than 300 presentation in over 60 countries worldwide.



GNATOLOGIJA - TEMELJ SVIH PROTETSKIH REHABILITACIJA

VERENA NIŽIĆ

Uspostavljanje pravilnog odnosa između gornje i donje čeljusti, odnosa zuba u okluziji i artikulaciji jedan je od najzahtjevnijih koraka u svakoj protetskoj terapiji. Predavanje sadrži prikaze slučaja potpunih rekonstrukcija solo krunama (litij disilikat) kod različitih pacijenata. Timski prikaz slučajeva s gledišta zubnog tehničara i terapeuta koji obuhvaća važnost korištenja obraznog luka, individualne udlage, pravilnog podizanja vertikalne dimenzije te svi postupci od planiranja do završnog rada kroz prikaz laboratorijskih i kliničkih faza rada.

Biografija

Verena Nižić, dr.med.dent. završava srednju Medicinsku školu u Rijeci, smjer dentalni tehničar 1995. godine. Diplomirala je na Studiju dentalne medicine na Medicinskom fakultetu u Rijeci 2001. godine. Suvlasnica je Dental CORE ordinacije dentalne medicine, te Dental Core Education centra za edukaciju. Uže polje interesa su joj estetska dentalna medicina, dentalna protetika i implanto-protetika. Od 2015. godine je ESCD (European Society of Cosmetic Dentistry) Chairperson za Hrvatsku te je član više domaćih i međunarodnih udruženja : certificirani član ESCD, AIOP (Academia Italiana di Odontoiatria Protetica), HDEDM (Hrvatsko društvo estetske dentalne medicine) kao i HKDM (Hrvatske komore dentalne medicine). Autorica je više stručnih radova iz područja dentalne protetike kao i nagrađivanih poster prezentacija iz implanto-protetike i estetske dentalne medicine. Redovito se educira na domaćim i međunarodnim kongresima i skupovima, na kojima i sama često predaje. 2016. godine osvaja nagradu HDEDM za najboljeg doktora estetske dentalne medicine u Hrvatskoj. 2017. godine osvaja nagradu ESCD-a za značajni doprinos organizaciji kongresa tog društva. Od 2018. godine postaje CCC (Country Chairperson Coordinator) pri ESCD-u te se tako pridružuje užem odboru ESCD-a.

MINIMALLY INVASIVE SMILE ENHANCEMENT USING BIOMETRICS - COMPOSITE VS. CERAMIC - DIGITAL APPROACH

DARIO NOVAK

Using the digital protocol in the smile design process has become increasingly important in modern dentistry. In this lecture, we will explore how digital technology has revolutionized the use of composite and ceramic veneers in smile design, focusing on the "smilecloud" program. We can now accurately previsualize the final restoration using dental photography and digital tools, allowing for more precise and efficient treatment planning. By discussing the benefits of both materials, this lecture will provide dentists with valuable insights into the latest advances in smile design. Join us as we explore the exciting possibilities of digital protocol in modern minimally-invasive dentistry.

Biografija

Diplomirao na Stomatološkom fakultetu Sveučilišta u Zagrebu 2016. godine. Već kao student pokazao je interes za istraživaču aktivnost te je dobitnik Rektorove nagrade za individualne znanstvene i umjetničke zasluge za svoj rad o učestalosti neželjenih kožnih reakcija na lateks. Nakon završenog staža u Zagrebu, pridružio se Denum timu gdje radi kao specijalist za dizajn osmijeha s minimalno invazivnim pristupom. Osnivač je obrazovne platforme coronadentis.com koja nudi online i live predavanja te praktične tečajeve za stomatologe u Europi. Aktivno predaje na temu minimalno invazivnog pristupa „smile designa“ i dentalne protetike. Član je Hrvatske komore dentalne medicine. Aktivni je član Hrvatskog društva za estetsku dentalnu medicinu. KOL je i međunarodni predavač za DMG, Hamburg.



SMJERNICE ZA KORIŠTENJE DRUŠTVENIH MREŽA TE POTICANJE RAZVOJA E-PROFESIONALIZMA DOKTORA MEDICINE I DOKTORA DENTALNE MEDICINE

DANKO RELIĆ

Društvene mreže mogu se definirati kao online mediji i sučelja osmišljena za povezivanje ljudi te olakšavanje interakcije i razmjene sadržaja među njima. Njihova važna specifičnost je stvaranje osobnih profila kojima se lakše ograničava vidljivost i dostupnost dijeljenih informacija. Razvoj društvenih mreža utječe na sve aspekte društva u cjelini, a zdravstveni djelatnici i zdravstvene institucije nisu izuzetak.

Društvene mreže mogu se koristiti u osobne i profesionalne svrhe. Funkcioniraju po modelu dvosmjerne komunikacije te su vrlo dostupne, neformalne i javne. Potrebno je pretpostaviti da je sadržaj objavljen na društvenim mrežama u javnoj domeni i dostupan svima, bez obzira na postavke privatnosti – jednom kada se informacija objavi na internetu, vrlo teško ju je u potpunosti ukloniti.

Rezultati istraživanja ukazuju na vrlo jasnu potrebu kontinuiranog praćenja i istraživanja društvenih mreža u nastajanju te kreiranju i ažuriranju smjernica. Nadalje, potrebno je poduzimanje određenih obrazovnih intervencija imajući u vidu specifičnosti svake zdravstvene profesije, a s obzirom na različit potencijal korištenja društvenih mreža.

Smjernice su vrlo korisne kao upute u novim neistraženim područjima te područjima koja se vrlo dinamično mijenjaju, a društvene mreže upravo su takve. Smjernice su namijenjene savjetovanju i educiranju, a koriste se za preveniranje pogrešaka ili se mogu koristiti nakon što je pogreška učinjena u njihovom ispravljanju ili promišljanju. Zdravstveni djelatnici bi trebali prepoznati utjecaj i potencijal društvenih mreža te razmotriti kako ublažiti moguće rizike. Ove su smjernice izrađene kako bi educirale zdravstvene djelatnike te pružile okvir za donošenje odluka o optimalnom korištenju društvenih mreža za osobne i profesionalne svrhe.

Smjernice su strukturirane u obliku izjava koje predlažu ili preporučuju specifično profesionalno ponašanje zdravstvenih djelatnika na društvenim mrežama. Namjera im je olakšati kontinuirani sustavni razvoj zdravstvene profesije te pomoći pri pružanju najkvalitetnije moguće skrbi.

Biografija

Rođen u Slavanskom Brodu gdje završava osnovnu školu „Ivan Goran Kovačić“ te klasičnu gimnaziju fra Marijana Lanosovića. Od 2006. do 2012. g. studirao je na Medicinskom fakultetu Sveučilišta u Zagrebu – dobitnik je posebne Dekanove i Rektorove nagrade.

Od 2013. do 2014. g. pripravnički staž odrađivao je za Dom zdravlja Zagreb – Zapad nakon čega polaže stručni ispit za doktore medicine. Od 2014. g. do 2015. g. radi kao liječnik opće medicine u Domu zdravlja Zagreb – Centar. 2015. g. izabran je u suradničko zvanje asistenta u Katedri za medicinsku statistiku, epidemiologiju i medicinsku informatiku Medicinskog fakulteta Sveučilišta u Zagrebu te sudjeluje u izvođenju nastave preddiplomskih, diplomskih i poslijediplomskih studija.

Na poslijediplomskom doktorskom studiju „Biomedicina i zdravstvo“ Medicinskog fakulteta Sveučilišta u Zagrebu doktorirao je 2021.g. na temu „Razvoj modela za planiranje specijalističkog usavršavanja doktora medicine u Republici Hrvatskoj“. Potom biva izabran u suradničko zvanje višeg asistenta u ranije spomenutoj Katedri.

Autor je i koautor brojnih stručnih i znanstvenih radova – <https://www.bib.irb.hr/profile/39282>. Član je istraživačkog tima uspostavnog projekta Hrvatske zaklade za znanost (HRZZ UIP-2017-05-2140) „Opasnosti i prednosti društvenih mreža: e-profesionalizam zdravstvenih djelatnika; SMePROF projekt“.

Od 2015. g. predstojnik je Centra za planiranje zanimanja u biomedicini i zdravstvu Medicinskog fakulteta Sveučilišta u Zagrebu. Aktivno sudjeluje u radu Centra za zdravstvenu djelatnost Medicinskog fakulteta Sveučilišta u Zagrebu. 2023.g. polaganjem specijalističkog ispita postaje specijalist obiteljske medicine.

Inicijator je obnavljanja Hrvatskog društva mladih liječnika Hrvatskog liječničkog zbora u kojem je obnašao dužnost predsjednika te je jedan od osnivača Udruge narodnog zdravlja „Andrija Štampar“. Organizator je brojnih domaćih i međunarodnih simpozija i konferencija. Dobitnik je povelje Hrvatske liječničke komore za brigu o ugledu liječničkog staleža.

Aktualni je član Europskog gospodarskog i socijalnog odbora, savjetodavnog tijela institucija Europske unije, iz Republike Hrvatske.



PERIORESTORATIVE TREATMENT(S): ACHIEVING OPTIMAL TISSUE HEALTH AND AESTHETICS

GABRIELLA ROMANO

It may often be the case that in endeavouring to obtain perfect clinical results, the aesthetics of periodontal treatment may be of secondary importance. Nevertheless, an optimal integration of restoration work and periodontal tissues is a key factor in achieving best possible tissue health and aesthetics. We will look at how adopting a biologically integrated approach within the most favourable treatment and surgical timeframes will allow us to achieve greater clinical success.

Biografija

She was born in Casarano in 1979, she graduated with honors in Dentistry and Dental Prosthetics at the University of Bari. She has participated as a speaker at several international scientific congresses and Masters. Active member of the Italian Academy of Conservative and Restorative Dentistry and Italian Academy of Esthetic Dentistry. Master Member of the Adhestetics study group of dr. Federico Ferraris. She works as a freelancer in her studies in Galatina and Casarano, dealing exclusively with restorative and aesthetic dentistry and periodontology. Incoming General Secretary of the Italian Academy of Conservative and Restorative Dentistry



HOW TO INCREASE YOUR AESTHETIC SOLUTIONS AND MAKE YOUR PATIENTS HAPPY, WITH NEW GENERATION ZIRCONIA IN COMBINATION OF DIGITAL TECHNOLOGY

DANIELE RONDONI

During the first part it will analyzed the difference and the property of the new generation zirconia with a dedicated accuracy and finalization. Moreover the speaker will show you a new approach that will help you in a very easy way to create predictable aesthetics in producing dental restorations. Additionally it will be show how we can improve our skills and efficiency with a ideal digital work flow.

Biografija

Born in Savona in 1961, he has always lived and worked in his home town. A talented student at "P. Gaslini" Dental School in Genoa, in 1981, upon request of Prof. Derchi, he helped laying the basis for the first Savona-based dental school and one year later he started his own dental lab. The second turning point in his career is in 1988, after an inspiring experience at Master Oliviero Turillazzi's clinic in Brescia. Further remarkable professional experiences soon followed, in Switzerland, Germany and in Japan too, at the side of Hitoshi Aoshima, one of the world's most recognized masters in odontology. Always focused on morphology and dental aesthetics, Daniele Rondoni has constantly been committed to the development of new generation materials, combining traditional analogical approach and latest digital technologies. A consultant for Dr. Jules Allemand and Micerium dental company since 1993, in 1994 he joined EAED, the European Academy of Esthetic Dentistry, becoming an Affiliate Member first and then an Active Member, respectively in 2005 and 2007. In 2013 he was invited to participate as an official lecturer at the 27th Annual Meeting of the Academy held in Crete. He has authored a number of articles published on the most renowned dental magazines and journals. In 1997, his book "Tecnica della Multistratificazione in Ceramica" (Ceramic Multilayering Technique) was published by Italian leading scientific editor UTET, and in his "Handbook for the use of composite materials" - providing useful protocols for both composite indirect and press techniques on metal frameworks and implants -, the "TENDER - inverse hardness layering system" he has invented is exhaustively illustrated. Some of the cases he treated have been published in the volume "Il restauro anteriore conservativo dei denti anteriori" by L. Vanini, F. Mangani, O. Klimovscaja (Conservative anterior restoration of anterior teeth - Ed. E. Masson). Other cases, treated at Dr. Devoto's dental clinic, have been published in "Odontoiatria restaurativa: procedure di trattamento e prospettive future" (Restoration dentistry: treatment procedures and perspectives - Ed. E. Masson). He has also participated in "LAYERS, un atlante sulla stratificazione della resina composita" by J. Manauta - A. Salat (Layers, an atlas on composite resin layering - Ed. Quintessenza). Deeply devoted to teaching, he is the mind behind the AAT Community College, a project to support education and professional training in odontology. Since 2011 he has acted as International Instructor for Kuraray Europe Dental Inc., the European branch of the renowned Japanese dental company, and in 2014 he founded NISC, the Noritake Italian Study Club, always in collaboration with Kuraray Europe. An associate professor of Restorative Odontology at the University of Chieti-Pescara and a Member of the Teaching Staff at the "Endodontics and Restorative Odontology" Master Course at the University of Siena, he is also an associate member, lecturer and cultural advisor of SICED, the Brescia-based Italian School of Dental Ceramic.



NON PREP 25 YEARS – OVER 7000 UNITS

JAN SCHÜNEMANN

Topic number one at the moment are the techniques of minimally invasive veneers, not least because these techniques lead to a positive end result relatively quickly and easily. Here, the planning is one of the crucial points to define the patient's wishes exactly. The advantage of a mock-up allows us to visualise the expected result for the patient in advance. We create measurable values and thus a plannable result. We can look back to 25 years experience with more than 7000 elements. The most important key of success is the bonding protocol. We will share our strategy step by step. But there are also many other areas in dentistry where procedures have been established that are also minimally invasive. But to what extent can these also be planned or calculated? How does the bone develop after augmentation? How much loss can be expected? Due to the experiences since the beginning of implantology, the strategies have changed constantly and new insights are constantly being added. A deep understanding of biology is key to the success of any dental treatment. Minimally Inverse Dentistry, when this application was defined, has: "a systematic respect for the original fabric." A thorough understanding of the biology and respect for the tissue work in synergy to minimise patient trauma and ultimately our treatment steps. Treatment concepts that formerly involved massive surgical interventions can generally be implemented today with reduced interventions. The advantages of guided surgical planning and its execution in different treatment scenarios; Flap formation, miniflap access, immediate extractions and minimally invasive bone grafting procedures are explained.

Biografija

Educated as dental technician from 1979 – 1983 in Hamburg; Examination for the grade of master, April 22nd, 1992 in Munster, NRW. Working as practical technician for one year Working in commercial laboratories in Bielefeld from 1985–1988 Self-employed since 1989 in Bielefeld; Journalist for "Quintessenz der Zahntechnik"; Advisory function, Product development, Marketing concepts, Product photography (Dental, Food, Lifestyle), Presentations; Foundation of an institution for further education in 1988; National and international lectures; External consultant in Germany, Italy, Poland, Hungary, England, Benelux, Bosnia, USA, Canada, Russia, Sweden, Norway, Denmark and South Africa Numerous publications; Inventor of FB Analyzer, Tribos V-shade, Denture Art, Carrara Paint



TIME AND TECHNOLOGY- KEY SUCCES FACTORS IN NON SURGICAL SOFT TISSUE MANAGEMENT AROUND IMPLANTS IN THE ESTHETIC ZONE

ANGIE SEGATTO

Living in an "instant" World can creates the illusion that you can get everything faster. But biology doesn't work like this illusion. One of the most critical and sensitive procedures in our profession is recreating the natural look of the soft tissues around the implants in the esthetic zone. Modern technology gives us all that we need to successfully achieve the best result. Using them the right way and respecting all rules is one of the key success factors. But this is not enough. The other key element is TIME. That's what we must respect the most. Non compromise success is guaranteed if we can connect time and technology in a most optimal way.

Biografija

Angie Segatto, restorative specialist graduated from Semmelweis University in 2001. From the very first moment she has been devoted to non-compromised esthetics and was extremely motivated in doing natural restorations on a high level. After two specializations in dentistry she became assistant professor at Szeged University in 2009. Nowadays she practices in her private clinic, being involved in post-graduate programs only. In 2018 and 2022 she attended The Buser & Belser Master Course in Esthetic Implant Dentistry. Her main area of interest is front esthetics in difficult cases. In 2022 she joined the MIS Academy as a lecturer in this specific topic.



RIJETKI-BIJELI-LIJEPI

DAVOR SEIFERT

Riječ estetika potječe iz staro grčkog jezika „aistanomai“ gledam, opažam te znači umijeće zapažanja. U univerzalnoj uporabi estetika se kao naziv pojavljuje tek s A.G. Baumgartnerom godine 1735., koji u svom djelu „Filozofske meditacije“ spominje estetiku kao novu znanost o „osjetilnoj spoznaji“. Od tada pa sve do današnjih dana navedena definicija vrijedi kao važan dio medicine i dentalne medicine u svakodnevnoj praksi. U današnje vrijeme estetika postaje ultimativni zahtjev. Pacijenti žele ostati mladi i lijepi, a u tome im pomažu lijepi, bijeli, pravilno postavljeni i zdravi zubi. Prvi estetski nadomjesci u dentalnoj protetici bile su fasetirane krunice, a zatim nakon niza godina nastavlja se metal-keramičkim krunicama. Razvojem tehnologije materijala razvijala se i drugačija tehnologija koja je dovela do potpuno keramičkih sustava. Estetska svojstva, prvenstveno optička, koja posjeduje keramika čine ju nenadmašnim materijalom za nadomjestke. Upravo ta svojstva današnje keramike i način svezivanja sa zubnim tkivima, omogućili su estetske korekcije zuba.

Biografija

Davor Seifert rođen je 15. studenog 1955. godine u Zagrebu. Nakon završenog visokoškolskog obrazovanja na Stomatološkom fakultetu, od 1982. godine radi u nekoliko javnozdravstvenih i privatnih stomatoloških institucija. 1997. godine izabran je u naslovno zvanje višeg znanstvenog asistenta na Zavodu za Fiksnu protetiku Stomatološkog fakulteta Sveučilišta u Zagrebu. 2001. – 2007. godine izabran je u naslovno zvanje Docenta na Zavodu za Stomatološku protetiku Stomatološkog fakulteta u Zagrebu te je sudjelovao u nastavi kolegija „Fiksna protetika“. Od 2004. do 2008. godine suosnivač je i suvoditelj, a do 2010. suradnik u nastavi poslijediplomskog kolegija Športska stomatologija, pri Stomatološkom fakultetu Sveučilišta u Zagrebu. 2009. godine priznat mu je naslov Primarijus odlukom povjerenstva Ministarstva zdravstva Republike Hrvatske. 2010. godine izabran je u znanstveno zvanje znanstvenog suradnika. 2010. godine – izabran u naslovno zvanje Docenta pri Studiju dentalne medicine Medicinskog fakulteta Sveučilišta u Splitu. Od 2012. do 2023. godine voditelj je kolegija Gnatologija pri Studiju dentalne medicine Medicinskog fakulteta Sveučilišta u Splitu. 2016. godine izabran je u znanstveno zvanje Viši znanstveni suradnik, Matični odbor za područje biomedicine i zdravstva, znanstveno područje/polje: biomedicina i zdravstvo/dentalna medicina. 2016. godine zaposlen je u znanstveno-nastavnom zvanju Docenta na Fakultetu za Dentalnu medicinu i zdravstvo Sveučilišta J.J. Strossmayera u Osijeku. 2019. godine postaje predstojnik Katedre za Dentalnu medicinu na Fakultetu za Dentalnu medicinu i zdravstvo Sveučilišta J.J. Strossmayera u Osijeku. 2021. godine izabran je u znanstveno-nastavno zvanje Izvanrednog profesora na Fakultetu za Dentalnu medicinu i zdravstvo Sveučilišta J.J. Strossmayera u Osijeku.

U prvom sazivu skupštine Hrvatske stomatološke komore bio je vijećnik i rizničar, te član Izvršnog odbora. Osim aktivnog sudjelovanja na međunarodnim znanstvenim i stručnim skupovima u zemlji i inozemstvu što je vidljivo iz objavljenih radova poglavito kongresnih priopćenja, pasivno je sudjelovao na kongresima Svjetske stomatološke udruge (FDI) u Orlando, SAD 1996., Barceloni, Španjolska 1998., Mexico City, Mexico 1999., Paris, Francuska 2000., Šenzen, Kina 2006., te Stockholmu, Švedska 2008. godine.

Objavio je preko stotinu znanstvenih i stručnih radova, te kongresnih priopćenja, od kojih su neki s CC i SCI prepoznatljivošću.



DIGITALNI ALATI U IMPLANTOPROTETSKOJ REHABILITACIJI

IGOR SMOJVER

Razvojem digitalnih tehnologija sve je veća i njihova primjena u dentalnoj medicini. Njihova preciznost i pouzdanost izvrstan su partner prilikom rješavanja problema s kojima se susrećemo u izazovima implantoprotetske rehabilitacije u estetskoj zoni. U predavanju će se govoriti o korištenju coDiganostiX-a softvera za planiranje i pozicioniranje implantata u skladu sa protetskim planom terapije; kao i korištenje intraoralnog skenera i 3D printera.

Ključ je naravno na poštivanju protokola i timskom pristupu gdje ovi digitalni alati olakšavaju međusobnu komunikaciju između ordinacije i dentalnog laboratorija.

Biografija

Igor Smojver, dr.med.dent., specijalist oralne kirurgije završio je Stomatološki fakultet Sveučilišta u Zagrebu 2009. godine. Za vrijeme studija bio je demonstrator na Zavodu za endodonciju i restorativnu stomatologiju te volonter na Zavodu za oralnu kirurgiju. Specijalističko usavršavanje obavio je na Klinici za oralnu kirurgiju KBC Zagreb te položio specijalistički ispit 2016. Poslijediplomski doktorski studij dentalne medicine u Zagrebu upisao je 2017. godine, pod mentorstvom prof.dr.sc. Dragane Gabrić iz polja dentalne implantologije. Posebno je educiran iz polja parodontne plastične kirurgije te modernih tehnika augmentacija na Hurzeler/Zuhr Akademiji u Muenchenu. Autor je i koautor 12 znanstvenih radova od čega 6 u CC bazi podataka, 39 poster prezentacija na međunarodnim kongresima te 1 poglavlje u knjizi. Redovito sudjeluje na tečajevima stručnog usavršavanja u zemlji i inozemstvu, povremeno i kao predavač. Član je Hrvatske komore dentalne medicine (HKDM), Hrvatsko liječničkom zbora (HLZ), Hrvatskog društva za oralnu kirurgiju (HDOK), Hrvatskog društva za dentalnu implantologiju (HDDI). U svakodnevnom radu poseban naglasak stavlja na mikrokirurške operativne tehnike, zahvate na mekim tkivima i implantoprotetske rehabilitacije u estetskoj zoni dok je u znanstvenom radu fokusiran na istraživanje prevencije i liječenja periimplantitisa.



AESTHETICS: SYNTHESIS THROUGH DIFFERENT RESTORATIVE MATERIALS

DIMITRIOS SPAGOPOULOS

In an ERA of different treatment options every clinician creates his own treatment plan individualized for the patient. To restore the aesthetic zone in the older days we only had some specific options. Different cases that include crowns, implants, veneers will be presented as well as the necessary steps to achieve harmony in the anterior region.

Biografija

He graduated from the dental school of the Athens University in 2012 as a doctor of dental surgery, and has continued working there as a clinical assistant. In 2013 he was admitted to the postgraduate programme at the operative department of the same university. Since July 2022 he is a Phd candidate at the University of Athens, focusing on intraoral scanners and their features.

During the postgraduate program he won (2015, 2016) the first prize in Heraeus Kulzer's award regarding the best class IV restoration for two consecutive years and the first prize in ICDAS II caries diagnosis (2015). Since 2015 he is part of the PERIOCARE GOUMENOS, a dental clinic with an practicing aesthetic dentistry, prosthodontics, restorative dentistry and implants. Additionally, he owns his private dental clinic focusing in the same fields of dentistry.

He has published numerous papers in Greek and international scientific journals and has participated in Greek and international conferences as a speaker. He also serves as an editorial team member of Dentorama and Dental journal magazines (Omnipress).

He is one of the Key Opinion Leaders for HU-FRIEDY and a member of the European Academy of Esthetic Dentistry (EAED), European Osteointegration Academy (EAO), Hellenic society of Odontostomatologic research and Hellenic academy of esthetic dentistry (HAED).

MODERN ALL-CERAMIC PROSTHODONTICS: STATE OF THE ART OF TOOTH AND IMPLANT SUPPORTED RECONSTRUCTIONS

FRANK SPITZNAGEL

Today, dentists and dental technicians face the challenge to select the appropriate all-ceramic material for fixed tooth and implant prosthetics. Bi-layer or monolithic materials? Glass ceramics or zirconia restorations? Modern digital technologies facilitate not only the manufacturing process, but can also lead to increased efficiency and effectiveness with allceramic reconstructions. In this lecture, modern all-ceramic materials for fixed tooth and implant-supported reconstructions will be discussed and scientifically highlighted on the basis of clinical cases. Moreover, this lecture will give an overview of current systems, manufacturing processes and will provide guidelines for clinicians.

Biografija

Završio je studij Studij stomatologije Sveučilišta Albert-Ludwigs u Freiburgu 2014. godine. 2015. postaje doktor asistent i znanstveni asistent, pri Klinici za stomatološku protetiku (ravnatelj: prof. dr. h.c. Jörg Strub), Sveučilište Albert-Ludwigs, Freiburg. Od 2016. do danas radi kao doktor asistent i znanstveni asistent Poliklinike za stomatološku protetiku (ravnateljica klinike: prof. dr. sc. Petra Gierthmühlen), Sveučilište Heinrich Heine, Düsseldorf. 2018. godine postaje certificiran od DGI-ja u području implantologije i kvalifikacija specijalista implantologije. Glavna područja rada i klinički fokus: potpunokeramički sustavi i minimalno invazivni oblici preparacije, digitalni CAD/CAM tijekom rada u restaurativnoj stomatologiji i implantologiji, estetska stomatologija i adhezivne tehnologije.



DIGITALNI ALATI U IMPLANTOPROTETSKOJ REHABILITACIJI

LUKA STOJIĆ

Razvojem digitalnih tehnologija sve je veća i njihova primjena u dentalnoj medicini. Njihova preciznost i pouzdanost izvrstan su partner prilikom rješavanja problema s kojima se susrećemo u izazovima implantoprotetske rehabilitacije u estetskoj zoni. U predavanju će se govoriti o korištenju coDiagnostiX-a softvera za planiranje i pozicioniranje implantata u skladu sa protetskim planom terapije; kao i korištenje intraoralnog skenera i 3D printera. Ključ je naravno na poštivanju protokola i timskom pristupu gdje ovi digitalni alati olakšavaju međusobnu komunikaciju između ordinacije i dentalnog laboratorija.

Biografija

Dr. Luka Stojić rođen je 1978. godine u Zagrebu. Diplomirao je 2003.god. te specijalizirao stomatološku protetiku 2018.god. Trenutno pohađa poslijediplomski doktorski studij na Stomatološkom fakultetu u Zagrebu. Aktivan je član Hrvatske komore dentalne medicine i ITI-a (International team for implantology). Nakon stjecanja višegodišnjeg iskustva u kliničkom radu i vođenju privatne prakse, postao je jedan od osnivača renomirane zagrebačke dentalne klinike DentA Centar.

Predavač i ključni suradnik za renomirani implantološki sustav Straumann od 2019.g. od kada redovito održava tečajeve i predavanja iz područja implantoprotetske rehabilitacije.

Stručnjak je u radu i planiranju sa dijagnostičkim coDiagnostiX software-om.

Primaran fokus njegova rada je postizanje maksimalne funkcionalnosti i prirodnog izgleda zubi te primjena digitalne tehnologije u implantoprotetskoj rehabilitaciji.

KOREKCIJA DONJE TREĆINE LICA ART FILERIMA

VLADIMIR B. STOJILJKOVIĆ

Donja trećina lica predstavlja dio lica koji, uz sljepoočnice, sudjeluju u stvaranju njegove konture. Ova činjenica odavno je prepoznata: u „trokutu mladosti“, pored jagodica koje predstavljaju temelj lica, treći vrh ovog trokuta čini brada. Također, donja trećina lica trpi značajne posljedice tijekom procesa starenja, od resorpcije kosti i duboke masti, do promjena na mišićima, kako elevatora, tako i depresora. Korekcija može biti kirurška i minimalno invazivna, i svaka nosi svoje prednosti i nedostatke. Pored toga, istaknuta je primarna uloga usana u emocionalnoj ekspresiji i atraktivnosti cijelog lica. Kroz seriju kliničkih slučajeva prikazan je sistem rejuvenacije baziran na korekciji uzroka s ciljem zadržavanja što prirodnijeg izgleda pacijenta, uz preporuke kako to učiniti na siguran način.

Biografija

Mr sc. med. dr Vladimir B. Stojiljković je priznati plastični kirurg koji svoj klinički i istraživački rad posvećuje estetskoj kirurgiji lica i tijela, razvijajući vlastite tehnike uz primjenu najsuvremenijih materijala. Pionir je u oblasti regenerativne kirurgije na našim prostorima i poznat je po edukacijama koje drži kolegama plastičnim kirurzima, dermatolozima, stomatolozima, a iz oblasti minimalno invazivnih procedura na licu, kao i po tome što je uveo BRAVA metodu kod nas kojom se grudi povećavaju prirodnim putem, vlastitom mašću.

Kada govorimo o njegovom radu sa pacijentima, fokusiran je na lice i tijelo, estetiku, uklanjanje znakova starenja na licu i usporavanje procesa starenja. Fokusiran je na primjenu minimalno invazivnih procedura na licu, insistirajući na poznavanju kirurške anatomije lica i promjenama tokom procesa starenja.

Dr Vladimir Stojiljković je objavio više od 20 radova iz oblasti estetske, rekonstruktivne kirurgije i opekotina, dobitnik je Stipendije Ministarstva odbrane SR Jugoslavije (1996-1998) i Stipendije grada Niša za talente (1996-1998). Učestvovao je na čuvenim kongresima u zemlji i inostranstvu, kao gost i kao predavač.



FAILING IMPLANTS – TREATMENT OPTIONS

MARKUS TRÖLTZSCH

Oral implantology has become a very safe and predictable procedure. Although implant placement and augmentative procedures are routine procedure nowadays, many pitfalls can adversely affect long term satisfaction of the patient and the surgeon. Today the dentist's challenge is to select the appropriate technique and material for the given task while the options and the medical challenges grow constantly. The literature and nowadays social media boast high success rates and satisfied patients but reality sometimes offers a different picture.

This presentation will focus on implant failures of various origin and give an insight into repair and rehabilitation protocols.

Attendees will learn:

- How to assess a patient in order to choose the correct technique and material for the given case
- Reasons and prevention strategies for complications in implant – and augmentation surgery
- How to remove and restore implants that cannot be saved

Biografija

Markus Tröltzsch completed his dental training and received his DMD degree in 2005 from the Dental School at the University of Erlangen in Nuremberg, Germany. In 2010, Dr. Troeltzsch completed his medical education at the University of Erlangen, Nuremberg Medical School, and received his MD degree. Dr. Troeltzsch continued his dental studies in 2008 and 2009, specializing in restorative and esthetic Dentistry (Curriculum DGÄZ). First, he spent six months in the Department of Surgery at the University of Sydney in Australia. Then he proceeded to the Department of Maxillofacial Surgery at the University of Zurich in Switzerland. Afterward, he performed his residency at the University Clinics in Bochum (Germany) and Göttingen (Germany), where he passed the board exam for maxillofacial surgery. As a result, Dr. Troeltzsch was appointed as consultant and senior physician for maxillofacial surgery at the University of Göttingen in January 2016. In September 2016, he moved on and maintained a private office for dentistry and oral and maxillofacial surgery in Ansbach, Bavaria, Germany, and directs the Department for oral and maxillofacial surgery at the Hospital of Ansbach, Bavaria, Germany. In November 2016, he was elected as the director of the APW, the Academy for continuous postgraduate education of the German dental association, and was reelected in November 2020. He lectures and publishes internationally and nationally on various topics, especially about up-to-date procedures of methods of augmentation of the jaws, implants and the various aspects of medicine in dentistry. He is the main author of the augmentation guidelines paper of the Consensus conference of the German Society of Implantology (DGI) and the head editor of a The comprehensive textbook "Medicine for dentists" was published in the Fall of 2020. He is a member of several prestigious German and international professional and scientific organizations, including EACMF, ESCD, DGI, and others.

STACKABLE GUIDE

MATEJ VIDIĆ

Koncept "stackable guide" nam pruža predvidljivost, preciznost i dovoljno prostora za nepredvidljive situacije bilo da se radi o bezuboj ili ozubljennoj čeljusti. Koristeći Exocad paletu programa prezentirat će se planiranje implantata u Exoplanu, provizorij izraden u Exocadu uz Smile creator modul te PartialCad za izradu različitih komponenti "stackable guidea". Izrada šablona za fiksaciju, implantiranje, nivelaciju kosti te provizorija sve u naprijed pripremljeno samo sa osnovnim informacijama CBCT, scan/otisak i portret fotografija. U doba kada je vrijeme svima pa tako i pacijentima od velike važnosti, možemo iskoristiti digitalni način rada za brz i učinkovit rezultat.

Biografija

Završio je srednju zubotehničku školu u Rijeci 2009. godine. Do 2019. radio je u privatnim dentalnim laboratorijima u Rijeci. 2019. otvara vlastiti dentalni laboratorij. Radio je kao CAD Software demonstrator/ trener. Demonstrator je za Kulzer i certificirani Exocad trener (level 3). Posvećen je kontinuiranom vlastitom obrazovanju u Hrvatskoj i inozemstvu.

PULP
PROPHYLAXIS
PREMOLARS
CHECK
CLEANING
DENTIN
TEETH
DENTAL
PREMOLAR
PROPHYLAXIS
ENAMEL
HEALTH
BRACES
DECAY
BRIDGE
ORTHODONTIST
TEETH
GINGIVITIS
CROWN
ORAL
PROFESSIONAL

DENTAL

EDUCATION

CROWN
CLEANING
ORTHODONTIST
CAD/CAM
X-RAYS
TEETH
VENEERS



CARE
ENAMEL
THIRD
DENTAL
COMPOSITES
MOLARS
BLEACHING
INCISORS
ABSCESS
EXOCAD

RADIONICE



KAKO ENDODONTSKI ZAHVAT POSTANE LAKO IZVEDIV I PREDVIDLJIVOG USPJEHA? PROTAPPE ULTIMATE SYSTEM INSTRUMENTACIJE I PUNJENJA KANALA TE POSTENDODONTSKA OPSKRBA

IVICA ANIĆ

Radni tečaj obuhvaća predavanje o novoj, ProTaper Ultimate tehnici instrumentacije korijenskog kanala. Detaljno će se objasniti konstrukcija i način uporabe instrumenata te ProTape tehnike punjenja kanala. Prikazat će se materijali te tehnike izvođenja postendodontske opskrbe korijena i zuba kao pripreme za protetsku nadgradnju. Nakon teoretskog dijela, svaki polaznik će napraviti, na plastičnom modelu, strojnu instrumentaciju i punjenje kanala. Nakon toga će na plastičnim modelima postaviti kompozitni kolčić te napraviti nadogranju kompozitnim "Core" materijalom" tehnikom monobloka.

Biografija

Ivica Anić redoviti je profesor na Stomatološkom fakultetu Sveučilišta u Zagrebu. Objavio je preko 120 znanstvenih i stručnih radova, kongresnih priopćenja i nastavnih tekstova. Od toga, 72 rada je citirano u Current Contentsu. Glavni urednik je dva vodeća udžbenika iz karijesologije i endodoncije te koautor na jednoj knjizi o laserima u stomatologiji te tri udžbenika studija stomatologije u Hrvatskoj i BiH. Mentor je brojnih diplomskih radova te više magisterija i doktorata, te brojnih specijalizanata. Član je HLZ od 1984, aktivni je član i predstavnik zemlje pri European Society of Endodontology, od 1995. do 2002. Godine, predsjednik je Hrvatskog endodontskog društva, redoviti član Hrvatske akademije medicinskih znanosti od 1997. godine i International Association for Dental Research od 1995. godine. Predstojnik Zavoda „Endodoncija i restaurativna stomatologija“ i prodekan za znanost bio je od 2003. do 2009. godine.. Primarijus pri KBC Zagreb je postao 2005. godine.

Obnašao je funkciju pročelnika Zavoda za bolesti zubi, Klinike za stomatologiju KBC-a Zagreb od 2003. Do 2017. godine za koje vrijeme je bio nositelj programa specijalizacije iz endodoncije s restaurativnom stomatologijom. Osim endodoncije bavi se estetskom restaurativnom dentalnom medicinom, implantologijom i endodontskom kirurgijom.



PERIODONTAL AND PERI-IMPLANT TISSUE RECONSTRUCTION: FUNDAMENTALS OF MICROSURGICAL TISSUE HANDLING, PRIMARY WOUND CLOSURE AND BIOMATERIAL MANAGEMENT

SERHAT ASLAN

Developments in the microsurgery have led to an era of invisible dentistry. Technical improvements and advancement in biomaterials facilitate to augment the deficient sites. Despite these developments, the rules of the biology remain the same. Blood supply, handling of the soft tissues, flap thickness, design and tension are key elements to achieve optimal surgical outcome. These factors should be critically evaluated and controlled by clinician. In this training module, participants will receive the core of modern periodontal treatment concepts for periodontal and peri-implant tissue reconstruction.

Learning objectives are:

- To obtain primary wound closure using microsurgical principles (basic and advanced suturing techniques, elimination of flap tension)
- To prepare split- and full-thickness flaps
- To trim and tack a barrier membrane for ridge augmentation

The participants will have an opportunity to work with a variety of (bio)materials: a bone substitute material, collagen membranes, a collagen matrix, a non-resorbable membrane and a titan pin set.

Biografija

Serhat Aslan, DDS, PhD is a graduate of Ege University, School of Dentistry, where he received his DDS degree. He attended the Periodontology Program of Graduate Study offered by the Institute of Health Sciences at Ege University and graduated with PhD degree in Periodontics. He maintains a private practice limited to periodontics, fixed prosthodontics, and implants, focusing on microsurgery, tissue regeneration, and minimally invasive surgery. Currently, he is the board member of the Turkish Society of Periodontology. Dr. Aslan is intensely involved in mono/multi-centre clinical research and development in periodontology, with special emphasis to plastic-periodontal surgery, guided bone/tissue regeneration and esthetic implant therapy.



SAME DAY DIGITAL INDIRECT RESTORATIONS: PREPARATION TO CEMENTATION

ERHAN ÇÖMLEKOĞLU

Chairside single-unit indirect restoration philosophy is the game changer for dentistry. Subtractive and additive manufacturing techniques may be preferred. Recently, due to rapid progress in technology, there is a huge demand through additive manufacturing technology for permanent restorations in the dental market. In the theoretical part of the presentation digital workflow for chairside restorations, preparation principles, fundamentals of 3D-printing technology, digital occlusion and articulation for design and cementation options will be described. During the workshop all participants will scan prepared teeth and check the occlusion of the immediately 3D printed permanent restorations. A dental technician will make the digital design of the crowns during the course and the digital articulation process will be discussed on the restoration designs.

09.00–09.45 Theoretical part

Digital workflow for new kind of permanent restorations: Scan & Make it designed & Print Limits & possibilities with printable resins.

09.45–10.00 Demonstration

Intraoral scanning protocol for 3D print cases (Instructor demonstration)

10.00–10.30 Hands-on

Scanning of the prepared tooth on the models

10.30–10.45 Coffee break

10.45–11.30 Tooth preparation principles for printed restorations

11.30–12.00 Digital occlusion and digital articulation

12.00–12.30 Cementation principles for printed restorations

12.30–13.00 Hands-on

Fitting of the 3D printed individual restorations on the model

Biografija

Erhan Çömlekoğlu is a graduate of Ege University, School of Dentistry where he received his DDS degree. He attended Prosthesis Program of Graduate Study offered by Institute of Health Sciences at Ege University and graduated with Ph.D. degree at Prosthodontics. He is a Professor and resident at the Department of Prosthodontics, School of Dentistry at Ege University, İzmir, Turkey.

He completed several scientific projects supported by national and international institutions. He was honoured more than 30 national and international scientific awards. With these projects he authored more than 70 articles in peer-reviewed scientific journals in the field of adhesive and implant dentistry and established CAD/CAM restorative laboratory at the dental school.

His clinical practice is limited to Prosthodontics at the Department of Prosthodontics, School of Dentistry, Ege University. Dr. Çömlekoğlu is intensely involved in scientific research regarding adhesive dentistry and implant dentistry. His current research interest particularly covers implant-periodontium interactions and their clinical outcomes.



KAKO OD NAJBOLJE PLAĆENOG ZAPOSLENIKA DO VLASNIKA SVOJE ORDINACIJE?

SINIŠA DROBNJAK

Veliki broj stomatologa se još uvijek nalazi u ulozi najbolje plaćenog zaposlenika vlastite ordinacije, umjesto da budu u ulozi vlasnika.

Poslovna strana stomatologije za koju nisu bili školovani, im se jednostavno "dogodila" – a cijena koju plaćaju je da njihova ordinacija upravlja njima, umjesto obrnuto.

Razlika između stomatologa "zaposlenika" i stomatologa "vlasnika" je što se onaj prvi bavi taktičkim, a onaj drugi strateškim rješenjima.

Vlasnik koristi "polugu" drugih ljudi, njihovih vještina i vremena, dok stomatolog "zaposlenik" rješava probleme radeći još duže i više. Konačni ishod je premorenost, nezadovoljstvo i frustracija, koju novac ne može nadoknaditi.

Na ovoj radionici ćete saznati što je sve potrebno da iz uloge zaposlenika pređete u ulogu vlasnika, odnosno koje su to vještine koje vlasnik mora imati da bi mogao upravljati svojim poslovanjem.

Teme koje ćemo obraditi u okviru radionice:

- 12 "smrtnih" grijeha u poslovanju ordinacije i kako njima upravljati
- Osnovni financijski izvještaji za stomatologe
- Ključni pokretači i pokazatelji poslovanja u stomatologiji
- 5 stvari koje stomatolog "vlasnik" ne smije delegirati drugima

Biografija

Siniša Drobniak nakon srednje škole završava Fakultet Elektrotehnike i Računarstva 1993. godine u Zagrebu, smjer diplomirani inženjer elektrotehnike. Godinu kasnije polaže državni ispit za zaštitu od zračenja te već iduće godine osniva tvrtku S.D. Informatika d.o.o. koja uspješno posluje već 20 godina.

Uz stalno usavršavanje dodatno je 2006. godine završio školovanje za računalno vođenu implantologiju. Godine 2008. je predavač na Specijalističkom studiju Stomatološkog fakulteta u Zagrebu, a od 2009. godine je i predstavnik Hrvatske komore dentalne medicine za informatizaciju. Na temelju stečenog iskustva već iduće godine postaje savjetnik Hrvatske komore medicinskih sestara za sestrinsku dokumentaciju. Ujedno je i član nadzornog odbora HDBMT od 2013. godine kao i član konzorcija e-Health Croatia.

Od istaknutijih stečenih znanja koja su trenutno aktualna možemo naglasiti upravljanje ključnim aktivnostima u poslovanju tvrtke, upravljanje ljudskim resursima, vođenje razvojnog tima za izradu programskih rješenja u zdravstvu, rad na e-Gluko projektu financiranim od strane Ministarstva znanosti, obrazovanja i sporta, rad na RONNA- Robotska neuronavigacija – projektu financiranim od strane Ministarstva znanosti, obrazovanja i sporta, razvoju programskih rješenja u zdravstvu, prijavi međunarodnih projekata i upravljanju aktivnostima unutar istih.



PROSTHETIC GUIDED IMPLANTOLOGY – HOW THE DIGITAL WORKFLOW CHANGES OUR DAILY LIVES

DIMITAR FILTCHEV

In this workshop we will go through a different treatment planning protocol – a new way of digital planning and incorporating a psychology-based teeth design. A full digital protocol will be presented for complex treatment planning.

Based on the planning, there are different treatment options, including perio, ortho, implant, and prosthetic treatment.

How predictable are the different protocols, what are the positives and negatives of digital planning? Can we fully trust the contemporary digital imaging systems, intra-oral scanners? Can we use orthodontic approach to solve our perio, implant and esthetic cases?

Based on our clinical experience, we will answer some of these questions and show how the digital tools changed our thinking and working in the recent years.

The practical session will focus on scanning protocols for teeth and implants, creating a personalized smile design, and surgical guide for implant placement.

Learning objectives

At the end of this workshop, participants should be able to:

- Describe the various prosthetic options that are available
- Understand the clinical assessments and criteria for these prosthetic options
- Understand how to plan predictable prosthetic rehabilitations using the latest materials and digital tools
- Gain understanding digital planning benefits

Biografija

Dr. Dimitar Filtchev obtained his degree in Dental Medicine from the Faculty of Dental Medicine in Sofia, in 1998. In 2000 he was appointed Assistant Professor at the Department of Prosthetic Dentistry at the same Faculty and from 2022 is elected as a Professor at the same department. In 2003 he acquired a postgraduate specialization in Prosthetic Dentistry. In 2013 he presented his thesis and got a PhD degree. From 2007-2015 is a President of the Sofia Dental Meeting Association. Co-founder of the Implant Dental Center at the Medical University in Sofia. Specialization in Prosthodontics, Faculty of Dentistry – Munster, Germany. Participated at trainings in Prosthodontics with N.Bichacho, M.Fradeani, in Implantology-H.Salama, in Perio- A.Saadoun, M.Hurzeller, G.Zucchelli. Honorary Member of Style Italiano Group, the Bulgarian Society of Esthetic Dentistry, Bulgarian Scientific Dental Association, Affiliate of the EAED, Instructor at the Zimmer Institute Switzerland. Since 1998 he has been running a successful practice in Sofia, focused on Implantology, Esthetic and Digital Dentistry and Orthodontics. Dr. Filtchev has more than 80 publications in scientific journals, many scientific presentations, numerous participations as an keynote speaker at national and international congresses.



MICROLAYERING TECHNIQUES FOR DYEING ZIRCONIA

mitsutaka fukushima

The masterclass is the lecture's extension. Zirconia dyeing will be demonstrated.

Biografija

Mitsutaka Fukushima, dental technician is a world renowned ceramist from Japan. Mitsu has been working in ceramics for over 20 years in the specialty of color matching. Using internal stain techniques, his unique approach allows him to make ceramics with colours very close to natural teeth. For his first ever trip to Dubai, Mitsu is offering 15 dental technicians the exclusive opportunity to learn these skills from the master himself. He is a MPF KOL in Japan, official instructor of Aidite and Initial zr-fs worldwide colour matching trainer.

INJEKCIJSKA TEHNIKA – MOŽEMO LI OSTVARITI POLIKROMATSKI IZGLED

DAVID GEŠTAKOVSKI

Injekcijska tehnika je indirektno/direktna metoda izrade kompozitnih ljuski kojom kopiramo planiranu morfologiju s wax up-a transparentnim silikonskim ključem. Kasnije ga koristimo kao kalup za ubrizgavanje tekućeg kompozita direktno na površinu zuba.

Na radionici će biti objašnjene osnove planiranja i klinički protokol injekcijske tehnike.

Demonstracija: – izrada transparentnog silikonskog ključa – izrada kompozitne ljuskice injekcijskom tehnikom
Praktično: – izrada kompozite ljuske, završna obrada i poliranje

Biografija

Diplomirao je na Stomatološkom fakultetom, Sveučilište u Zagrebu. Dobitnik je dekanovih i rektorovih nagrada za uspjeh tijekom studija. Tijekom fakulteta boravio je na stranim sveučilištima (EVP), u Bratislavi (2015.), Valenciji (2016.), Stockholmu (2017.) i Strasbourgu (2018.). Osnivač je edukacijske platforme „Injectable technique by David Geštakovski“ u sklopu koje organizira online predavanja i hands-on tečajeve o injekcijskoj tehnici. Kao gostujući predavač sudjeluje na međunarodnim kongresima i edukacijskim centrima diljem svijeta. Autor je objava u Quintessence International (QI) i International Journal of Esthetic Dentistry (IJED). Član je HDEDM-a (Hrvatsko društvo estetske dentalne medicine). Radio je u Dublinu, Irskoj (3Dental), a trenutno je zaposlen u Ordinaciji Geštakovski (Zagreb, Croatia). GC je key-opinion leader.



DIGITALNI RECEPTI

DEJAN LISJAK

Detaljna teorijska i praktična objašnjenja masterclassa:

Digitalni protokoli uz rad sa zubnom tehnikom; Digitalni protokoli kod jednoseansnih protetskih nadoknada; Digitalni protokoli u implantoprotetici.

Speed dentistry vs. slow dentistry:

- generalno opredjeljenje doktora ili izbor protokola u odnosu na indikaciju

Prikazi slučajeva

Dizajn preparacije zuba:

-u odnosu na izbor materijala; u odnosu na mock-up; u odnosu na način cementiranja

Intraoralno skeniranje:

-izbor skenera (brzina, preciznost, cijena); priprema radnog polja za skeniranje; tehnika skeniranja; primjena intraoralnog skenera kao osnovnog alata stomatološke prakse

Digitalni dizajn:

-osnovni principi; biblioteke zuba; biogeneric funkcija; biocopy funkcija; copy&mirror funkcija; virtualni artikulatork

Što nas čeka u budućnosti kada je digitalna stomatologija u pitanju...

Praktični rad:

Cilj praktičnog rada je stjecanje povjerenja u digitalne protokole (brzina, preciznost, kvaliteta), usvajanje novog digitalnog "mindseta" i učenje planiranja indikacija kroz digitalne protokole.

Svaki od polaznika će na modelu naučiti osnove:

- Intraoralnog skeniranja
- Digitalnog dizajna (krunica, inlay/onlay)
- Strategije rezanja

Biografija

Prim. dr Dejan Lisjak rođen u Beogradu 1970. godine, diplomirao na Stomatološkom fakultetu u Beogradu 1996., gde je i stekao stručno zvanje specijaliste iz oblasti STOMATOLOŠKA PROTETIKA 2001. godine. Vlasnik je stomatološke prakse CERECENTAR u Beogradu od 2000. godine.

Poseban akcenat u razvoju prakse stavlja na primeni savremenih dijagnostičkih i terapijskih stomatoloških procedura i doprinosi razvoju kompjuterizovane stomatologije u regionu.

Jedan je od osnivača Udruženja za kompjuterizovanu stomatologiju, osnovanog u Beogradu 2010. godine. Stručno zvanje Primarijusa stiče 2010. godine. 2019. godine postaje opinion leader firme DENTSPLY-SIRONA i postaje njihov globalni predavač. Autor i koautor mnogobrojnih naučnih radova publikovanih u domaćim i stranim stručnim časopisima.



THE ART OF LAYERING

SABINE MAYER

Nature shows us everything we need to know to create a natural restoration. In order to achieve lifelike morphology, surface, shape and color, it is very important to consciously observe, study and imitate natural teeth. Contrasts with opal and effect materials used correctly, playing with the colors and bold details then produce the desired result. Nature is our best teacher.

Course content:

In a Powerpoint, the speaker presents her workflow, her philosophy and cases of everyday laboratory work.

In the subsequent workshop:

An anterior tooth individually with dentin, effect, and opal materials, layered on a zircon framework and a monolithic anterior tooth painted with stains.

Only opal materials are used for the layered crown, as these come closest to the natural tooth enamel.

Step by step towards a morphologically correct crown shape, inspired by nature through individual processing of shape and surface.

Surface finish by hand polishing.

Biografija

Sabine Mayer is a dental technician focusing on ceramics. She had previously worked in dental laboratories in Austria and since October 2020 is working in the ACCADENT Dental Lab in Koblenz, Germany. She has had extensive training and education with world-renowned dental technicians in areas of dental ceramics and dental photography. She has published papers in Quintessenz and Dental Dialog. She is a KOL for Dentsply Sirona and a member of Atelier Dentaire International. She speaks and gives courses internationally.

DIGITALIZATION | CLINICAL PERFORMANCE

NAZARIY MYKHAYLYUK

1. Short presentation about preparation for veneers and onlays.
2. Pre scanning with intra oral scanner.
3. Preparation of 3 teeth for different types of veneers. (Live demo and hands-on)
4. Final scanning with intra oral scanner. (Live demo and hands-on)
5. Fabrication of provisional restorations. (Live demo and hands-on)

Biografija

Nazariy Mykhaylyuk is a specialist in the field of microscopic and digital dentistry. Works in Kyiv and Ivano-Frankivsk, Ukraine in family clinics in a team with his father and dental technician Bogdan Mykhaylyuk (M.Vision Lab-Oral Design Ukraine) and sister. Dr. Mykhaylyuk first started organising courses in 2010, after creating M.Vision Academy, and has since taught on the topics of "Tooth preparation with a microscope for full crowns", "Photo and video documentation in dentistry. Microscopic approach", "Total rehabilitation from A to Z" and "Indirect restoration - from macro to micro. MicroVision approach". He has developed preparazion kits and hand instruments in collaboration with Komet and Deppeler. He is a DentalXP expert. He has given more than 300 presentation in over 60 countries worldwide.



441 SYSTEM A NEW TECHNICAL APPROACH USING ZIRCONIA KATANA YML

DANIELE RONDONI

High Translucence Multilayered Katana Zirconia features sophisticated aesthetic as well as outstanding mechanical properties which have positively influenced the lab-based digital workflow and given winning answers to the ever higher clinical morphological/functional requests. Hence, the possibility to point out a “distinctive” technical approach to each project while combining competent lab-based communication skills and the wide range of chromatic adaptability of ML zirconia. This is necessary in case of extensive, individual full-contour zirconia posterior solutions with the new FC paste porcelain.

In order to achieve an ideal final result, it is paramount to have logical selection criteria of new Zirconia and to adopt a specific manual finishing technique.

Our aim is to finalize:

- micro cut-back YML zirconia: a single anterior restoration by microlayering technique, ILS and Luster porcelain
- zero-cut-back YML zirconia: a full contour crown 16 by microlayering technique with FC paste stain

Introduction to:

- select the Zirconia Katana Multilayered
- manage the interface with Internal Live Stain technique
- microlayering technique with nanoporcelain mechanical polishing

Biografija

Born in Savona in 1961, he has always lived and worked in his home town. A talented student at “P. Gaslini” Dental School in Genoa, in 1981, upon request of Prof. Derchi, he helped laying the basis for the first Savona-based dental school and one year later he started his own dental lab. The second turning point in his career is in 1988, after an inspiring experience at Master Oliviero Turillazzi’s clinic in Brescia. Further remarkable professional experiences soon followed, in Switzerland, Germany and in Japan too, at the side of Hitoshi Aoshima, one of the world’s most recognized masters in odontology. Always focused on morphology and dental aesthetics, Daniele Rondoni has constantly been committed to the development of new generation materials, combining traditional analogical approach and latest digital technologies. A consultant for Dr. Jules Allemand and Micerium dental company since 1993, in 1994 he joined EAED, the European Academy of Esthetic Dentistry, becoming an Affiliate Member first and then an Active Member, respectively in 2005 and 2007. In 2013 he was invited to participate as an official lecturer at the 27th Annual Meeting of the Academy held in Crete. He has authored a number of articles published on the most renowned dental magazines and journals. In 1997, his book “Tecnica della Multistratificazione in Ceramica” (Ceramic Multilayering Technique) was published by Italian leading scientific editor UTET, and in his “Handbook for the use of composite materials” – providing useful protocols for both composite indirect and press techniques on metal frameworks and implants –, the “TENDER – inverse hardness layering system” he has invented is exhaustively illustrated. Some of the cases he treated have been published in the volume “Il restauro anteriore conservativo dei denti anteriori” by L. Vanini, F. Mangani, O. Klimovscaja (Conservative anterior restoration of anterior teeth – Ed. E. Masson). Other cases, treated at Dr. Devoto’s dental clinic, have been published in “Odontoiatria restaurativa: procedure di trattamento e prospettive future” (Restoration dentistry: treatment procedures and perspectives – Ed. E. Masson). He has also participated in “LAYERS, un atlante sulla stratificazione della resina composita” by J. Manauta – A. Salat (Layers, an atlas on composite resin layering – Ed. Quintessenza). Deeply devoted to teaching, he is the mind behind the AAT Community College, a project to support education and professional training in odontology. Since 2011 he has acted as International Instructor for Kuraray Europe Dental Inc., the European branch of the renowned Japanese dental company, and in 2014 he founded NISC, the Noritake Italian Study Club, always in collaboration with Kuraray Europe. An associate professor of Restorative Odontology at the University of Chieti-Pescara and a Member of the Teaching Staff at the “Endodontics and Restorative Odontology” Master Course at the University of Siena, he is also an associate member, lecturer and cultural advisor of SICED, the Brescia-based Italian School of Dental Ceramic.



KOREKCIJA DONJE TREĆINE LICA ART FILERIMA

VLADIMIR B. STOJILJKOVIĆ

Radionica je nastavak teme predavanja, s radnim dijelom.

Biografija

Mr sc. med. dr Vladimir B. Stojiljković je priznati plastični kirurg koji svoj klinički i istraživački rad posvećuje estetskoj kirurgiji lica i tijela, razvijajući vlastite tehnike uz primjenu najsuvremenijih materijala. Pionir je u oblasti regenerativne kirurgije na našim prostorima i poznat je po edukacijama koje drži kolegama plastičnim kirurzima, dermatolozima, stomatolozima, a iz oblasti minimalno invazivnih procedura na licu, kao i po tome što je uveo BRAVA metodu kod nas kojom se grudi povećavaju prirodnim putem, vlastitom mašću.

Kada govorimo o njegovom radu sa pacijentima, fokusiran je na lice i tijelo, estetiku, uklanjanje znakova starenja na licu i usporavanje procesa starenja. Fokusiran je na primjenu minimalno invazivnih procedura na licu, insistirajući na poznavanju kirurške anatomije lica i promjenama tokom procesa starenja.

Dr Vladimir Stojiljković je objavio više od 20 radova iz oblasti estetske, rekonstruktivne kirurgije i opekotina, dobitnik je Stipendije Ministarstva odbrane SR Jugoslavije (1996-1998) i Stipendije grada Niša za talente (1996-1998). Učestvovao je na čuvenim kongresima u zemlji i inostranstvu, kao gost i kao predavač.

PULP
PROPHYLAXIS
PREMOLARS
CHECK
DECAY
BRIDGE
CLEANING
BRACES
DENTAL
PREMOLAR
ENAMEL
HEALTH
CROWN
ORAL
PROFESSIONAL
ORTHODONTIST
TEETH
GINGIVITIS

DENTAL



CROWN
CLEANING
ORTHODONTIST
CAD/CAM
X-RAYS
TEETH
VENEERS

CARE
ENAMEL
THIRD
DENTAL
COMPOSITES
ABSCESS
EXOCAD
MOLARS
BLEACHING
INCISORS

EDUCATION

POSTERI



MIKROINVAZIVNA I UČINKOVITA TERAPIJA – ICON INFILTRACIJSKA TEHNIKA

Antonija Pranjčić¹, Petra Petro¹, Marta Smok¹, Filip Matija Vuković^{2,3*}, Valentina Brzović Rajić^{2,4}

¹ Studentica pete godine, Stomatološki fakultet Sveučilišta u Zagrebu, Zagreb, Hrvatska

² Zavod za bolesti zubi, Klinika za stomatologiju, Klinički bolnički centar Zagreb, Zagreb, Hrvatska, *Specijalizant

³ Ordinacija dentalne medicine Josip Čes, Osijek, Hrvatska

⁴ Zavod za endodonciju i restaurativnu stomatologiju, Stomatološki fakultet Sveučilišta u Zagrebu, Zagreb, Hrvatska

Uvod: Individualna percepcija i specifični zahtjevi estetske dentalne medicine temelje se na postizanju maksimalnog učinka primjenom minimalno invazivnih terapijskih postupaka. Postizanje harmonije u proporcijama i estetičnosti svih dijelova lica imperativ je suvremenog pristupa restaurativnih zahvata. Estetske nesavršenosti uslijed demineralizacije ili razvojnih nepravilnosti moguće je učinkovito tretirati infiltracijom niskoviskoznom smolom. Fluktuacije pH-vrijednosti u biofilmu zuba uzrokuju gubitak minerala i povećanje broja pora površinske zone inicijalne karijesne lezije. Trajno zatvaranje mikroporoziteta unutar demineralizirane cakline te uspješan estetski učinak moguće je postići primjenom infiltracijske Icon tehnike.

Postupci: Kliničkim pregledom kod pacijentice (11) su na vestibularnim ploham gornjih inciziva dijagnosticirane nekarijesne difuzne bijele lezije. Sukladno kliničkim smjernicama i uputama proizvođača, proveden je protokol u svrhu zaustavljanja napredovanja lezija. Prije primjene infiltracijske smole Icon (DMG, Chemisch-Pharmazeutische Fabrik GmbH, Hamburg, Njemačka) provedeno je profilaktičko čišćenje zuba i izolacija postavljanjem zaštitne gumene plahtice. Nakon jetkanja 15% hidrokloridnom kiselinom (Icon-Etch) 2 minute te 30 sekundi ispiranja vodom i sušenja, vestibularne plohe zuba dehidrirane su 95% etanolom (Icon-Dry) 30 sekundi. Završno je nanosena niskoviskozna smola TEGDMA (Icon-Infiltrant) u trajanju 3 minute koja je potom polimerizirana 40 sekundi.

Ishodi: Po završetku infiltracije caklinski defekt je u potpunosti optički maskiran. Pacijentica je u jednoj posjeti dobila priželjkivano rješenje svog estetskog nedostatka primjenom potpuno bezbolnog i neinvazivnog postupka.

Zaključak: Suvremena dentalna medicina primjenom niskoviskozne infiltracijske smole nadomješta tradicionalne konzervativne postupke i dugotrajno je rješenje u svrhu mehaničke stabilnosti zatvorene lezije.

Ključne riječi: Minimalno invazivni terapijski postupci, Bijela mrlja, Infiltracijska smola



MICRO-INVASIVE AND EFFECTIVE THERAPY – ICON INFILTRATION TECHNIQUE

Antonija Pranjić¹, Petra Petro¹, Marta Smok¹, Filip Matija Vuković^{2,3+}, Valentina Brzović Rajić^{2,4}

¹ Fifth year student, School of Dental Medicine, University of Zagreb, Zagreb, Croatia

² Department of Dental Diseases, Dental Clinic, University Clinical Hospital Zagreb, Zagreb, Croatia, + Resident

³ Dental practice Josip Čes, Osijek, Croatia

⁴ Department of Endodontics and Restorative Dentistry, School of Dental Medicine, University of Zagreb, Zagreb, Croatia

Introduction: Individual perception and specific requirements of aesthetic dental medicine are based on achieving the maximum effect by applying minimally invasive therapeutic procedures. Achieving harmony in the proportions and aesthetics of all parts of the face is imperative for a modern approach to restorative procedures. Aesthetic imperfections due to demineralisation or developmental irregularities can be effectively treated by infiltration with a low-viscosity resin. Fluctuations in the pH value in the dental biofilm cause mineral loss and an increase in the number of pores in the surface zone of the initial caries lesion. Permanent closure of microporosity within demineralised enamel and a successful aesthetic effect can be achieved by applying the infiltration Icon technique.

Procedures: A clinical examination of the patient (11) revealed non-carious diffuse white lesions on the vestibular surfaces of the upper incisors. Following the clinical guidelines and the manufacturer's instructions, a protocol was implemented to stop the progression of the lesions. Before applying Icon infiltration resin (DMG, Chemisch-Pharmazeutische Fabrik GmbH, Hamburg, Germany), prophylactic tooth cleaning and isolation by placing a protective rubber dam was performed. After etching with 15% hydrochloric acid (Icon-Etch) for 2 minutes, rinsing with water for 30 seconds, and drying, the vestibular surfaces of the teeth were dehydrated with 95% ethanol (Icon-Dry) for 30 seconds. Finally, low-viscosity resin TEGDMA (Icon-Infiltrant) was applied for 3 minutes, which was then polymerised for 40 seconds.

Outcomes: At the end of the infiltration, the enamel defect is completely optically masked. The patient received the desired solution to her aesthetic deficiency in one visit using a completely painless and non-invasive procedure.

Conclusion: Modern dental medicine replaces traditional conservative procedures by using low-viscosity infiltration resin and is a long-term solution for the purpose of mechanical stability of a closed lesion.

Keywords: Minimally invasive therapeutic procedures; White spot; Infiltration resin



MULTIDISCIPLINARNI PRISTUP U SANACIJI PROTETSKOG PACIJENTA - PRIKAZ SLUČAJA

Elizabeta Četa Gornik^{1,2}, Marko Krmpotić¹, Nikolina Vuković Jusup³

¹ Poliklinika IMED, Zagreb, Hrvatska

² Specijalizant, Zavod za stomatološku protetiku, Klinika za stomatologiju, KBC Zagreb, Zagreb, Hrvatska

³ Dentalni laboratorij Nikolina Vuković Jusup, Zagreb, Hrvatska

Uvod: Planiranje protetske terapije složen je proces koji često zahtijeva znanja i vještine specijalista različitih grana dentalne medicine. Svrha ovog rada je prikazati multidisciplinarnu sanaciju pacijentice kroz više koraka.

Postupci: Pacijentica (48 god) dobrog općeg zdravstvenog stanja i dobre oralne higijene želi "promijeniti svoj osmijeh". Pregledom je ustanovljeno da nedostaju zubi 17,14,25,26,27 i 46. Učinjen je plan sanacije koji se proveo kroz više koraka.

Korak 1 - Sanacija karijesa u gornjoj i donjoj čeljusti te endodonsko liječenje zuba 24 i opskrba s individualnom lijevanom nadogradnjom.

Korak 2 - Frenulektomija u gornjoj čeljusti prije ortodonske terapije.

Korak 3 - Ortodonska terapija; zatvaranje dijastema, otvaranje prostora za fiksno-protetski rad u lateralnom segmentu.

Korak 4 - Kirurška terapija; vađenje zuba 15 i 16 te imedijatna ugradnja implantata (Nobel Biocare, Kloten, Švicarska) u regiji 14,16 i 46.

Korak 5 - Izbjeljivanje devitaliziranog zuba 21 s Opalescence 35% HP gelom (Ultradent Products, Inc., South Jordan, SAD) te izrada mekih individualnih udlaga s rezervoarima za izbjeljivanje zubi s Opalescence 16 PF gelom, u trajanju od 2 tjedna.

Korak 6 - Protetska terapija; metal-keramički mostovi nošeni implantatima (u regiji 14-16), uporišnim zubima (24-27) te krunica na implantatu u regiji 46.

Ishodi: Po završetku cjelokupnog terapijskog postupka pacijentica je iskazala zadovoljstvo finalnim radom.

Zaključak: Protetska terapija kompleksnih slučajeva, uz adekvatno planiranje i multidisciplinarni pristup u liječenju, daje funkcionalno i estetski visokozadovoljavajuće rezultate.

Ključne riječi: Multidisciplinarni pristup; Protetska terapija; Implantološka terapija; Dentalni implantati



MULTIDISCIPLINARY APPROACH IN REHABILITATION OF A PROSTHETIC PATIENT - CASE REPORT

Elizabetha Četa Gornik^{1,2}, Marko Krmpotić¹, Nikolina Vuković Jusup³

¹ Polyclinic IMED, Zagreb, Croatia

² Resident, Department of prosthodontics, University Hospital Centre Zagreb, Zagreb, Croatia

³ Dental laboratory Nikolina Vuković Jusup, Zagreb, Croatia

Introduction: Prosthetic treatment planning is a complex process that often requires the knowledge and skills of specialists in various areas of dental medicine. The purpose of this case report is to present a multidisciplinary rehabilitation conducted through several steps.

Procedures: A patient (48 years old) of good general health and oral hygiene wanted to “transform her smile”. The clinical examination revealed missing teeth 17, 14, 25, 26, 27, and 46. A rehabilitation plan was made and carried out through several steps.

Step 1 - Rehabilitation of caries in the upper and lower jaw, endodontic treatment of tooth 24 and an individual metal post.

Step 2 - Frenulectomy in the upper jaw before orthodontic therapy.

Step 3 - Orthodontic therapy; closing the diastema, opening the space for fixed prosthetic work in the lateral segment.

Step 4 - Surgical therapy; extraction of teeth 15 and 16 and immediate installation of implants (Nobel Biocare, Kloten, Switzerland) in the 14,16 and 46 region.

Step 5 - Whitening of devitalised tooth 21 with Opalescence 35% HP gel and making individual soft trays with reservoirs for teeth whitening with Opalescence 16 PF gel (Ultradent Products, Inc., South Jordan, USA) for 2 weeks.

Step 6 - Prosthetic therapy; metal-ceramic bridges supported by: implants (in the 14-16 region), abutment teeth (24-27), and a crown on an implant in region 46.

Outcomes: At the end of the comprehensive therapeutic procedure, the patient expressed her satisfaction with the final work.

Conclusion: Prosthetic therapy of complex cases, with adequate planning and a multidisciplinary approach to treatment, gives functionally and aesthetically highly satisfactory results.

Keywords: Multidisciplinary approach; Prosthetic treatment; Implant therapy; Dental implants



ESTETSKA REHABILITACIJA - MULTIDISCIPLINARNI PRISTUP

Tena Stilinović^{1,2,3}, Martina Juzbašić^{1,4}, Vanja Delladio^{1,5}

¹ Specijalizant, Zavod za stomatološku protetiku, Klinički bolnički centar Zagreb, Zagreb, Hrvatska

² Ordinacija Stilinović, Slavonski Brod, Hrvatska

³ Poliklinika Fiziodent, Zagreb, Hrvatska

⁴ Medicinski centar Mursa, Osijek; Fakultet za dentalnu medicinu i zdravstvo, Sveučilište J.J.Strossmayera Osijek, Osijek, Hrvatska

⁵ Poliklinika Ortho Design, Gornji Kuršanec, Hrvatska

Uvod: Estetska stomatologija često podrazumijeva multidisciplinarni pristup kako bi se postigli najbolji mogući rezultati, uključujući znanja i vještine različitih područja kao što su ortodoncija, restaurativna stomatologija, endodoncija, oralna kirurgija, parodontologija i protetika. Razvojem tehnologije i novih gradivnih materijala omogućeno je da se na predvidljiv i jednostavniji način dođe do željenih rezultata.

Postupci: Dvadesetosmogodišnja pacijentica dolazi u kliniku zbog nezadovoljstva estetikom gornjih frontalnih zubi. Pregledom je ustanovljena kompresija gornjih centralnih inciziva te endodontski liječen, diskoloriran, mikrodontni gornji lijevi lateralni inciziv. Učinjen je plan terapije koji je uključivao ortodontsku, restaurativnu i protetsku terapiju, rukovodeći se minimalno invazivnim pristupom rješavanja problema u estetskoj zoni. Terapija je započeta hibridnom ortodontskom terapijom koja je uključivala kombinaciju fiksnog aparata i alignera kako bi se zubi doveli u „idealni“ položaj. Gornji lijevi lateralni inciziv potom je izbijeljen intrakanalnim uloškom 35% hidrogen peroksida sa svrhom smanjenja diskoloracije budućeg bataljka, a ostatak zubi izbijeljen je uz pomoć udlaga za kućno izbijeljivanje preparatom na bazi 16% karbamid peroksida. Desni lateralni inciziv te centralni incizivi restaurirani su kompozitnim ljuskicama injekcijskom tehnikom u željeni oblik. Potom je lijevi lateralni inciziv izbrušen na zaobljenu stepenicu. Umjesto klasičnog otiskivanja korišten je intraoralni skener te je sken poslan u zubotehnički laboratorij. Do izrade finalnog protetskog rada, pacijentica je bila opskrbljena privremenim nadomjeskom (PMMA), kako bi se što bolji oblikovala meka tkiva i dobio što bolji estetski rezultat s konačnim nadomjeskom. Materijal izbora za konačni protetski rad bio je cirkonijev dioksid zbog svojih dobrih estetskih svojstava u slučaju diskoloriranih zubi. Po završetku terapije pacijentica je dobila ortodontski retainer.

Ishodi: Uz pomoć predvidljivosti ortodontske preprotetske pripreme, stvoreni su uvjeti za minimalno invazivni pristup te zadovoljavajuću estetiku s poštedom tvrdih zubnih tkiva.

Zaključak: Multidisciplinarnim pristupom koji je obuhvaćao ortodontsku, restaurativnu te protetsku terapiju stvorili su se uvjeti za estetsku sanaciju prednjeg segmenta gornje čeljusti uz minimalnu preparaciju tvrdih zubnih tkiva.

Ključne riječi: Estetika; Multidisciplinarni pristup; Ortodoncija; Protetika



AESTHETIC REHABILITATION - MULTIDISCIPLINARY APPROACH

Tena Stilinović^{1,2,3}, Martina Juzbašić^{1,4}, Vanja Delladio^{1,5}

¹ Resident, Department of prosthodontics, Dental Clinic, University Hospital Centre Zagreb, Zagreb, Croatia

² Dental practice Stilinović, Slavonski Brod, Croatia

³ Polyclinic Fiziodent, Zagreb, Croatia

⁴ Medical centre Mursa, Osijek; Faculty of Dental Medicine and Health Osijek, J.J.Strossmayer University Osijek, Osijek, Croatia

⁵ Polyclinic Ortho Design, Gornji Kuršanec, Croatia

Introduction: Aesthetic dentistry often presumes a multidisciplinary approach to achieve the best possible results, including knowledge and skills from different dental fields, such as orthodontics, restorative dentistry, endodontics, oral surgery, periodontology, and prosthetics. Furthermore, the development of dental technologies and new materials has made it possible to achieve desired results predictably and simply.

Procedures: A 28-year-old female patient came to the clinic dissatisfied with the aesthetics of her maxillary front teeth. The examination revealed compression of the upper central incisors and an endodontically treated, discoloured, microdontic upper left lateral incisor. For this patient, pursuing a multidisciplinary approach that includes orthodontics, restorative dentistry and prosthodontics was decided to solve the problem minimally invasively. Therapy was started with hybrid orthodontic treatment, which included a combination of fixed orthodontics and aligners to align the teeth into the "ideal" position. The maxillary left lateral incisor was then whitened with an intracanal application of 35% hydrogen peroxide to reduce the discolouration of the future tooth preparation. The rest of the teeth were whitened using home whitening trays with a gel based on 16% carbamide peroxide. Using the injectable technique, the right lateral incisor and central incisors were restored to the desired shape with composite veneers. Furthermore, the left lateral incisor was chamfer prepared. Instead of a classic impression, an intraoral scanner was used, and the scan was sent to the dental laboratory. Until the final prosthetic restoration was made, the patient wore temporary PMMA crowns to better shape the soft tissues and achieve the best possible aesthetic result. The material of choice for the final prosthetic restoration was zirconium dioxide because of its good aesthetic properties in the case of discoloured teeth. At the end of the therapy, the patient received an orthodontic retainer.

Outcomes: Predictability of orthodontic pre-prosthetic preparation created conditions for a minimally invasive procedure and satisfactory aesthetics while preserving hard tooth structure.

Conclusion: A multidisciplinary approach that included orthodontics, restorative dentistry and prosthodontics enabled minimally invasive treatment, and avoided unnecessary overpreparation of maxillary right lateral and central incisors.

Keywords: Aesthetics; Multidisciplinary approach; Orthodontics; Prosthodontics



ESTETSKO I FUNKCIJSKO ZBRINJAVANJE PACIJENTA S GENERALIZIRANOM POTROŠENOSTI I GUBITKOM VERTIKALNE DIMENZIJE OKLUZIJE

Sandra Štetić¹

¹Navident centar dentalne medicine, Velika Gorica, Hrvatska

Uvod: Nekarijesna oštećenja zuba nastaju utjecajem fizičko-mehaničkih i kemijskih čimbenika. Tijekom određenog vremenskog perioda međusobnim djelovanjem fiziološkog trošenja i patološkog gubitka tvrdih zubnih tkiva (atricije, abrazije, erozije, abfrakcije, bruksizma) mijenjaju se prvobitni međučeljusni odnosi što dovodi do razvoja simptoma koji su primarni razlog pacijenta za nezadovoljstvo i posjet stomatološkoj ordinaciji.

Postupci: Pacijent u dobi od 43 godine dolazi u ordinaciju sa željom poboljšanja estetike osmijeha. Navodi da mu smetaju kratki, slabo vidljivi zubi u gornjoj frontu, pojava boli i osjetljivosti. Kliničkim pregledom ustanovljena je generalizirana potrošenost, gubitak vertikalne dimenzije okluzije i nedostatak interokluzijskog prostora. U ovom slučaju odlučeno je da će biti potrebna oralna rehabilitacija gornjeg i donjeg zubnog luka i povišenje vertikalne dimenzije okluzije radi postizanja adekvatne funkcije sa zadovoljavajućim estetskim rezultatom. Nakon toga su izrađeni dijagnostički wax-up i mock-up na temelju anatomske otiske gornje i donje čeljusti, prijenosa obraznim lukom, centričnog registrata s prethodno određenom vertikalnom dimenzijom, portretnih fotografija i fotografija osmijeha. Terapija je započeta brušenjem zuba preko mock up-a s ciljem oblikovanja minimalno invazivne preparacije i maksimalnim očuvanjem tvrdih zubnih tkiva nakon čega su uzeti korekturni otisci adicijskim silikonom. U laboratoriju je izrađen privremeni PMMA rad u novoj vertikalnoj dimenziji okluzije na temelju početne dijagnostike i planiranja. Pacijent je zatim nosio privremeni rad 3 mjeseca kako bi se testirala funkcija, estetika i fonacija. Unutar tog perioda nije bilo simptoma temporomandibularnih poremećaja te se krenulo u izradu konačnog protetskog rada solo krunicama na svim zubima u obje čeljusti s blagim kvržicama na premolarima i molarima. Materijal izbora je bio monolitni višeslojni (multilayer) cirkonijev dioksid čija je prednost manje brušenje zuba, visoka estetska svojstva (translucencija), velika preciznost i smanjen rizik od otkrhuća. Nakon završetka terapije pacijent je dobio zaštitnu Michigan udlagu.

Ishod: Dugoročan uspjeh oralne rehabilitacije moguć je provođenjem dobre dijagnostike i planiranja, poštivanjem vremena adaptacije na promjenu visine zagriža, uvažavanjem pacijentovih subjektivnih tegoba i estetskih zahtjeva i pažljivim odabirom konačnog materijala protetskog rada.

Zaključak: Detaljnom dijagnostikom, planiranjem i provedbom protetske terapije u pacijenata s generaliziranom potrošenosti i sniženom vertikalnom dimenzijom okluzije uspješno se postiže zadovoljavajuća funkcija i estetika.

Ključne riječi: oralna rehabilitacija, vertikalna dimenzija okluzije, estetika



AESTHETIC AND FUNCTIONAL TREATMENT IN PATIENT WITH GENERALISED TOOTH WEAR AND DECREASED OCCLUSAL VERTICAL DIMENSION

Sandra Štetić¹

¹Navident dental medicine centre, Velika Gorica, Croatia

Introduction: Non-carious tooth damage is caused by physical, mechanical and chemical factors. Over time the interaction between physiological wear and pathological loss of hard dental tissues (attrition, abrasion, erosion, abfraction, bruxism) changes the original interocclusal relations, leading to the development of symptoms that are the primary reason for the patient's dissatisfaction and visit to the dental office.

Procedures: A 43-year-old patient came to the dental office to improve smile aesthetics. He reported trouble with short, poorly visible teeth in the upper front, pain, and sensitivity. A clinical examination revealed generalised tooth wear, decreased occlusal vertical dimension and lack of interocclusal space. It was decided that oral rehabilitation and increasing the occlusal vertical dimension would be necessary to achieve adequate function with a satisfactory aesthetic result. Diagnostic wax-up and mock-up were made based on anatomical impressions, face bow transfer, centric registration with a previously determined vertical dimension portrait and smile photography. Treatment began with tooth preparation over the mock-up, aiming for minimally invasive preparation and maximum preservation of hard dental tissues. This was followed by impressions with polyvinyl siloxane and laboratory temporary PMMA teeth made in the new occlusal vertical dimension based on the initial diagnosis and planning. The patient wore the temporary teeth for 3 months to test function, aesthetics and phonation. During this period, there were no symptoms of temporomandibular disorders, and the final prosthetic work was then made with solo crowns on all teeth, with lower cusps on the premolars and molars. The material of choice was monolithic multilayer zirconia which allows less tooth preparation, high aesthetic properties (translucency), high precision and reduced risk of chipping. After completing the therapy, the patient received a protective Michigan splint.

Results: Long-term success of oral rehabilitation is possible through good diagnosis and planning, an adjustment period with temporary teeth and considering the patient's complaints, aesthetic demands and choice of the suitable dental material.

Conclusion: Strategic considerations in prosthodontic treatment planning in patients with generalised tooth wear and reduced occlusal vertical dimension lead to successful function and aesthetics achievement.

Keywords: Oral rehabilitation; Occlusal vertical dimension; Aesthetics



POTPUNO KERAMIČKE LJUSKICE KAO MINIMALNO INVAZIVNO RJEŠENJE U PREDNJOJ REGIJI, TROGODIŠNJE PRAĆENJE

Mateja Zaher Švarc¹, Ivan Štrosar²

¹ Ordinacija dentalne medicine Mateja Zaher Švarc, Zagreb, Hrvatska

² Dentalni laboratorij Štrosar, Zagreb, Hrvatska

Uvod: Keramičke ljuskice su tanki keramički nadomjesci kojima se zbrinjavanju zubi sa promijenjenim oblikom, bojom ili položajem. One su jedno od najčešćih minimalno invazivnih rješenja u estetskoj stomatologiji. Cementiraju se adhezivnim cementima na caklinu prednje površine zuba.

Postupci: Pacijent je došao u ordinaciju dentalne medicine sa željom da uljepša vlastiti osmijeh. Uzeta je opća i stomatološka anamneza, učinjena je analiza rendgenske snimke te analiza međučeljusnih odnosa. Intraoralnim pregledom je dobiven uvid u stanje mekih i tvrdih zubnih tkiva. Učinjeno je skeniranje intraoralnim skenerom (TRIOS 3, 3Shape, Kopenhagen, Danska), kako bi se pristupilo detaljnoj dijagnostici. U dogovoru sa dentalnim tehničarom napravljen je dijagnostički wax-up s ciljem prikaza budućeg rada pacijentu. Nakon što je pacijent pristao na terapiju, pristupilo se minimalno invazivnoj preparaciji središnjih i lateralnih sjekutića te očnjaka. Bukalne plohe zuba brušene su svrdlom za preparaciju zuba za ljuskice (Diamond 868B, Komet dental, Lemgo, Njemačka) uz minimalno brušenje incizalnog brida te očuvane interdentalne kontakte na zubima bez kompozitnih ispuna. Preostali zubi tretirani su sredstvom za izbjeljivanje (Opalescence TM Boost, Ultradent Products, Inc., South Jordan, SAD). Za vrijeme izrade trajnog rada, pacijentu su cementirane privremene ljuskice kao termička zaštita brušenim zubima.

Prije definitivnog otiskivanja, u sulkus zuba su postavljeni retrakcijski konci #000 (Ultrapak TM, Ultradent Products, Inc., South Jordan, SAD). Intraoralnim skenerom skenirana je gornja i donja čeljust, registrirani su međučeljusni odnosi te odnos obje čeljusti u prednjoj i lateralnim kretnjama.

Nakon probe gotovih keramičkih ljuskica, pristupilo se cementiranju. Ljuskice su cementirane dvostruko polimerizirajućim cementom za adhezivno vezanje (Variolink Esthetics DC, Ivoclar Vivadent, Lichtenstein).

Nakon 3 godine pacijent dolazi na redovni kontrolni pregled, pri kojem su uklonjene tvrde i meke zubne naslage. Keramički nadomjesci su dokumentirani ekstraoralnim i intraoralnim fotografijama.

Ishodi: Nakon izrade i trajnog cementiranja potpuno keramičkih ljuskica pacijent je potpuno zadovoljan rezultatom. Ovim fiksno protetskim radom je dobivena željena estetika te potrebna funkcija. Crveno-bijela estetika je potpuno zadovoljena.

Zaključak: Nakon tri godine, potpuno keramičke ljuskice pokazuju se kao izvrsno estetsko i funkcijsko rješenje za zbrinjavanje estetski manje vrijednih zuba u prednjoj regiji. Nema vidljivih upalnih promjena parodontnog tkiva kao ni promjena na keramičkim nadomjescima.

Ključne riječi: Keramička ljuskica; Minimalno invazivno brušenje; Digitalno otiskivanje



FULL CERAMIC VENEERS AS A MINIMALLY INVASIVE SOLUTION IN THE ANTERIOR REGION - 3Y FOLLOW-UP

Mateja Zaher Švarc¹, Ivan Štrosar²

¹ Dental practice Mateja Zaher Švarc, Zagreb, Croatia

² Dental laboratory Štrosar, Zagreb, Croatia

Introduction: Ceramic veneers are thin ceramic replacements used to improve the appearance of teeth that have changed in shape, colour, or position. They are one of the most common minimally invasive solutions in aesthetic dentistry. They are cemented with adhesive types of cement on the front surface of the teeth.

Procedure: The patient came to the dental clinic to enhance their smile. General and dental anamnesis were taken, and X-ray images and inter-occlusal relationships were analysed. An intraoral examination provided insight into soft and hard dental tissue conditions. Scanning was performed using an intraoral scanner (TRIOS 3, 3Shape, Copenhagen, Denmark) to perform detailed diagnostics. The diagnostic wax-up was made to show the patient's future work. After the patient agreed to the therapy, a minimally invasive preparation was performed. Buccal surfaces of the teeth were prepared with a drill for veneers with minimal preparation of the incisal edge and preserved interdental contacts. The remaining teeth were treated with a bleaching agent (Opalescence TM Boost-Ultradent Products, Inc., South Jordan, USA). Temporary veneers were cemented for thermal protection. Before taking the definitive impression, #000 retraction cords (Ultrapak TM, Ultradent Products, Inc., South Jordan, USA) were placed in the sulcus of the teeth. Then, the upper and lower jaws were scanned with an intraoral scanner, and inter-occlusal relationships and anterior and lateral movements were registered. After the final fitting, the veneers were cemented with dual-curing adhesive cement (Variolink Esthetics DC, Ivoclar Vivadent, Lichtenstein).

After three years, the patient came for a regular check-up, during which hard and soft dental deposits were removed. Ceramic replacements were documented with extraoral and intraoral photographs.

Outcome: The patient was completely satisfied with the result after the permanent cementation of fully ceramic veneers. The desired aesthetics and necessary function were achieved with this fixed prosthodontic work. The red-white aesthetics were fully satisfied.

Conclusion: After three years, fully ceramic veneers prove to be an excellent aesthetic and functional solution for managing aesthetically less valuable teeth in the anterior region. There were no visible inflammatory changes on tissue or veneers.

Keywords: Ceramic veneer; Minimal invasive preparation; Digital impression



ULOGA PRIVREMENOG NADOMJESTKA KOD IMEDIJANTE IMPLANTACIJE – PRIKAZ SLUČAJA

Nives Tea Lovrić¹, Joško Viskić²

¹ Specijalizant, Zavod za stomatološku protetiku, Klinika za stomatologiju, Klinički bolnički centar Zagreb, Zagreb, Croatia

² Zavod za fiksnu protetiku, Stomatološki fakultet Sveučilišta u Zagrebu, Zagreb, Hrvatska

Uvod: Imedijatna ugradnja implantata je kirurški zahvat ugradnje implantata u postekstrakcijsku alveolu neposredno nakon vađenja zuba. Glavne prednosti ovog pristupa su kratko vrijeme zahvata, veća udobnost za pacijenta i visoke stope uspješnosti (97-98%). Međutim, imedijatna ugradnja implantata također može dovesti do nemogućnosti procjene buduće razine mekih i tvrdih tkiva te predstavljati izazov u postizanju primarne stabilnosti implantata. Kako bi se postigli najbolji estetski rezultati kod imedijatno postavljenih implantata, preporučuje se imedijatna postava provizorija.

Postupci: Pacijent od 74 godine dolazi u ordinaciju s dubokim prijelomom korijena zuba 21. Učinjene su dijagnostičke intraoralne pretrage i CBCT, te je planirana i izvedena ekstrakcija korijena navođenom imedijatnom ugradnjom implantata i izradom provizorija. Primarna stabilnost je dobivena vrijednostima momenta sile od preko 40 Ncm. Kruna postojećeg slomljenog zuba je modificirana, postavljena u infraokluziju i ekstraoralno cementirana na prefabriciranu PEEK nadogradnju te pričvršćena vijkom na implantat.

Ishodi: Nakon 24 sata napravljen je pregled, a mjesto implantacije bilo je bez boli i otekline s visoko estetskim rezultatom. Nakon 6 mjeseci provizorij je bio na mjestu, s odgovarajućim cijeljenjem i estetskim odgovorom tvrdih i mekih tkiva.

Zaključak: Za uspjeh u implantološkom postupku i konačni estetski rezultat potrebno je planiranje te pažljiv odabir slučaja. Nakon imedijatne ugradnje implantata izrada provizorija je predvidljiv i poželjan postupak koji osigurava stabilnost i estetiku tvrdih i mekih tkiva.

Ključne riječi: Imedijatna implantacija; Privremeni nadomjestak; Navođena implantološka kirurgija; Imedijatno funkcionalno opterećenje



THE ROLE OF PROVISIONAL RESTORATION IN IMMEDIATE IMPLANT PLACEMENT – A CASE REPORT

Nives Tea Lovrić¹, Joško Viskić²

¹ Resident, Department of prosthodontics, Dental Clinic, University Hospital Centre Zagreb, Zagreb, Croatia

² Department of Fixed Prosthodontics, School of Dental Medicine, University of Zagreb, Zagreb, Croatia

Introduction: Immediate implant placement (IIP) is a surgical procedure of inserting an implant into the post-extraction alveolus immediately after tooth extraction. The main advantages of this approach include a short treatment period, increased patient comfort, and high success rates (97-98%). However, IIP could also result in an inability to estimate the future soft-tissue and hard-tissue levels and challenges in achieving primary implant stability. Therefore, to achieve the best aesthetic results around immediately placed implants, immediate provisionalisation is recommended.

Procedures: A 74 yr-old patient with a deep root fracture of tooth number 21 presented in our office. Diagnostic intraoral scans and CBCT was performed, and root extraction with fully guided immediate implant placement and provisionalisation was planned and performed. Primary stability was confirmed with torque values over 40 Ncm. The preexisting crown of the fractured tooth was modified, dissoccluded and extraorally cemented onto a prefabricated PEEK abutment and screw-retained to the implant.

Outcomes: Recall was made after 24h with the surgical site presenting with no pain or swelling and a high esthetic outcome. After 6 months, the provisional restoration was still in place, with adequate healing and esthetical hard and soft tissue response.

Conclusion: Careful planning and case selection are required to achieve success in the implantation procedure and final aesthetic results. Provisionalisation following immediate implant placement is a predictable and desirable procedure ensuring hard and soft tissue stability and esthetics.

Keywords: Immediate implantation; Provisional restoration; Guided implant surgery; Immediate functional loading



CRNI TROKUTI KAO POSLJEDICA NEKROZE PAPILA KOD PACIJENTICE S ANUG-OM – PRIKAZ SLUČAJA

Mia Haring¹, Nera Gržetić¹, Larisa Musić²

¹Studentica 6. godine, Stomatološki fakultet Sveučilišta u Zagrebu, Zagreb, Hrvatska

²Zavod za parodontologiju, Stomatološki fakultet Sveučilišta u Zagrebu, Zagreb, Hrvatska

Uvod: Akutni ulceronekrotični gingivitis (ANUG) je akutno nastupajuća, destruktivna upalna bolest gingive, uzrokovana primarno fuziformnim bakterijama i spirohetama te često posredovana narušenim odgovorom imunskog sustava domaćina. Patognomonični simptomi ANUG-a jesu izrazita bol gingive i zadah. Kliničku sliku odlike specifičan kraterasti izgled papila („negativne papile“) s pseudomembranoznom naslagom.

Postupci: Pacijentica, 22 godine starosti, dolazi na Zavod za parodontologiju s primarnom pritužbom na iznimnu bol gingive koja traje unazad 3 tjedna, ponajviše u predjelu donjih prednjih zubi. Ne navodi prisutnost sustavnih simptoma. Medicinska anamneza bila je bez osobitosti. Prigodni je pušač, a navela period intenzivnih društvenih aktivnosti (narušen uobičajeni raspored spavanja). Iz parodontološke anamneze može se zaključiti prethodna prisutnost generaliziranog gingivitisa.

Klinički se uočavaju tipične ulceronekrotične promjene u području papila gornjih i donjih prednjih zubi. Higijena ne zadovoljava. Indeks upale i dubine sondiranja nije moguće izmjeriti zbog iznimne boli pri mehaničkom podražaju gingive. Izražena halitoza (OLS=4).

Na temelju simptoma i kliničkog nalaza donesena je dijagnoza ANUG-a. Kliničko terapijsko postupanje uključilo je profesionalno nježno supragingivno uklanjanje naslaga uz prethodno lokalno anesteziiranje. Propisana kućna upotreba otopine klorheksidina (CHX 0,12%) 2x dnevno. Sustavni antibiotik nije propisan. Drastično poboljšanje parodontnog statusa nastupilo je već nakon ponovljene supragingivne instrumentacije. Pacijentica je instruirana u pravilno provođenje oralne higijene u svrhu sprječavanja ponavljanja epizode ANUG-a.

Ishodi: Nakon 3 tjedna vidljiva je potpuna rezolucija upale. Interdentalne papile gornjih prednjih zubi su djelomično izgubljene, „odrezanog“ izgleda. U donjoj čeljusti u području prednjih zubi vidljivi su potpuno prazni interdentalni prostori, tzv. crni trokuti.

Zaključak: Ako izostane kontrola rizičnih faktora, epizode ANUG-a mogu se ponavljati. Posljedice nekroze papila često su dugoročne te rezultiraju neestetskim izgledom interdentalnih područja, što može zahtijevati restaurativnu ili protetsku opskrbu.

Ključne riječi: ANUG; Crni trokuti; Gubitak papile



BLACK TRIANGLES AS A CONSEQUENCE OF PAPILLA NECROSIS IN A PATIENT WITH ANUG – A CASE REPORT

Mia Haring¹, Nera Gržetić¹, Larisa Musić²

¹Sixth year student, School of Dental Medicine, University of Zagreb, Zagreb, Croatia

²Department of Periodontology, School of Dental Medicine, University of Zagreb, Zagreb, Croatia

Introduction: Acute ulceronecrotic gingivitis (ANUG) is an acutely occurring, destructive inflammatory disease of the gingiva, caused primarily by fusiform and spirochete bacteria and often associated with an impaired immune host response. Pathognomonic symptoms of ANUG are severe gingival pain and halitosis. In addition, the clinical picture is characterised by a specific crater-like appearance of papillae (“negative papillae”) with a pseudomembranous layer.

Procedures: The patient, 22 y/o, came to the Department of Periodontology with a primary complaint of extreme gingival pain that has been present for the past 3 weeks, mainly in the area of the lower front teeth. She did not report any other systemic symptoms. Her medical history was unremarkable. She is an occasional smoker and also reported a period of intense social activities (disturbed sleeping schedule). The previous presence of generalised gingivitis could be deduced from the periodontal history.

Clinically, typical ulceronecrotic changes were observed in the area of the papillae of the upper and lower front teeth. Hygiene was unsatisfactory. The index of inflammation and probing depth could not be measured due to the extreme pain upon mechanical stimulation of the gingiva. Strong halitosis was present (OLS=4).

Based on the symptoms and clinical findings, ANUG was diagnosed. Clinical treatment included professional, gentle supragingival plaque removal in local anaesthesia. She was prescribed a chlorhexidine solution (CHX 0.12%) 2x a day for at-home use. A systemic antibiotic was not prescribed. She presented with a drastic improvement in the periodontal status already after repeated supragingival instrumentation. The patient was instructed in proper oral hygiene to prevent a repeated ANUG episode.

Outcome: A complete resolution of the inflammation is visible after 3 weeks. The interdental papillae of the upper front teeth were partially lost, presenting with a “cut off” appearance. In the lower jaw, in the area of the front teeth, completely empty interdental spaces were visible, the so-called black triangles.

Conclusion: Without risk factor control, ANUG episodes may recur. The consequences of papilla necrosis are often long-term, resulting in an unaesthetic appearance of the interdental areas, which may require restorative or prosthetic treatment.

Keywords: ANUG; Black triangles; Loss of papilla



POBOLJŠANJE CRVENE ESTETIKE U SLUČAJU GENERALIZIRANOG GINGIVITISA JEDNOSTAVNIM KLINIČKIM POSTUPCIMA - PRIKAZ SLUČAJA

Lucija Jambrešić¹, dr.sc. Larisa Musić²

¹ Studentica 5. godina, Stomatološki fakultet Sveučilišta u Zagrebu, Zagreb, Hrvatska

² Zavod za parodontologiju, Stomatološki fakultet Sveučilišta u Zagrebu, Zagreb, Hrvatska

Uvod: Gingivitis jest reverzibilno upalno stanje gingive uzrokovano bakterijskim biofilmom, bez gubitka kliničkog pričvrsta. Odlikuje ga i klinička promjena izgleda marginalne i papilarne gingive koja postaje eritematozna i edematozna.

Postupci: Ovaj prikaz slučaja opisuje 14-godišnju pacijenticu koja na Zavod za parodontologiju dolazi jer unazad par mjeseci primjećuje krvarenje iz gingive prilikom četkanja zubi, a majka napominje i prisutnost halitoze. Osobna anamneza je bez osobitosti. Iz parodontološke obiteljske anamneze se izdvaja da majka boluje od parodontitisa. Kliničkim pregledom utvrđena je eritematozna gingiva, kao i edem papila i marginalnih tkiva gingive, uz mogućnost odmicanja papilarne gingive. Prisutno je generalizirano krvarenje (FMBS=38%). Higijena ne zadovoljava (FMPS=54%). Dubine sondiranja su unutar fizioloških granica, a radiografska analiza pokazuje fiziološku razinu alveolarne kosti. Halitoza je organoleptički procijenjena kao prisutna i umjerenog intenziteta (OLS=3). Pacijentici je dijagnosticiran generalizirani gingivitis induciran plakom.

Terapijski postupak rađen je prema kliničkom protokolu Guided Biofilm Therapy (GBT). U svrhu vizualizacije biofilma korišten je plak revelator (EMS Biofilm Discloser). Na temelju toga pacijentici su dane upute o oralnoj higijeni uz demonstraciju i vježbu korištenja interdentalnih četkice i električne četkice. Zatim je učinjeno detaljno profesionalno uklanjanje prisutnih mekih (EMS Airflow, Plus prah) i tvrdih (EMS Piezon) naslaga. Navedeni je terapijski postupak također ponavljen pri sljedećem dolasku.

Ishodi: Prilikom finalnog kontrolnog pregleda ocijenjeno je poboljšanje parodontnog statusa. Krvarenje je značajno smanjeno, a poboljšanje oralne higijene vidljivo je nakon ponovnog prikazivanja biofilma plak revelatorom. Halitoza bila je odsutna (OLS=0). Klinički izgled gingive je uvelike poboljšan, uz normalan izgled marginalne i papilarne gingive, adekvatne boje i primjerene teksture.

Zaključak: Pubertet je faza života u kojoj je gingivitis visoko prevalentan, često povezan s nedostatkom motivacije za oralnu higijenu i posredovan spolnim hormonima. Patologije usne šupljine, pa tako i gingivitis i halitoza, mogu negativno utjecati na psihološku dobrobit adolescenata. S obzirom na obiteljsku parodontološku anamnezu opisane pacijentice te povezanost između gingivitisa i parodontitisa potreban je trud i motivacija kako od strane stomatološkog tima, tako i od strane pacijenta, da bi se spriječilo daljnje napredovanje bolesti.

Ključne riječi: Gingivitis; Guided biofilm therapy; Biofilm; Crvena estetika



THE IMPROVEMENT OF RED AESTHETICS IN THE CASE OF GENERALISED GINGIVITIS WITH SIMPLE CLINICAL PROCEDURES – A CASE REPORT

Lucija Jambrešić¹, dr.sc. Larisa Musić²

¹Fifth year student, School of Dental Medicine, University of Zagreb, Zagreb, Croatia

²Department of Periodontology, School of Dental Medicine, University of Zagreb, Zagreb, Croatia

Introduction: Gingivitis is a reversible inflammatory condition of the gingiva caused by bacterial biofilm, without clinical attachment loss. It is also characterised by the change in the appearance of the marginal and papillary gingiva, which become erythematous and edematous.

Procedures: This case report describes a 14-year-old patient who came to the Department of Periodontology. She noticed gingival bleeding when brushing her teeth in recent months, while her mother also noted the presence of halitosis. Her personal medical history was unremarkable. The periodontal family history highlighted that the mother suffers from periodontitis. The clinical examination revealed erythematous gingiva and oedema of the papillae and marginal tissues of the gingiva, with the possible physical displacement of the papillary gingiva. Generalised bleeding was present (FMBS=38%). Hygiene was unsatisfactory (FMPS=54%). Probing depths were within physiological limits, and radiographic analysis revealed physiological alveolar bone level. Halitosis was organoleptically assessed as present and of moderate intensity (OLS=3). The patient was diagnosed with biofilm-induced generalised gingivitis.

The therapeutic procedure was performed according to the Guided Biofilm Therapy (GBT) clinical protocol. A plaque discloser (EMS Biofilm Discloser) was used to visualise the biofilm. Based on the clinical findings, the patient was given instructions on oral hygiene with a demonstration and practice of using an interdental and electric brush. Finally, a thorough professional removal of the present soft (EMS Airflow, Plus powder) and hard (EMS Piezon) deposits was done. The mentioned therapeutic procedure was also repeated at the next visit.

Outcomes: An improvement in the periodontal status was noted during the final control examination. Bleeding was significantly reduced, and the improvement in oral hygiene was visible after re-disclosing the biofilm. Halitosis was absent (OLS=0). In addition, the clinical appearance of the gingiva was greatly improved, with a normal appearance of the marginal and papillary gingiva, adequate colour and appropriate texture.

Conclusion: Puberty is a phase of life in which gingivitis is highly prevalent, often associated with a lack of motivation for oral hygiene and mediated by sex hormones. Pathologies of the oral cavity, including gingivitis and halitosis, can negatively affect adolescents' psychological well-being. Considering the family history of periodontitis of the described patient and the connection between gingivitis and periodontitis, effort and motivation are needed both on the part of the dental team and the patient's part to prevent further progression of the disease.

Keywords: Gingivitis; Guided biofilm therapy; Biofilm; Red aesthetics



KOMPOZITNI SPLINT / MOST OJAČAN VLAKNIMA KOD PARODONTOLOŠKI KOMPROMITIRANOG PACIJENTA – PRIKAZ SLUČAJA

Ana Đerek¹, Larisa Musić²

¹ Studentica 5. godine, Stomatološki fakultet Sveučilište u Zagrebu, Zagreb, Hrvatska

² Zavod za parodontologiju, Stomatološki fakultet Sveučilište u Zagrebu, Zagreb, Hrvatska

Uvod: Uznapredovali gubitak kosti uslijed parodontitisa uzrokom je povećane pomičnosti zahvaćenih zubi. Ona može negativno utjecati na žvačnu i fonetsku funkciju te psihološku dobrobit pojedinca. Terapijskim postupkom izrade parodontnog splinta (šine / udlage) patološki pomični zubi mogu se imobilizirati vezivanjem za susjedne zube. Ovisno o vremenu i metodi splintiranja, ono se dijeli na privremeno, polutrajno i trajno, odnosno mobilno i fiksno.

Postupci: Ovaj prikaz slučaja opisuje pacijenta (rođ. 1952.) koji je prvotno ušao u terapijski postupak liječenja parodontitisa na Zavodu za parodontologiju 2015. godine (Dg/ Generalizirani parodontitis stadij III, razred C). Boluje od loše kontroliranog T2DM. 2018. donji prednji zubi imobilizirani su kompozitnim splintom ojačanim vlaknima. Zbog napredovanja bolesti i opetovanih apscesa u području zubi 41 i 42, amputirani su korijeni navedenih zubi, dok su krune zadržane unutar splinta kao privremeno rješenje, do planirane izrade trajnog fiksnog protetskog rada (2019.) Nedugo po zahvatu pacijent se prestaje javljati na redovite kontrolne preglede u sklopu potporne terapije. U travnju 2023. godine pacijent dolazi zbog odvajanja zubi 41 i 42 iz splinta te ih donosi pohranjene u zaštitnoj kutijici. Pacijent izražava i daljnju nemogućnost izrade trajnog protetskog rada te se pristupa izradi novog kompozitnog splinta (mosta) uz ugradnju krune zubi u isti. Uklanja se sav stari materijal s prisutnih zubi. Krune zubi 41 i 42 su očišćene te je učinjena njihova značajnija preparacija radi povećanja adhezivne površine. Po jetkanju, ispiranju i sušenju nanesen je adheziv (Single Bond Universal, 3M ESPE AG, Seefeld, Njemačka). Na prvi sloj krutog kompozita (Filtek Universal) nanosena je i prilagođena traka polietilenskih vlakana (Ribbond, Inc., Seattle, SAD), prethodno pripremljena prema uputama proizvođača. Za finalni sloj korišten je kombinacija krutog i tekućeg (Filtek Supreme Flowable) kompozita. Provjereni su kontakti te je provedena završna obrada.

Ishodi: Izgled finalne restauracije bio je i više nego estetski prihvatljiv, uz iznimno zadovoljstvo pacijenta.

Zaključak: Kompozitni splint ojačan vlaknima vrlo je dobro rješenje kako za imobilizaciju zubi, tako i u funkciji mosta kojima se nadoknađuje estetika i izgubljene funkcije. Ovaj tip restauracija može vremenski premašiti očekivanu trajnost.

Ključne riječi: Parodontitis; Parodontni splint; Kompozitni splint ojačan vlaknima; Gubitak zubi



FIBRE-REINFORCED COMPOSITE SPLINT / BRIDGE IN A PERIODONTALLY-COMPROMISED PATIENT – A CASE REPORT

Ana Đerek¹, Larisa Musić²

¹ Fifth year student, School of Dental Medicine, University of Zagreb, Zagreb, Croatia

² Department of Periodontology, School of Dental Medicine, University of Zagreb, Zagreb, Croatia

Introduction: Advanced bone loss due to periodontitis increases teeth mobility. It can negatively affect chewing and phonetic functions and psychological well-being. Periodontal splinting immobilises pathologically mobile teeth by connecting them to adjacent teeth. Based on duration and splinting method, they are classified as temporary, semi-permanent and permanent, or removable and fixed, respectively.

Procedures: This case report describes a patient (b. 1952) initially enrolled at the Department of Periodontology in 2015 for treatment of periodontitis (Dg/Generalised periodontitis stage III, grade C). He suffers from poorly controlled T2DM. In 2018, the lower front teeth were immobilised with a fibre-reinforced composite splint. Due to the disease's progression and repeated abscesses around teeth 41 and 42, their roots were amputated (2019). Their crowns remained within the periodontal splint as a temporary solution until the permanent fixed prosthetic work was done. The patient stopped attending regular clinical SPT check-ups not long after the procedure. In April 2023, the patient returned to the clinic as 41 and 42 fell out of the splint, having stored them in a protective box. As the patient stated his inability to start permanent prosthetic treatment, a new composite splint (bridge) was planned, including 41 and 42 crowns. The old material was removed. The 41 and 42 crowns were cleaned and prepared significantly to increase the adhesive surface. After etching, rinsing and drying, an adhesive (Single Bond Universal, 3M ESPE AG, Seefeld, Njemačka) was applied. A strip of polyethylene fibres (Ribbond, Inc., Seattle, USA), previously prepared according to the manufacturer's instructions, was applied to the first layer of conventional composite (Filtek Universal). A combination of conventional and flowable (Filtek Supreme Flowable) composite was used for the final layer. Occlusion was checked and final adjustments were made.

Outcomes: The appearance of the final restorations was more than aesthetically acceptable, and the patient was extremely satisfied.

Conclusion: A fibre-reinforced composite splint is a very good solution, both for tooth immobilisation and as a bridge, restoring aesthetics and lost functions. This type of restoration may exceed the expected durability in time.

Keywords: Periodontitis; Periodontal splint; Fibre-reinforced composite splint; Tooth loss



UTJECAJ EDUKACIJSKE INTERVENCIJE NA IZMJENU POSTAVKI PRIVATNOSTI PROFILA NA DRUŠTVENIM MREŽAMA STUDENATA MEDICINE I DENTALNE MEDICINE

Joško Viskić¹, Marko Marelić², Danko Relić², Kristijan Sedak³, Tea Vukušić Rukavina²

¹ Stomatološki fakultet Sveučilišta u Zagrebu, Hrvatska

² Škola narodnog zdravlja Andrija Štampar, Medicinski fakultet Sveučilišta u Zagrebu, Hrvatska

³ Odjel za komunikologiju, Katoličko sveučilište u Zagrebu, Hrvatska

Uvod: Studenti medicinskih profesija učestali su korisnici društvenih mreža (DM). Cilj ovoga rada bio je istražiti učestalost i razloge zbog kojih studenti medicine Medicinskog fakulteta i dentalne medicine Stomatološkog fakulteta Sveučilišta u Zagrebu, polaznici jednosemestralnih izbornih/elektivnih predmeta, izmjenjuju postavke privatnosti svojih profila na DM te utjecaj edukacijske intervencije na promjenu postavki privatnosti profila na DM.

Materijali i metode: Istraživanje „pred-test post-test zatečenih grupa“ provedeno je korištenjem online upitnika na uzorku studenata medicine i dentalne medicine na početku i na kraju izvođenja nastave (T1 i T2). Upitnik je sadržavao instrument o postavkama privatnosti. Deskriptivna statistika i McNemar test provedeni su prilikom obrade podataka.

Rezultati: Oba puta upitnik je ispunilo 53 studenata (16 studenata medicine i 37 studenata dentalne medicine). Od svih ispitanika, samo jedan nije koristio DM, te je 52 ušlo u finalni uzorak. Nakon odslušane nastave statistički značajno više studenata izmijenilo je postavke privatnosti na DM koju koriste, najviše u odnosu na one koji to nisu učinili ili ne znaju jesu li to učinili (T1 61,5 % vs. T2 84,6 %, $p=.012$). Od 32 studenta koji su odgovori pozitivno na pitanje o promjeni postavki, ne postoji statistički značajna razlika u razlozima promjene postavki privatnosti. Najčešće su studenti mijenjali postavke privatnosti zbog „zaštite osobnih podataka od nepoznatih osoba“ te zbog „nepovjerenja u sigurnost početnih postavki privatnosti društvenih mreža“. Iako nema statistički značajne razlike, u česticama „zbog savjeta kolega i prijatelja“ (T1 15,6 % vs. T2 28,1 %, $p=.289$) i „rizika da bi njihov profil mogao vidjeti trenutni ili budući poslodavac“ (T1 21,9 % vs. T2 43,8 %, $p=.289$) vidi se porast nakon nastave.

Zaključak: Edukacijska intervencija je imala statistički značaj utjecaj na aktivnost promjene postavki privatnosti profila na DM. Najzastupljeniji razlozi promjene bili su nepovjerenje u sigurnost početnih postavki te zaštita osobnih podataka od nepoznatih osoba.

Zahvala: Ovo istraživanje dio je UIP 2017-05-2140 projekta Hrvatske zaklade za znanosti „Opasnosti i prednosti društvenih mreža: e-profesionalizam zdravstvenih djelatnika - SMePROF“

Ključne riječi: Društvene mreže; Profesionalizam; Medicina; Dentalna medicina; Studenti



THE IMPACT OF AN EDUCATIONAL INTERVENTION ON CHANGES TO PRIVACY SETTINGS OF MEDICAL AND DENTAL STUDENTS' SOCIAL MEDIA PROFILES

Joško Viski¹, Marko Marelić², Danko Relić², Kristijan Sedak³, Tea Vukušić Rukavina²

¹ Faculty of Dental Medicine, University of Zagreb, Croatia

² School of Public Health Andrija Štampar, School of Medicine, University of Zagreb, Croatia

³ Department of Communication Sciences, Catholic University of Croatia

Introduction: Students in the healthcare profession are frequent social media (SM) users. This study aimed to investigate the frequency and reasons why students of medicine at the School of Medicine and students of dental medicine at the School of Dental Medicine, University of Zagreb, change the privacy settings of their SM profiles and the impact of an educational intervention (a one-semester elective course) on changes of the profile privacy settings.

Materials and methods: The "one group pre-test post-test design" study was conducted using an online questionnaire on a sample of medical and dental medicine students at the beginning and the end of the course (T1 and T2). The questionnaire contained an instrument on privacy settings. Descriptive statistics and McNemar's test were used for data analysis.

Results: The questionnaire was completed by 53 students both times (16 medical and 37 dental medicine). Only one participant did not use SM, leaving 52 in the final sample. After the course, significantly more students changed their privacy settings on the SM they use the most, compared to those who did not or were unsure if they did (T1 61.5% vs T2 84.6%, $p=.012$). Among the 32 students who answered positively to the question about changing their settings, there was no significant difference in the reasons for doing so. The most common reasons were "protecting personal information from unknown persons" and "not trusting the security of initial privacy settings on social media platforms". Although there were no statistically significant differences, there was an increase in the percentage of students who cited "advice from colleagues and friends" (T1 15.6% vs T2 28.1%, $p=.289$) and "fear of a current or future employer seeing their profile" (T1 21.9% vs T2 43.8%, $p=.289$) after the course.

Conclusion: The educational intervention had a statistically significant impact on the change of privacy settings on SM. The most common reasons for changing were protecting personal information from unknown persons or not trusting the security of initial privacy settings on SM platforms.

Acknowledgement: This study is part of a project funded by the Croatian Science Foundation UIP 2017-05-2140 "Dangers and benefits of social networks: E-Professionalism of healthcare professionals – SMePROF".

Keywords: Social media; Professionalism; Medicine; Dental medicine; Students



PREKRIVANJE GINGIVNIH RECESIJA KONVENCIONALNIM I MODIFICIRANIM SLOBODNIM GINGIVNIM TRANSPLANTATOM – (NE)MOGUĆE?

Larisa Musić¹, Ivan Puhar¹, Domagoj Vražić^{1,2}

¹ Zavod za parodontologiju, Stomatološki fakultet Sveučilišta u Zagrebu, Zagreb, Hrvatska

² Zavod za parodontologiju, Klinika za stomatologiju, Klinički bolnički centar Zagreb, Zagreb, Hrvatska

Uvod: Pojas keratiniziranog tkiva definiran je kao udaljenost je od marginalnog gingivnog ruba do mukogingivnog spojišta, tj. početka nekeratinizirane alveolarne mukoze. Keratinizirani pojas <2 mm često se navodi kao rizični faktor za nastanak gingivnih recesija zbog otežanog ili nemogućnosti održavanja oralne higijene. Nakupljanje biofilma u takvim slučajevima pogoduje nastajanju i produbljivanju recesije, koji u zatvorenom krugu, dalje doprinosi sužavanju pojasa keratiniziranog tkiva, tzv. mukogingivni problem. Slobodni gingivni transplantat (SGT) najčešće je indicirani zahvat za proširenje keratiniziranog pojasa, međutim uspješnost prekrivanja korijena iznimno je varijabilna te mu stoga to nije primarna indikacija.

Postupci: Ovaj prikaz slučaja prikazuje ishode operacija dvije pacijentice sa sličnim, dubokim solitarnim recesijama na zubu 31. Pacijentica 1 liječena je klasičnim postupkom SGT-a. Nakon preparacije primateljskog mjesta, transplantat uzet s nepca učvršćuje se pojedinačnim i križnim šavovima. Nakon 2 tjedna cijeljenja vidljiva je parcijalna nekroza centralnog dijela transplantata. Nakon 1 i 6 mjeseci vidljiva je maturacija transplantata i puzajući pričvrstak, uz daljnju prisutnost recesije koja zahtjeva sekundarni zahvat. Pacijentica 2 liječena je novijom tehnikom modificiranog SGT-a. Nakon klasične pripreme primateljskom mjesta, preparira se režanj poludebljine u apikalnom dijelu operativnog polja i prebacuje prema koronarno. Učvršćuje se resorptivnim koncem, a preko njega se učvršćuje SGT uzet s nepca. Nakon 2 tjedna vidljivo je gotovo potpuno prekrivanje korijena uz zadebljanje transplantata. 3 mjeseca transplantat je maturirao te je prisutna minimalna recesija od 0,5mm koja ne zahtjeva daljnje kirurško zbrinjavanje.

Ishodi: Tehnika modificiranog SGT-a novija je tehnika kojom se osiguraju bolja krvna opskrba transplantata, manje skupljanje tkiva i veći izgledi za potpunim prekrivanjem korijena.

Zaključak: Modifikacijom tehnike SGT-a ova tehnika ponovno dobiva važnu i vrijednu ulogu u ne samo proširenju keratiniziranog pojasa, već i prekrivanju recesija.

Ključne riječi: Slobodni gingivni transplantat; Modificirani slobodni gingivni transplantat; Pojedinačna recesija



GINGIVAL RECESSION COVERAGE WITH CONVENTIONAL AND MODIFIED FREE GINGIVAL GRAFT – (IM)POSSIBLE?

Larisa Musić¹, Ivan Puhar¹, Domagoj Vražić^{1,2}

¹ Department of Periodontology, School of Dental Medicine, University of Zagreb, Zagreb, Croatia

² Department of Periodontology, Dental Clinic, University Hospital Centre Zagreb, Zagreb, Croatia

Introduction: The keratinized tissue width is defined as the distance from the gingival margin to the mucogingival junction, i.e., the beginning of the non-keratinized alveolar mucosa. A keratinized tissue width of <2 mm is often proposed as a risk factor for gingival recession, as it may pose a challenge or make it impossible to maintain proper oral hygiene. Accumulation of biofilm in such cases contributes to the formation and deepening of a recession, which further contributes to the narrowing of the keratinized tissue, known as the „mucogingival problem“. Free gingival graft (FGG) is the most commonly indicated procedure for increasing the keratinized tissue width. However, its effectiveness in achieving root coverage can vary greatly, and therefore, root coverage is not typically the primary objective of this procedure.

Procedures: This case report presents the outcomes of surgeries performed on two patients with similar deep solitary recessions on tooth 31. Patient 1 was treated with the conventional FGG. After preparing the recipient site, a graft taken from the palate was secured with interrupted and cross sutures. After 2 weeks of healing, partial necrosis of the central part of the graft was noticed. At 1 and 6 months, graft maturation and creeping attachment were visible, but there was still some recession present which required an additional procedure. Patient 2 was treated with the newer modified FGG technique. After preparing the recipient site, a partial thickness flap was prepared in the apical part of the surgical field and flipped coronally. It was secured with resorbable sutures, and the FGG taken from the palate was secured over it. After 2 weeks, almost complete root coverage was visible, along with graft thickening. At 3 months, the graft had matured, and minimal recession of 0.5 mm was present, which did not require further surgical treatment.

Outcomes: The modified FGG technique is a recently developed method that offers several advantages, such as better blood supply to the graft, less shrinkage, and an increased likelihood of complete root coverage.

Conclusion: This modified FGG technique has become an important and valuable approach not only for expanding the keratinized tissue width but also for recession coverage.

Keywords: Free gingival graft; Modified free gingival graft; Single recession



STABILIZACIJSKE UDLAGE KAO ZAŠTITNO SREDSTVO ZA FIKSNE PROTETSKE NADOMJESTKE

Dujam Mario Tudor¹, Amir Ćatić², Lidija Bagić³

¹ Klinika za stomatologiju KBC-a Zagreb, Zagreb, Hrvatska, specijalizant stomatološke protetike

² Zavod za fiksnu protetiku, Stomatološki fakultet Zagreb Sveučilišta u Zagrebu, Klinika za stomatologiju KBC-a Zagreb, Zagreb, Hrvatska

³ Studentica 5. godine, Stomatološki fakultet Zagreb Sveučilišta u Zagrebu, Zagreb, Hrvatska

Uvod: Funkcijski poremećaji poput bruksizma i bruksomanije čest su razlog oštećenja različitih vrsta nadomjestaka u stomatološkoj protetici. Kod dvoslojnih sustava (npr. metal-keramika) dolazi do lomova obložne keramike koji mogu biti unutar strukture (eng. chipping; kohezivni tip) i na granici dva materijala (delaminacija; adhezivni tip) pri čemu se dentalna keramika u potpunosti odvaja od nosivnog dijela konstrukcije. Protetsko pravilo da okluzalna morfologija nadomjestka mora biti u skladu s okluzalnom morfologijom ostalih pacijentovih zubi uvjet je izrade primjerenog protetskog nadomjeska, i način na koji se značajno reducira mogućnost loma. Ipak, čak i kad su zadovoljeni svi kriteriji izrade nadomjestka, može doći do loma keramike zbog parafunkcija i prekomjernih sila u žvačnom sustavu.. Učinkovit način da se navedeno spriječi je izrada zaštitne stabilizacijske udlage čija je uloga smanjiti opterećenja i naprezanja po jedinici površine i zaštititi zube i protetske nadomjeske. Ovdje je prikazan jedan takav slučaj iz svakodnevne prakse.

Postupci: Na Zavod za fiksnu protetiku Stomatološkog fakulteta Sveučilišta u Zagrebu došla je pacijentica od 67 godina s nedostatkom zuba 36. Napravljen je intraoralni i rtg pregled, čime je utvrđena potreba za endodontskom revizijom zuba 26 i brusne fasete na pretkutnjacima lijeve i desne strane. Plan terapije uključivao je izradu metal-keramičkih mostova 34-35-0-37, te 24-0-26 i izradu stabilizacijske udlage nakon završetka fiksnoprotetske terapije.

Ishodi: Udlaga je usklađena s pacijentovom statičkom i dinamičkom okluzijom te joj je potom predana uz upute vezane za održavanje i potrebno vrijeme nošenja. Na kontrolnim pregledima nije utvrđeno oštećenje protetskih nadomjestaka niti dodatno oštećenje prirodnih zubi. Pacijent je udlagu redovito nosio i održavao prema uputama koje je dobio.

Zaključak: Stabilizacijska udlaga izrađuje se s ciljem da se smanji djelovanje prekomjernih sila na zube, čime se smanjuje trošenje tvrdog zubnog tkiva, ali i produžuje strukturna trajnost fikсно-protetskih nadomjestaka. Istovremeno, udlaga stabilizira položaj kondila u temporomandibularnom zglobu te time smanjuje napetost i sile žvačnih mišića.

Ključne riječi: Stabilizacijska udlaga; Fiksno-protetski nadomjestak; Lom dentalne keramike



STABILIZATION SPLINTS AS A PROTECTIVE MEASURE FOR FIXED PROSTHODONTIC APPLIANCES

Dujam Mario Tudor¹, Amir Ćatić², Lidija Bagić³

¹ Resident, Department of Prosthodontics, Dental Clinic, University Hospital Centre Zagreb, Zagreb, Croatia

² Department of Fixed Prosthodontics, School of Dental Medicine, University of Zagreb; Department of Prosthodontics, Dental Clinic, University Hospital Center Zagreb, Zagreb, Croatia

³ 5th year student, School of Dental Medicine, University of Zagreb, Zagreb, Croatia

Introduction: Functional disorders such as bruxism and bruxomania are common reasons of damage to various types of appliances in dental prosthodontics. In heterogenic systems (e.g. metal-ceramics), there are fractures of veneering ceramic which can occur within the structure (chipping; cohesive type) and at the interface between the two materials (delamination; adhesive type), causing dental ceramic to completely separate from the base layer of the construction. The prosthodontic rule that the occlusal morphology of the replacement must be in line with the occlusal morphology of the patient's other teeth is a prerequisite for making an appropriate prosthodontic appliance and significantly reduces the risk of fracture. However, even when all the criteria appliance production are met, ceramic fractures may occur, often due to parafunctions and excessive forces in the masticatory system. An effective way to prevent this is to make a protective stabilization splint, whose role is to reduce the load and stress per surface area hence protecting teeth and prosthodontic appliances. This is a presentation of a case report from everyday practice.

Procedures: A 67-year-old patient with a missing tooth 36 came to the Department of Fixed Prosthodontics, School of Dental Medicine, University of Zagreb. An intraoral and radiographic examination was performed, which determined the need for an endodontic revision of the tooth 26 and the presence of grinding of the premolars on the left and right sides. The treatment plan included making metal-ceramic FPDs 34-35-0-37, as well as 24-0-26, and making a stabilization splint after completing the fixed prosthodontic therapy.

Outcomes: The splint was adjusted to the patient's static and dynamic occlusion and then handed over to the patient with instructions on maintenance and necessary wearing time. No damage to FPDs or additional damage to natural teeth was found in follow-up examinations. The patient wore and maintained the splint regularly according to the instructions given.

Conclusion: A stabilization splint is made with the aim of reducing the effect of excessive forces on teeth, thus reducing the wear of hard dental tissue and prolonging the structural durability of fixed prosthodontic replacements. At the same time, the splint stabilizes the position of the condyle in the temporomandibular joint, reducing tension and forces on the masticatory muscles.

Keywords: Stabilization splint; Fixed prosthodontic replacement; Fracture of dental ceramic



ANALIZA UČINKOVITOSTI RAZLIČITIH TEHNIKA U KREIRANJU PRIVREMENIH NAKNADA

Anđela Stevčević¹, Miodrag Šćepanović²

¹ Stomatološki fakultet Sveučilišta u Beogradu, Beograd, Srbija

² Klinika za stomatološku protetiku stomatološkog fakulteta Sveučilišta u Beogradu, Beograd, Srbija

Uvod: Uvođenjem novih materijala i tehnika u izradi privremenih nadomjestaka, suvremena stomatologija nastavlja postizati sve veću preciznost i sve bolje estetske rezultate. Idealno bi bilo rubno zaptivanje između granice brušenog zuba i privremenog nadomjestka, bez razmaka i minimalnog prostora za cement u dijelu krune. Cilj rada bila je analiza različitih digitalnih tehnika i materijala za izradu privremenih krunica, kao i analiza preciznosti postavljanja nadoknada na demarkaciji prepariranog zuba.

Materijal i metode: Analiza će se provoditi na printanim modelima izrađenim u maksimalnoj rezoluciji na Asiga printeru, a na temelju intraoralnog skena realiziranog skenerom Trios 3Shape koristit će se isti radni model za sve privremene krunice. Skenirat će se model čeljusti s brušenim zubom, antagonistima i kontaktnim površinama u središnjem okluzijskom položaju. Virtualni model privremene krunice bit će dizajniran u softveru 3Shape i dizajn će biti isti za sve restauracije. Privremeni nadomjesci 1 i 2 izrađuju se na CNC stroju VHF K5 od: polimetil metakrilata (PMMA) i HIPC (breCAM HIPC) materijala; 3. u 3D printeru Asiga MAX UV tehnika selektivne polimerizacije fotoosjetljive smole (DLP- Digital Light Processing), korištenjem Asiga DentaTOOTH u rezoluciji od 25 mikrona. Na modelu će se pomoću mikroskopa analizirati točnost pristajanja privremenih nadomjestaka, a mikroskopom i mjernim instrumentom registrirati i izmjeriti dimenzije zazor. Eksperiment će se izvoditi na Klinici za stomatološku protetiku i restaurativnu stomatologiju Stomatološkog fakulteta Sveučilišta u Beogradu.

Rezultati: Nakon analize nadomjestaka pod mikroskopom i mjerenja razmaka, najveću preciznost pokazao je nadomjestak izrađen na 3D printeru, zatim PMMA, a najmanju nadomjestak izrađen od HIPC materijala, izrađen na CNC stroju.

Zaključak: Tehnika 3D printanja pokazala je superiornost u smislu preciznosti u odnosu na CNC strojnu tehniku rezanja.

Ključne riječi: Digitalne proizvodne tehnologije; 3D ispis; CNC stroj; Privremene krunice; PMMA; HIPC



ANALYSIS OF THE EFFECTIVENESS OF DIFFERENT TECHNIQUES IN CREATING PROVISIONAL RESTORATIONS

Anđela Stevčević¹, Miodrag Šćepanović²

¹ Faculty of Dental Medicine University of Belgrade, Belgrade Serbia

² Clinic for Dental Prosthetics, Faculty of Dental Medicine, University of Belgrade, Belgrade, Serbia

Introduction: By introducing new materials and techniques in the fabrication of provisional restorations, modern dentistry continues to achieve more precision and better aesthetic results. Ideally, there should be marginal sealing between the demarcation of the filed tooth and the temporary restoration. This study aimed to analyse different digital techniques and materials for making temporary crowns and analyse the accuracy of placing provisional on the demarcation of the prepared tooth.

Material and methods: The analysis will be carried out on printed models made in maximum resolution on the Asiga printer. Based on the intraoral scan made with the Trios 3Shape scanner, the same working model will be used for all provisionals. A jaw model with a prepared tooth, antagonists and contact surfaces in the central occlusion will be scanned. The virtual model of the temporary crown will be designed in 3Shape software. Temporary restorations 1. and 2. will be cut on CNC machine VHF K5 from: PMMA and from HIPC; 3. in the 3D printer Asiga MAX using the UV technique of selective polymerisation of photosensitive resin in a resolution of 25 microns. We will analyse the accuracy of placing temporary crowns on the model using a microscope, while the dimensions of the gap will be registered and measured using a microscope and a measuring instrument. The experiment will be performed at the Clinics for Dental Prosthetics and Restorative Dentistry of the Faculty of Dental Medicine, University of Belgrade.

Results: After observing under the microscope and measuring the gap, the highest precision was shown by the restoration made on a 3D printer, followed by PMMA, and the lowest precision was shown by the restoration made of HIPC material produced on a CNC machine.

Conclusion: The 3D printing technique showed superiority in terms of precision compared to the CNC machine cutting technique.

Keywords: Digital manufacturing technologies; 3D printer; CNC machine; Temporary crowns; PMMA; HIPC



INTRAORALNI SKENER ILI OTISNA MASA, ŠTA JE BRŽE?

Ilija Vešković¹, Miodrag Šćepanović²

¹ Stomatološki fakultet Sveučilišta u Beogradu, Beograd, Srbija

² Klinika za stomatološku protetiku Stomatološkog fakulteta Sveučilišta u Beogradu, Beograd, Srbija

Uvod: Konvencionalni otisak predstavlja zapis takiva u negativu uzet otisnim materijalima i kašikom.. Digitalni otisci dobijaju se postupkom skeniranja zubnih lukova intraoralnim skenerima. Cilj ispitivanja je usporedno analizirati potrebno vrijeme za konvencionalno i digitalno otiskivanje u postupku izrade solo krune na brušenom zubu i na implantatu u regiji premolara gornje vilice.

Materijal i metode: Analiza je izvršena simulacijom procesa rada na dva para printanih modela fiksiranih u artikulatorku. Na prvom paru modela, u gornjoj vilici nalazi se preparisan zub u regiji premolara. Na drugom paru modela, u istoj regiji gornje vilice nalazi se implantat replika sa privremenom krunom i umjetnom silikonskom gingivom koja omogućava simulaciju registriranja forme izlaznog profila gingive. Protokoli analognog i digitalnog otiskivanja provedeni su za obje indikacije. Prilikom konvencionalnog, jednovremenog dvofaznog otiskivanja gornjih modela korišten je Zhermack adicijski silikon, kombinacijom putty i light body konzistencije. Za otiskivanje donjih modela korišten je Zhermack Tropic alginat, a za registraciju zagrižaja Zhermack bite silikon. Otisci su realizirani standardnom kašikom, tehnikom sa dva konca. Skeniranje je vršeno Trios 3Shape 3 intraoralnim skenerom. Ukupno vreme otiskivanja konvencionalnim pristupom mereno je od faze odabira podesne kašike, zaključno sa dezinfekcijom otisaka. Digitalni protokoli mereni su od momenta otvaranja naloga pacijenta do slanja dokumenta u laboratoriju. Vrijednosti utrošenog vremena poređene su u odnosu na kompletnu proceduru. Eksperiment je proveden na Razvojno-istraživačkom implantološkom centru Stomatološkog fakulteta Sveučilišta u Beogradu.

Rezultati: Dobijeni rezultat za model sa brušenim zubom iznosio je 21:02s za analogni protokol, a 16:27s za digitalni. Kada je reč o indikaciji za solo krunicu na implantatu konvencionalnim pristupom utrošeno je 16:34s, dok je digitalnim bilo potrebno 9:44s.

Zaključak: Digitalni protokol otiskivanja je za ispitivane indikacije pokazao superiornost u odnosu na konvencionalne metode kada je utrošeno vrijeme u pitanju.

Ključne riječi: Otisak; Intraoralni skener; Digitalni otisak



INTRAORAL SCANNER OR IMPRESSION MATERIAL, WHICH IS FASTER?

Ilija Vešković¹, Miodrag Šćepanović²

¹ Faculty of Dentistry, University of Belgrade, Belgrade, Serbia

² Clinic for Dental Prosthetics, Faculty of Dentistry, University of Belgrade, Belgrade, Serbia

Introduction: Conventional impressions involve taking a negative record of the tissue using impression materials and a tray. Digital impressions are obtained by scanning dental arches using intraoral scanners. The study aims to analyze the time required for conventional and digital impressions in fabricating a single crown on a prepared tooth and on an implant in the premolar region of the upper jaw.

Materials and Methods: The analysis was performed by simulating the work process on two pairs of printed models fixed in an articulator. In the first pair of models, a prepared tooth is located in the premolar region of the upper jaw. In the second pair of models, in the same region of the upper jaw, there is an implant replica with a temporary crown and an artificial silicone gingiva, which allows for the simulation of registering the shape of the emergence profile. Analogue and digital impression protocols were performed for both indications. During conventional, simultaneous two-phase impressions of the upper models, Zhermack addition silicone was used, combining putty and light body consistency. Zhermack Tropic alginate was used for the lower models, and Zhermack bite silicone was used to register the bite. Impressions were made with a standard tray using a two-cord technique. Scanning was performed using the Trios 3Shape 3 intraoral scanner. The total time for conventional impressions was measured from the phase of selecting a suitable tray to disinfecting the impressions. Digital protocols were measured from the moment of opening the case to sending the document to the laboratory. The values of the time used were compared with the entire procedure. The experiment was conducted at the Development and Research Implantology Center of the Faculty of Dentistry, University of Belgrade.

Result: The result obtained for the model with a prepared tooth was 21:02s for the analogue protocol and 16:27s for the digital protocol. For indication for a single crown on an implant, 16:34s was spent using the conventional approach, while it took 9:44s for the digital approach.

Conclusion: Digital impression protocol showed superiority over conventional methods in terms of time used for the tested indications.

Keywords: Impression; Intraoral scanner; Digital impression

NOVA GENERACIJA

KometaBio Smart Dentin Grinder - GENESIS

Ne bacajte izvađene zube. Koristite ih za proizvodnju autolognog grafta vrhunske kvalitete direktno u ordinaciji.

KometaBio
Tissue Engineering



- Moderniji dizajn
- Poboljšana operativnost
- Veća stabilnost prilikom rada
- Tiši motor
- Jedna tipka za funkcije GRIND (drobi) i SORT (prosijavanje)
- Skraćeno trajanje protokola (7 minuta)

AKCIJA
-15%*

*do 30.6.2023. tza kupnju KometaBio SDG Starter kita

Distributer:

BEGO Croatia d.o.o.

Brozova 30, 10000 Zagreb

Tel/Fax: +385 (0)1 3375 921

e-mail: info-croatia@bego.com



Stomatologija sutrašnjice dogaća se već danas

Za postizanje najboljih rezultata u Vašem radu znamo da je preciznost ključna. Zato CEREC besprijekorno podržava Vašu stručnost u cilju izrade savršeno preciznih restauracija prirodnog izgleda. Sada možete prihvatiti više različitih indikacija sa sigurnošću da će rezultat uvijek biti izvanredan, sa savršenim rubom preparacije i površinskim detaljima. Uz CEREC skeniranje, izrada i predaja restauracije u jednom posjetu je moguća uz zajamčeno bolji i brži tijek rada za Vas i Vašu ordinaciju.

CEREC: Tehnologija s iskustvom

Saznajte više: dentsplysirona.com/en-hr



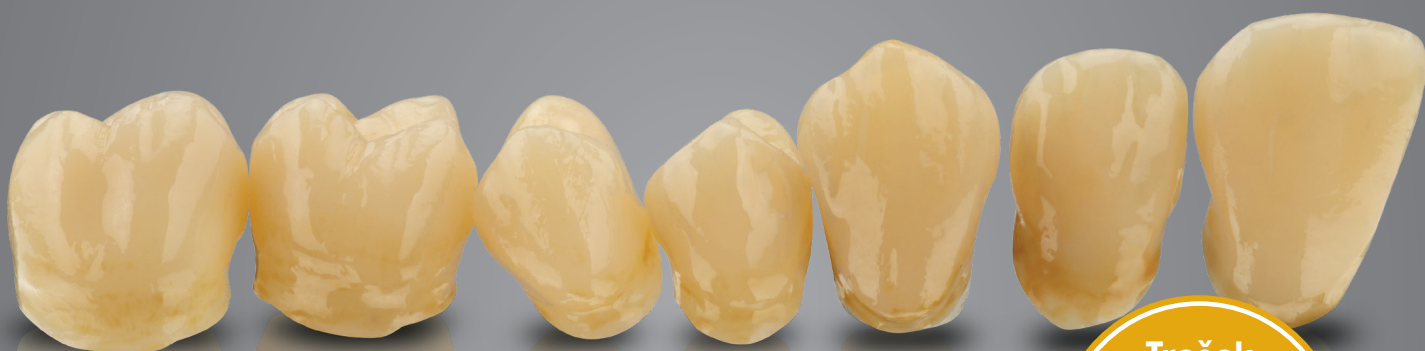REVOLUTION
IN A BOX!

mis[®] | c1 XD[™]

FULL PROCEDURE IN EVERY IMPLANT PACKAGE. **MAKE IT SIMPLE**

Every MIS C1 implant is now supplied with XD Single-Use drills. These single-use drills are designed for optimal implant-drill compatibility and high initial stability, while ensuring safe and simplified procedures. Learn more about MIS at: www.mis-implants.com

3D PRINTANJE SVJETSKA PREMIJERA



Trošak
materijala po
krunici već od
2,5 €

VarseoSmile Crown ^{plus}

Prvi hibridni materijal na svijetu za 3D printanje
trajnih protetskih nadomjestaka

Izvršne karakteristike materijala potvrdile su
kliničke studije renomiranih sveučilišta i instituta

Kompatibilno s ASIGA 3D printerima



CEREC Tessaera™

Napredni litijev disilikat

Trojstvo brzine, čvrstoće i estetike

Brzina, čvrstoća, estetika - prije ste morali birati dva svojstva. Danas, s naprednom strukturom kristalne matrice - litijev disilikat + virgilit - CAD/CAM blokovi CEREC Tessaera optimizirani su za beskompromisno postizanje sva tri zahtjeva



Posjetite
dentsplysirona.com/CERECTessaera

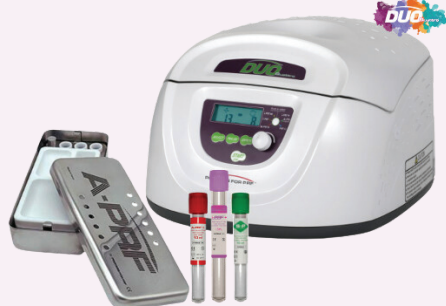

PRF PROCESS™
CHOUKROUN

A-PRF™
CHOUKROUN

S-PRF™

i-PRF™+



TEČAJEVI:

PRF u kliničkoj praksi (i tečaj vađenja krvi)
PRF - primjena za estetiku lica (i vađenje krvi)



THE Graft™
Natural Bone Substitute

THE Graft™



SVINJSKA TRABEKULARNA DEMINERALIZIRANA
KOST

THE Graft™ Collagen



SVINJSKI KOLAGEN + SVINJSKA TRABEKULARNA
DEMINERALIZIRANA KOST



D BOX



i-BOX
PRVI IZBOR MODERNOG STOMATOLOGA
MIS

**Tokuyama
BOX**

ULTRADENT

**NAZOVITE
IVORA!
091.6370.075**



D STORE

PRVI IZBOR MODERNOG STOMATOLOGA



DENTALNI MEGASTORE D.O.O. :: PODLOŽNICA 17, VELIKA GORICA 10410
URED - DOBRIŠE CESARIĆA 8, ZAGREB (ŠPANSKO) 10090
TEL: 01.6370.040 :: 01.6370.046 :: email: info@dentalni-megastore.hr

**UPRAVLJAJTE
SVOJOM
ORDINACIJOM**



Umjesto da ona upravlja vama

POSJETITE NAS NA **MIS** ŠTANDU I DOGOVORITE PREZENTACIJU

Kontaktirajte nas na sinisa@sdinformatika.hr



BEGO Varseo XS

Kompaktni DLP 3D pisač posebno razvijen za dentalnu primjenu

4.000,00 €

- DLP 3D pisač visoke razlučivosti s izvanrednom preciznošću po atraktivnoj cijeni
- Brzina printa neovisna o broju elemenata koji se trebaju proizvesti
- Praktična platforma za printanje – ispis do 20 kruna ili dva mosta velikih raspona s do sedam članova
- Mrežni priključak putem W-LAN ili Ethernet veze omogućuje brzu i nekomplikiranu razmjenu podataka s računalom
- Kompatibilan sa sljedećim materijalima:
 - VarseoSmile Crown plus
 - VarseoSmile Temp
 - VarseoWax CAD/Cast
 - VarseoWax model
- Zamijenjivi spremnik za 3D print materijal omogućuje jednostavnu promjenu materijala
- Kompaktnih dimenzija i privlačnog dizajna

BEGO Varseo Cure

Novi član 3D print tima

NOVO

- **Kompaktan** - Ne zauzima puno mjesta sa svojim dimenzijama od Š 220 x D 200 x 160 mm, a pri tom ima dovoljno velik prostor za polimerizaciju dimenzija Š 145 x D 142 x 80 mm
- **Jednostavan za korištenje** - Instalirana biblioteka materijala sadrži parametre za sve BEGO materijale
- **Siguran** - Instalirani parametri osiguravaju pravilno vrijeme osvjetljavanja materijala
- **Snažan** - Inteligentni menadžment izvora svjetlosti za maksimalnu energetska učinkovitost i idealan intenzitet svjetlosti od 365 nm, 385 nm i 405 nm
- **Svestran** - Čitač SD kartica za ažuriranje i dodavanje datoteka u biblioteku materijala
- **Pouzdan** - 2 godine BEGO jamstva
- **Povoljan** - Savršen za početak rada u području 3D printa u dentalu

1.875,00 €

BEGO Croatia d.o.o.

Brozova 30, 10000 Zagreb

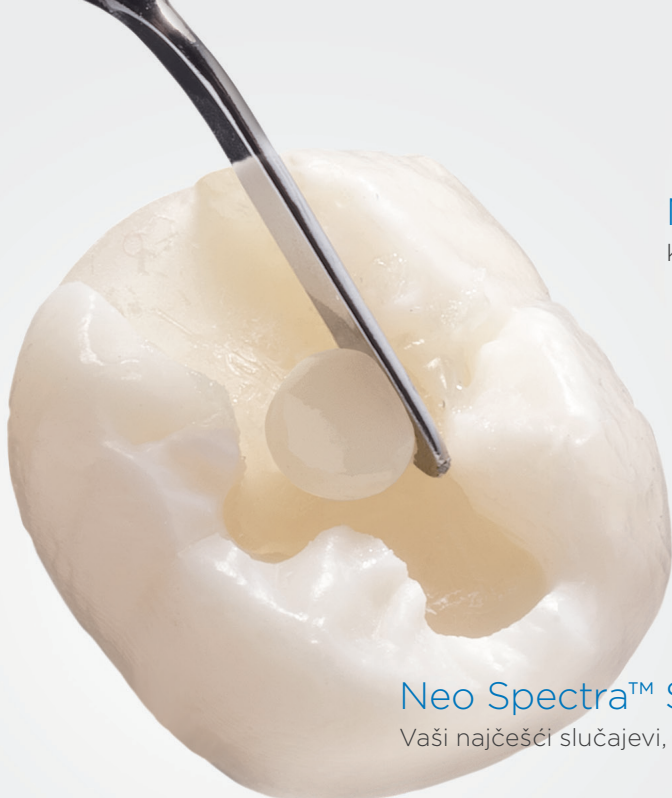
Tel/Fax: +385 (0)1 3375 921

e-mail: info-croatia@bego.com



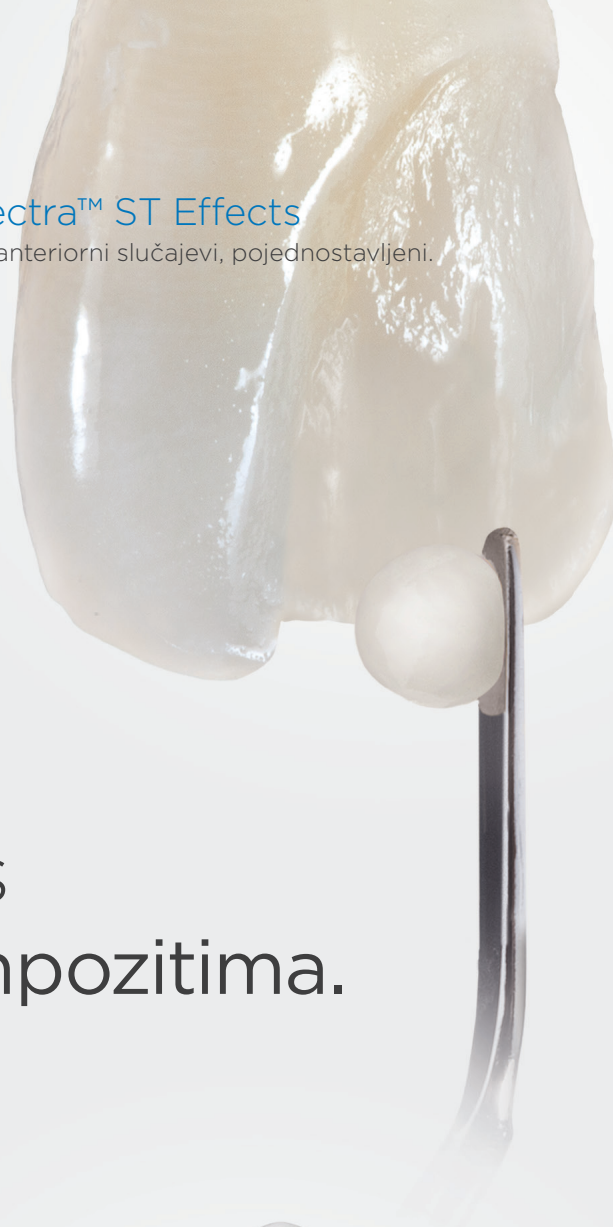Neo Spectra™ ST Effects

Kompleksni anteriorni slučajevi, pojednostavljeni.



Neo Spectra™ ST

Vaši najčešći slučajevi, pokriveni.



Učinkovita estetika s Neo Spectra™ ST kompozitima.

Naša dokazana SphereTEC® formula sada obuhvaća cijeli, raspon 'Spectra' nijansi i mogućnosti obrade, pružajući savršenu ravnotežu svega što je stomatolozima bitno.


Poboljšana obrada. Ne lijepi se za instrument, lako se adaptira u kavitet, jednostavno se oblikuje i ima značajno smanjen rizik od neuspjeha. Dostupan je u visokoj i niskoj viskoznosti.

Pojednostavljeno nijansiranje. Sa samo 5 nijansi pokriva čitav VITA®* spektar boja.

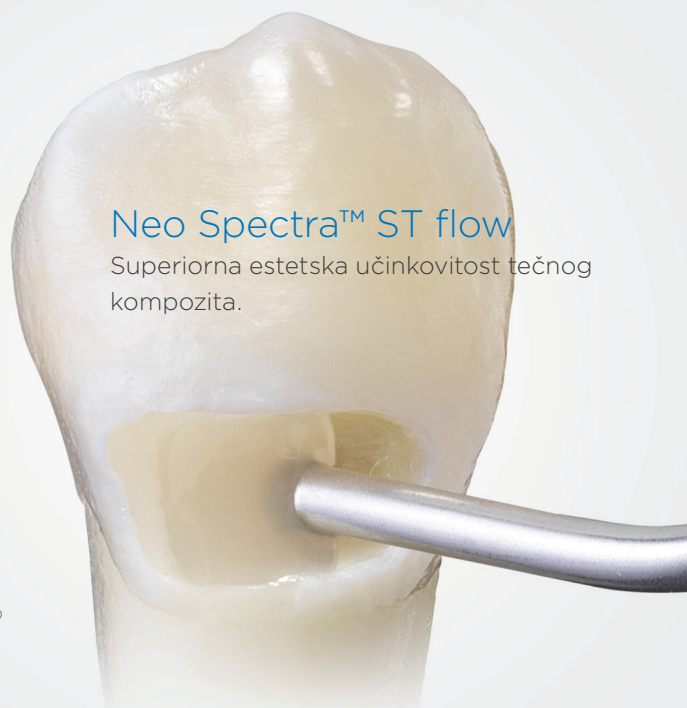Dokazana dugotrajnost. Izvrsna otpornost na prebojavanje, poliranje do iznimnog sjaja.

Posjetite

dentsplysirona.com/NeoSpectraST



omogućeno uz
SphereTEC®
tehnologiju



Neo Spectra™ ST flow

Superiorna estetska učinkovitost tečnog kompozita.

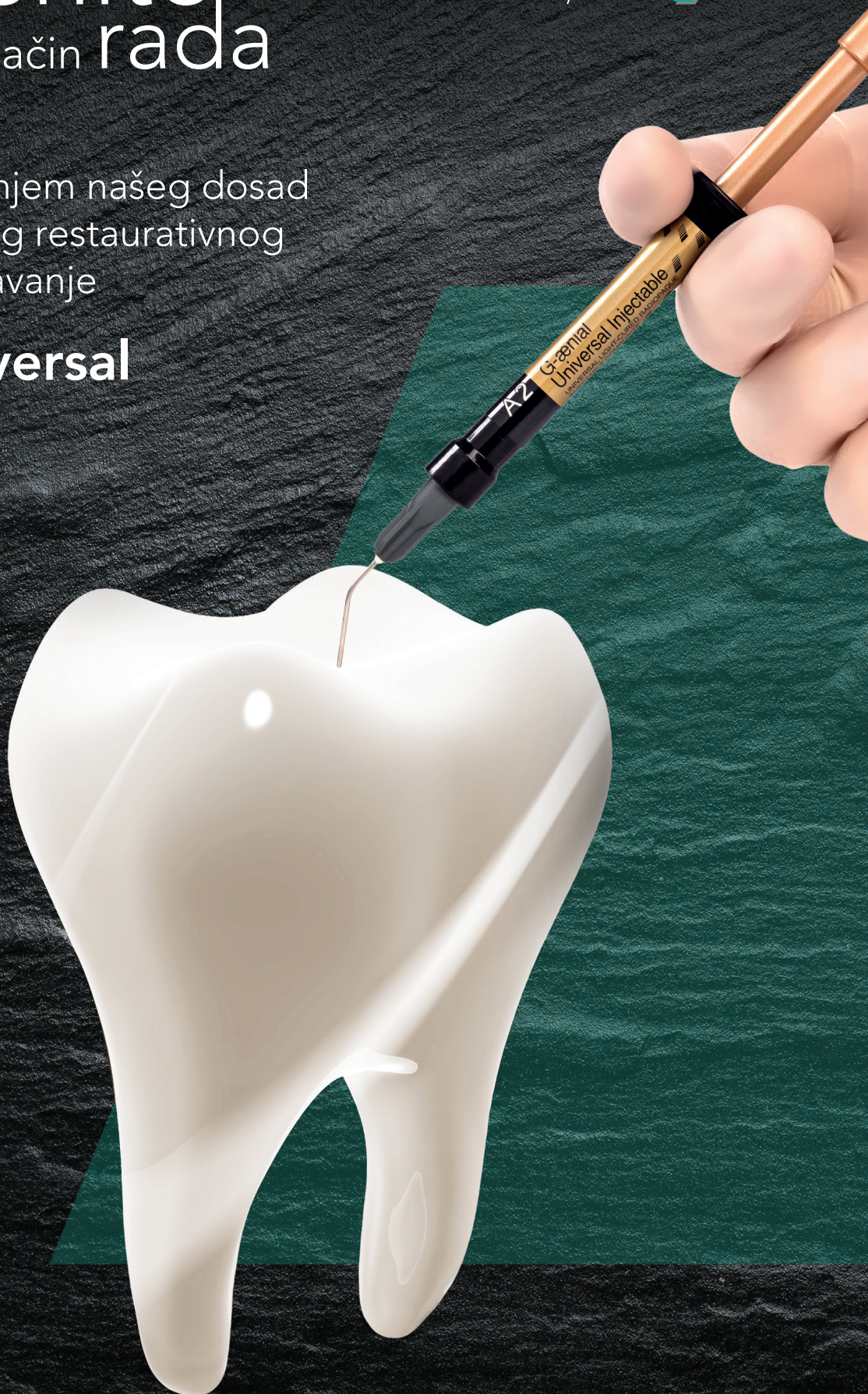*VITA nije registrirani znak tvrtke Dentsply Sirona.

Promijenite način rada



Započnite s korištenjem našeg dosad najčvršćeg direktnog restaurativnog kompozita za uštrcavanje

G-ænial® Universal Injectable



GC



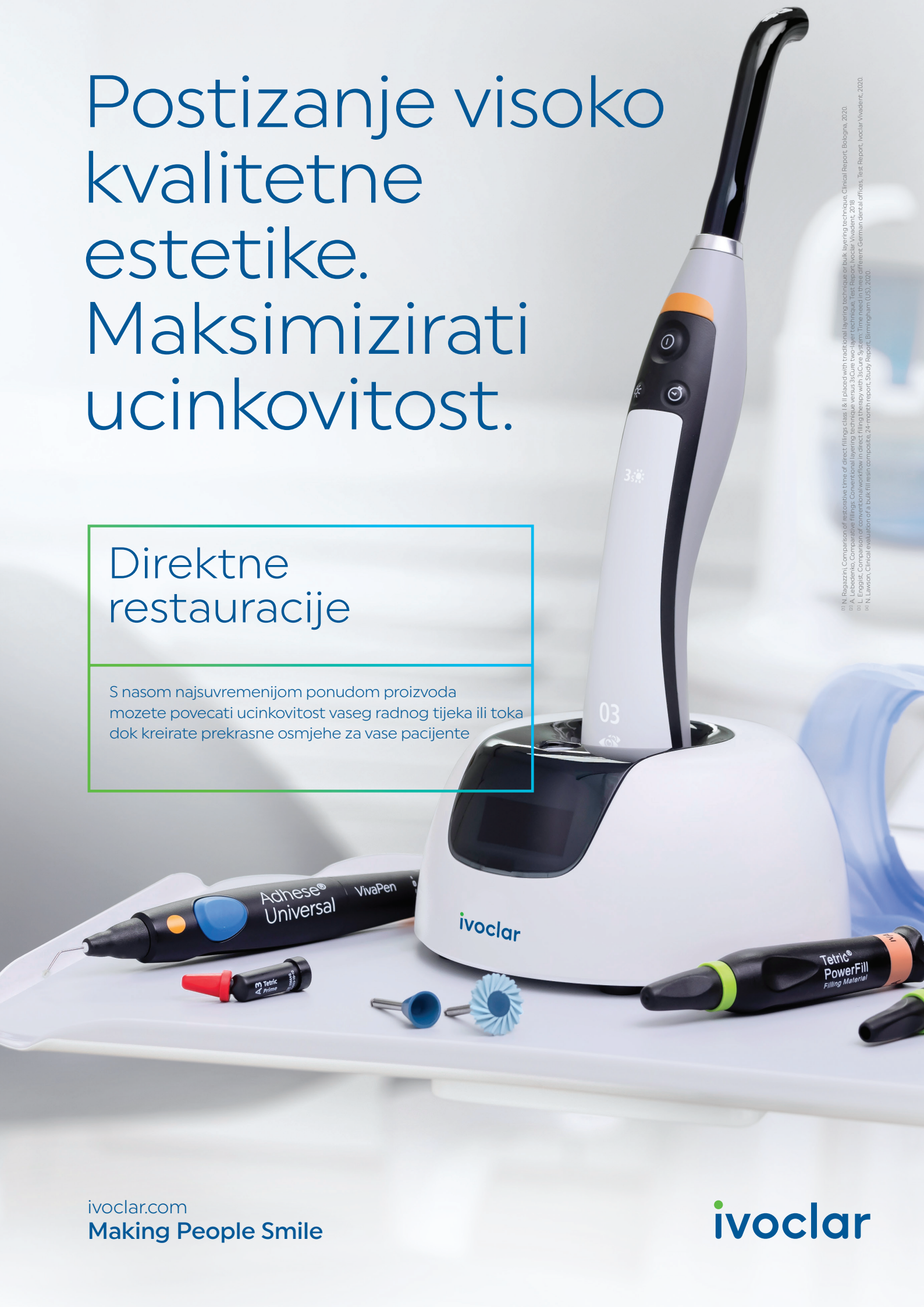Since 1921
100 years of Quality in Dental

GC EUROPE N.V.
GCEEO Croatia
HR - 10020 Zagreb, Siget 19b
Tel. +385.1.61.54.597
Fax. +385.1.61.54.597
info.croatia@gc.dental
<https://www.gc.dental/europe/hr-HR>

Postizanje visoko kvalitetne estetike. Maksimizirati ucinkovitost.

Direktne restauracije

S nasom najsvremenijom ponudom proizvoda
možete povećati ucinkovitost vasesh radnog tijeka ili toka
dok kreirate prekrasne osmjehe za vase pacijente

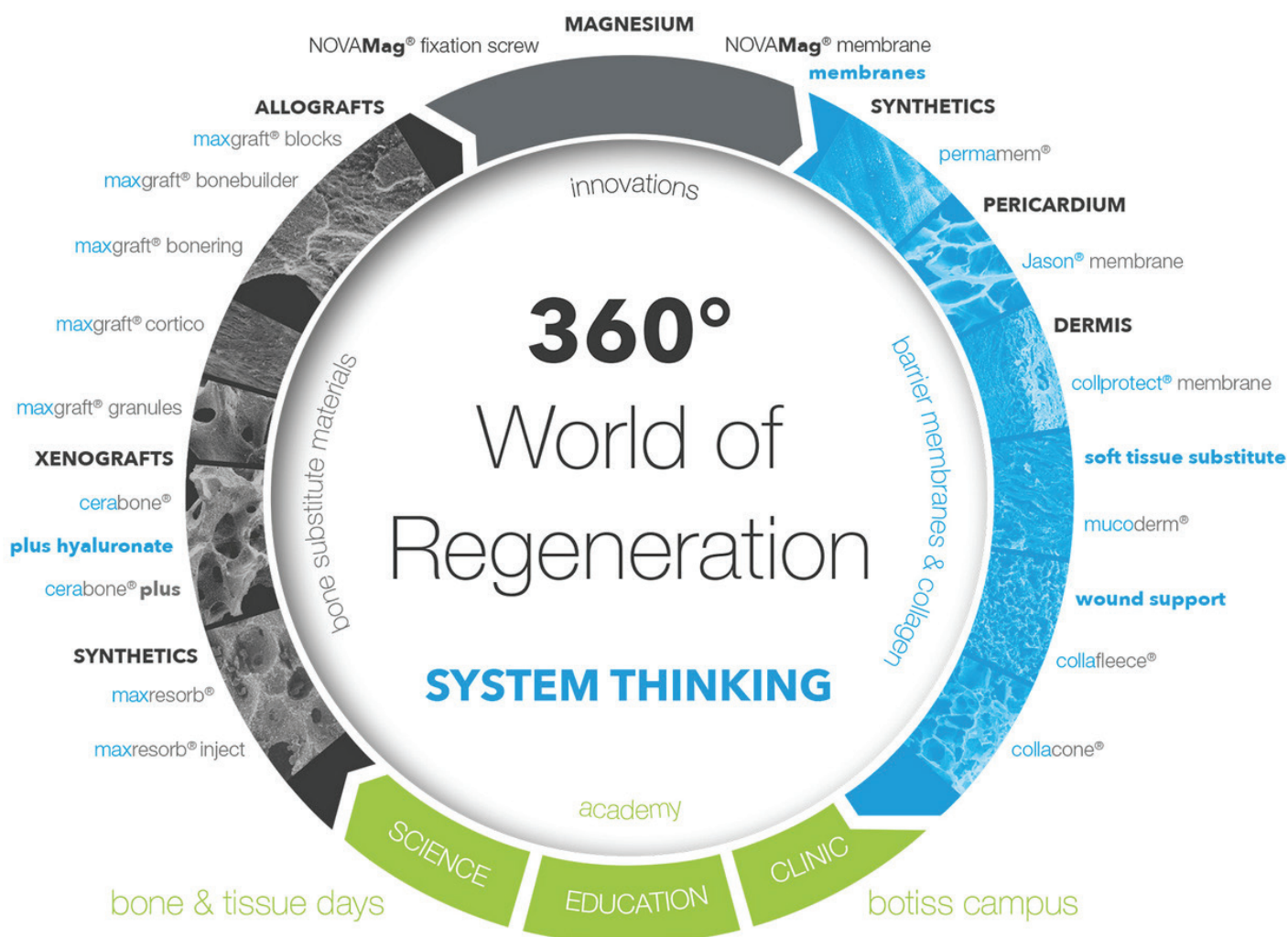


1) N. Ragazzini, Comparison of restorative time of direct fillings class I & II placed with traditional layering technique or bulk layering technique. Clinical Report, Bologna, 2020.
2) A. Lebedenko, Comparative fillings. Conventional layering technique versus 3Secure two-layer technique. Test Report, Ivoclar Vivadent, 2018.
3) L. Engstad, Comparison of conventional workflow in direct filling therapy with 3Secure System. Time needed in three different German dental offices. Test Report, Ivoclar Vivadent, 2020.
4) N. Lawson, Clinical evaluation of a bulk-fill resin composite. 24 French reports. Study Report, Birmingham (UK), 2020.

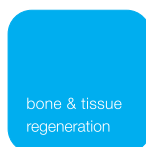


DDENTAL
SOLUTIONS

botiss regeneration system



botiss.com
novodent.hr



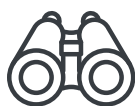coDiagnostiX®

For Clinicians

Planning power at your fingertips



coDiagnostiX®, our state-of-the-art dental treatment planning software, is **the all-in-one solution to help you achieve predictable outcomes and improve your efficiency**, supporting the full range of clinical indications, including guide design for implantation, endodontic, bone reduction, sinus-lift guides.



PREDICTABLE



EFFICIENT



EASY

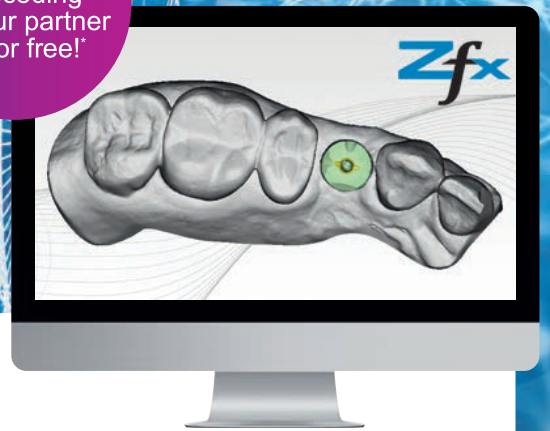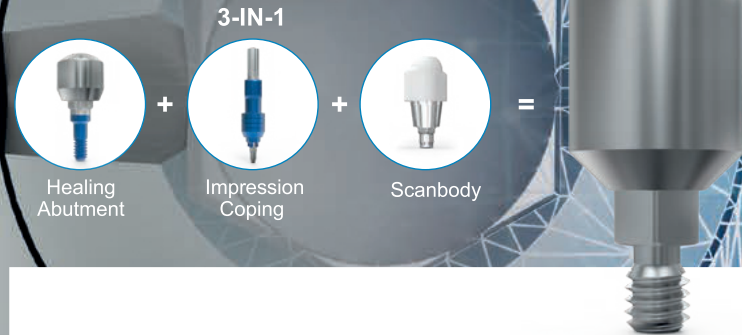
straumanngroup
Digital Solutions

Encode® Impression System

The next level of digital impression taking

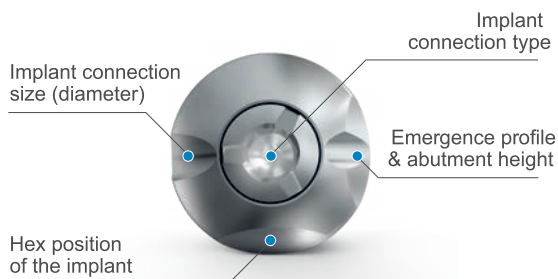
Productive. Protective. Proven.

Software module & decoding for your partner lab for free!



ENCODE HEALING ABUTMENTS

Unique codes on the 3-in-1 healing abutment communicate information on the implant place. The information can be decoded by the lab and is used to design the final prosthesis.



ZFX™ CONVERTER

Software-module intended for the decoding of 3D information of Encode Healing Abutments. The software module and the decoding is for free.



MORE INFORMATION about Zfx Converter you can find in our product flyer at www.zfx-dental.com

Prednost na prvi pogled.



dentalart



vatech



POSLOVNICE I PRODAJNI CENTRI

www.dentalgrupa.hr

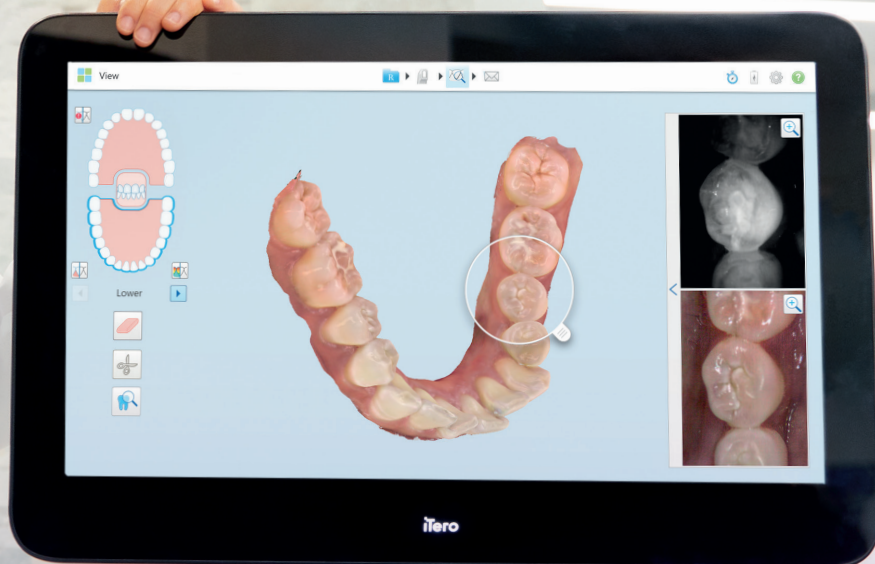
Rijeka 051/37 43 74
Zagreb 01/23 71 999

Split 021/56 85 02
Umag 052/75 21 06

info@dentalgrupa.hr

EXPAND

Poboljšajte svoje preglede.
Snažno, neprimjetno, bez odgode.



Bolje performanse. Veća produktivnost.

iTero Element 5D Plus sustav omogućuje:

- Napredne mogućnosti vizualizacije
- Nove snažne karakteristike
- Prikaz 3D modela, intraoralne snimke i pomoć pri detekciji karijesa
— sve u samo jednoj snimci koja doprinosi vašoj digitalnoj produktivnosti

Zakažite termin za demonstraciju već danas i saznajte više na [iTero.com](https://www.itero.com)

it starts with **iTero**

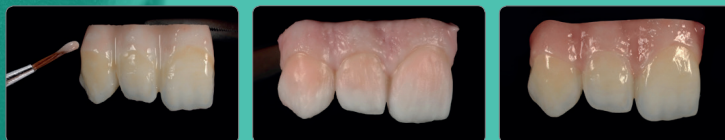Invisalign, iTero, iTero Element, iTero logotip, među ostalima, žigovi su i/ili zaštićene usluge kompanije Align Technology Inc., ili jedne od njenih podružnica ili povezanih društava i mogu biti registrirani u SAD-u i/ili drugim državama.

© 2021 Sva prava pridržana. Align Technology Switzerland GmbH, Suurstofli 22, 6343 Rotkreuz, Švicarska. MKT-0006716 Rev B



initial[™]
IQ ONE SQIN

Keramički sustav za
bojanje i oblikovanje



Ustupio dentalni tehničar Stefan M. Roozen (Austrija)



GC

GC EUROPE N.V.
GCEEO Croatia
HR - 10020 Zagreb, Siget 19b
Tel. +385.1.61.54.597
Fax. +385.1.61.54.597
info.croatia@gc.dental
<https://europe.gc.dental/hr-HR>

Redefiniranje estetike cirkonij oksid

IPS e.max[®]
ZirCAD
Prime Esthetic

- Jednostavno glodanje - sinteriranje - glazura
- Besprijevano napredovanje boja i translucencije zbog GT tehnologije
- Prikladno za krunice i troclani most

IPS e.max[®] ZirCAD
Prime Esthetic

A3


↑ 16 mm



Incisal side
Occlusal side

ivoclar
digital:

Novo



novodent

novodent.hr

...vaš pouzdan partner u stomatologiji


edukacije • implantologija • dentalni proizvodi • dentalna oprema • laboratorij • oralna higijena



EDUCEN

DENTALNI EDUKACIJSKI CENTAR
POWERED BY NOVODENT

educen.hr



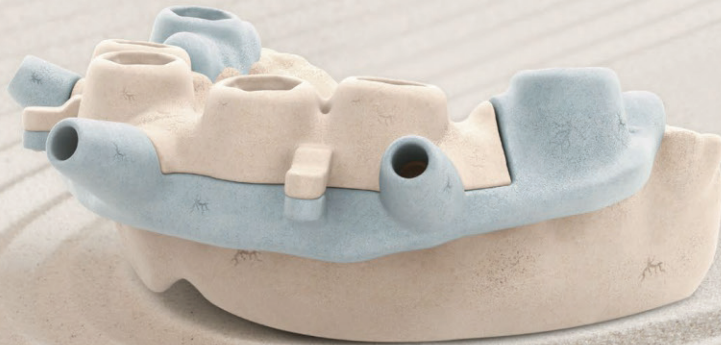**TO UNLOCK THE
POTENTIAL OF
PEOPLE'S LIVES.**

straumanngroup

NEW

RealGUIDE™ SandBox™

Seamless, timesaving, and fully-integrated modeling environment

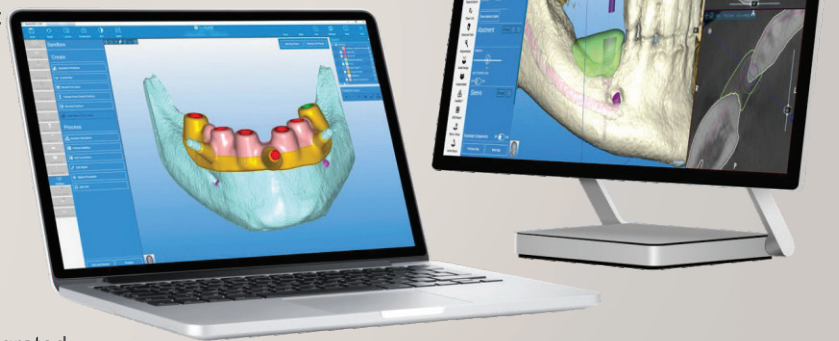

Tired of switching between software platforms in order to bring your complex designs to life?

SandBox could be your solution.

- Simplify your workflow and create customized environments with individual protocols and libraries
- Manipulate STL files with a fully integrated parametric modeling environment to cut, split, merge, and repair any STL file
- Use your imagination to design objects, custom prostheses, generate geometric primitives, and more. Examples include:
 - Bone reduction and stackable guides
 - Custom bone grafts
 - Models
 - Custom bars
 - Prosthetic connectors
 - Partial frameworks
 - Grids and sub-periosteal implants
 - Patent-pending functionalities such as volume splitting

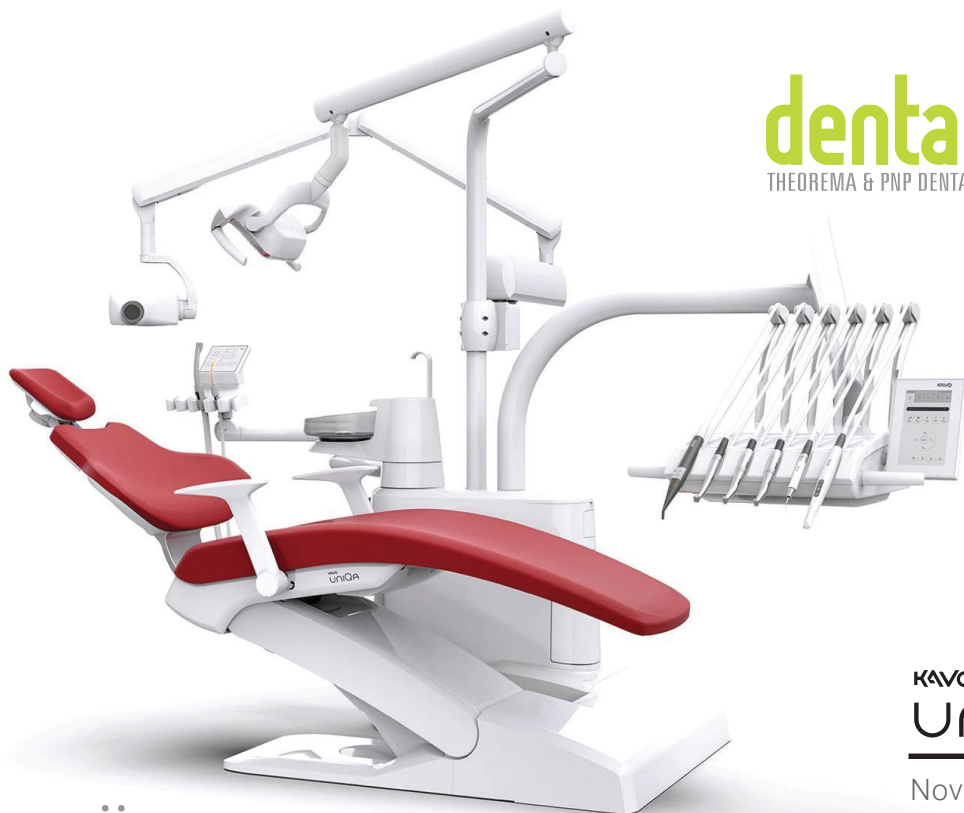FREE
FOR RealGUIDE
GUIDE
SUBSCRIBERS



As part of the RealGUIDE Software Suite, this integrated SandBox feature includes several software modules for a thorough diagnosis, virtual implant positioning, and advanced surgical guide design. Get more information at realguide.com

All content herein is protected by copyright, trademarks, and other intellectual property rights, as applicable, owned by or licensed to 3Diemme SRL or its affiliates unless otherwise indicated, and must not be redistributed, duplicated, republished or reprinted, in whole or in part, without express written consent the owner. This material is intended for clinicians only and does not comprise medical advice or recommendations. Distribution to any other recipient is prohibited. ZV0218 Rev A 05/22 ©2022 ZimVie. All rights reserved.

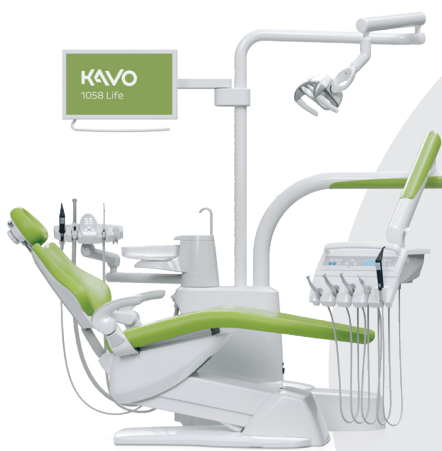 **RealGUIDE™**
UNIVERSAL OPEN SYSTEM



KAVO
UNIQA

Nova premium klasa.

Nova generacija najsuvremenijih platformi



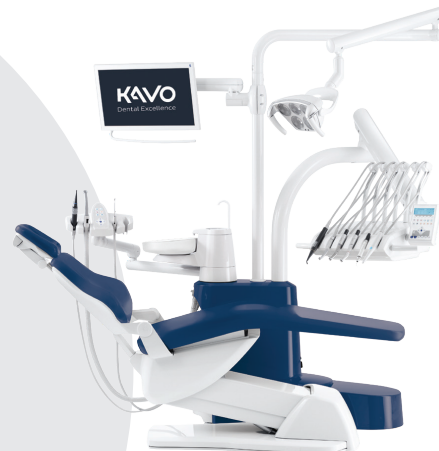KaVo Primus™ Life 1058

Vremenom dokazan.

Najprodavaniji i
najzastupljeniji Kavo model u
Hrvatskoj

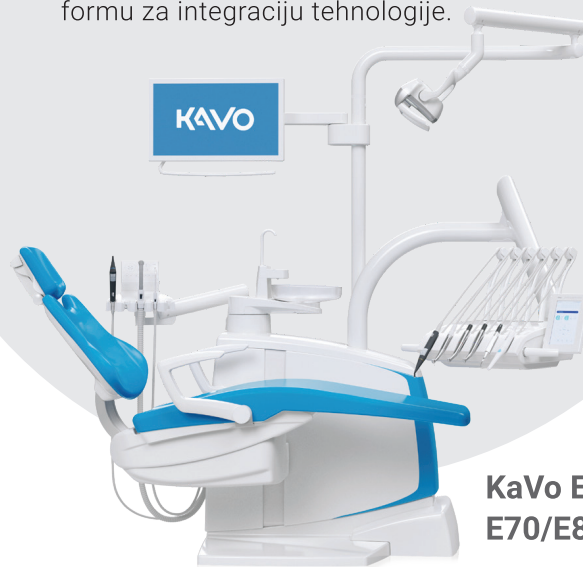već od 18.000 Eur + PDV

Lijepo linije, udobnost pacijenta i jednostavno rukovanje samo su neke od prednosti KaVo linije dentalnih jedinica. Sve što vam je potrebno za izvođenje bilo kojeg postupka nalazi se u našem rješenju. Ova nova generacija jedinica za tretman prepuna je pametnih, inovativnih značajki za povećanje produktivnosti i pruža najsuvremeniju platformu za integraciju tehnologije.



KaVo ESTETICA™ E50 Life

Udobna stomatološka
stolica u svom
najljepšem obliku.



KaVo ESTETICA™ E70/E80 Vision

U kontaktu sa svojom
vizijom.

POSLOVNICE I PRODAJNI CENTRI

Poslovnica Split
☎ 021/56 85 00

Poslovnica Rijeka
☎ 051/37 43 74

Poslovnica Umag
☎ 052/75 21 06

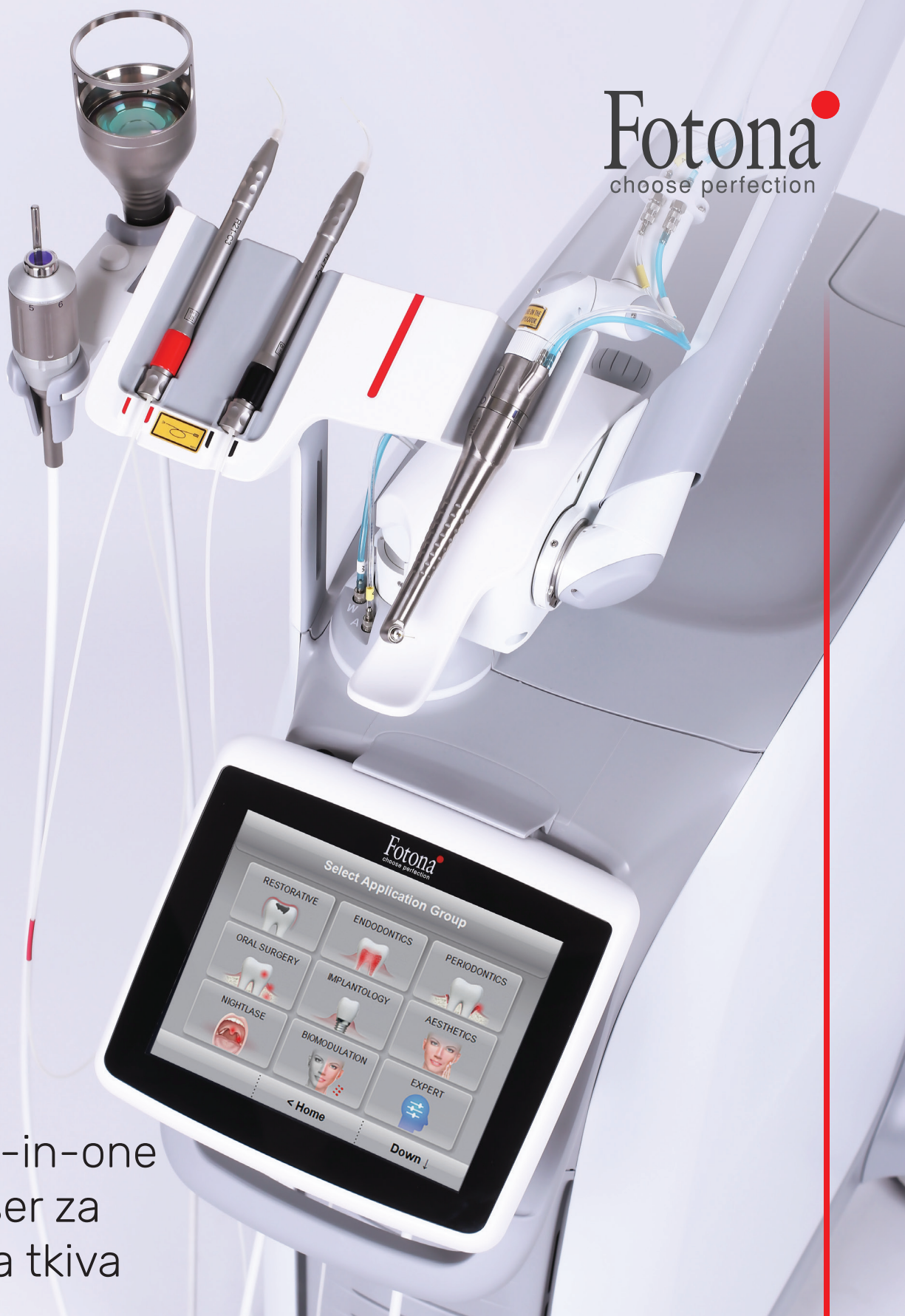Poslovnica Zagreb
☎ 01/23 71 999

info@dentalgrupa.hr / www.dentalgrupa.hr



Aether
STOMATOLOŠKA OPREMA I SERVIS

Fotona
choose perfection



Vrhunski all-in-one
dvovalni laser za
meka i tvrda tkiva

Beskrajne mogućnosti liječenja u:

- Restaurativnoj stomatologiji
- Endodonciji
- Parodontologiji
- Oralnoj kirurgiji
- Implantologiji
- Estetskim tretmanima poput pomlađivanja kože te uklanjanja benignih i vaskularnih lezija
- NightLase®-hrkanje
- Fotobiomodulacija i upravljanje boli

LightWalker®



Ul. Dražice 121D, 51000 Rijeka

prodaja.aether@gmail.com / 091 729 68 69 / 091 616 93 07 / www.aether.hr



3M Universal Series

Za pojednostavljene restauracije od zaliha do rezultata - ova su tri proizvoda sve što trebate.

Od vas se, kao stomatologa, traži da radite sve. Trebali biste imati proizvode koji također mogu raditi sve – prednje i stražnje, izravne i neizravne restauracije, samostvrđavajuće materijale i one koji stvrđavaju s pomoću svjetla*, sve klase i sve tehnike jetkanja. 3M nudi tri univerzalna proizvoda koja će vam pojednostaviti dan.

Ta su tri proizvoda sve što trebate za izvođenje praktički svake restauracije.

3M proizvodi pomažu vam da:

- provedete manje vremena u upravljanju narudžbama
- uštedite vrijeme na pripremi sljedećeg pacijenta
- uštedite vrijeme na obuci svojeg osoblja
- pojednostavite postupke sa smanjenim brojem proizvoda
- optimizirate protokole liječenja
- smanjite zalihe i uredite svoju ladicu

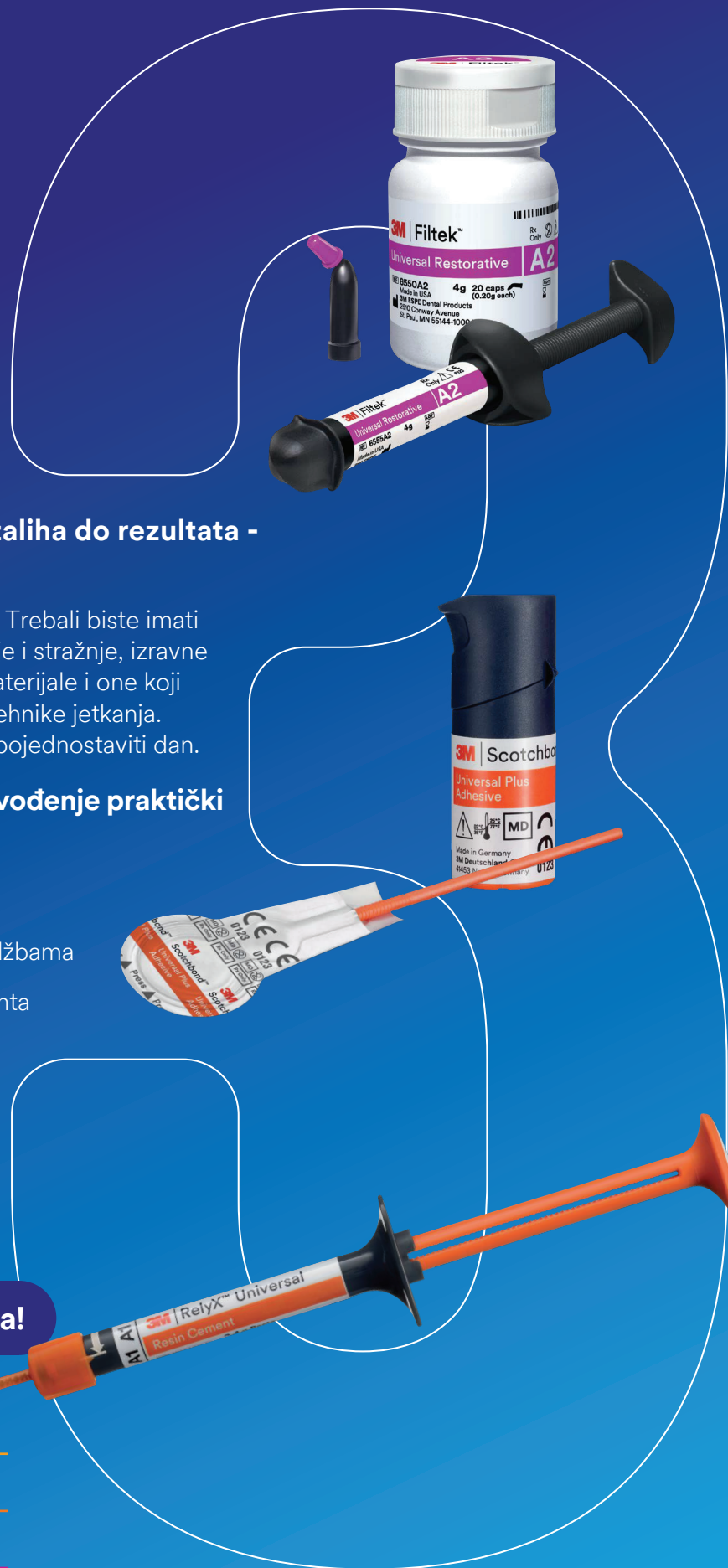Sve što trebate su tri proizvoda!

3M™ RelyX™ Universal Resin Cement

3M™ Scotchbond™ Universal Plus Adhesive

3M™ Filtek™ Universal Restorative

* Univerzalni adheziv Scotchbond Universal Plus Adhesive kompatibilan je s dvostrukim stvrđivanjem; kompoziti Filtek namijenjeni su samo za stvrđivanje s pomoću svjetlosti



MEDEST

MEDICINA ESTETIKA

www.medest.eu

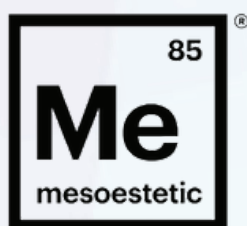
20 godina iskustva
300 različitih proizvoda
1000 zadovoljnih klijenata
1 000 000 odrađenih tretmana

- jedan MEDEST -

Inspirirani ljepotom i napretkom opremamo klinike i estetske centre uređajima posljednje generacije uz konstantno održavanje edukacija i seminara
Za Vas biramo samo najbolje partnere:

FILLMED
LABORATOIRES

 **DERMOAROMA**[®]



the element
for skincare
experts

 biotec italia

 **ERCHONIA**
World Leaders in Low Level Laser Technology


VENUSCONCEPT

LUMENIS

 **SINCLAIR**

 **FotoFinder**[®]

VALO™ X

ŠIROKOPOJASNA LED POLIMERIZACIJSKA LAMPA

NOVO!



NOVO POGLAVLJE U FOTO-POLIMERIZACIJI

POJEDNOSTAVLJENO
SUČELJE

NOVA FUNKCIJA
SENZORA POKRETA

VEĆA LEĆA OD 12.5 MM

UV I BIJELO SVJETLO
ZA DIJAGNOSTIKU

ZA VIŠE DETAJA SKENIRAJTE QR KOD ILI POSJETITE [ULTRADENT.COM/VALOX-EU](https://www.ultradent.com/valox-eu)





Aidite®

cameo *Elegant 3*



JUST SCAN IT

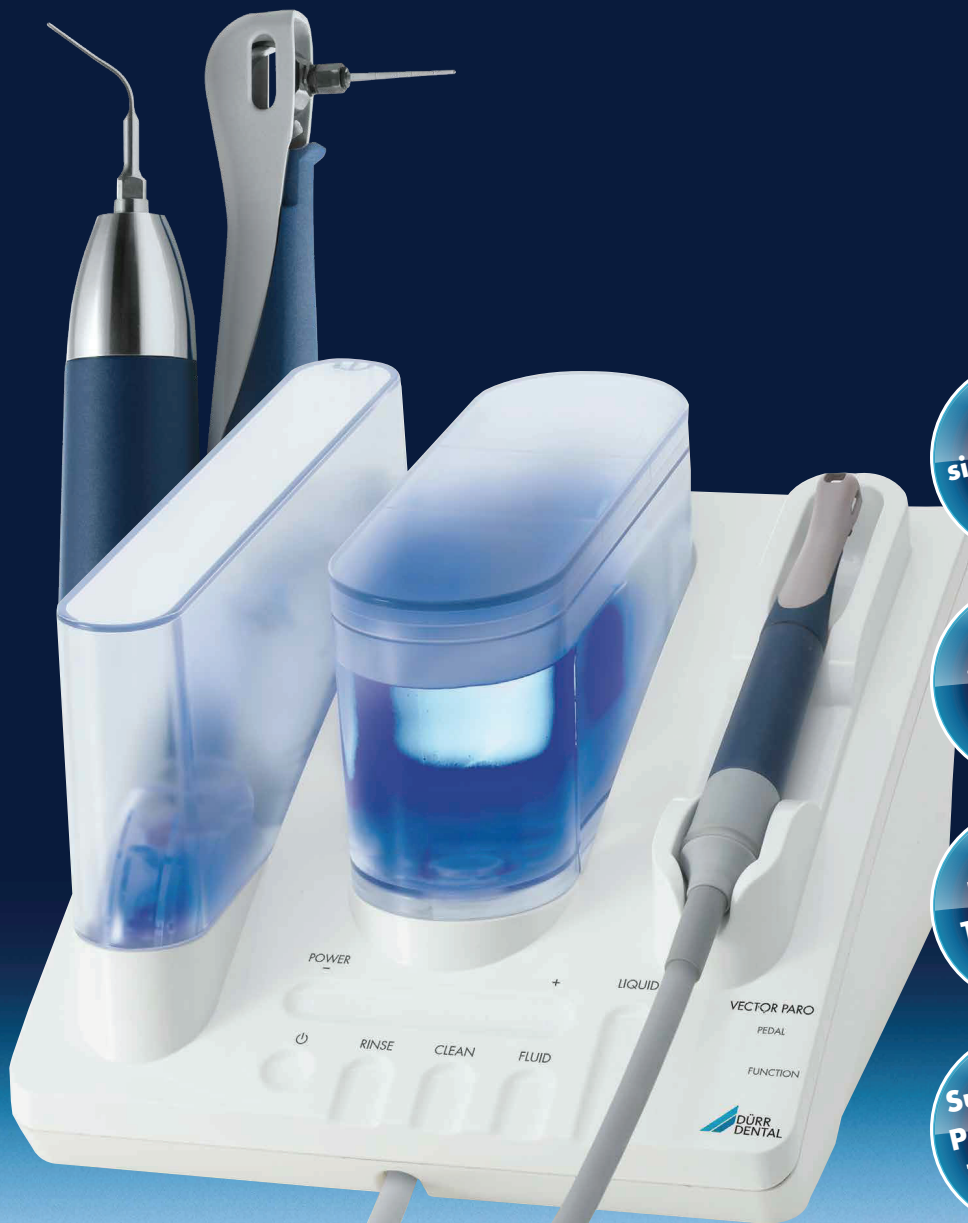Najbolji omjer
cijene i kvalitete!



Za više informacija

kontaktirajte nas na info@maico.hr ili nazovite 042 261 330

ONE FOR THE WHOLE TEAM – VECTOR®!



Profes-
sional Teeth
Cleaning

Anti-
infective
Therapy

Perio/PI
Treatment

Supportive
Periodontal
Treatment

Vector®-System: Einer für alle und alles.

- Easy to use
- A single system for a whole host of prophylaxis and periodontitis/peri-implantitis treatment applications
- Low-aerosol, low-pain treatment
- Suitable for subgingival and supragingival cleaning

For more information please visit www.duerrdental.com



Video: Dr Lababidi
from Prague on Vector®



ORGANIZATORI



ZLATNI SPONZORI



SREBRNI SPONZORI



BRONČANI SPONZORI



OSTALI SPONZORI



PARTNER KONGRESA



TEHNIČKI ORGANIZATOR





HRVATSKO DRUŠTVO ESTETSKE DENTALNE MEDICINE

Rudeška cesta 234, Zagreb
+385 98 9278 635
email: info@ad-sinergija.com
web: www.hdedm.hr

