

Should the Application of Diode Laser Completely Replace Conventional Pulpotomy of Primary Teeth?

Šimunović, Luka; Špiljak, Bruno; Vranić, Lara; Bašić, Rebecca; Negovetić Vranić, Dubravka

Source / Izvornik: **Applied Sciences**, 2022, 12

Journal article, Published version

Rad u časopisu, Objavljena verzija rada (izdavačev PDF)

<https://doi.org/10.3390/app122211667>

Permanent link / Trajna poveznica: <https://urn.nsk.hr/urn:nbn:hr:127:243161>

Rights / Prava: [Attribution 4.0 International](#)/[Imenovanje 4.0 međunarodna](#)

Download date / Datum preuzimanja: **2024-09-07**






Repository / Repozitorij:

[University of Zagreb School of Dental Medicine
Repository](#)



Article

Should the Application of Diode Laser Completely Replace Conventional Pulpotomy of Primary Teeth?

Luka Šimunović ¹ , Bruno Špiljak ^{1,*} , Lara Vranić ¹, Rebecca Bašić ² and Dubravka Negovetić Vranić ¹ ¹ School of Dental Medicine Zagreb, University of Zagreb, 10000 Zagreb, Croatia² Private Dental Office, 10000 Zagreb, Croatia

* Correspondence: bruno.spiljak@gmail.com

Abstract: Nowadays, the use of lasers in dental medicine has become an effective approach for numerous restorative and soft tissue therapeutic procedures. The use of different types of lasers depends on how the tissue interacts with the laser light and the purpose of treatment. Although some studies show the benefits of laser pulpotomy compared to the conventional method of pulpotomy, clinical studies are lacking. Moreover, the material used for a definitive restoration of endodontically treated primary teeth can also affect the outcome of the therapy. Therefore, this prospective study aimed to compare the clinical use of the diode laser and the conventional method of vital pulpotomy, as well as the influence of the material chosen for a definitive restoration for the outcome of the procedure. Patients were divided into two groups: conventional pulpotomy and 980 nm diode laser. Each group was then divided into two subgroups according to the type of material for the final restoration. By comparing the success of the therapy according to clinical parameters depending on the material of the final restoration, the advantage of the composite material compared to the glass ionomer cement was noticed at 6 months checkup ($p = 0.045$). A strong positive correlation between the quality of the final restoration according to the United States Public Health Service (USPHS) criteria and the success of the clinical parameters was found in all investigated time points. There is no statistically significant difference between the diode laser and the conventional pulpotomy, however, the choice and quality of the final restoration significantly contribute to the outcome of therapy.

Keywords: diode lasers; endodontology; primary teeth

Citation: Šimunović, L.; Špiljak, B.; Vranić, L.; Bašić, R.; Negovetić Vranić, D. Should the Application of Diode Laser Completely Replace Conventional Pulpotomy of Primary Teeth? *Appl. Sci.* **2022**, *12*, 11667. <https://doi.org/10.3390/app122211667>

Academic Editors: Bruno Chrcanovic and Marina Consuelo Vitale

Received: 14 October 2022

Accepted: 15 November 2022

Published: 17 November 2022

Publisher's Note: MDPI stays neutral with regard to jurisdictional claims in published maps and institutional affiliations.



Copyright: © 2022 by the authors. Licensee MDPI, Basel, Switzerland. This article is an open access article distributed under the terms and conditions of the Creative Commons Attribution (CC BY) license (<https://creativecommons.org/licenses/by/4.0/>).

1. Introduction

With the development of technologies, the use of lasers is nowadays ubiquitous in all fields of dental medicine, especially in pedodontics [1]. Due to the development of the concept of minimally invasive dentistry guided by the principle of “fill without drilling”, children and adolescents represent one of the target groups in which laser application is increasingly present today [2,3]. The reason why its use is multiply justified in these groups of patients lies in the fact that children and adolescents represent the population group most sensitive to pain and bleeding during dental procedures and frequent visits to the dentist [4]. The effect of lasers on biological tissues is determined by the specific interaction between the wavelengths of laser radiation and target tissue components (water, proteins, melanin, haemoglobin, hydroxyapatite) called chromophores [5–7]. For example, shorter wavelength radiation, approximately between 500 and 1000 nm, is primarily absorbed by pigmented tissue, while longer wavelength radiation is primarily absorbed by water and hydroxyapatite [8]. It is therefore important to point out that the wrong choice of wavelength results in an unfavourable effect or the absence of an effect [9,10]. Another important effect of the laser lies in its analgesic effect, the mechanism of which is based on the interference of signal transmission and the inhibition of the formation of the action potential [11]. In dental medicine, there are groupings of different types of lasers depending on their application: lasers for exclusively soft tissues, lasers for hard and soft tissues, for

photopolymerization, teeth whitening, caries detection, and lasers for use in low doses [12]. Each of those laser types has its unique application in dental medicine [1]. The choice of laser depends on the optical affinity of the tissue and the wavelength at which the laser emits photons, that is, light particles [12]. There are four different ways of interaction between the laser and the tissue. The laser beam can be reflected from the surface (reflection), scattered (dispersion), absorbed into the tissue (absorption), or pass through the tissue unchanged (transmission) [13,14]. The use of different types of lasers during the therapy of different tissues depends on the way the tissue interacts with the laser light and the desired effect for the purpose of treatment [15]. Thus, for example, low-power lasers are used in the prevention, diagnostics, and achieving bio-stimulating effects, in contrast to high-power lasers that have found their use in caries removal and laser surgery of hard and soft tissues [15]. In general, the laser effect on tissues is the result of the absorption and dispersion of laser radiation, and it depends on the wavelength of the radiation and the optical properties of the tissue [13,14]. For example, if the laser light passes through the tissue, it will not have any effect on the tissue itself. The specific effect of the absorbed laser energy can be controlled by the physical settings of the laser: laser power, radiation time, size of the radiation surface, laser operation mode, water cooling, and laser working distance [13,14]. The result of all these factors is the photodynamic, photochemical, and photothermal action of the laser [13,14]. However, one should pay attention to the doses of reflected radiation, because they represent a possible danger for the surrounding tissues, as well as for health personnel [12]. In endodontics, the indications for the use of lasers include very common therapeutic interventions for deciduous teeth: pulp covering, pulpotomy, and root canal disinfection [16,17]. For this purpose, low laser energy is used, which ensures good surface coagulation and decontamination in order to preserve the vitality of the residual pulp [18]. Although there are many lasers available on the market, the Er: YAG laser is mainly used in pulpotomy procedures. This way, the placement of chemicals in the pulp chamber is avoided. Pulpotomy is performed by placing a laser on the coronal part of the tooth, with or without water. The laser beam penetrates through the pulp chamber for 15 s until adequate hemostasis is achieved, after which zinc oxide eugenol is placed [19]. The laser beam is only slightly absorbed by the dentin, which is of particular importance when sterilizing the root canal since the goal is to achieve deep penetration of the laser into the intertubular tissue, and thus a bactericidal effect in the deeper layers. This is why diode lasers as well as Nd: YAG lasers are particularly suitable for endodontic purposes. Most of the Gram-negative and some Gram-positive bacteria (e.g., *E. faecalis*) are very sensitive to their use which is supported by the success rate of 99.91% in reducing *E. faecalis* bacteria with a diode laser [6]. It is considered that the diode laser has a better antimicrobial effect than the classic methods of pulpotomy [5]. Other advantages of laser pulpotomy are improved patient cooperation, simplicity of the method, and reduced pain [20]. Nevertheless, classic materials for covering the pulp remain the basis of therapy [21]. Conversely, the use of lasers in exposed pulps to stimulate healing has proven to be superior compared to manual or rotary techniques [22]. By using the Er,Cr:YSGG laser, the duration of the procedure for cleaning and widening the root canals of primary teeth was reduced while maintaining the same quality of the preparation [23,24]. This research aims to compare the effectiveness of two different pulpotomy methods for primary teeth in the follow-up period of 6, 12, and 24 months. Given that the majority of studies in the available literature [18,25–29] conducted the follow-up of teeth treated with pulpotomy for up to one year, the question arises as to what the fate of these teeth is after more than a year from the end of the treatment. Therefore, the null hypothesis of this study is: “The type of pulpotomy (diode laser vs. conventional) and the material of the final restoration (composite and glass ionomer cement) have no influence on the clinical and radiological success of the treated deciduous teeth.”

2. Materials and Methods

2.1. Study Design

The participants of this prospective study were patients of the Department of Pediatric and Preventive Dentistry, School of Dental Medicine, University of Zagreb, who enrolled in the study according to the indications. Before patient enrollment sample size analysis was determined. Considering the required sample size of 124 subjects, and possible exclusions and withdrawals of subjects, 140 patients were enrolled in the study. The study protocol consisted of 2 allocations (pulpotomy treatment and final restoration) and 3 follow-up periods—after 6, 12, and 24 months. Subsequently, due to drop-outs, the data of 120 respondents were complete and ready for analysis (Figure 1). Although the analysis included a smaller sample than determined by the sample size analysis, the post-hoc power analysis confirmed sufficient power (83%).

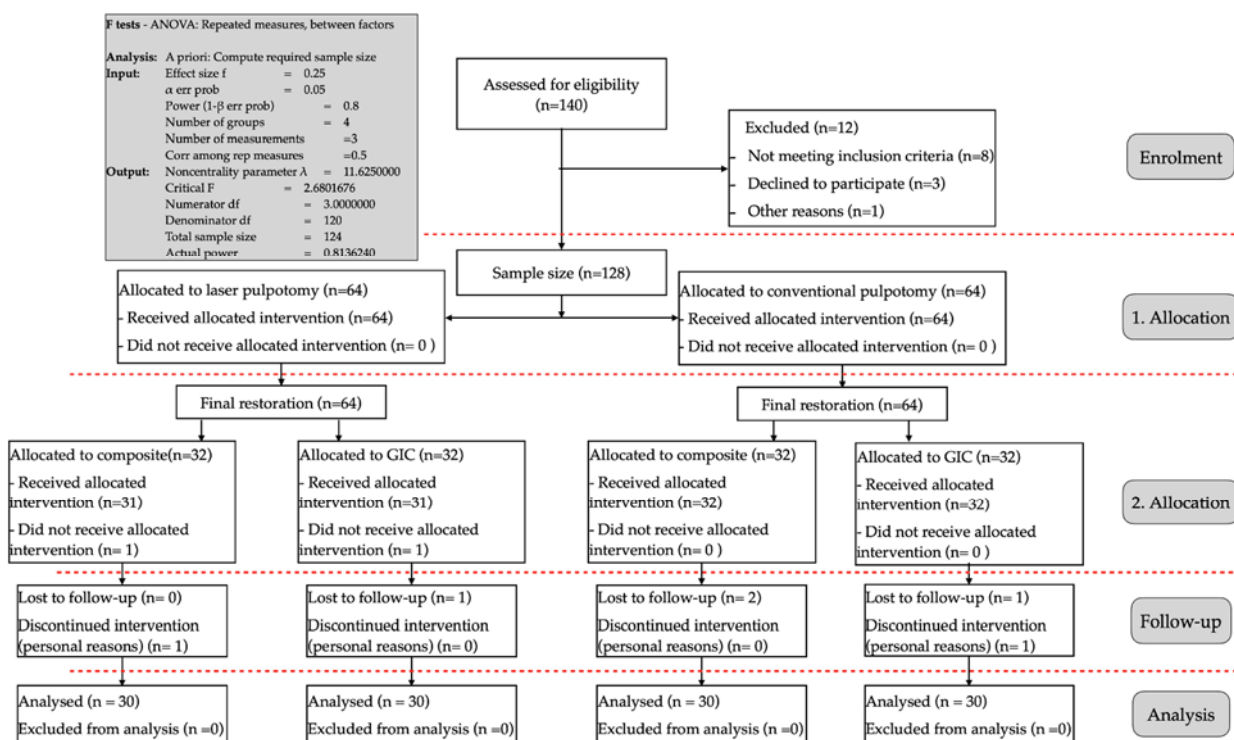


Figure 1. Sample size and the study protocol.

The research included 120 subjects (M:57, F:63) aged 5–8 years. Parents received a written explanation of the entire procedure, while written consent was obtained. Only respondents whose parents signed the informed consent were included in the research. The research was approved by the Ethics Committee of the School of Dental Medicine Zagreb (number: 05-PA-15-10/2017) in accordance with the ethical standards of the Declaration of Helsinki. It included patients with one or more deep carious lesions on primary molars with unresorbed roots and feasible restorative treatment who did not mention the appearance of spontaneous or permanent pain in the anamnesis and in which it is possible to achieve hemostasis with a sterile cotton swab within 5 min after amputation. Patients with the following characteristics: the presence of swelling or fistula, insensitivity to percussion and palpation, pathological mobility, allergy to some of the ingredients of the used materials, children with special needs, and the existence of systemic disease that would further impair oral health were excluded from this research. Before the start of treatment, a clinical examination of the affected tooth, its surrounding structures, and the condition of the tooth root and periapical tissue were performed on an intraoral roentgenogram where radiographic evidence of pulp or periradicular pathosis and calcification in the pulp chamber were additional criteria for the exclusion of participants. Patients were then

randomly divided into two groups. In the first group, 60 subjects underwent pulpotomy using the traditional method with a sterile steel drill (3M/ESPE, Seefeld, Germany) or excavator (LM-Dental, Planmeca, Parainen, Finland) under local anesthesia using Ubistesin forte (3M/ESPE, Seefeld, Germany). In the second group, devitalization was performed using a diode laser with a wavelength of 980 nm LaserHF Comfort (Hager & Werken, Duisburg, Germany). A 3 W laser beam was used continuously through an optical fibre with a diameter of 320 µm in contact with the pulp tissue for two and a half minutes. In both groups, the Biodentine (Septodont, Saint-Maur-des-Fossés, France) was used to cover the root part of the pulp. Each group was further randomly divided into two subgroups according to the type of material for the definitive filling. In the first subgroup, glass ionomer Fuji IX (GC, Tokyo, Japan) was used as a material for permanent fillings, while in the second, the material of choice was Tetric Ceram composite (Ivoclar Vivadent, Schaan, Liechtenstein). Follow-up examinations were carried out 6 months, 12 months, and 24 months after the pulpotomy. During the control examinations, a clinical examination and X-ray analysis using the Gendex™ GXS-700™ sensor (Gendex Dental Systems, Hatfield, PA, USA) of the treated teeth was carried out in the same way as before the procedure. The clinical examination included: intraoral and extraoral visual examination, percussion, and palpation. X-ray analysis was used to observe the continuity of the lamina dura and the existence of periapical lesions in the area that includes the supporting apparatus of the treated tooth, the surrounding tissues of the adjacent two teeth, and the formation area of the permanent tooth underneath. The treatment success criteria were: a tooth without symptoms, no discoloration, no periapical changes, no loss of periodontal attachment, proper radiological findings, and function in occlusion until natural exfoliation. The absence of the mentioned parameters was recorded as 1, and the arithmetic mean was calculated to show success as a percentage of 100%. The quality of the filling was evaluated by the USPHS (United States Public Health Service) criteria, which include monitoring the color change of the filling, the presence of marginal discoloration, secondary caries, preserved marginal integrity, and the change in the surface texture of the filling [30]. Alpha (A), Bravo (B), and Charlie (C) marks were used according to USPHS criteria for the clinical evaluation of fillings (Table 1). The success of the therapy according to the USPHS criteria was calculated as the share of alpha responses, using the formula success = the total number of variables labeled alpha/total number of variables. The subjects who did not respond to control examinations (recall) and/or had the sudden appearance of the disease during the research period were also excluded from the analysis.

Table 1. USPHS criteria for clinical evaluation of restoration [30]. Adapted from ref. [30–33].

Characteristic	A (Alfa)	B (Bravo)	C (Charlie)	D (Delta)
Color	The restoration appears to match the shade and translucency of adjacent tooth tissues.	The restoration does not match the shade and translucency of adjacent tooth tissues, but the mismatch is within the normal range of tooth shades. (Within normal range: similar to silicate cement restorations for which the dentist did not quite succeed in matching tooth color by his choice among available silicate cement shades).	The restoration does not match the shade and translucency of the adjacent tooth structure, and the mismatch is outside the normal range of tooth shades and translucency.	N/A

Table 1. Cont.

Characteristic	A (Alfa)	B (Bravo)	C (Charlie)	D (Delta)
Marginal adaptation	The explorer does not catch when drawn across the surface of the restoration toward the tooth, or, if the explorer does not catch, there is no visible crevice along the periphery of the restoration.	The explorer catches and there is visible evidence of a crevice, which the explorer penetrates, indicating that the edge of the restoration does not adapt closely to the tooth structure. The dentin and/or the base are not exposed, and the restoration is not mobile.	The explorer penetrates a crevice defect extended to the dentin-enamel junction.	Restoration is fractured or completely missing.
Cavosurface marginal discoloration	There is no visual evidence of marginal discoloration different from the color of the restorative material and from the color of the adjacent tooth structure.	There is visual evidence of marginal discoloration at the junction of the tooth structure and the restoration, but the discoloration has not penetrated along the restoration in a pulpal direction.	There is visual evidence of marginal discoloration at the junction of the tooth structure and the restoration that has penetrated along the restoration in a pulpal direction.	N/A
Secondary caries	The restoration is a continuation of the existing anatomic form adjacent to the restoration.	There is visual evidence of dark keep discoloration adjacent to the restoration (but not directly associated with cavosurface margins)	N/A	N/A
Postoperative sensitivity	No postoperative sensitivity	Postoperative sensitivity	N/A	N/A

N/A—Not applicable.

2.2. Statistical Analysis

Descriptive analysis shows the distribution between sex, age, and the success of clinical parameters. The comparison of pulpotomy techniques and the material used for the final restoration after 6, 12, and 24 months were shown with the *t*-test and ANOVA for repeated measures test, while the correlation between the clinical success of the tooth and the USPHS quality of the filling was shown with the Pearson's *r* test, given that the changes in the measured parameters did follow a normal distribution, which was confirmed by the Shapiro–Wilk normality test and the Kolmogorov–Smirnov test for each parameter. Moreover, indicators of asymmetry indicated normal distribution. Results were considered statistically significant at the $p < 0.05$ significance level (correlation at $p < 0.01$). The analysis was performed using the Statistica program package (TIBCO® Statistica™ Version 13.5.0.17., Palo Alto, CA, USA).

3. Results

The results of 57 male and 63 female respondents were statistically processed. There is no statistically significant difference in age distribution between the sexes ($p = 0.613$). The average age of girls was 6.63 years and of boys 6.52 years. The most common age was 7 years in both groups, the lowest was 5, and the highest was 8 years.

The results of the success of clinical parameters depending on the pulpotomy technique at intervals of 6, 12, and 24 months were as follows:

- Teeth without symptoms after 6 months—diode laser 75%, burr 63.33%
- Teeth without symptoms after 12 months—diode laser 86.67%, burr 75%
- Teeth without symptoms after 24 months—diode laser 91.67%, burr 86.67%
- Teeth without periapical change after 6 months—diode laser 73.3%, burr 63.3%
- Teeth without periapical change after 12 months—diode laser 81.67%, burr 75%
- Teeth without periapical change after 24 months—diode laser 93.3%, burr 83.3%
- Teeth without change on X-ray after 6, 12, and 24 months—diode laser 86.67%, burr 73.3%

There was no statistically significant difference in the success of therapy after 6, 12, and 24 months between diode laser and conventional (burr) pulpotomy techniques. However, there is a difference in the success of therapy in the girls group at 12 months ($p = 0.03$) and 24 months ($p = 0.03$) in favor of the diode laser, while there is no difference at 6 months of checkup. In the boys group, there is no difference in any observed interval.

By comparing the success of the therapy according to clinical parameters depending on the material of the final filling, the advantage of the composite material compared to the glass ionomer cement was noticed at 6 months checkup ($p = 0.045$), while in the intervals of 12 and 24 months there was no significant difference between the compared materials.

A descriptive analysis of the USPHS parameters of the composite and GIC is shown in Table 2, while the comparison of restoration quality did not show any statistically significant difference in the intervals of 6, 12, and 24 months. Whether there is a correlation between the quality of the final filling according to the USPHS and the success of the clinical parameters for $p < 0.01$ is shown in Table 3. The most significant correlation was found at an interval of 6 months after the therapy ($k = 0.84$). There are also positive correlations for the intervals of 12 and 24 months after the end of therapy (12 months $k = 0.78$, 24 months $k = 0.68$). The influence of both investigated factors—pulpotomy treatment and final restoration material—on clinical success is shown in Figure 2.

Table 2. Descriptive analysis of USPHS parameters of composites and GICs that had an Alfa rating.

Parameter	Valid N	Composite		GIC		Total	
		Sum	%	Sum	%	Sum	%
USPHS color 6 months	120	52	86.67	47	78.33	99	82.50
USPHS color 12 months	120	49	81.67	43	71.67	92	76.67
USPHS color 24 months	120	40	66.67	39	65.00	79	65.83
USPHS marginal adaptation 6 months	120	52	86.67	47	78.33	99	82.50
USPHS marginal adaptation 12 months	120	49	81.67	41	68.33	90	75.00
USPHS marginal adaptation 24 months	120	37	61.67	36	60.00	73	60.83
USPHS marginal discoloration 6 months	120	52	86.67	47	78.33	99	82.50
USPHS marginal discoloration 12 months	120	45	75.00	38	63.33	83	69.17
USPHS marginal discoloration 24 months	120	36	60.00	36	60.00	72	60.00
USPHS secondary caries 6 months	120	55	91.67	48	80.00	103	85.83
USPHS secondary caries 12 months	120	47	78.33	45	75.00	92	76.67
USPHS secondary caries 24 months	120	47	78.33	45	75.00	92	76.67
USPHS postoperative hypersensitivity 6 mo.	120	54	90.00	48	80.00	102	85.00
USPHS postoperative hypersensitivity 6 mo.	120	53	88.33	48	80.00	101	84.17
USPHS postoperative hypersensitivity 6 mo.	120	51	85.00	43	71.67	94	78.33
Success USPHS 6 months	120	52	86.67	47	78.33	99	82.50
Success USPHS 12 months	120	42	70.00	37	61.67	79	65.83
Success USPHS 24 months	120	32	53.33	34	56.67	66	55.00

GIC—glass ionomer cement.

Table 3. Correlation of the quality of restoration according to USPHS (Success restoration) and the success of clinical parameters (Success).

Correlations						
MD Pairwise Deleted						
Marked Correlations are Significant at $p < 0.01000$						
Variable	Success 6 mo.	Success Restoration 6 mo.	Success 12 mo.	Success Restoration 12	Success 12 mo.	Success Restoration 12
Success 6 mo.	1.000000	0.839654 *				
Success restauration 6 mo.	0.839654 *	1.000000				
Success 12 mo.			1.000000	0.776305 *		
Success restauration 12 mo.			0.776305*	1.000000		
Success 24 mo.					1.000000	0.68467 *
Success restauration 24 mo.					0.68467 *	1.000000

mo.—months, * statistical significance ($p < 0.01$)

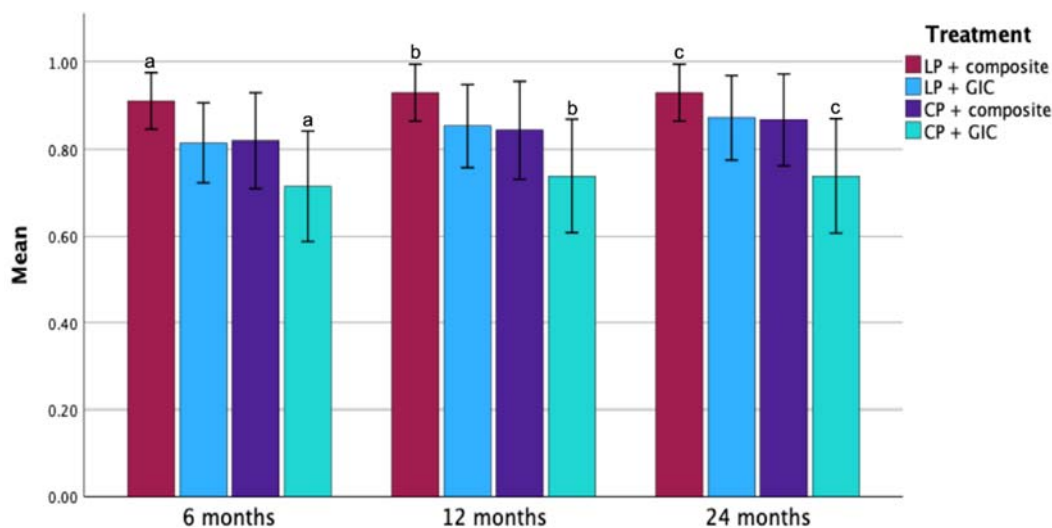


Figure 2. Influence of pulpotomy treatment and final restoration material on clinical success after 6, 12, and 24 months follow-up. LP—laser pulpotomy; CP—conventional pulpotomy; GIC—glass ionomer cement; a, b, and c—statistically significant difference ($p < 0.05$).

4. Discussion

The quest for the optimal treatment technique for the pulp of primary teeth has been a challenge for clinicians for several decades. Given that there are still concerns about the use of formocresol considering its mutagenic, toxic, and carcinogenic effect on humans [34–39], there seems to be a need for an acceptable and biocompatible method as an alternative to the conventional pulpotomy. Considering some of the advantages, such as bleeding control, sterilization, and stimulation of pulp cell healing, among the therapeutic interventions, the use of lasers of different wavelengths is advocated as a possible alternative [40]. Since the laser beam in this process does not come into contact with the tissues, the cutting process does not mechanically affect or damage the irradiated tissues, while the laser itself has the potential to provide an aseptic working field [40].

Up to date, in the available literature, the effectiveness of a number of clinical protocols and medications in the pulp therapy of primary molars has been tested for the purpose of protecting the remaining pulp tissue and promoting healing [19]. Although many different techniques have been tested so far [41], a recent Cochrane review stated that there is no agreement on the most appropriate technique [42].

Among the investigated methods, the diode laser is mentioned as one of the most suitable laser wavelengths for application on the pulp to complete the pulpotomy procedure

due to its high absorption rate [19]. In a very small package, a diode laser uses nearly microscopic chips of gallium arsenide or other useful semiconductors to produce coherent light. Differences within the energy levels in these semiconductors between conduction and valence band electrons provide the basis for laser action. The overall efficiency is therefore much higher and at the same time more practical [43]. The working mechanism of this type of laser is based on the emission of a beam of infrared light and the creation of a well-localized ablation of soft tissues, whereby the laser energy is converted into heat [19]. This reaction is most often accompanied by thermal peripheral tissue damage and tissue loading at the point of impact [44,45]. Due to the high absorption of the wavelength (980 nm) at which energy is produced in tissues such as the dental pulp, which have a very high water content, the diode laser used in this study is more suitable for pulpotomy technique compared to other types of lasers [44,45].

Nowadays, this contact laser is widely used in dental medicine, especially in procedures on soft tissues (e.g., excision, incision, ablation) which are in direct contact with the laser tip (micrometer range) [19]. Unlike soft tissues, the tooth structure absorbs this laser energy relatively poorly, which is why the diode laser has a minimal effect on hard dental tissues. Its application in dental medicine lies in its conductivity through optical fibers while its small size, portability, and relatively low price compared to other types of lasers available on the market additionally contribute to its practicality and accessibility [19]. Additionally, the diode laser offers a number of advantages, including minimal or no bleeding, faster healing, reduced incidence of postoperative infections, and minimal or no need for anesthesia [19,40].

The success of the results of applying the diode laser in pulpotomy differs in the available literature, depending on the spectrum of laser settings and method of use. If the pulp tissue is treated with laser radiation, a surface of coagulation necrosis is formed which is consistent with the underlying tissue and isolates the pulp from the harmful effects of the subbase [26]. Variations in laser application parameters, such as laser power, frequency, exposure time, and water/air dry-mode, result in different pulpal tissue responses varying the clinical and radiographic outcomes [26]. Such findings in the case of laser-assisted pulpotomy may be responsible for the conflicting results obtained in human clinical trials [26]. In general, however, the results of applying diode lasers are at least as good as those of other therapies such as ferrous sulfate, NaOCl, mineral trioxide aggregate (MTA), biodentine, or even better [46–48].

In a review article by Ansari et al. [49] from 2018, it was concluded that laser pulpotomy is better or comparable to formocresol pulpotomy and suggests that it can be considered an alternative for vital pulp therapy on human primary teeth. On the other hand, Lin et al. [50] in their review article concluded that after 18–24 months, formocresol, ferric sulfate, and MTA showed statistically significant better clinical and radiographic outcomes than calcium hydroxide and laser therapies in primary molar pulpotomy. However, in the same review article, drop-out rates were regarded as a failure in the final meta-analysis which could affect the final results and consequently lead to different conclusions.

Taking into account all the above, the data of our research are comparable to those of studies carried out to date. In this study, there is no statistically significant difference in the success of therapy (clinical and radiographic outcomes) after 6, 12, and 24 months between diode laser and conventional (burr) pulpotomy techniques, although in all observed parameters the success of the diode laser was slightly higher. These results are supported by numerous research available in the literature [18,19,25–29,46,48,51–55]. In a study by Ansari et al. [25], there was no statistically significant difference between diode laser (810 nm, 10 W) pulpotomy in a non-contact mode and formocresol pulpotomy of human primary teeth after 6 and 12 months and a 100% clinical success rate of both laser and formocresol was reported. This result is also supported by the results of studies by Huth et al. [51] in which the effectiveness of four pulpotomy techniques (Er:YAG laser, calcium hydroxide, ferric sulfate, dilute formocresol) was examined. Moreover, Durmus and Tanbuga [26] reported that no statistically significant difference was found between

the clinical and radiographic outcomes of pulpotomy treatment performed with a diode laser compared to pulpotomy with formocresol and ferrous sulfate at 6, 9, and 12 months of follow-up. However, considering the radiographic success rate (75%), the question arises whether the application of the diode laser can truly replace the traditional formocresol and ferrous sulfate pulpotomy on primary molars [26]. In 2020, Pei et al. [27] compared clinical and radiographic success rates between a diode laser (915 nm, 2 W) and formocresol pulpotomy in human primary molars followed for 12 months. These results are also consistent with the research of Saltzman et al. [19], in which the split-mouth technique was used to investigate the success rates of a diode laser (980 nm, 3 W) pulpotomy with MTA and formocresol pulpotomy with zinc oxide eugenol (ZOE) with an average follow-up period of 15.7 months; there was no significant difference between these two groups (a similar clinical success rate was 100%). In 2019, Shaikh et al. [52] compared the use of a diode laser (810 nm, 1.5 W) in a continuous mode for 10 s and formocresol for pulpotomy in primary molars. Although no statistically significant difference in radiographic outcomes was found between the two study groups, the diode laser was observed to offer a higher success rate in terms of clinical outcomes. Similar work modes of diode laser were used in the study by Kuo et al. [53] which compared a diode laser (970 nm, 3 W) with sodium hypochlorite intervention or no medication (according to the clinical symptoms and signs and radiographic features) as well in the study by Gupta et al. [18] where 2 min and 31 s exposure to a diode laser (980 nm, 3 W) showed better clinical as well as radiographical results than electrosurgical and ferrous sulfate pulpotomy. In both pieces of research, a clinical success rate of 100% was determined, while the radiographic success rates of the two studies were 97.6% and 100%, respectively, for one-year follow-up and 90.9% for two-year follow-up according to the research by Kuo et al. [18,53]. Research from Uloopi et al. [46] compared the use of a diode laser (810 nm, energy 2 J/cm²) and MTA pulpotomy and found that the success rate of a diode laser is lower, but still comparable to MTA pulpotomy. A similar success rate was noted in the study by Cuadros-Fernández et al. [54] in which the effectiveness of Biodentine as a primary teeth pulpotomy material was demonstrated as it performed similar results as MTA at a 12-month evaluation. Distinctly higher results were found in 2021 in a study by Nayyar et al. [28] in which the combination of a diode laser (810 nm, 1.5 W) and MTA gave better clinical and radiographic success rates compared to pulpotomy procedures performed with MTA alone in 9 months of follow-up, thus concluding that lasers can be an adjuvant alternative for vital pulp therapy in human deciduous teeth. Furthermore, Yadav et al. [48] found higher clinical success rates of diode laser (810 nm, 3 W) than ferrous sulfate nine months after treatment while the radiographic success rate was the same between those two examined groups. In 2022, Kaya et al. [29] compared four different techniques (calcium hydroxide pulpotomy with 820-nm diode laser and calcium hydroxide, formocresol, MTA pulpotomies without biostimulation) in primary molars. Among all groups, no statistically significant difference in clinical success was found at a six-month and one-year follow-up, whereas a decrease in success over time was observed only in the calcium hydroxide group for radiographic outcomes. On the other hand, a study by Ebrahimi et al. [55] in 2022 compared three groups of partial pulpotomy: MTA alone, MTA with low-level laser therapy (660 nm, 200 mW), and MTA with high power (810 nm, 1 W) diode laser radiation. No significant differences in the incidence of clinical or radiographic failure were found between the groups at any interval up to 18 months after therapy, while the addition of low- or high-power diode laser irradiation to the MTA partial pulpotomy procedure did not cause a significant difference in success rates.

Taking into consideration all the aforementioned studies, it is necessary to point out that the differences in the results obtained in the conducted research are caused by numerous factors that determine the long-term success of the procedures, such as proper case selection, strict aseptic protocol, parameters of the laser used, and patient cooperation for the procedure.

Information in the available literature data states that permanent restoration materials can affect the outcome of pulpotomy due to their biological and physical properties [56].

With this in mind, our study took into account the material of the final restoration as a factor (Figure 2), in which a statistically significant difference was observed between the group of subjects designated to diode laser pulpotomy with composite as the final restoration material in comparison to conventional pulpotomy with glass ionomer cement in all three observed time points. Taking these results into account, we partially reject the null hypothesis. The influence of restoration quality on the outcome of pulpotomy has been proven [40,46,57]. By comparing the success of the therapy according to clinical parameters depending on the material of the final restoration in this study, the advantage of the composite material compared to the glass ionomer cement was noticed in the interval of 6 months ($p = 0.045$), while in the intervals of 12 and 24 months there was no significant difference between compared materials. Furthermore, the USPHS criteria decreased through the intervals of 6, 12, and 24 months in both tested final restoration materials, of which the composite showed greater stability. Additionally, the relationship between the quality of restoration according to the USPHS and the success of clinical parameters after pulpotomy was analyzed on each follow-up indicates an undoubted connection between the quality of the final restoration and the performed procedure. These results could be explained by the fact that although composites, due to their hardness and strength, are suitable for the molar region where the occlusal forces are stronger, they can develop a marginal crack due to polymerization shrinkage [57]. On the other hand, glass ionomers are bioactive materials and therefore acceptable for primary dentition, but due to weaker physical-mechanical properties, they are prone to wear [57]. It is necessary to emphasize the limitations of this research. First, in this study, there was a relatively short follow-up period (only up to 24 months), which is why the long-term outcomes of the therapy and procedures performed could not be predicted with certainty. Another possible limitation is the lack of evaluation at the histological level, given that it relied entirely on the clinical and radiographic profile as well as the results of the performed procedures, which can sometimes lead researchers in the wrong direction of thinking. For the above reasons, this research warrants the need for further studies to be conducted on larger sample sizes and with longer follow-up periods (e.g., five-year follow-up) in order to reach valid conclusions.

5. Conclusions

Due to the minimal invasiveness and increased patient cooperation, lasers can be used as an adequate replacement, supplementary diagnostic, or therapeutic choice in preventive and restorative dental medicine, as well as in endodontics. During endodontic laser procedures on primary teeth, clinicians must pay attention to the influence of the laser on the pulp and root canals of primary teeth, bearing in mind the anatomy of the apical openings and the depth of penetration of the laser into the tissues. The limiting factors for the use of lasers in dental medicine are the necessary education and experience of clinicians, as well as the price and availability of lasers on the market. Given that it provides numerous benefits from the patient's point of view, as well as the dentist's, in pedodontics, a laser is a valuable tool in the provision of dental care. Although a statistically significant difference between laser pulpotomy and conventional, i.e., vital pulpotomy was not confirmed in this study, a slightly higher success rate in favor of the diode laser was noted. However, this research indicates that the quality of the final restoration of an endodontically treated tooth immensely contributes to the success of the therapeutic intervention, regardless of the pulpotomy method used. To sum up, regardless of the fact that this is a significant shift in this scientific field in terms of longer follow-up compared to most of the earlier research, we believe that 2 years is not enough to give a definitive conclusion about the durability of an endodontically treated tooth. Guided by this thought, future studies should be conducted on a larger number of subjects and with a longer period of follow-up (e.g., 5 years).

Author Contributions: Conceptualization, R.B. and D.N.V.; methodology, D.N.V.; software, L.Š.; validation, D.N.V.; formal analysis, L.Š.; investigation, R.B.; data curation, L.Š.; writing—original draft preparation, L.Š., B.Š. and L.V.; writing—review and editing, L.Š., B.Š., L.V. and D.N.V.; visualization, L.Š.; supervision, D.N.V.; project administration, L.Š. and B.Š. All authors have read and agreed to the published version of the manuscript.

Funding: This research received no external funding.

Institutional Review Board Statement: The study was conducted in accordance with the Declaration of Helsinki, and approved by the Institutional Review Board, University of Zagreb, School of Dental Medicine (05-PA-15-10/2017).

Informed Consent Statement: Informed consent was obtained from all subjects involved in the study.

Data Availability Statement: Not applicable.

Conflicts of Interest: The authors declare no conflict of interest.

References

- Nazemisalman, B.; Farsadeghi, M.; Sokhansanj, M. Types of Lasers and Their Applications in Pediatric Dentistry. *J. Lasers Med. Sci.* **2015**, *6*, 96–101. [[CrossRef](#)] [[PubMed](#)]
- De Coster, P.; Rajasekharan, S.; Martens, L. Laser-assisted pulpotomy in primary teeth: A systematic review. *Int. J. Paediatr. Dent.* **2013**, *23*, 389–399. [[CrossRef](#)] [[PubMed](#)]
- Kornblit, R.; Trapani, D.; Bossù, M.; Muller-Bolla, M.; Rocca, J.P.; Polimeni, A. The use of Erbium:YAG laser for caries removal in paediatric patients following Minimally Invasive Dentistry concepts. *Eur. J. Paediatr. Dent.* **2008**, *9*, 81–87. [[PubMed](#)]
- Pala, S.P.; Nuvvula, S.; Kamatham, R. Expression of pain and distress in children during dental extractions through drawings as a projective measure: A clinical study. *World J. Clin. Pediatr.* **2016**, *5*, 102–111. [[CrossRef](#)] [[PubMed](#)]
- Bahrololoomi, Z.; Fekrazad, R.; Zamaninejad, S. Antibacterial Effect of Diode Laser in Pulpotomy of Primary Teeth. *J. Lasers Med. Sci.* **2017**, *8*, 197–200. [[CrossRef](#)]
- Bahrololoomi, Z.; Poursina, F.; Birang, R.; Foroughi, E.; Yousefshahi, H. The Effect of Er:YAG Laser on Enterococcus faecalis Bacterium in the Pulpotomy of Anterior Primary Teeth. *J. Lasers Med. Sci.* **2017**, *8*, 166–171. [[CrossRef](#)]
- Parker, S.; Cronshaw, M.; Anagnostaki, E.; Mylona, V.; Lynch, E.; Grootveld, M. Current Concepts of Laser-Oral Tissue Interaction. *Dent. J.* **2020**, *8*, 61. [[CrossRef](#)]
- Kumar, M.; Grishmi, M.; Girish, N.; Harish, B. State of the art laser technology in dentistry. *IERJ* **2017**, *3*, 3–6.
- Dhar, V.; Marghalani, A.A.; Crystal, Y.O.; Kumar, A.; Ritwik, P.; Tulunoglu, O.; Graham, L. Use of Vital Pulp Therapies in Primary Teeth with Deep Caries Lesions. *Pediatr. Dent.* **2017**, *39*, 146–159.
- Chung, H.; Dai, T.; Sharma, S.K.; Huang, Y.Y.; Carroll, J.D.; Hamblin, M.R. The nuts and bolts of low-level laser (light) therapy. *Ann. Biomed. Eng.* **2012**, *40*, 516–533. [[CrossRef](#)]
- David, C.M.; Gupta, P. Laser in Dentistry: A Review. *Int. J. Adv. Health Sci.* **2015**, *2*, 7–13.
- Caprioglio, C.; Olivi, G.; Genovese, M.D. Paediatric laser dentistry. Part 1: General introduction. *Eur. J. Paediatr. Dent.* **2017**, *18*, 80–82.
- Najeeb, S.; Khurshid, Z.; Zafar, M.S.; Ajlal, S. Applications of Light Amplification by Stimulated Emission of Radiation (Lasers) for Restorative Dentistry. *Med. Princ. Pract.* **2015**, *25*, 201–211. [[CrossRef](#)] [[PubMed](#)]
- Patil, U.A. Overview of lasers. *Indian J. Plast. Surg.* **2008**, *41*, 101–113. [[CrossRef](#)]
- Baraba, A.; Miletić, I.; Jukić Krmek, S.; Perhavec, T.; Božić, Ž.; Anić, I. Ablative Potential of the Erbium-Doped Yttrium Aluminium Garnet Laser and Conventional Handpieces: A Comparative Study. *Photomed. Laser Surg.* **2009**, *27*, 921–927. [[CrossRef](#)] [[PubMed](#)]
- Kuzekanani, M.; Plotino, G.; Gutmann, J.L. Current applications of lasers in endodontics. *G. Ital. Di Endod.* **2019**, *33*, 13–23.
- Bago Jurić, I.; Anić, I. The Use of Lasers in Disinfection and Cleaning of Root Canals: A Review. *Acta Stomatol. Croat.* **2014**, *48*, 6–15. [[CrossRef](#)]
- Gupta, G.; Rana, V.; Srivastava, N.; Chandna, P. Laser Pulpotomy—An Effective Alternative to Conventional Techniques: A 12 Months Clinico radiographic Study. *Int. J. Clin. Pediatr. Dent.* **2015**, *8*, 18–21. [[CrossRef](#)]
- Saltzman, B.; Sigal, M.; Clokie, C.; Rukavina, J.; Titley, K.; Kulkarni, G.V. Assessment of a novel alternative to conventional formocresol-zinc oxide eugenol pulpotomy for the treatment of pulpally involved human primary teeth: Diode laser-mineral trioxide aggregate pulpotomy. *Int. J. Paediatr. Dent.* **2005**, *15*, 437–447. [[CrossRef](#)]
- Ambika, S.; Suchitra, M.S. Diode Laser in Pediatric Dentistry. *IJSR* **2018**, *7*, 363–369.
- Bagchi, P.; Kashyap, N.; Biswas, S. Pulpotomy: Modern concepts and materials. *Int. J. Oral Health Dent.* **2021**, *7*, 245–252.
- Payahoo, S.; Jamali, S.; Jabbari, G.; Jamee, A. Efficacy of lasers treatment of exposed pulps to stimulate healing: A systematic review and meta-analysis. *Pesqui. Bras. Em Odontopediatria E Clínica Integr.* **2020**, *20*, 51. [[CrossRef](#)]
- Caprioglio, C.; Olivi, G.; Genovese, M.D.; Vitale, M.C. Paediatric laser dentistry. Part 3: Dental trauma. *Eur. J. Paediatr. Dent.* **2017**, *18*, 247–250. [[PubMed](#)]

24. Olivi, G.; Caprioglio, C.; Olivi, M.; Genovese, M.D. Paediatric laser dentistry. Part 2: Hard tissue laser applications. *Eur. J. Paediatr. Dent.* **2017**, *18*, 163–166. [[PubMed](#)]
25. Ansari, G.; Chitsazan, A.; Fekrazad, R.; Javadi, F. Clinical and Radiographic Evaluation of Diode Laser Pulpotomy on Human Primary Teeth. *Laser Ther.* **2018**, *27*, 187–192. [[CrossRef](#)]
26. Durmus, B.; Tanboga, I. In vivo evaluation of the treatment outcome of pulpotomy in primary molars using diode laser, formocresol, and ferric sulphate. *Photomed. Laser Surg.* **2014**, *32*, 289–295. [[CrossRef](#)]
27. Pei, S.; Shih, W.; Liu, J. Outcome Comparison between Diode Laser Pulpotomy and Formocresol Pulpotomy on Human Primary Molars. *J. Dent. Sci.* **2020**, *15*, 163–167. [[CrossRef](#)]
28. Nayyar, A.; Satyarth, S.; Alkhamis, A.; Almunahi, H.; Abdulaziz Alsuheybi, M.; Vadde, H.; Senapathi, S.N.; Shami, A.; Aldrewhesh, R. Comparative Evaluation of Mineral Trioxide Aggregate Pulpotomy and Laser-Assisted Mineral Trioxide Aggregate Pulpotomy: An Original Research Article. *J. Microsc. Ultrastruct.* **2021**, *9*, 7. [[CrossRef](#)]
29. Kaya, C.; Elbay, Ü.Ş.; Elbay, M.; Uçar, G. The Comparison of Calcium Hydroxide + Biostimulation, Calcium Hydroxide, Formocresol, and MTA Pulpotomies without Biostimulation in Primary Teeth: 12-Months Clinical and Radiographic Follow-Up. *Lasers Med. Sci.* **2022**, *37*, 2545–2554. [[CrossRef](#)]
30. Ryge, G. Clinical criteria. *Int. Dent. J.* **1980**, *30*, 347–358.
31. Sadeghi, M.; Lynch, C.D.; Shahamat, N. Eighteen-Month Clinical Evaluation of Microhybrid, Packable and Nanofilled Resin Composites in Class I Restorations. *J. Oral. Rehab.* **2010**, *37*, 532–537. [[CrossRef](#)] [[PubMed](#)]
32. Türkün, L.Ş.; Türkün, M.; Özata, F. Two-Year Clinical Evaluation of a Packable Resin-Based Composite. *J. Am. Dent. Assoc.* **2003**, *134*, 1205–1212. [[CrossRef](#)] [[PubMed](#)]
33. Türkün, L.Ş.; Aktener, B.O. Twenty-Four-Month Clinical Evaluation of Different Posterior Composite Resin Materials. *J. Am. Dent. Assoc.* **2001**, *132*, 196–203. [[CrossRef](#)] [[PubMed](#)]
34. Petticrew, M. Systematic reviews from astronomy to zoology: Myths and misconceptions. *BMJ* **2001**, *322*, 98–101. [[CrossRef](#)]
35. Ranly, D.M. Pulpotomy therapy in primary teeth: New modalities for old rationales. *Pediatr. Dent.* **1994**, *18*, 403–409.
36. 's-Gravenmade, E.J. Some biochemical considerations of fixation in endodontics. *J. Endod.* **1975**, *1*, 233–237. [[CrossRef](#)]
37. Ranly, D.M.; Lazzari, E.P. A biochemical study of two bifunctional reagents as alternatives to formocresol. *J. Dent. Res.* **1983**, *62*, 1054–1057. [[CrossRef](#)]
38. Goldmacher, V.S.; Tilley, W.G. Formocresol is mutagenic for cultured human fibroblasts. *Mutat. Res.* **1983**, *116*, 417–422. [[CrossRef](#)]
39. Hill, S.D.; Berry, C.W.; Seale, N.S.; Kaga, M. Comparison of antimicrobial and cytotoxic effects of glutaraldehyde and formocresol. *Oral Surg. Oral Med. Oral Pathol.* **1991**, *71*, 89–95. [[CrossRef](#)]
40. Odabas, M.E.; Bodur, H.; Baris, E.; Demir, C. Clinical, radiographic, and histopathologic evaluation of Nd:YAG laser pulpotomy on human primary teeth. *J. Endod.* **2007**, *33*, 415–421. [[CrossRef](#)]
41. Ranly, D.M.; Garcia-Godoy, F. Current and potential pulp therapies for primary and young permanent teeth. *J. Dent.* **2000**, *28*, 153–161. [[CrossRef](#)]
42. Nadin, G.; Goel, B.R.; Yeung, C.A.; Glenney, A.M. Pulp treatment for extensive decay in primary teeth. *Cochrane Database Syst. Rev.* **2003**, Cd003220. [[CrossRef](#)]
43. Lerner, E.J. Diode lasers offer efficiency and reliability. *Laser Focus World* **1998**, *34*, 93–98.
44. Miserendino, L.J.; Neiburger, E.J.; Walia, H.; Luebke, N.; Brantley, W. Thermal effects of continuous wave CO2 laser exposure on human teeth: An in vitro study. *J. Endod.* **1989**, *15*, 302–305. [[CrossRef](#)]
45. Jeffrey, I.W.; Lawrenson, B.; Saunders, E.M.; Longbottom, C. Dental temperature transients caused by exposure to CO2 laser irradiation and possible pulpal damage. *J. Dent.* **1990**, *18*, 31–36. [[CrossRef](#)]
46. Uloopi, K.S.; Vinay, C.; Ratnaditya, A.; Gopal, A.S.; Mrudula, K.J.; Rao, R.C. Clinical evaluation of low level diode laser application for primary teeth pulpotomy. *J. Clin. Diagn. Res.* **2016**, *10*, ZC67–ZC70. [[CrossRef](#)] [[PubMed](#)]
47. Krothapalli, N.; Prasad, M.G.; Vasa, A.A.; Divya, G.; Thakur, M.S.; Saujanya, K. Clinical evaluation of outcome of primary teeth pulpotomy using mineral trioxide aggregate, laser and biodentine—an in vivo study. *J. Clin. Diagn. Res.* **2015**, *9*, ZC35–ZC37.
48. Yadav, P.; Indushekar, K.; Saraf, B.; Sheoran, N.; Sardana, D. Comparative evaluation of ferric sulfate, electrosurgical and diode laser on human primary molars pulpotomy: An “in-vivo” study. *Laser Ther.* **2014**, *23*, 41–47. [[CrossRef](#)]
49. Ansari, G.; Aghdam, H.S.; Taheri, P.; Ahsaie, M.G. Laser pulpotomy—An effective alternative to conventional techniques—A systematic review of literature and meta-analysis. *Laser Med. Sci.* **2018**, *33*, 1621–1629. [[CrossRef](#)]
50. Lin, P.Y.; Chen, H.S.; Wang, Y.H.; Tu, Y.K. Primary molar pulpotomy: A systematic review and network meta-analysis. *J. Dent.* **2014**, *42*, 1060–1077. [[CrossRef](#)]
51. Huth, K.C.; Paschos, E.; Hajek-Al-Khatat, N.; Hollweck, R.; Crispin, A.; Hickel, R.; Folwaczny, M. Effectiveness of 4 pulpotomy techniques—randomized controlled trial. *J. Dent. Res.* **2005**, *84*, 1144–1148. [[CrossRef](#)] [[PubMed](#)]
52. Shaikh, M.N.; Jha, M.N.; Undre, M.I.; Ershad, A.; Shaikh, T.N. Outcome of Pulpotomy in Primary Teeth Using Diode Laser. *J. Contemp. Dent.* **2019**, *9*, 72–77. [[CrossRef](#)]
53. Kuo, H.Y.; Lin, J.R.; Huang, W.H.; Chiang, M.L. Clinical outcomes for primary molars treated by different types of pulpotomy: A retrospective cohort study. *J. Formos. Med. Assoc.* **2018**, *117*, 24–33. [[CrossRef](#)] [[PubMed](#)]
54. Cuadros-Fernández, C.; Lorente Rodríguez, A.I.; Sáez-Martínez, S.; García-Binimelis, J.; About, I.; Mercadé, M. Short-term treatment outcome of pulpotomies in primary molars using mineral trioxide aggregate and Biodentine: A randomized clinical trial. *Clin. Oral Investig.* **2016**, *20*, 1639–1645. [[CrossRef](#)] [[PubMed](#)]

55. Ebrahimi, M.; Changiz, S.; Makarem, A.; Ahrari, F. Clinical and Radiographic Effectiveness of Mineral Trioxide Aggregate (MTA) Partial Pulpotomy with Low Power or High Power Diode Laser Irradiation in Deciduous Molars: A Randomized Clinical Trial. *Lasers Med. Sci.* **2022**, *37*, 2293–2303. [[CrossRef](#)]
56. Khademi, A.; Akhlaghi, N. Outcomes of Vital Pulp Therapy in Permanent Teeth with Different Medicaments Based on Review of the Literature. *Dent. Res. J.* **2015**, *12*, 406. [[CrossRef](#)]
57. Demarco, F.F.; Rosa, M.S.; Tarquinio, S.B.C.; Piva, E. Influence of the Restoration Quality on the Success of Pulpotomy Treatment: A Preliminary Retrospective Study. *J. Appl. Oral Sci.* **2005**, *13*, 72–77. [[CrossRef](#)]