

Comparison of the effectiveness of various rotary and reciprocating systems with different surface treatments to remove gutta-percha and an epoxy resin-based sealer from straight root canals

Bago, I.; Suk, M.; Katić, M.; Gabrić, D.; Anić, I.

Source / Izvornik: **International Endodontic Journal**, 2018, 52, 105 - 113

Journal article, Published version

Rad u časopisu, Objavljena verzija rada (izdavačev PDF)

<https://doi.org/10.1111/iej.12985>

Permanent link / Trajna poveznica: <https://urn.nsk.hr/urn:nbn:hr:127:041911>

Rights / Prava: [In copyright](#) / [Zaštićeno autorskim pravom.](#)

Download date / Datum preuzimanja: **2025-02-10**



Repository / Repozitorij:

[University of Zagreb School of Dental Medicine
Repository](#)



Comparison of the effectiveness of various rotary and reciprocating systems with different surface treatments to remove gutta-percha and an epoxy resin-based sealer from straight root canals

I. Bago¹ , M. Suk¹, M. Katić², D. Gabrić³ & I. Anić¹

¹Department of Endodontics and Restorative Dentistry, School of Dental Medicine; ²Department of Quality, Faculty of Mechanical Engineering and Naval Architecture; and ³Department of Oral Surgery, School of Dental Medicine, University of Zagreb, Zagreb, Croatia

Abstract

Bago I, Suk M, Katić M, Gabrić D, Anić I. Comparison of the effectiveness of various rotary and reciprocating systems with different surface treatments to remove gutta-percha and an epoxy resin-based sealer from straight root canals. *International Endodontic Journal*, 52, 105–113, 2019.

Aim To compare the Reciproc Blue, Reciproc and ProTaper Universal Retreatment systems with regard to the effective removal of epoxy resin-based sealer and gutta-percha during the retreatment of oval, straight root canals.

Methodology Forty-five extracted, human mandibular first premolars with single straight oval canals were selected on the basis of cone beam computed tomography evaluations. The root canals were instrumented with the ProTaper Next system up to the X2 file, and filled with gutta-percha and epoxy resin-based sealer using the cold lateral condensation technique. After 1 month, the samples were randomly divided into three groups ($n = 15$) according to the retreatment system used: Reciproc Blue R40, Reciproc R40 and ProTaper Universal. The specimens were scanned at the resolution of 1.2 μm by a

microcomputed tomography device after the root filling and retreatment procedures, and the decrease in the volume of filling material after each retreatment protocol was measured. The results were analysed using the Kruskal–Wallis test and additional box-and-whisker plots.

Results Although the volume of the filling material decreased significantly in all three groups ($P < 0.05$), none of the systems removed the material completely. The Reciproc system removed significantly more material than the ProTaper Universal ($P < 0.001$) and Reciproc Blue ($P = 0.005$) systems, with the latter two exhibiting equal volumes of remaining material ($P = 0.068$).

Conclusion The Reciproc system was more effective than the Reciproc Blue and ProTaper Universal Retreatment systems during the removal of filling material from oval, straight canals, although none of the systems completely removed the filling material.

Keywords: gutta-percha, microcomputed tomography, ProTaper, Reciproc, retreatment, sealer.

Received 25 January 2018; accepted 6 July 2018

Correspondence: Ivona Bago, Department of Endodontics and Restorative Dentistry, School of Dental Medicine, University of Zagreb, Gundulićeva 5, 10 000 Zagreb, Croatia (Tel.: +38514802128; Fax: +38524802159; e-mail: bago@sfzg.hr).

Introduction

The main cause of post-treatment disease after root canal treatment is persistent and secondary intraradicular infection (Haapasalo *et al.* 2008, Siqueira *et al.* 2014). Teeth with apical periodontitis that either persisted or developed after initial root

canal treatment are most often indicated for retreatment. The success rate for well-performed retreatment with appropriate measures for the control and prevention of endodontic infection in cases of post-treatment disease ranges from 62% to 85.9% (Farzaneh *et al.* 2004, Imura *et al.* 2007). The reasons for a lower success rate for retreatment than for initial root canal treatment include long-term intracanal infection with resistant persistent bacteria, development of intratubular infection and difficulty in removal of the previous filling material in order to access the bacteria (Siqueira 2011).

During retreatment, the previous root filling can be removed by hand or rotary, reciprocating or ultrasonic instruments. Although it has not been proven that the complete removal of filling material is mandatory for a positive outcome, filling remnants can prevent effective root canal irrigation and disinfection (Ng *et al.* 2008), thus, compromising the bond between the sealer of the new root filling and dentine (Rached-Junior *et al.* 2014). Many studies have compared different retreatment techniques. Comparisons between manual instrumentation and various mechanical instrumentation have yielded contradictory results depending on the initial root canal preparation size, canal morphology (straight, curved, oval) (Rodrigues *et al.* 2016, Yilmaz *et al.* 2018), filling material (Hammad *et al.* 2008, Rossi-Fedele & Aly Ahmed 2017, Yilmaz *et al.* 2018) and filling technique (Ma *et al.* 2012, Rödiger *et al.* 2018). Several previous studies reported the efficacy of reciprocating instruments [Reciproc (VDW, Munich, Germany) and WaveOne] for the retreatment of straight and curved canals, albeit without complete removal of the filling materials (Fruchi *et al.* 2014, Bernardes *et al.* 2016, Monquilhott Crozeta *et al.* 2016a,b). Compared with rotary retreatment systems, reciprocating instruments were, in some studies, more efficient in the removal of epoxy resin-based sealer and zinc-oxide sealer (Zuolo *et al.* 2013, Monquilhott Crozeta *et al.* 2016a). Another study reported that rotary files were more efficient than Reciproc files in the removal of apical filling material (Monquilhott Crozeta *et al.* 2016b), whilst yet another study reported similar efficacies for both systems, regardless of the canal anatomy (Rödiger *et al.* 2014, Rossi-Fedele & Aly Ahmed 2017).

AH Plus (Dentsply DeTrey, Konstanz, Germany) is an epoxy resin-based root canal sealer, that has been widely used due to its good sealing ability and adhesion (Cobankara *et al.* 2006), low solubility and disintegration (Versiani *et al.* 2006). Its retreatability has

been investigated and compared with other sealers in past studies. In a study by Kim *et al.* (2015), the epoxy resin-based sealer had retreatment characteristics comparable to a calcium silicate-based sealer, which was explained by their similar adhesion and penetrability in dentinal tubules (Zhang *et al.* 2009, Ersahan & Aydin 2010). Similar results have also been reported (Ersev *et al.* 2012, Suk *et al.* 2017). However, complete removal of the epoxy resin-based sealer has not been achieved in any of the previously published study regardless of the filling technique and retreatment technique used (Bernardes *et al.* 2016, Monquilhott Crozeta *et al.* 2016a, Nevares *et al.* 2016, Rödiger *et al.* 2018).

The ProTaper Universal (PTU) Retreatment system has been evaluated in straight and curved root canals and has been reported to be effective, however, it has been associated with procedural errors (instrument fractures and perforations) in curved canals (Ersev *et al.* 2012, Ma *et al.* 2012, Rödiger *et al.* 2014, 2018). The system consists of three instruments (D1, D2 and D3) that have convex and triangular cross section. The D1 (size 30, .09 taper) instrument has an active working tip and is created for the removal of cervical third of filling material. The D2 (size 25, .08 taper) instrument is used in the middle part of the root canal, and the D3 (size 20, .07 taper) instrument for the removal of filling material from the entire canal. These instruments are developed to gain working length during retreatment and require the use of additional instruments to remove the remaining filling material.

The Reciproc Blue (VDW, Munich, Germany) system belongs to a new generation of single-file reciprocating systems and was recently introduced in the market. The manufacturing process for Reciproc Blue instruments involves heat treatment to alter the molecular structure of the M-Wire instrument, which increases the flexibility and resistance to cyclic fatigue (Topçuoğlu & Topçuoğlu 2017). The instrument design (S-shaped cross section, two cutting edges and a noncutting tip) and instrumentation technique are the same for the Reciproc and Reciproc Blue systems. In addition, according to the manufacturer, Reciproc Blue files can also be used for retreatment.

The aim of this study was to compare the Reciproc Blue, Reciproc and PTU Retreatment systems with regard to the effective removal of epoxy resin-based sealer and gutta-percha during the retreatment of oval, straight root canals. The null hypothesis of the study was that there are no significant differences in

the endodontic retreatment abilities of the Reciproc Blue, Reciproc and PTU systems.

Materials and Methods

Preparation of samples

The study protocol was approved by the Ethics Committee School of Dental Medicine, University of Zagreb (approval no. 05-PA-26-11/2016). The study sample comprised 45 extracted human premolars with a single straight oval canal, which had been selected on the basis of cone beam computed tomography (CBCT) evaluations (Cranex 3DX, Soredex, Tuusula, Finland) performed under the following parameters: field of view, 5 × 5 (5.0 mm) mm; ENDO, 85 µm; 6.3 mA; 90 kV; 8.7 s; and 450.3 mGycm². The canals were classified as oval if the buccolingual diameter was more than 2.5 times larger than the mesiodistal diameter (De-Deus *et al.* 2010). Only teeth with oval root canals were included. Premolars with previous endodontic treatment, intracanal calcifications, root caries, external resorption and/or internal resorption were not included.

The teeth were prepared according to the protocol described by Suk *et al.* (2017). Access openings were prepared using a water-cooled diamond fissure bur No. 016 (Komet, Rock Hill, SC, USA). The tooth crown was cut to standardize the working length at 15 mm. Canal patency was confirmed by the insertion of a size 10 K-file (Dentsply Sirona Endodontics, Ballaigues, Switzerland) through the apical foramen before and after canal preparation. Teeth with apical foramen having diameters smaller than those of a size 15 K-file or larger than those of a size 20 K-file were not included. The root canals were prepared by a single operator (MS) using the ProTaper Next (PTN) rotary system (Dentsply Sirona Endodontics). The PTN X1, X2 and X3 (master apical file, MAF; size 30, .07 taper) files were used up to the working length. During instrumentation, 10 mL of 2.5% sodium hypochlorite (NaOCl) was used for canal irrigation via a 30G needle (BD, Microlance, Becton Dickinson, Madrid, Spain). After chemomechanical instrumentation, the intracanal smear layer was removed by the final rinsing protocol: 1 mL of 15% ethylene diaminetetraacetic acid (Calsinase, Lege artis, Dettenhausen, Germany) for 1 min, 1 mL of 2.5% NaOCl for 30 s and 1 mL of saline solution for 30 s. The canals were dried with sterile PTN X3 paper points (Dentsply Sirona Endodontics).

Subsequently, the dried canals were obturated with gutta-percha points and epoxy resin-based sealer (AH Plus) using the cold lateral condensation technique. The sealer was inserted into the canal using a PTN X3 gutta-percha point (Dentsply Sirona Endodontics) placed up to the working length. For lateral condensation, a size 25 hand spreader (Anataeos, München, Germany) and additional size 25, .02 taper gutta-percha points (DiaDent, Seoul, Korea) were used. The gutta-percha points were coated with the sealer before insertion into the root canal. The canals were filled up to 1 mm short of the root apex. Following canal filling, the access cavities were restored with a temporary restoration material (Cavition, GC, Tokyo, Japan), and the quality of root filling was confirmed on CBCT (Cranex 3DX) images. Then, all samples were stored at 37 °C and 100% relative humidity for 1 month.

Root canal retreatment

The prepared samples were randomly divided into three experimental groups according to the retreatment system used ($n = 15$). One independent researcher, who did not know the aim of the study, took samples individually from a group of samples placed in an envelope by random selection and assigned them to one of the groups. One experienced operator (IB) performed the retreatment procedures for all samples.

Group I: Reciproc Blue system

In Group I, the R40 file (size 40, .06 taper) from the Reciproc Blue system was used with the VDW Gold motor (VDW) set in the reciprocating mode. The instrument was advanced apically using an in-and-out pecking motion with an amplitude of approximately 3 mm. According to the manufacturer's instructions, gentle apical pressure was applied with a brushing action against the lateral walls. After three pecking motions, the instrument was removed from the canal and cleaned with sterile gauze, and the canal was irrigated with 2.5% NaOCl. This procedure was repeated until the instrument reached working length.

Group II: Reciproc system

In Group II, the R40 file (size 40, .06 taper) from the Reciproc system was used with the VDW Gold motor (VDW) set in the reciprocating mode. The retreatment technique was the same as that described for Group 1.

Group III: ProTaper Universal retreatment system

In Group III, the retreatment procedure was performed using the PTU Retreatment system (Dentsply Sirona Endodontics). The working parameters were as follows: speed, 300 rpm and torque, 2.5 N cm⁻². The D1 file was used for removal of the material from the coronal part of the canal, whilst the D2 and D3 files were used for removal of the material from the middle and apical thirds of the canal. The canal was further prepared with the X3 (size 30, .07 taper) and X4 (size 40, .06 taper) files used up to the working length (Bernardes *et al.* 2016). After instrumentation with each file, the root canal was flushed with 2.5% NaOCl.

A total of 15 mL of NaOCl were used during each retreatment procedure. Each instrument was used for the retreatment and instrumentation of three root canals. Retreatment was considered complete when each instrument reached the working length five times (Bernardes *et al.* 2016).

After mechanical retreatment, the root canals were irrigated with 1 mL of 2.5% NaOCl using a 30G needle and syringe, filled with 15% EDTA that was left in the canal for 3 min, rinsed with 1 mL of 2.5% NaOCl and dried with sterile paper points.

Micro-computed tomography (Micro-CT)

For analysis of remnant filling material after rotary retreatment, all specimens were scanned by a micro-CT device after the filling procedure and after the rotary retreatment.

The volume of filling material was measured using an industrial micro-CT (Nikon XT H 225, Tring, UK) device with a target having a focal size of 0.7 µm and a 400 × 300-mm, 14-bit flat panel detector with a 127-µm pixel size. Samples were measured at 80 kV and 60 µA using 1600 projections at an exposure time of 1 s. The geometrical magnification was ≈100, which yielded a structural resolution of 1.2 µm. All samples were measured at the same position and same radiation settings. Similar postprocessing procedures were performed for all measurement sets; beam hardening was reduced using a Hanning filter, noise was reduced using a median filter and surface detection was performed using an adaptive search algorithm (Volume Graphics VGMax 2.2). During analysis, the filling material was treated as an inclusion in the base tooth material; this was possible because of very distinct greyscale values for the tooth and filling material (typically 10 000 and 40 000, respectively). With the greyscale value for the tooth

as the base value, a simple threshold algorithm was used to detect the volume of filling material in the internal tooth volume. The result was expressed as a percentage of the filling material in the base (tooth) material using relational values. The variation in sample volumes was effectively excluded from the analysis of the material removal rate. The same procedure was applied for all samples before and after the retreatment, thus, providing a constant metric for the rate of removal of material in the root canal.

Statistical analysis

The decrease in the amount of filling material after each retreatment protocol was analysed using the Kruskal–Wallis test and additional box-and-whisker plots. A *P*-value of <0.05 was considered statistically significant. All statistical analyses were performed using IBM SPSS version 23.0 (IBM, Armonk, New York, NY, USA).

Results

There were no significant differences in the initial filling volume of the filling material amongst the samples (*P* > 0.05).

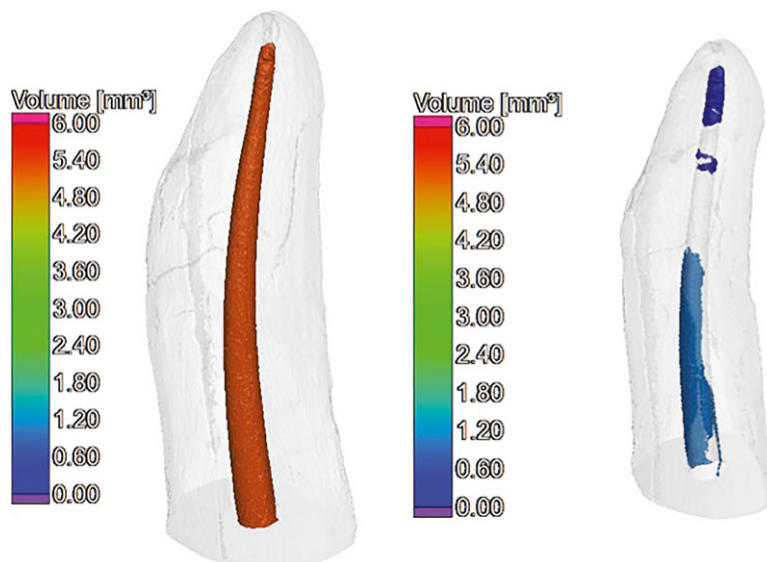
The amount of filling material in the root canals decreased significantly after all three retreatment protocols (*P* < 0.05). However, none of the protocols succeeded in complete removal of the material from any root canal. Table 1 shows the initial volume of the filling material (in mm³) and the remaining volume after the retreatment protocols. Table 2 shows the rate of decrease (%) in the filling material after the Reciproc Blue, Reciproc and PTU retreatment protocols. The Reciproc system removed the filling material more effectively than the Reciproc Blue (*P* = 0.005) and PTU (*P* < 0.001) systems, with the latter two

Table 1 Volume of the filling material (mm³) after the filling and the retreatment procedures: Reciproc Blue, Reciproc and ProTaper Universal retreatment protocols

Group	Minimum	Maximum	Mean
Baseline volume			
Reciproc blue	5.000	8.150	6.605
Reciproc	4.710	7.150	5.561
ProTaper universal	5.380	8.760	7.220
Retreatment protocols			
Reciproc Blue	0.200	2.350	0.711
Reciproc	0.010	0.300	0.169
ProTaper Universal	1.210	2.300	1.459

Table 2 Rate of decrease (%) in the filling material volume after retreatment with the Reciproc Blue, Reciproc and ProTaper Universal retreatment protocols

Groups	N	Mean (%)	Minimum (%)	Maximum (%)	Percentiles (%)		
					25th	50th (Median)	75th
Reciproc Blue	15	84.74	61.29	97.50	74.08	93.13	95.57
Reciproc	15	96.82	93.56	99.78	95.14	97.24	98.20
ProTaper Universal	15	76.17	69.74	86.19	70.27	74.16	83.00

**Figure 1** Three-dimensional model of a tooth (coloured according to the volume of material under investigation) after filling and retreatment procedure with Reciproc Blue.**Figure 2** Three-dimensional model of a tooth (coloured according to the volume of material under investigation) after filling and retreatment procedure with Reciproc.

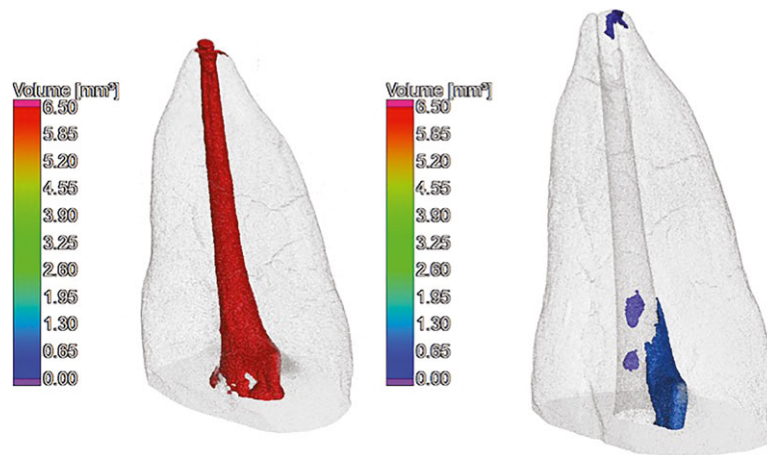


Figure 3 Three-dimensional model of a tooth (coloured according to the volume of material under investigation) after filling and retreatment procedure with ProTaper Universal.

systems showing no significant differences ($P = 0.068$) (Figs. 1, 2 and 3).

Discussion

In the present study, the ability of the Reciproc Blue, Reciproc and PTU Retreatment systems to remove root filling material from the oval and straight root canals of mandibular premolars was analysed. The Reciproc system was the most effective in the removal of gutta-percha and epoxy resin-based sealer, although none of the systems completely removed the filling material. Thus, the null hypothesis of the present study was rejected.

The removal of filling materials during retreatment procedures enables instruments and irrigants to reach all areas of the root canal system, which results in more effective intracanal cleaning and disinfection. According to a recent review (Rossi-Fedele & Aly Ahmed 2017), no existing retreatment protocol can completely remove root filling materials, with the mean percentage of residual material ranging from 45.4% (Yilmaz *et al.* 2018) to 0.02% (Hammad *et al.* 2008). Even in the present study, complete removal of epoxy resin-based sealer and gutta-percha using the reciprocating and rotary systems with the final irrigation protocol was not achieved. Reciproc instrumentation resulted in the least amount of remnant filling material after retreatment (0.69 mm^3). Moreover, the Reciproc (size 40, .06 taper) system was the most successful retreatment system, with a mean filling material decrease rate of 96.72%. Several

previous studies have reported the superiority of the Reciproc system over rotary systems for removing existing filling material (Zuolo *et al.* 2013, Bernardes *et al.* 2016). The ability of the Reciproc system is probably associated with its design, which is characterized by an S-shaped cross section with two sharp cutting edges, more positive cutting angle, larger chip space and greater removal capability (Bürklein *et al.* 2012, Plotino *et al.* 2014a,b). According to Plotino *et al.* (2014a) and Bürklein *et al.* (2012), cross-sectional design had a great influence on the cutting efficiency of an instrument. Therefore, it can be assumed that S-shaped cross section of the Reciproc instrument is responsible for its greater efficiency compared with the triangular cross section of the ProTaper Universal System (Bürklein *et al.* 2012). In the present study, only the R40 file was used for retreatment, because the initial canal diameter was standardized to the diameter of the size 25 K-file. In addition, according to Monquilhott Crozeta *et al.* (2016a), the Reciproc system has the same retreatment ability when a single file or a combination of files is used.

In contrast to the findings of the present study, no significant differences were found between the Reciproc and PTU systems in several recent studies involving curved or straight round canals (Rios *et al.* 2014, Rödig *et al.* 2014, Monquilhott Crozeta *et al.* 2016a). In addition, Rossi-Fedele & Aly Ahmed (2017) recently conducted a systematic review and concluded that reciprocating and rotary systems exhibit similar removal of canal filling material. The conflicting findings of comparisons between reciprocating

and rotary systems in previous studies are probably associated with the anatomy of the root canal system (straight, curved, oval), type and quality of the initial root filling material, and use of a solvent. In the present study, oval, straight canals of mandibular first premolars that were filled using the cold lateral condensation technique were used. Moreover, as in previous studies (Zuolo *et al.* 2013, Bernardes *et al.* 2016, Monquilhott Crozeta *et al.* 2016a), no solvent was used in order to yield more comparable results and because it has been found that dissolved gutta-percha may be pushed into irregularities and dentinal tubules, which compromises the quality of cleaning and retreatment (Ma *et al.* 2012). The results are in accordance with those presented by Bernardes *et al.* (2016), who used a similar study protocol and reported that the amount of remnant filling material (AH Plus sealer and gutta-percha, cold lateral compaction with thermomechanical compaction) was significantly reduced after retreatment with the Reciproc R40 file compared with PTU retreatment files (D1 to F40). Because the root canals in the present study were initially prepared with the PTN system up to the final X2 file (size 25, .06 taper), the root canals in the PTU group (D1 to D3) were additionally instrumented with the PTN X3 and X4 files after retreatment. However, when comparing these two techniques, the anatomy of root canal as well as the filling technique has to be taken into consideration. So in a recent study by Nevares *et al.* (2016), Reciproc (R25) and the rotary ProTaper Next (X2 and X3 instrument) technique were equally effective in the removal of gutta-percha and AH Plus sealer (using thermoplastified technique with AH Plus sealer) from severely curved root canals. In a more recent study (Martins *et al.* 2017), the ProTaper Next (X2, X3 and X4) and Reciproc system (R40) were equally effective in the removal of filling material (gutta-percha and zinc oxide and eugenol-based sealer, single cone filling technique). Also, the reason for the different results with those of the present study could be related to the size of the retreatment instruments. In a study of Martins *et al.* (2017), the retreatment instruments (R40 and X4) were the same as the initial root canal instrumentation (PTU F4), and in the present study, the retreatment was achieved with instruments one size larger (R40, X4) than the initial size of the root canals (X3) so more material and dentine covered by the material could be removed.

In the present study, the mean filling material decrease rate was 84.74% when the Reciproc Blue

R40 file was used for retreatment; this was significantly lower than the rate achieved with the Reciproc R40 file. Because the designs of the Reciproc Blue and Reciproc files are the same (S-shaped cross section, two cutting edges and a noncutting tip), the reduced retreatment ability of the Reciproc Blue system can be attributed to the manufacturing process, which decreases the shape memory of the blue alloy. In addition, the low surface microhardness and the consequent softness of the instruments (De-Deus *et al.* 2017, Topçuoğlu & Topçuoğlu 2017), which provide them with greater flexibility during the preparation of curved root canals and lower the risk of intracanal breakage and transportation (Plotino *et al.* 2014b), could be factors for the reduced removal of canal filling material. However, more *ex vivo* studies including different canal anatomies and filling materials are necessary to clarify the endodontic retreatment ability of the Reciproc Blue system.

AH Plus is a hydrophobic epoxy resin-based sealer and is a gold standard filling material (Zhou *et al.* 2013). Epoxy resin sealers have the ability to penetrate into open dentinal tubules especially in the cervical part of root canal (Simsek *et al.* 2014). According to Donnermeyer *et al.* (2018), retreatment time and the percentage of root filling remnants may be affected by the sealer and instrument used. It was clearly shown that AH Plus sealer, after retreatment, was associated with significantly more remnants compared to calcium silicate-containing sealers. Although gutta-percha does not form a monoblock when used with AH Plus sealer (Tyagi *et al.* 2013), the resin tags that may be observed inside the dentinal tubules, when epoxy resin sealer was used, may influence the amount of root filling remnants. This also can be caused by covalent bond between epoxide and exposed amino groups in collagen (Vilanova *et al.* 2012). Furthermore, according to Lee *et al.* (2017), AH Plus maintained almost constant mass (change rate within -0.5% by water sorption after polymerization) in a wet environment for 30 days; thus, dimensional stability and positive rate of polymerization can make it difficult to remove material from the walls and may also influence on the amount of material remnants.

Conclusion

Reciproc was more effective than the Reciproc Blue and PTU files in the removal of gutta-percha and epoxy resin-based sealer during the retreatment of oval root canals in extracted premolar teeth.

Acknowledgements

This manuscript presents the results achieved in the framework of the project IKARUS (European Regional Development Fund, MIS: RC.2.2.08-0042, Faculty of Mechanical Engineering and Naval Architecture, University of Zagreb).

Conflict of interest

The authors have stated explicitly that there are no conflicts of interest in connection with this article.

References

- Bernardes RA, Duarte MA, Vivian RR *et al.* (2016) Comparison of three retreatment techniques with ultrasonic activation in flattened canals using micro-computed tomography and scanning electron microscopy. *International Endodontic Journal* **49**, 890–7.
- Bürklein S, Hinschitzka K, Dammaschke T, Schäfer E (2012) Shaping ability and cleaning effectiveness of two single-file systems in severely curved root canals of extracted teeth: Reciproc and WaveOne versus Mtwo and ProTaper. *International Endodontic Journal* **45**, 449–61.
- Cobankara FK, Orocoglu H, Sengun A, Belli S (2006) The quantitative evaluation of apical sealing of four endodontic sealers. *Journal of Endodontics* **32**, 66–8.
- De-Deus G, Barino B, Zamlyi RQ *et al.* (2010) Suboptimal debridement quality produced by the single-file F2 ProTaper technique in oval-shaped canals. *Journal of Endodontics* **36**, 1897–900.
- De-Deus G, Silva EJ, Vieira VT *et al.* (2017) Blue thermomechanical treatment optimizes fatigue resistance and flexibility of the Reciproc files. *Journal of Endodontics* **43**, 462–6.
- Donnermeyer D, Bunne C, Schäfer E, Dammaschke T (2018) Retreatability of three calcium silicate-containing sealers and one epoxy resin-based root canal sealer with four different root canal instruments. *Clinical Oral Investigation* **22**, 811–7.
- Ersahan S, Aydin C (2010) Dislocation resistance of iRoot SP, a calcium silicate-based sealer, from radicular dentine. *Journal of Endodontics* **36**, 2000–2.
- Ersev H, Yilmaz M, Dağlaroğlu R (2012) The efficacy of ProTaper Universal rotary retreatment instrumentation to remove single gutta-percha cones cemented with several endodontic sealers. *International Endodontic Journal* **45**, 756–62.
- Farzaneh M, Abitbol S, Friedman S (2004) Treatment outcome in endodontics: the Toronto study. Phases I and II: orthograde retreatment. *Journal of Endodontics* **30**, 627–33.
- Fruchi LDC, Ordinola-Zapata R, Cavenago BC *et al.* (2014) Efficacy of reciprocating instruments for the removing filling material in curved canals obturated with a single-cone technique. A micro-computed tomography analysis. *Journal of Endodontics* **40**, 1000–4.
- Haapasalo M, Shen Y, Ricucci D (2008) Reasons for persistent and emerging post treatment endodontic disease. *Endodontics Topics* **18**, 31–50.
- Hammad M, Qualtrough A, Silikas N (2008) Three-dimensional evaluation of effectiveness of hand and rotary instrumentation for retreatment of canals filled with different materials. *Journal of Endodontics* **34**, 1370–3.
- Imura N, Pinheiro ET, Gomes BP, Zaia AA, Ferraz CC, Souza-Filho FJ (2007) The outcome of endodontic treatment: a retrospective study of 2000 cases performed by a specialist. *Journal of Endodontics* **33**, 1278–82.
- Kim H, Kim E, Lee S-J, Shin S-J (2015) Comparisons of the retreatment efficacy of calcium silicate and epoxy resin-based sealers and residual sealer in dentinal tubules. *Journal of Endodontics* **41**, 2025–30.
- Lee JK, Kwak SW, Ha JH, Lee WC, Kim HC (2017) Physico-chemical properties of epoxy resin-based and Bioceramic-based root canal sealers. *Bioinorganic Chemistry and Applications*. **2017**, 2582849.
- Ma J, Al-Adhaw AJ, Shen Y *et al.* (2012) Efficacy of ProTaper Universal rotary retreatment system for gutta-percha removal from oval root canals: a micro-computed tomography study. *Journal of Endodontics* **38**, 1516–20.
- Martins MP, Duarte MA, Cavenago BC, Kato AS, de Solveira Bueno CE (2017) Effectiveness of the ProTaper Next and Reciproc systems in removing root canal filling material with sonic or ultrasonic irrigation: a micro-computed tomographic study. *Journal of Endodontics* **43**, 467–71.
- Monquilhott Crozeta B, de Sousa-Neto MD, Leoni GB *et al.* (2016a) A micro-computed tomography assessment of the efficacy of rotary and reciprocating techniques for filling material removal in root canal retreatment. *Clinical Oral Investigation* **20**, 2235–40.
- Monquilhott Crozeta M, Silva-Soussa YT, Leoni GB (2016b) Micro-computed tomography study of filling material removal from oval-shaped canals by using rotary, reciprocating and adaptive motion systems. *Journal of Endodontics* **42**, 793–7.
- Nevaes G, de Albuquerque DS, Freire LG *et al.* (2016) Efficacy of ProTaper NEXT compared with Reciproc in removing obturation material from severely curved root canals: a micro-computed tomography study. *Journal of Endodontics* **42**, 803–8.
- Ng YL, Mann V, Gulabivala K (2008) Outcome of secondary root canal treatment: a systematic review of the literature. *International Endodontic Journal* **41**, 1026–46.
- Plotino G, Giansiracusa Rubini A, Grande NM, Testarelli L, Gambarini G (2014a) Cutting efficiency of Reciproc and WaveOne reciprocating instruments. *Journal of Endodontics* **40**, 1228–30.
- Plotino G, Grande NM, Cotti E *et al.* (2014b) Blue treatment enhances cyclic fatigue resistance of vortex nickel-titanium rotary files. *Journal of Endodontics* **40**, 1451–3.

- Rached-Junior FJ, Sousa-Neto MD, Souza-Gabriel AE, Duarte MA, Silva-Sousa YT (2014) Impact of remaining zinc oxide-eugenol-based sealer on the bond strength of a resinous sealer to dentine after root canal retreatment. *International Endodontic Journal* **47**, 463–9.
- Rios M de A, Villela AM, Cunha RS et al. (2014) Efficacy of 2 reciprocating systems compared with a rotary retreatment system for gutta-percha removal. *Journal of Endodontics* **40**, 543–6.
- Rödig T, Reicherts P, Konietzschke F, Dullin C, Hahn W, Hülsmann M (2014) Efficacy of reciprocating and rotary NiTi instruments for retreatment of curved root canals assessed by micro-CT. *International Endodontic Journal* **47**, 942–8.
- Rödig T, Wagner J, Wiegand A, Rizk M (2018) Efficacy of the ProTaper Retreatment system in removing Thermafil, GuttaCore or vertically compacted gutta-percha from curved root canals assessed by micro-CT. *International Endodontic Journal* **51**, 808–15.
- Rodrigues CT, Hungaro MA, de Almeida MM, de Andrade FB, Bernardineli N (2016) Efficacy of CM-Wire, M-Wire, and nickel-titanium instruments for removing filling materials from curved root canals: a micro-computed tomographic study. *Journal of Endodontics* **42**, 1651–5.
- Rossi-Fedele G, Aly Ahmed HM (2017) Assessment of root canal filling removal effectiveness using micro-computed tomography: a systematic review. *Journal of Endodontics* **43**, 20–6.
- Simsek N, Keles A, Ahmetoglu F, Ocak MS, Yologlu S (2014) Comparison of different retreatment techniques and root canal sealers: a scanning electron microscopic study. *Brazilian Oral Research* **28**, 1–7.
- Siqueira JF Jr (2011) Treatment failures: retreatment and periradicular surgery. In: Siqueira Jr JF, ed. *Treatment of Endodontic Infections*, 1st edn. Berlin, Germany: Quintessence Publishing Co. Ltd, pp. 343–60.
- Siqueira Jr JF, Rôças IN, Ricucci D, Hülsmann M (2014) Causes and management of post-treatment apical periodontitis. *Brazilian Dental Journal* **216**, 305–12.
- Suk M, Bago I, Katić M, Šnjarić D, Munitić ŠM, Anić I (2017) The efficacy of photon-initiated photoacoustic streaming in the removal of calcium silicate-based filling remnants from the root canal after rotary retreatment. *Lasers in Medical Science* **32**, 2055–62.
- Topçuoğlu HS, Topçuoğlu G (2017) Cyclic fatigue resistance of Reciproc Blue and Reciproc files in an S-shaped canal. *Journal of Endodontics* **43**, 1679–82.
- Tyagi S, Mishra P, Tyagi P (2013) Evolution of root canal sealers: an insight story. *European Journal of General Dentistry* **2**, 199–218.
- Versiani MA, Carvalho-Junior JR, Padilha MI, Lacey S, Pascon E, Sousa-Neto MD (2006) A comparative study of physicochemical properties of AH Plus and Epiphany root canal sealants. *International Endodontic Journal* **39**, 464–71.
- Vilanova WV, Carvalho-Junior JR, Alfredo E, Sousa-Neto MD, Silva-Sousa YT (2012) Effect of intracanal irrigants on bond strength of epoxy resin-based and methacrylate resin-based sealers to root canal walls. *International Endodontic Journal* **45**, 42–8.
- Yilmaz F, Koç C, Kamburoğlu K et al. (2018) Evaluation of 3 different retreatment techniques in maxillary molar teeth by using micro-computed tomography. *Journal of Endodontics* **44**, 480–4.
- Zhang W, Li Z, Peng B (2009) Assessment of a new root canal sealer's apical sealing ability. *Oral Surgery Oral Medicine Oral Pathology Oral Radiology and Endodontics* **107**, 79–82.
- Zhou HM, Shen Y, Zheng W, Li L, Zheng YF, Haapasalo M (2013) Physical properties of 5 root canal sealers. *Journal of Endodontics* **39**, 1281–6.
- Zuolo AS, Mello Jr JE, Cunha RS, Zuolo ML, Bueno CE (2013) Efficacy of reciprocating and rotary techniques for removing filling material during root canal retreatment. *International Endodontic Journal* **46**, 947–53.