

How to Intervene in the Caries Process: Early Childhood Caries - A Systematic Review

Schmoeckel, Julian; Gorseta, Kristina; Splieth, Christian H.; Juric, Hrvoje

Source / Izvornik: **Caries Research**, 2020, 54, 102 - 112

Journal article, Published version

Rad u časopisu, Objavljena verzija rada (izdavačev PDF)

<https://doi.org/10.1159/000504335>

Permanent link / Trajna poveznica: <https://um.nsk.hr/um:nbn:hr:127:668532>

Rights / Prava: [In copyright](#) / [Zaštićeno autorskim pravom.](#)

Download date / Datum preuzimanja: **2025-02-27**



Repository / Repozitorij:

[University of Zagreb School of Dental Medicine
Repository](#)



How to Intervene in the Caries Process: Early Childhood Caries – A Systematic Review

Julian Schmoeckel^a Kristina Gorseta^b Christian H. Splieth^a Hrvoje Juric^b

^aDepartment of Preventive and Paediatric Dentistry, University of Greifswald, Greifswald, Germany; ^bDepartment of Paediatric and Preventive Dentistry, School of Dental Medicine, University of Zagreb, Zagreb, Croatia

Keywords

Early childhood caries · Nonoperative · Restoration · Treatment · Children · Review

Abstract

For an Organisation for Caries Research/European Federation of Conservative Dentistry consensus, this systematic review is aimed to assess the question of how to manage the caries process in the case of early childhood caries (ECC). Medline via PubMed was searched systematically regarding management of ECC. First priority was existing systematic reviews or randomized clinical trials otherwise cohort studies dealing with management of ECC, primarily with carious anterior teeth. After data extraction, the potential risk of bias was estimated depending on the study types, and the level of evidence was evaluated. Regarding management of ECC, results are presented for silver diamine fluoride (SDF, $n = 5$), nonoperative caries management (NOCM, $n = 10$), and restorative approaches (RA, $n = 8$) separately, as different kinds of studies with different levels of evidence were found for the different aspects in the management of ECC. The 5 systematic reviews on SDF showed a high potential for arrest of ECC on a high level of evidence. In NOCM, a low level of evi-

dence for a moderate effect of fluoride varnish in arresting or remineralizing, especially non-cavitated lesions, was assessed. For RA in carious anterior upper primary teeth, a low level of evidence was found for higher failure rates of glass ionomer cement and composite fillings than composite strip crowns even if placed under general anaesthesia and especially compared to other crowns (stainless steel and zirconia). In conclusions, ECC may be managed successfully with nonoperative (SDF, regular fluoride application) and moderately well with operative approaches, but the decision is affected by many other variables such as pulpal involvement, the child's cooperation, or a general anaesthesia setting.

© 2020 S. Karger AG, Basel

Introduction

Early childhood caries (ECC) is a specific form of caries that occurs in children on primary teeth. ECC is worldwide and a highly prevalent disease [Chen et al., 2019] and should be considered a relevant burden for the children and their families [Thomson, 2016]. ECC is characterized as “the early onset of caries in young children with often fast progression which can finally result in complete destruction of the

primary dentition” [Machiulskiene et al., 2019]. The aetiology of ECC is quite clear: high sugar intake usually via a nursing bottle and insufficient or no oral hygiene, as parents do not brush or not well enough, leading to an atypical pattern of caries attack, particularly on smooth surfaces of upper anterior teeth in young children [Drury et al., 1999; Tinanoff et al., 2019; Wyne, 1999; Machiulskiene et al., 2019]. In contrast to the ECC classification regarding typical clinical patterns [Wyne, 1999], the epidemiological ECC classification of ECC records any carious lesions in primary teeth in children younger than 6 years [AAPD classification]. Many studies indicate that severe ECC can negatively influence the quality of life in preschool children, but fortunately be improved when treated [Collado et al., 2017]. Moreso, due to young age and often low cooperation, general anaesthesia (GA) or sedation is frequently necessary for invasive dental interventions (e.g., fillings, pulp therapy, extraction), going along with higher risks for the children and efforts for families, and also considerable costs for the health systems [Casamassimo et al., 2009; Thomson, 2016]. This leads to a more complex dental decision making in how to manage ECC as not only the diagnosis of the caries lesion at the tooth level but also the caries management on the patient level needs to be considered. Furthermore, dentists face a lot of challenges when planning operative interventions of (severe) ECC:

- The morphology of primary teeth in comparison with permanent teeth is different; as they exhibit large pulp chamber and a thinner enamel–dentin layer, which shorten the time for the caries process to reach the pulp and may cause pain and pulp complications.
- Pain and fear caused by ECC in emergency dental care can compromise future oral health-related quality of life of the child.
- Young children are immature, and usually pre-cooperative (sedation or GA might be needed), and a more complex decision-making process as parents are responsible to take care for their child.
- Premature loss of anterior primary teeth may cause problems with eating/biting, difficulties in speech development, and retarded eruption of permanent incisors.

Another paper in this review consortium for a consensus paper of the European Organisation for Caries Research and the European Federation of Conservative Dentistry deals especially with the management of carious primary molars and different methods of removal of carious tissue and the subsequent restorations. Therefore, this topic is not included in this systematic review. This review focuses on the management of ECC, especially carious primary (upper) anterior teeth.

The aim of this review was to systematically evaluate the current state of knowledge on how to intervene in the caries process in carious primary (upper anterior) teeth in ECC.

Material and Methods

This systematic review aims to answer the following Participants, Interventions, Comparisons, and Outcomes questions:

How to intervene in the caries process in ECC (especially upper anterior teeth)?:

1. What is the effect of non-invasive management options on ECC?
2. What are the success rates of restorative management options of ECC?

The authors discussed the review protocol a priori. No further external registration was performed as the topic was given to the authors by the joined chairs of the Organisation for Caries Research/European Federation of Conservative Dentistry Consensus Workshop on how to intervene in the caries process.

Search Strategy

For the comprehensive search strategy, Medline was searched via PubMed for appropriate papers up to and including March 2019. The used search terms and the full search strategy are shown in Figure 1. Titles and abstracts were screened to exclude papers not related to the topic. The remaining full-text articles were screened for eligibility and references hand-searched for additional sources. Publications on humans in English language were included.

The inclusion criteria were (Participants, Interventions, Comparisons, and Outcomes):

- Patients: preschool children, ECC, carious incisors, non-cavitated and cavitated (anterior) primary teeth
 - Intervention:
 - Nonoperative management of carious lesions in primary (anterior) teeth with silver diamine fluoride (SDF) or any other nonoperative strategies or measures of secondary prevention;
 - Restorative management of carious lesions in anterior teeth.
 - Control:
 - Any other nonoperative strategy (or if available restorative approach [RA]);
 - Any other restorative material.
 - Outcome:
 - Caries or lesion progression (major failure, when necessity for pulpal therapy);
 - Survival of restoration (major failure, when pain/necessity for pulpal therapy).
 - Meta-analyses, systematic reviews, and in case of no studies for these high evidence levels also randomized controlled trials (RCTs) and/or cohort studies (prospective and retrospective).
- The exclusion criteria were:
- Permanent teeth, schoolchildren, adults;
 - ECC primary prevention, (vast majority of participants with caries-free primary teeth at baseline);
 - Only caries lesions in primary molars;
 - Case presentations, case series;
 - No clinical outcomes reported.

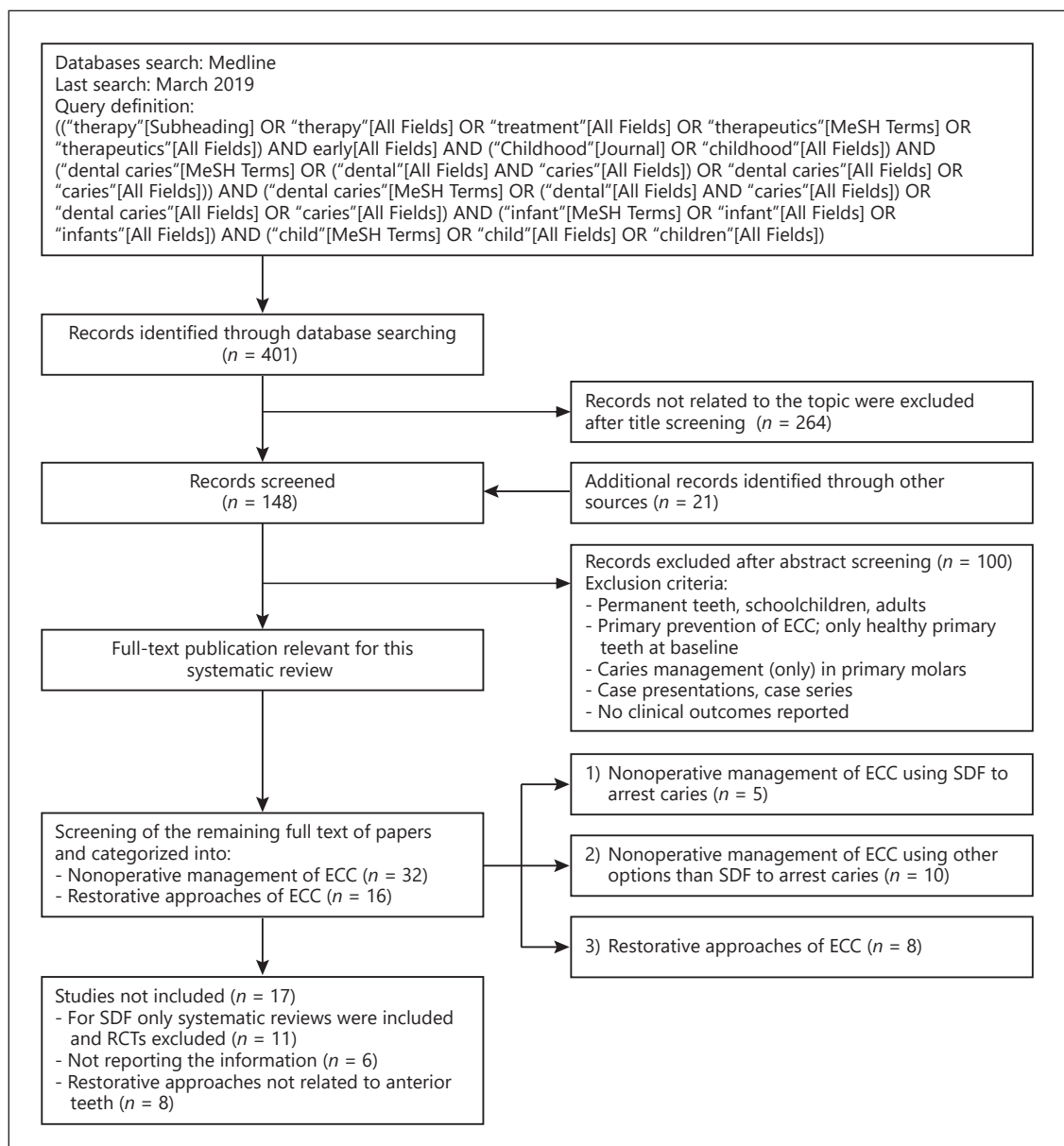


Fig. 1. Flowchart of the systematic review on the management of ECC. ECC, early childhood caries; SDF, silver diamine fluoride; RCT, randomized controlled trial.

Screening, Selection, and Data Extraction

The title and abstract lists, containing 401 hits, were independently assessed by 2 authors (K.G. and J.S.), respectively. Each of them screened the titles, abstracts, full-texts of eligible papers regarding management of ECC categorized into subchapter (1) nonoperative management (SDF and other nonoperative caries management [NOCM]) and (2) RAs. Papers with questionable inclusion were discussed in telephone conferences among the authors (K.G., J.S., C.H.S., and H.J.).

Eligible papers were read in full-text by the authors, especially for methodology, bias, and outcome. Disagreement between the authors was resolved by discussion in additional telephone confer-

ences. The papers that fulfilled all of the selection criteria were processed for data abstraction (Fig. 1).

Information extracted from the studies included publication details, setting, participants, focused question, search results, comparators, main outcomes, and conclusions (Tables 1–3).

Quality Assessment and Assessment of Heterogeneity

Depending on the type of studies, the reviewers (K.G. and J.S.) assessed and classified the risk of bias, mostly according to the PRISMA statement for reporting systematic reviews and meta-analyses of studies that evaluate health-care intervention [Liberati et al., 2009] by scoring the reporting and methodolog-

Table 1. Systematic reviews on nonoperative management of ECC with silver fluoride products

Author/year	Study design and sample	Analysis	Main results
Duangthip et al. [2015]	SR 4 studies (3 RCTs and 1 cohort), 3–6 years-old arresting or slowing down the progression of active dentinal caries in primary teeth 3 studies: SDF at different application frequencies vs. other interventions 1 study: SDF versus other interventions	Caries arrested rate (number needed to treat)	Three studies reported that topical applications of SDF solution could arrest dentinal caries in preschool children; one study supported that having a daily toothbrushing exercise in kindergarten using toothpaste with 1,000 ppm fluoride could stabilize the caries situation in young children
Gao et al. [2016]	SR and MA 16 trials on primary teeth (SR), <6 years old MA (8 RCTs) on 38% SDF to arrest caries in primary teeth 1 study: semiannual SDF applications versus control 1 compared SDF to placebo and sodium FV; 1 study: SDF at different concentrations; 1 study: SDF vs. other interventions; 4 studies: SDF at different application frequencies	Caries arrest	The overall percentage of active carious lesions that became arrested was 81%; 38% SDF was effective in arresting dentine carious lesions in primary teeth
Contreras et al. [2017]	SR 8 RCTs, 3–9 years old preventing and arresting caries in the primary dentition and permanent first molars 1 study: SDF at different concentrations; 3 studies: SDF versus other interventions; 2 studies: SDF at different application frequencies and with other interventions; 1 study: semiannual SDF applications versus a control	Number of arrested surfaces	At concentrations of 30 and 38%, SDF shows potential as an alternative treatment for caries arrest in the primary dentition
Chibinski et al. [2017]	SR and MA 11 RCTs, 4–9 years old arresting caries in the primary dentition and permanent first molars 1 study: NSF to placebo 1 study: SDF to placebo 1 study: SDF to no treatment 3 studies compared SDF to ART 2 studies compared SDF to placebo and sodium FV 2 studies compared SDF and sodium FV 1 study compared SDF at different concentrations versus no treatment	Caries arrest	The use of SDF is 89% more effective in arresting caries than other management options or placebos; The quality of the evidence was graded as high
Oliveira et al. [2019]	SR and MA 6 reports of 4 RCTs preventing and arresting caries in the primary dentition 2–12 years old, overall 915 participants analysed 2 trials compared SDF to no treatment; 1 compared SDF to placebo and sodium FV; 1 compared SDF to high-viscosity GIC	Arrest and development of new dentinal carious lesions	After 2-year follow-up, in comparison to placebo, no treatment, and FV, SDF applications significantly reduced the development of new dentinal carious lesions (placebo or no treatment: WMD -1.15, PF = 77.5%; FV WMD = -0.43, PF = 54.0%); GIC was more effective than SDF after 12 months of follow-up but the difference between them was not statistically significant (WMD, dmft: 0.34, PF: -6.09%)

SR, systematic review; MA, meta-analysis; RCT, randomized controlled trial; SDF, silver-diamine-fluoride; FV, fluoride varnish; GIC, glass ionomer cement; WMD, weighted mean difference; ART, atraumatic restorative treatment; NSF, nano-silver fluoride; ECC, early childhood caries.

ical quality of the included systematic reviews on NOCM with SDF (online suppl. Table 1; for all online suppl. material, see www.karger.com/doi/10.1159/000504335). A list of 27 items was assessed, and if all individual items were given a positive rating by summing these items an overall score of 100% was ob-

tained. Only systematic reviews including meta-analysis could achieve a full score of 100%. The estimated risk of bias was interpreted as follows: 0–40%: high risk of bias; 40–60%: substantial risk of bias; 60–80%: moderate risk of bias; 80–100%: low risk of bias.

Table 2. Overview on the selected studies (part of a meta-analysis, RCTs, cohort studies, partially as cohorts from SDF-RCTs) for NOCM of ECC reporting results on other options than silver fluoride products

Author/year	Country	Study design and sample	Analysis	Main results/outcome for NOCT
FV Gao et al. [2016] part of MA		SR and MA 17 RCTs included in total 10 studies investigated the remineralizing effect on ECC using silicon tetrafluoride, fluoride gel, SDF, or NaF	Meta-analysis	Meta-analysis was performed on 4 papers using 5% sodium FV to remineralize early enamel caries, and the overall percentage of remineralized enamel caries was 63.6% (95% CI 36.0–91.2%; $p < 0.001$)
Autio-Gold and Courts [2001] RCT	USA	9 months RCT $n = 142$ children (3–5 years old) – active enamel lesions at baseline (1) FV (Duraphat) baseline and after 4 months (2) CG (without treatment)	Active or inactive enamel lesions, enamel caries progression in the primary dentition	In the varnish group, 81.2% of active enamel lesions became inactive, 2.4% progressed, and 8.2% were still active enamel lesions
Divaris et al. [2013] RCT	Australia aborigines	2 years RCT $n = 543$ (3–4 years old) Anterior and posterior teeth sound and precavitated surfaces F varnish 2×/year training of primary care coworkers+ community health promotion + F varnish 2×/year Control group – without treatment (initial examination and after 2 years)	Surface level diagnoses net 2-year surface-level cavitation risk estimates (cumulative incidence and 95% CL) for sound, opaque, hypoplastic and precavitated surfaces at baseline	The intervention resulted in a 25% reduction (RR 0.75; 95% CL = 0.71, 0.80) in the 2-year surface-level caries risk; there was substantial heterogeneity in FV efficacy by baseline surface pathology: RRs were 0.73 for sound, 0.77 for opaque, 0.90 for precavitated, and 0.92 for hypoplastic surfaces; Among sound surfaces, maxillary anterior facials received significantly more benefit (RR 0.62) compared to pits and fissures (RR 0.78)
Itaborahy et al. [2015] RCT	Brazil	5 weeks pilot RCT $n = 7$ (24 active WSL) 2–5 years-old (1) Duraphat 1×/week for 4 weeks (2) Duofluorid XII 1×/week for 4 weeks	Maximum mesiodistal and incisogingival dimensions of WSL measured with a periodontal probe; The average between the 2 dimensions represented the value of the WSL dimension	After 5 weeks, most WSL were ranked as inactive (G1 = 71.4% and G2 = 40%); no significant difference between G1 and G2 in relation to lesion activity was observed ($p = 0.124$); there was a significant decrease of 24% between initial (3.12 ± 1.49 mm) and final WSL dimension (2.35 ± 1.06 mm; $p = 0.012$) in G1; in G2, there was a significant reduction of 40% in lesion dimension with initial value of 5.7 mm (± 3.82 mm) and final value of 3.4 mm (± 3.35 mm; $p = 0.013$)
Memarpour et al. [2015] RCT	Iran	1-year RCT $n = 140$ (12–36 months) anterior maxillary teeth with WSL (1) control (2) OH and dietary instr. (3) OH+FV 4, 8, 12 months after baseline (4) OH + tooth mousse 2×/year	Mean percent WSL area dmft index values	OH along with 4 FV applications during the 12-month period reduced the size of WSL in anterior primary teeth; Significant decreases in the size of the WSL; the greatest reduction was in group 4 (63%) followed by group 3 (51%) and group 2 (10%) after 12 months. There were no significant differences between the groups
Duangthip et al. [2018] Control cohort in RCT on SDF	Hong Kong	RCT, 30 months $n = 371$ (3–4 years) Gr. (3) 5%NaF 3×/week at baseline	ICDAS scores and caries arrest	For cavitated lesions (ICDAS code 5 or 6), the caries arrest rate of Group 3 was (34%); For moderate caries lesions without visible dentine (ICDAS code 3 or 4), the caries arrest rates for NaF group was 51%

Table 2 (continued)

Author/year	Country	Study design and sample	Analysis	Main results/outcome for NOCT
Chu et al. [2002] Control cohorts in RCT on SDF	China, RCT	RCT, 30 months, <i>n</i> = 375 children (3–5 years), upper anterior primary teeth (3) Excavation +5%NaF 4×/year (4) 5%NaF 4×/year (5) Control	Number of arrested caries lesions	The mean numbers of arrested caries tooth surfaces in NaF group and control were 1.5, 1.5, and 1.3, respectively; no statistically significant differences in the mean number of arrested carious tooth surfaces after 30 months were found between children who had their caries excavated prior to NaF varnish application and those who had not
Other options for NOCM				
Sitthitsetpong et al. [2012] RCT	Thailand	1 year double-blind, placebo-controlled clinical trial <i>n</i> = 150 (2.5–3.5 years old) (1) regular toothbrushing with a fluoride toothpaste (1,000 ppm) (CG) (2) add daily application of 10% w/v CPP-ACP for 1 year (67.6% of children had ECC [dmfs of upper anterior teeth ≥1], mean baseline dmft 4.3)	Transition scores of enamel caries according to ICDAS (regression, stable, or progression)	The odds of enamel caries lesion transitions to a state of regression or stability, compared with progression from baseline, was also not different between groups (OR 1.00, 95% CI (0.86–1.17)). This trial found that daily application of 10% w/v CPP-ACP paste on school days for 1 year, when added to regular toothbrushing with a fluoride toothpaste (1,000 ppm), had no significant added effect in preventing caries in the primary dentition of these pre-school children
Memarpour et al. [2015] RCT	Iran	1 year RCT <i>n</i> = 140 (12–36 months) anterior maxillary teeth with WSL (1) control (2) OH and dietary instr. (3) OH + FV 4, 8, 12 months after baseline (4) OH + tooth mousse 2×/year	Mean percent WSL area dmft index values	OH along with constant CPP-ACP during the 12-month period reduced the size of WSL in anterior primary teeth; significant decreases in the size of the WSL; the greatest reduction was in group 4 (63%) followed by group 3 (51%) and group 2 (10%) after 12 months; There were no significant differences between the groups
Lo et al. [1998] CS	Southern China	3 years longitudinal study <i>n</i> = 289 children (3–6 years) (1) regular oral health education and daily brushing with 1,000 ppm fluoridated toothpaste (2) control (no intervention)	Clinical examination criteria: arrested caries: dark brown to black in colour with hard surface	Statistically significant difference between the mean no. of arrested caries in Gp 1 and 2 which was 1.8 and 1.1 respectively; at 3 years, 28% of the active dentin caries in Gp 1 had become arrested while 12% of the caries were arrested in the control
Peretz et al. [2006] CS	Israel	Cohort study, 12 months <i>n</i> = 30 (2–4 years) Lesions on buccal surface	Mean diameter of lesions, plaque level, brushing and eating sweets (initial, at 6 and 12 months)	The vast majority of patients the progression of ECC was arrested after a preventive regimen was implemented

SR, systematic review; MA, meta-analysis; RCT, randomized controlled trial; CS, Cohort study; FV, fluoride varnish; WSL, white spot lesion; ECC, early childhood caries; SDF, silver-diamine fluoride; CG, control group; OH, oral hygiene instructions; NOCM, nonoperative caries management; RR, relative risk.

Only few studies with higher level of evidence reporting outcomes on NOCM and operative options were found, to at least gain some impressions of the results of these various management options not only systematic reviews and RCTs were included. Due to the diversity of the study types, the quality assessment for the nonoperative and operative management of ECC was performed (C.H.S. and J.S.) according to the Newcastle-Ottawa Scale (online suppl. Tables 2, 3), which is primarily aiming at assessing the quality of nonrandomized studies [Wells et al., 2016].

The heterogeneity across studies was investigated according to the following factors as retrieved by the included literature:

- Study and subject characteristics;
- Methodological heterogeneity (variability in study design and risk of bias);
- Analysis performed (descriptive or meta-analysis).

Table 3. Studies on restorative approaches regarding management of ECC

Author/year	Country	Sample and study design	Analysis	Main results
Eshghi et al. [2013]	Iran	1 year randomized clinical study $n = 54$ (2–4 years-old), $n = 161$ teeth restorative techniques for primary anterior teeth with extensive carious lesions (1) reversed metal post technique (2) composite post (3) fibre post reconstruction with composite resin using celluloid crowns; placed under GA or local anaesthesia	Clinical success rate of posts primary maxillary anterior teeth	According to the evaluation criteria after restoration of severely damaged primary anterior teeth at the 12-month follow-up, 98% of composite posts, 84% of fibre posts, and 90% reversed metal post restorations were regarded acceptable
Sawant et al. [2017]	India	1 year randomized clinical study $n = 60$ (3–5 years old) evaluation of novel glass fibre-reinforced composite technique for primary anterior teeth with deep carious lesions group I: EverStick glass fibre-reinforced composite post group II: ParaPost Taper Lux post	Longevity and failures of posts in primary maxillary anterior teeth	After 3-month, 1/30 cases in group I and 2/30 cases in group II showed failure due to dislodgement of the posts; at 6-month recall, 3/30 cases in group I and 11/30 cases in group II showed failure due to dislodgement of the posts; the difference between the groups was statistically significant
Arrow et al. [2016]	Australia	1 year RCT, 12 months follow-up $n = 254$ (mean 3.8 years), anterior and posterior teeth (165 anterior restorations and 432 posterior restorations) (1) ART technique with high viscosity GIC (2) conventional restoration: local anaesthetic, rotary instruments, complete caries removal and restorations (GIC or resin cements)	Restoration retention	No significant differences in restorative success between groups after 12 months; more children in the control (49%) were referred for specialist care compared with ART (6%) $p < 0.001$; after 12 months, 17% of anterior restorations failed regardless of the group
Walia et al. [2014]	UAE	RCT, 6 months $n = 39$ children, 129 anterior teeth (3–5 years) (1) Resin composite strip crowns (2) Prevented SSCs (3) Prefabricated primary Zirconiawcrowns placed with behavioural management techniques and physical restraint	Restoration failure, tooth wear, gingival health scores	The retention rate was highest for zirconia crowns (100%) followed by veneered SSCs (95%); strip crowns were the least retentive (78%)
Trairatvorakul et al. [2004]	Thailand	Clinical study, 24 months $n = 36$ (2.5–5 years) Class III restorations (anterior teeth) slot design class III dovetail design class III	Marginal adaptation, anatomic form, secondary caries, marginal discoloration	The results revealed no statistical significance in the difference of clinical characteristics between the 2 designs ($p > 0.05$); After 24 months, 91% of slot and 86.4% of dovetail Class III composite restorations were rated as optimal
Amin et al. [2016]	Canada	Retrospective cohort study, 3 years $n = 818$ children (2–5 years) Restorative treatments in primary anterior teeth: RCRs – anterior buccal/lingual composite; anterior 2-surface composite; anterior multi-surface composite; anterior composite crown placed under GA	Restoration failure	The success rate of buccal and lingual anterior RCRs was 92.4%; anterior 2-surface RCRs had a 90.2% success over 3 years; almost half of failed 2-surface anterior composite restorations (47.7%) were replaced, while 22.7%, of them were extracted; multi-surface anterior RCRs and anterior resin composite crowns were successful 90.9 and 88.6%, respectively

Table 3 (continued)

Author/year	Country	Sample and study design	Analysis	Main results
Buecher et al. [2013]	Germany	Retrospective cohort study, mean observation period 30.9 months <i>n</i> = 855 teeth (1,017 composite fillings placed under GA) ECC I, ECC II, ECC III	Longevity of composite restoration according to Black classification: classes I–V	Reasons for failure: fracture (9.6%), secondary caries (44%), complete restoration loss (46.4%); retention rates of 81.5% – mean observation period 30.9 months, annual failure rate of 4.2%; the longevity of fillings for class III (<70%) and IV (<85%) showed significantly lower survival probability rates compared with class I and V after 48 months (>90%)
Ram et al. [2006]	Israel	Retrospective study, 24 months, <i>n</i> = 387 children (2–4 years) resin-bonded composite strip crowns placed in primary maxillary incisor	Nr./location of ds, colour, texture, and chipping of the restoration; X-ray evaluation: quality of restoration margins, presence of pulpal and/or periapical pathoses, habits	More than 80% of the restorations were successful at the 2 years follow-up; The retention rate is lower in teeth with decay in 3 or more surfaces

SR, systematic review; RCT, randomized controlled trial; SDF, silver diamine fluoride; FV, fluoride varnish; GIC, glassionomer cement; WMD, weighted mean difference; ART, atraumatic restorative treatment; RCR, resin composite restoration; GA, general anaesthesia; SSC, stainless steel crowns; ECC, early childhood caries.

Outcome Measures and Statistical Analysis

Due to the availability of a higher level of evidence for SDF (systematic reviews/meta-analyses) and the fact that in contrast to other NOCM options the effect of SDF was well examined for cavitated carious lesions, this subchapter of NOCM was presented individually (Table 1), whereas other NOCM options are shown together (Table 2). For SDF and other measures of NOCM, the outcome was mainly caries arrest (e.g., hardness, colour, lesion size), and for RA, the main outcome was survival of restoration, that is, restorations not needing any restorative reintervention (replacement or repair).

Results

Management of ECC

The results are presented for SDF, NOCM, and RA separately, as different kinds of studies with different levels of evidence were found for the different aspects in managing ECC on the tooth level. No RCT investigated NOCM options versus RA.

Silver Diamine Fluoride

The application of SDF for ECC has been investigated in many studies. Within the selected manuscripts, there were 5 systematic reviews (Table 1), of which, 3 [Oliveira et al., 2019; Chibinski et al., 2017; Gao et al., 2016] contained a meta-analysis. All of the reviews containing a total of 22 different RCTs which homogeneously show the high potential for caries arrest of SDF. The higher the concentration of SDF, the better the arrest rates, espe-

cially when applied several times, for example, biannually. SDF solution applied once or twice a year could arrest active caries lesions involving dentine with a success rate of 79 and 91%, respectively [Duangthip et al., 2015]. Adverse effects such as black stains were reported in studies using 38% SDF [Duangthip et al., 2015].

Nonoperative Caries Management

Other NOCM approaches than SDF mostly employed fluoride varnish. For this subchapter, 10 studies were included (Table 2): one systematic review with a part of a meta-analysis [Gao et al., 2016], 5 RCTs, 2 cohort studies, and 2 control cohorts in SDF-RCTs [Duangthip et al., 2018; Chu et al., 2002]. The included studies showed that at least 63.6% [Gao et al., 2016] up to 81.2% [Autio-Gold and Courts, 2001] of enamel carious lesions were inactivated after fluoride varnish application. For cavitated lesions, fluoride varnish was effective in 30% of cases [Duangthip et al., 2018; Lo et al., 1998]. Sodium fluoride varnish has a moderate effect in remineralizing and/or arresting early enamel carious lesions (Table 2) [Gao et al., 2016; Autio-Gold and Courts, 2001; Sitthisettapong et al., 2012; Memarpour et al., 2015], and a lower effect for cavitated carious lesions [Divaris et al., 2013; Duangthip et al., 2018]. Moreso, by brushing with fluoride toothpaste (1,000 ppm), the arrest of ECC may be achieved [Lo et al., 1998; Peretz and Gluck, 2006], but the effect is low with a low level of evidence. There is also limited evidence for efficacy of casein phosphopeptide-amorphous calci-

um phosphate: Daily application of 10% casein phosphopeptide-amorphous calcium phosphate paste added to regular toothbrushing with a fluoride toothpaste showed no additional effect in arresting enamel caries in the primary anterior teeth [Sitthisettapong et al., 2012], contrary to the findings of [Memarpour et al., 2015].

Restorative Approaches

Regarding restorative options in carious anterior upper primary teeth, 8 studies (5 RCTs, 3 cohort studies; Table 3) were included. The level of evidence was assessed as low with a high potential of bias. In many of the studies, restorations were performed under GA (Table 3). Cohort studies showed success rates of composite restorations on tooth level of 50–90% (81.5%, ~2.5 years [Buecher et al., 2013; Ram and Fuks, 2006]). Looking into more details, multisurface composite restorations had clearly lower retention rates (<70% [Buecher et al., 2013], 80% [Ram and Fuks, 2006], 90.9% [Amin et al., 2016]) in anterior teeth than single surface resin composite restorations (>90% [Buecher et al., 2013; Amin et al., 2016]). Strip crowns had higher success rates (>80%, 2 years [Ram and Fuks, 2006], 78% [Walia et al., 2014]) than class III and IV fillings (67.8% [Buecher et al., 2013]), but lower than veneered stainless steel and zirconia crowns (95%, 100%, respectively 1/2 year [Walia et al., 2014]). Lower retention rates were found for GIC fillings (17% failure, 1 year), regardless if atraumatic restorative treatment or complete removal of carious tissue under local anaesthesia was used [Arrow et al., 2016]. For the use of posts in restoring carious primary maxillary anterior teeth with composite strip crowns, 12 months success rates of 63–98% were reported [Eshghi et al., 2013; Sawant et al., 2017].

Quality Assessment, Study Outcome Results, and Assessment of Heterogeneity

The estimated risk of bias regarding systematic reviews on SDF is presented in online supplementary Table 1, showing moderate to low potential risk of bias and homogeneous results.

Due to the diverse types of studies on NOCM (Table 2) and RAs (Table 3), the Newcastle-Ottawa Scale [Wells et al., 2016] was used for quality assessment (online suppl. Table 2, 3). Overall, considerable heterogeneity was observed in the NOCM and RAs and materials under analysis, the subject characteristics and outcome measures. Furthermore, quality assessment scales and reporting of effect scores varied among the publications. The results of NOCM were biologically and clinically plausible and

mostly in line with each other, as no outlying heterogeneity could be assessed. Nonetheless, a potential for a high risk of bias is present. Regarding operative approaches in ECC, the results were plausible for clinicians and not contradictory, while a potential for a high risk of bias is present due to the study type and underlying confounding factors.

Grading the “Body of Evidence”

The level of evidence emerging from this systematic review indicates that there is high evidence to support a high effect of SDF in arresting, especially cavitated carious lesions, a low level of evidence for a moderate effect of other NOCM options of ECC, especially non-cavitated lesions, as well as a low level of evidence of moderately high and clinical relevant failure rates for restorative care.

Discussion

ECC is highly prevalent worldwide and clearly a marker for high caries risks [Chen et al., 2019]. Therefore, it was not surprising that the literature search revealed a large number of studies, but the majority was excluded for this review as they dealt with the epidemiology or the primary prevention of ECC. On the other hand, it was surprising that the management options of ECC have not been investigated profoundly. In addition, rather rare options of posts in primary incisors have been examined in RCTs [Eshghi et al., 2013; Sawant et al., 2017], whereas frequently performed options such as fluoride varnish and fillings (glass ionomer cement, composite) have not been compared with each other in high-quality studies.

Management of cavitated carious lesions in primary teeth of very young children could be performed with SDF, as its effectiveness in arresting the activity of carious lesions (cavitated and non-cavitated) is clearly shown (Table 1). It is easy to apply, even outside dental offices, and relatively inexpensive solutions can be used, especially when compared to restorative intervention under GA. The few but relevant drawbacks of SDF are that: (1) not in all countries a SDF product is available or not to be used for caries management (off-label use only) and (2) the occurring black staining can result in a lower acceptability for caries management by parents/caretakers.

Nonoperative management of ECC has also shown to have moderate potential to inactivate the carious process, especially in enamel lesions (Table 2). The process of inactivation of dentinal carious lesions occurs clearly slower and less predictable, when compared with the applica-

tion of SDF. Similarly to the findings in this review (Tables 1, 2), the American evidence-based clinical practice guideline for NOCM in primary teeth strongly recommends 38% SDF for any cavitated carious lesion and 5% sodium fluoride varnish for non-cavitated enamel lesions [Slayton et al., 2018].

The combination of daily toothbrushing with fluoride toothpaste at home and fluoride varnish application in office or kindergartens has the advantageous effect that healthy behaviours such as daily toothbrushing and fluoride use are trained in recall visits, which may influence conviction of parental self-efficacy, laying the responsibility of treatment of ECC into caregivers hands away from the dentist (SDF or restoration). Adherence to oral hygiene instructions and diet counselling are essential in caries management on patient level and should be addressed for long-term effects. Guiding the awareness and understanding of one's responsibility are important for a potential long-term oral health in the children, making it clear that despite other management options NOCM should be obligatory for all children with ECC as an approach of secondary prevention on a child and tooth level.

RAs for the management of ECC are possible, but there was low scientific evidence to suggest that conventional composite fillings for anterior teeth are a valid surgical option in ECC. There is also insufficient information about atraumatic restorative treatment in anterior primary teeth leaving little scientific evidence for the choice of restoration [Waggoner, 2015] or a restoration at all instead of an extraction. Only in the studies where a post was used followed by a composite strip crown, higher success rates could be achieved (Table 3).

The RA often masks the caries activity in the child with ECC as the restorations show a high risk of failure frequently due to secondary carious lesions. When taking moderate success rates of 50–90% on the tooth level even for fillings performed under optimal circumstances such as GA (Table 3), these rates diminish to very low success rates on a patient level due to the usually high numbers of affected teeth in one child. GICs that are less technique sensitive and being placed in only one increment could restore and arrest active dentin carious lesions, but there was low scientific evidence to suggest GIC as material of choice for anterior primary teeth [Zhi et al., 2012]. When a RA is chosen for multisurface cavities, composite strip crowns should be favoured over fillings, but possibly pre-veneered stainless steel crowns or prefabricated primary zirconia crowns have higher success rates [Walia et al., 2014]. For RAs due to very young age and deep carious

lesions with potential pulpal involvement invasive treatment may frequently be performed under sedation or GA with all its risks, efforts and costs, which should always play a role in the individual decision-making process on how to intervene in the carious process of ECC.

Conclusion

Measures of secondary prevention should always be applied when managing ECC. Additionally, fluoride varnish is to be suggested for non-cavitated lesions and SDF for cavitated dentine lesions without irreversible pulpal involvement, while decisions for RAs should consider patient-related risk factors and the likelihood for the necessity of sedation or GA.

Acknowledgment

The authors especially thank David Manton for contribution in the search string.

Statement of Ethics

This research complies with the guidelines for human studies and was conducted ethically in accordance with the World Medical Association Declaration of Helsinki.

Disclosure Statement

Authors declare no conflicts of interest.

Author Contributions

J.S., K.G., C.H.S., and H.J. conceived the ideas of the systematic review and the methodological approach; K.G. and J.S. performed the screening and data extraction of this literature review. Final selection was performed by J.S., C.H.S., K.G., and H.J. The writing was led by J.S., C.H.S., and H.J.

References

- Amin M, Nouri MR, Hulland S, ElSalhy M, Azarpazhooh A. Success rate of treatments provided for Early Childhood Caries under general anesthesia: A retrospective cohort study. *Pediatric Dent.* 2016;38(4):317–24.
- Arrow P. Restorative outcomes of a minimally invasive restorative approach based on atraumatic restorative treatment to manage Early Childhood Caries: A randomised controlled trial. *Caries Res.* 2016;50(1):1–8.

- Autio-Gold JT, Courts F. Assessing the effect of fluoride varnish on early enamel carious lesions in the primary dentition. *J Am Dent Assoc*. 2001 Sep;132(9):1247–53.
- Bücher K, Tautz A, Hickel R, Kühnisch J. Longevity of composite restorations in patients with early childhood caries (ECC). *Clin Oral Investig*. 2014 Apr;18(3):775–82.
- Casamassimo PS, Thikkurissy S, Edelstein BL, Maiorini E. Beyond the dmft: the human and economic cost of early childhood caries. *J Am Dent Assoc*. 2009 Jun;140(6):650–7.
- Chen KJ, Gao SS, Duangthip D, Lo EC, Chu CH. Early childhood caries and oral health care of Hong Kong preschool children. *Clin Cosmet Investig Dent*. 2019 Jan;11:27–35.
- Chibinski AC, Wambier LM, Feltrin J, Loguercio AD, Wambier DS, Reis A. Silver diamine fluoride has efficacy in controlling caries progression in primary teeth: A systematic review and meta-analysis. *Caries Res*. 2017;51(5):527–41.
- Chu CH, Lo EC, Lin HC. Effectiveness of silver diamine fluoride and sodium fluoride varnish in arresting dentin caries in Chinese preschool children. *J Dent Res*. 2002 Nov;81(11):767–70.
- Collado V, Pichot H, Delfosse C, Eschevins C, Nicolas E, Hennequin M. Impact of early childhood caries and its treatment under general anesthesia on orofacial function and quality of life : A prospective comparative study. *Med Oral Patol Oral Cir Bucal*. 2017 May;22(3):e333–41.
- Contreras V, Toro MJ, Elias-Boneta AR, Encarnación-Burgos A. Effectiveness of silver diamine fluoride in caries prevention and arrest: a systematic literature review. *Gen Dent*. 2017 May-Jun;65(3):22–9.
- Divaris K, Preisser JS, Slade GD. Surface-specific efficacy of fluoride varnish in caries prevention in the primary dentition: results of a community randomized clinical trial. *Caries Res*. 2013;47(1):78–87.
- Drury TF, Horowitz AM, Ismail AI, Maertens MP, Rozier RG, Selwitz RH. Diagnosing and reporting early childhood caries for research purposes. A report of a workshop sponsored by the National Institute of Dental and Craniofacial Research, the Health Resources and Services Administration, and the Health Care Financing Administration. *J Public Health Dent*. 1999;59(3):192–7.
- Duangthip D, Jiang M, Chu CH, Lo EC. Non-surgical treatment of dentin caries in preschool children—systematic review. *BMC Oral Health*. 2015 Apr;15(1):44.
- Duangthip D, Wong MC, Chu CH, Lo EC. Caries arrest by topical fluorides in preschool children: 30-month results. *J Dent*. 2018 Mar;70:74–9.
- Eshghi A, Kowsari-Isfahan R, Khoroushi M. Evaluation of three restorative techniques for primary anterior teeth with extensive carious lesions: a 1-year clinical study. *J Dent Child (Chic)*. 2013 May-Aug;80(2):80–7.
- Gao SS, Zhang S, Mei ML, Lo EC, Chu CH. Caries remineralisation and arresting effect in children by professionally applied fluoride treatment - a systematic review. *BMC Oral Health*. 2016 Feb;16(1):12.
- Gao SS, Zhao IS, Hiraishi N, Duangthip D, Mei ML, Lo EC, et al. Clinical trials of silver diamine fluoride in arresting caries among children: A systematic review. *JDR Clin Trans Res*. 2016 Oct;1(3):201–10.
- Itaborahy R, Machado FC, Elias GP, Ribeiro LC, Ribeiro RA. Clinical effectiveness of two commercial fluoride varnish formulations on the control of white spot lesion in primary teeth: A pilot study. *Pesqui Bras Odontopediatria Clin Integr*. 2015;15:41–8.
- Liberati A, Altman DG, Tetzlaff J, Mulrow C, Götzsche PC, Ioannidis JP, et al. The PRISMA statement for reporting systematic reviews and meta-analyses of studies that evaluate health care interventions: explanation and elaboration. *PLoS Med*. 2009 Jul;6(7):e1000100.
- Lo EC, Schwarz E, Wong MC. Arresting dentine caries in Chinese preschool children. *Int J Paediatr Dent*. 1998 Dec;8(4):253–60.
- Machiulskiene V, Campus G, Carvalho JC, Dige I, Ekstrand KR, Jablonski-Momeni A, et al. Terminology of dental caries and dental Caries management: consensus report of a workshop organized by ORCA and Cariology Research Group of IADR. *Caries Res*. 2019, Epub ahead of print.
- Memarpour M, Fakhraei E, Dadaein S, Vossoughi M. Efficacy of fluoride varnish and casein phosphopeptide-amorphous calcium phosphate for remineralization of primary teeth: a randomized clinical trial. *Med Princ Pract*. 2015;24(3):231–7.
- Oliveira BH, Rajendra A, Veitz-Keenan A, Niederman R. The effect of silver diamine fluoride in preventing caries in the primary dentition: A systematic review and meta-analysis. *Caries Res*. 2019;53(1):24–32.
- Peretz B, Gluck G. Early childhood caries (ECC): a preventive-conservative treatment mode during a 12-month period. *J Clin Pediatr Dent*. 2006;30(3):191–4.
- Ram D, Fuks AB. Clinical performance of resin-bonded composite strip crowns in primary incisors: a retrospective study. *Int J Paediatr Dent*. 2006 Jan;16(1):49–54.
- Sawant A, Chunarwalla Y, Morawala A, S Kanchan N, Jain K, Talathi R. Evaluation of novel glass fiber-reinforced composite technique for primary anterior teeth with deep carious lesions: A 12-month clinical study. *Int J Clin Pediatr Dent*. 2017 Apr-Jun;10(2):126–30.
- Sitthisetpong T, Phantumvanit P, Huebner C, Derouen T. Effect of CPP-ACP paste on dental caries in primary teeth: a randomized trial. *J Dent Res*. 2012 Sep;91(9):847–52.
- Slayton RL, Urquhart O, Araujo MW, Fontana M, Guzmán-Armstrong S, Nascimento MM, et al. Evidence-based clinical practice guideline on nonrestorative treatments for carious lesions: A report from the American Dental Association. *J Am Dent Assoc*. 2018 Oct;149(10):837–49.e19.
- Thomson WM. Public Health aspects of paediatric dental treatment under general anaesthetic. *Dent J (Basel)*. 2016;4(2):20.
- Tinanoff N, Baez RJ, Diaz Guillory C, Donly KJ, Feldens CA, McGrath C, et al. Early childhood caries epidemiology, aetiology, risk assessment, societal burden, management, education, and policy: global perspective. *Int J Paediatr Dent*. 2019 May;29(3):238–48.
- Traitratvorakul C, Piwat S. Comparative clinical evaluation of slot versus dovetail Class III composite restorations in primary anterior teeth. *J Clin Pediatr Dent*. 2004;28(2):125–9.
- Waggoner WF. Restoring primary anterior teeth: updated for 2014. *Pediatr Dent*. 2015 Mar-Apr;37(2):163–70.
- Walia T, Salami AA, Bashiri R, Hamoodi OM, Rashid F. A randomised controlled trial of three aesthetic full-coronal restorations in primary maxillary teeth. *Eur J Paediatr Dent*. 2014 Jun;15(2):113–8.
- Wyne AH. Early childhood caries: nomenclature and case definition. *Community Dent Oral Epidemiol*. 1999 Oct;27(5):313–5.
- Zhi QH, Lo EC, Lin HC. Randomized clinical trial on effectiveness of silver diamine fluoride and glass ionomer in arresting dentine caries in preschool children. *J Dent*. 2012 Nov;40(11):962–7.