

Unwanted Skin Reactions to Acrylates: An Update

Lugović-Mihić, Liborija; Filiija, Eva; Varga, Vanja; Premuž, Lana; Parać, Ena; Tomašević, Renata; Barac, Ema; Špiljak, Bruno

Source / Izvornik: **Cosmetics, 2024, 11**

Journal article, Published version

Rad u časopisu, Objavljena verzija rada (izdavačev PDF)

<https://doi.org/10.3390/cosmetics11040127>

Permanent link / Trajna poveznica: <https://um.nsk.hr/um:nbn:hr:127:099726>

Rights / Prava: [Attribution 4.0 International](#) / [Imenovanje 4.0 međunarodna](#)

Download date / Datum preuzimanja: **2024-11-26**






Repository / Repozitorij:

[University of Zagreb School of Dental Medicine
Repository](#)



Review

Unwanted Skin Reactions to Acrylates: An Update

Liborija Lugović-Mihić ^{1,2,*} , Eva Filija ^{1,2}, Vanja Varga ^{1,2}, Lana Premuž ^{1,2}, Ena Parać ¹ , Renata Tomašević ^{1,2},
Ema Barac ¹ and Bruno Špiljak ^{2,*} 

¹ Department of Dermatovenereology, University Hospital Center Sestre Milosrdnice, 10000 Zagreb, Croatia; efilija@sfzg.hr (E.F.); vvarga@sfzg.hr (V.V.); lpremuz@sfzg.hr (L.P.); enaparac7@gmail.com (E.P.); renatavalogmail.com (R.T.); ema.barac@gmail.com (E.B.)

² School of Dental Medicine, University of Zagreb, 10000 Zagreb, Croatia

* Correspondence: liborija@sfzg.hr (L.L.-M.); bruno.spiljak@gmail.com (B.Š.)

Abstract: Acrylates and methacrylates, though common in a wide variety of products, especially in the dental industry, can cause adverse skin reactions. These compounds, including 2-hydroxyethyl methacrylate, triethylene glycol dimethacrylate, and bisphenol A-glycidyl methacrylate, are strong contact irritants or allergens. Found in dental prostheses, composite resins, dentin bonding materials, and glass ionomers, they pose a higher risk of exposure for dental personnel. Clinically, acrylate allergies manifest as facial rashes, eczema with cracked skin on fingers (pulpitis), nail dystrophy, and periungual dermatitis. Recently, however, the highest frequency of allergic reactions to acrylates has been observed in the beauty industry due to increased use in artificial nails, eyelashes, and hair extensions. This has led to greater sensitization. Acrylates are also used in medical applications such as bone cement for orthopedic endoprostheses, soft contact lenses, hearing aids, histological preparations, and wound dressings, which can also cause allergic reactions. For example, acrylates in surgical glue can cause severe dermatitis, and diabetic medical devices are also potential sources of allergic contact dermatitis. Given the extensive use and prolonged skin contact of products containing acrylates and methacrylates, this review aims to present current knowledge from the literature on reactions to these compounds across different industries.

Keywords: acrylates; methacrylates; contact reactions; skin; dentistry; cosmetics; allergy; contact dermatitis; nails; sensitization



Citation: Lugović-Mihić, L.; Filija, E.; Varga, V.; Premuž, L.; Parać, E.; Tomašević, R.; Barac, E.; Špiljak, B. Unwanted Skin Reactions to Acrylates: An Update. *Cosmetics* **2024**, *11*, 127. <https://doi.org/10.3390/cosmetics11040127>

Academic Editor: Enzo Berardesca

Received: 7 June 2024

Revised: 18 July 2024

Accepted: 23 July 2024

Published: 25 July 2024



Copyright: © 2024 by the authors. Licensee MDPI, Basel, Switzerland. This article is an open access article distributed under the terms and conditions of the Creative Commons Attribution (CC BY) license (<https://creativecommons.org/licenses/by/4.0/>).

1. Introduction

Acrylates are plastic materials obtained by polymerizing monomers derived from acrylic or methacrylic acid [1–4]. The type of acid utilized in the esterification process of these monomers influences their reactivity [5–9]. Acrylates serve as the basis for acrylic resins [10]. The double bonds of acrylates allow for polymerization to occur quickly at room temperature (spontaneously) or with the help of heat/ultraviolet (UV) light [11].

Acrylate monomers have many applications [11,12]. Thus, the presence of acrylates and methacrylates (MAs) is widespread, primarily in the dental industry. They are used in dental prostheses, composite resins, dentin bonding materials, and glass ionomers [9,10,13–15]. Historically, the most frequent human exposures to acrylates that were related to production processes were the most common forms of exposure to acrylates, especially printing, dyeing, coating, the metallurgical industry, and dentistry [11,12]. Familiar sources of acrylates include floor waxes, leather treatments, and textile and paper products. Today, many (meth)acrylates are mainly used in dental binders, printing inks, artificial nails, etc. By profession, dental personnel are particularly at risk for acrylate and MA allergies [16].

Contact dermatitis is an inflammatory dermatosis that can be triggered by various chemicals that cause irritant (toxic) effects or induce immune responses [4,6]. Allergic contact dermatitis (ACD) occurs only in persons who are sensitive to certain substances,

while the irritant type may occur in all people and depends on related factors like the amount and concentration of the substance, duration and frequency of exposure (short concentrated exposure or low repeated/prolonged exposure), previous skin damage, atopy constitution, etc. [7]. Contact dermatitis may manifest as an acute or chronic form (after repeated exposures) [8,9]. Contact dermatitis is a relatively frequent dermatosis, where the irritant type is more common than the allergic form [10]. By comparison, the irritant type is a non-specific skin reaction to direct chemical skin damage with the release of inflammatory mediators, while the allergic type is a delayed hypersensitivity reaction to allergens that includes immune responses [11]. Thus, irritant contact dermatitis (ICD) does not involve immune reactions, no sensitization (previous exposure to the substance) is required, and most individuals exposed to the same substance manifest a similar reaction [15]. Sometimes contact dermatitis (irritant or allergic) can be related to occupational activities and different workplace factors [17].

Acrylates and MAs can be irritants and allergens. Thus, acrylates and, more rarely, MAs such as 2-hydroxyethyl methacrylate (2-HEMA), triethylene glycol dimethacrylate (TEGDMA), and 2,2-bis[4-(2-hydroxy-3-methacryloxypropoxy)phenyl]propane (bis-GMA) are strong contact irritants or allergens. These compounds have been found in uncured dental adhesives and cement in 50 to 90% concentrations. It is also important to mention that methyl methacrylate (MMA) can penetrate through thin protective disposable gloves as a small molecular acrylate. While exposure to solid acrylic plastics is generally harmless, MA can evaporate even when solid, increasing the risk of exposure and irritation [8]. Thus, ACD caused by MA has been well documented. In ACD, skin reactions appear 24–48 h after repeated contact with an allergen/substance to which the skin was previously exposed and developed sensitization [17]. In addition, many papers on occupational ACD caused by (meth)acrylate monomers have also been published [11].

2. Chronological Development of the Application of Acrylates and the Appearance of Adverse Reactions

Starting in the 1930s, acrylates and methacrylates were developed for use in paints, glues, inks, and, most notably, plastic glass, trademarked as Plexiglas. Thus, their use became ubiquitous in a number of industries, including the medical and cosmetic industries [18–22].

Since the 1950s, many cases of ACD have been documented due to MMA exposure. Numerous papers have been published on the occupational origin of ACD caused by (meth)acrylate monomers since that time [11]. Occupational allergy to (meth)acrylates is also possible, which most often occurs among dental staff. In the 1990s, dental professionals observed a significant increase in sensitization to acrylates [23]. Dental personnel are exposed to many potential contact allergens, including untreated plastic (acrylate) resins such as acrylic monomers, MAs, urethane acrylates, and epoxy acrylates. These have been used in dentistry in dentures, dentin bonding materials, and glass ionomer materials [11,24]. Due to the frequent observation of these reactions, (meth)acrylates were named “allergen of the year” in 2012 by the American Society for Contact Dermatitis [8,10]. Additionally, isobornyl acrylate (IBOA) was 2020’s contact allergen of the year [11,25].

In recent decades, allergies to (meth)acrylates have been on the rise. These allergies are prevalent not only in dentistry but also in the beauty and medical device industries. For example, with the popularity of permanent manicures, reactions to acrylates in permanent nail polish have contributed to the rise in incidence. Another example is reactions caused by medical devices for diabetics [11].

3. Acrylates in Cosmetics and Medicine

The first case of an acrylate allergy to artificial nail products was reported by Canizares in 1956 [11,26–29]. Now, (meth)acrylate allergies in the beauty industry outpace the incidence in dentistry [26]. Artificial eyelashes and nails, as well as hair extensions, are the most common sources of exposure [27,28]. The wide availability of nail techniques based on

acrylates, MAs, or cyanoacrylates and the increased use of artificial nails has led to greater sensitization in beauticians and their clients [11,16,30]. Also, with the use of commercial nail kits for home use, there is an even greater risk of allergy development, already reported in Australia, Sweden, and Spain [27,31]. Notably, the appearance of an allergy can occur even after a person has already used artificial nails for months or years [11].

Nowadays, new sources of acrylates have appeared [11]. For example, a case of acrylate ACD caused by a liquid adhesive for a fixed hair prosthesis (in a man with scarring alopecia) was described after 4 weeks of use (Ghostbond) [32]. The patient developed pruritic eczematous lesions on the scalp and, despite switching out the liquid adhesive for tape, no improvement was seen [32]. A patch test confirmed an allergy to hydroxypropyl methacrylate (2-HPMA), hydroxyethyl acrylate, butyl acrylate, adhesive tape, and Ghostbond glue (2+). However, IBOA, previously used mainly in coatings, inks, cosmetics, and paints, is also a potential allergen, though less frequent than other (meth)acrylates [33].

Acrylates are also widely used for various medical purposes; thus, contact with anything from bone cement and wound dressings to histological preparations can trigger allergic reactions. Surgical glue, for instance, has been known to cause severe dermatitis, and adhesives used on the skin are known to pose a high risk for primary sensitization [11].

Multiple reports also indicate that diabetic medical devices are an important cause of ACD. For example, new technologies for rapid glucose measurement have been implicated [34]. According to the results of one multicenter study, skin reactions to Freestyle Libre, a flash glucose monitoring (FGM) system (which involves fixing the device to the skin with adhesive for two weeks), may occur directly below the adhesive part of the sensor and most patients exhibited a proven allergy to isobornyl acrylate, a component of the device [11,33,34]. In another study, following 70 diabetics (type 1) with a suspected contact allergy to their glucose sensor (tested by patch test), 81% of Freestyle Libre users exhibited IBOA reactions [33]. Recently, reactions to IBOA in insulin pumps have also been identified (OmniPod) [11,35]. Therefore, based on current observations and recommendations, manufacturers need to eliminate this allergen from these devices due to the increased prevalence of acrylate allergies [34]. Other acrylates, such as N,N-dimethylacrylamide (DMAA) and 2-ethyl cyanoacrylate adhesive, are also potential sensitizers in insulin infusion and glucose monitoring devices [36]. As a preventive measure, in cases of ACD caused by acrylates, patients can use hydrocolloid plates as a barrier that limits skin exposure to device adhesives [11,37,38].

Other sources of sensitization to acrylates include electrodes for transcutaneous electrical nerve stimulation (TENS) and electrocardiogram electrode adhesives [38,39]. Allergic reactions to acrylates can also occur in plastic surgery. For example, a case was described where a patient developed ACD to polymethyl methacrylate (PMMA) after an intradermal filler was used for the tip of his nose. Subsequently, an allergy to MMA (3+) was proven [40].

4. Acrylates as a Cause of Allergic Contact Dermatitis and Other Disorders

Clinically, an allergy to acrylates most often appears as a rash on the face and/or eyelids, hand eczema with cracking of the finger skin (pulpitis), nail dystrophy, and periungual dermatitis (Figure 1) [5,19]. When a person is sensitized to acrylate, lesions can appear anywhere on the skin, though the site of direct contact is where they commonly appear, often the hands and face. The overall clinical picture of skin allergy can also manifest as acquired leukoderma on the fingertips or sometimes with simultaneous dermatitis of the face or neck [11,16,30,41]. Nail abnormalities similar to psoriasis (due to onycholysis and severe subungual hyperkeratosis) can occur. However, not all skin lesions at contact sites can be attributed to ACD alone; other manifestations, such as irritant (non-allergic) contact dermatitis, may also occur. In a differential diagnosis of skin lesions, “acne mechanica,” which manifests as inflammatory papules and pustules caused by mechanical pressure, should also be considered [42]. In addition, acrylates and MAs can also cause asthma [43].

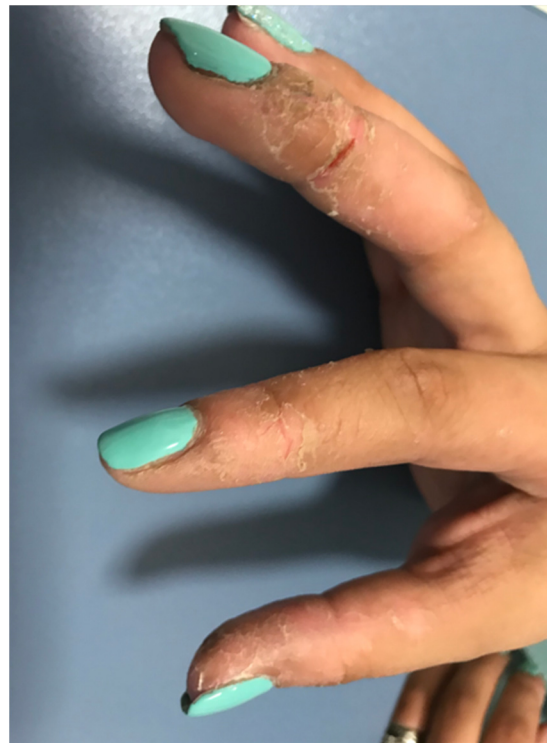

Figure 1. Skin lesions in the person who works as a manicurist (image from the archive of the main author, Prof. Dr. Lugović Mihić).

Different frequencies of allergies to certain acrylate haptens have been observed among dental personnel. For dentists and dental nurses, common allergens are 2-HEMA and MMA, while ethylene glycol dimethacrylate (EGDMA) is common for dental technicians [44]. According to the results of a study testing allergies in dental technicians and the connection with work-related ACD (patch tests conducted from 2001 to 2015 in Germany), the most common contact allergens were MAs and acrylates [24]. Eczema of the hand and fingertips were observed as typical clinical manifestations of allergies to (meth)acrylate in these dental professions, though generalized dermatitis is also possible [44–47]. The face and eyelids can also sometimes be affected due to acrylate particles in the air or the transmission of allergens via contaminated tools or hands [27]. Additionally, acrylates can cause respiratory hypersensitivity, such as difficulty breathing, asthma, or rhinoconjunctivitis.

Among other unwanted changes/lesions induced by acrylates, the term allergic contact stomatitis (ACS) is described in the literature. This condition has been seen in connection to dental prosthetic replacements where the acrylates used were not properly polymerized. [48]. Patients with ACS may experience oral symptoms like burning or pain in the mouth, loss of taste, numbness, inflammation of the mucous membrane, vesicles, erosions, and lichenoid reactions limited to the area of contact with dental materials [11]. Therefore, caution is recommended when working with sensitized patients who need dental procedures, as they may experience complications during dental work [49]. However, sometimes inadequately performed dental prosthetic work (which, by its impact, disrupts the biological width of the periodontium) can cause inflammation of the underlying mucosa (with hyperemia and erythema), or patients, after the creation of new prosthetic work, can report clinical problems (burning mouth syndrome), and so often wrongly/unfairly declare it an oral allergic reaction. Therefore, clinicians need to consider these possibilities when working with patients [50,51]. It is also important to note that lip and perioral skin inflammation can be triggered by certain metals or acrylates [52]. When cheilitis results from an allergic reaction, the lesions are usually localized to the site of contact.

Looking at adverse reactions when working in cosmetics, ACD caused by acrylates in artificial nail techniques is frequently overlooked due to the unobserved association of manicure product use with nail abnormalities [12,53]. In establishing a diagnosis, the clinical picture involvement of all the nails and the absence of psoriasis of the nails (e.g., “salmon patches”) can help (nail biopsies often are not necessary) [54]. According to research, acrylate allergy occurs most often in young female beauticians who suffer from hand dermatitis and sometimes facial dermatitis [27]. According to an international retrospective study [11 European Environmental Contact Dermatitis Research Groups (EEC DRGs)], most cases of ACD were to acrylates in nail styling materials (67%): 43% of patients were users/consumers, and 56% were contractors/workers. Furthermore, most occupational ACD cases (65%) were detected during the first year on the job. Study results highlight the high sensitizing power of acrylates [8,11,28]. A positive reaction to two or more acrylates was found in most patients, 2-HEMA, 2-HPMA, EGDMA, and ethyl cyanoacrylate being the most common allergens [11,28].

Looking at the negative impact of acrylates on beauticians, the mucosa of the eye, nasal passages, and respiratory tract can also be involved. In beauticians, there is a possible direct connection between exposure to allergens at the workplace, including (meth)acrylates, with lung function and airway inflammation [55]. Their nasal and respiratory symptoms can be associated with the strong irritating properties of acrylates [11,55]. Conjunctivitis, asthma, and rhinitis are all possible [49,55].

The negative influence of acrylates when performing eyelash extensions (a modern cosmetic trend) should also be mentioned, with possible unwanted reactions resulting from the process of glueing on artificial eyelashes (eyelash by eyelash on the natural eyelashes of clients) with glue that often contains cyanoacrylates. Clinically, possible unwanted manifestations in clients include eye disorders such as blepharitis and hand eczema in the beautician [56]. Conjunctivitis and rhinitis may occur first during the application of acrylate glue for eyelashes (which stimulates the influx of eosinophils into the tears and then into the nasal mucosa). A case was described of a beautician who used eyelash glue with acrylate to extend artificial eyelashes for two years (containing ethyl-2-cyanoacrylate, alkoxy-2-cyanoacrylate, and PMMA), leading to eye and nasal symptoms (discontinuing the use of these adhesives led to the withdrawal of symptoms) [11].

5. Diagnosis and Proof of Allergy to Acrylates

Patch testing is the gold standard for confirming the diagnosis of allergy to acrylates and to metals and other contact allergies (Figures 2 and 3) [11]. Thus, patch testing is useful for the investigation and confirmation of allergies to various substances (including acrylates) that cause allergic contact dermatitis. The test involves applying allergens (appropriately diluted) to the skin of the back for 48 h (In some specific situations when it is not possible to apply the allergens to the back, it may be carried out on another part of the body.). After 48 h, the allergens are removed, (the first reading) and, at 96 h, the results are recorded a second time (sometimes, also after 7 or 10 days for some allergens). In the case of positive allergic reactions at the sites of application, vesicles, papules, or blisters, etc., may be seen. Standard allergen sets for patch tests vary by country, but additional allergens may also be tested. Generally, aside from the patch test, which confirms type IV contact allergic reactions, there is also the prick test, which confirms early type I allergic reactions to, e.g., inhalant allergens and food, but is not important in the case of allergy to acrylates [1,11,14].

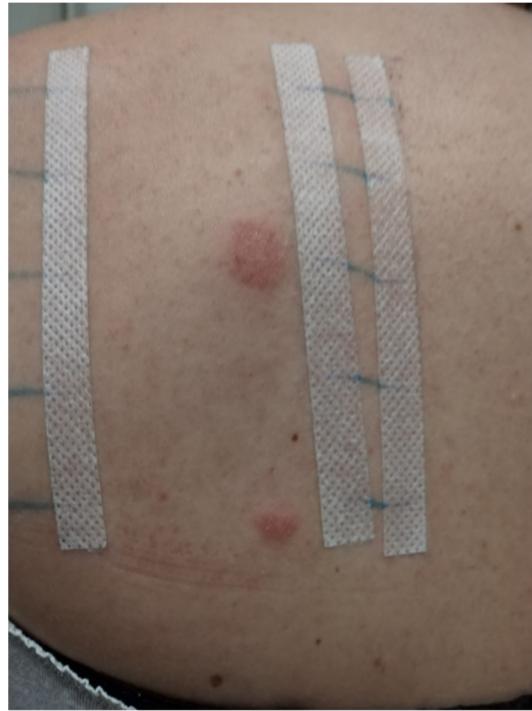

Figure 2. Positive patch test for contact allergens/standard testing procedure (image from the archive of the main author, Prof. Dr. Lugović Mihić).

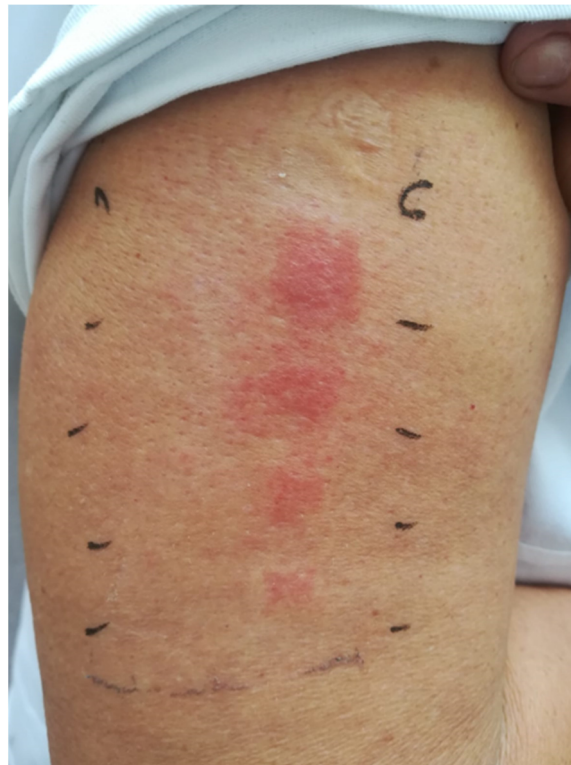

Figure 3. Positive patch test for acrylates and MAs in a dentist (image taken from the doctoral dissertation of Dr. Iva Japundžić [57], courtesy of Dr. Iva Japundžić Rapić).

Many commercial patch tests include acrylic monomers used in dentistry and the cosmetics industry [44]. A polyvalent allergy to acrylates is also common in test results (multiple positive reactions in the patch test), although individual patients likely would

not be exposed to each of these substances. In these cases, acrylic monomers may be cross-reacting due to their simultaneous presence in some products [8,44]. According to a study on acrylic compounds and cross-reactivity, sensitized patients were allergic to multiple compounds from the test (66.3%), which points to the need for preventive measures [10]. According to the results of a study conducted on 67 patients allergic to (meth)acrylates, reactions to one or two (meth)acrylates were proven in 42% of them, while allergies to ≥ 5 (meth)acrylates in 33% [24]. According to Raposo et al., positive patch tests for HEMA acrylates were observed in more than 90% of patients with an allergy to acrylates [21]. In comparison, 64.1% were positive for 2-HPMA, which could be a useful screening marker [21]. For this reason, 2-HEMA and HPMA should be included in the European basic patch test series [11,30]. Also, since acrylic monomers often cause cross-reactions, sensitized persons should not be exposed to any of these compounds [10,58].

In study results of allergy tests for nail acrylates and the results of their patch tests ("European Baseline Series and Acrylate Series Nails Artificial" and 10% ethyl cyanoacrylate), significant contact allergies to triethylene glycol diacrylate were observed [22]. In other studies, reactions were seen to dental and surgical products and medical devices. Therefore, clinicians and patients/clients who are in contact with acrylates should be adequately informed about possible adverse reactions, including how to recognize and confirm them [11,48].

According to research by Lyapina, more than two-thirds of all dentistry workers/students who reported skin symptoms (61.9%) were third- and fourth-year students and practitioners (most often without skin symptoms were dental professionals) [10]. According to these results, the general sensitization rates to MAs in the studied population were relatively high: from 25.9% (for MMA) to 31.7% (for TEGDMA). In addition, a significantly higher frequency of sensitization to MMA and TEGDMA in third- and fourth-year students compared with dental professionals was also observed. A significantly higher frequency of sensitization to EGDMA, BIS-GMA, 2-HEMA, and tetrahydrofuryl methacrylate was recorded in patients compared with dental professionals. Therefore, greater awareness of the possible adverse effects of exposure to MAs is needed [10].

Regarding the diagnostics of potential oral manifestations from acrylates, although the patch test is a standard method for confirmation of contact allergies, the correct interpretation of the results and their clinical importance for oral mucosal lesions (histologically different from the skin) can be complex. Differences in the concentration of haptens in the oral mucosa compared with standard substances and differences in pH values are essential for the patch test results, which can lead to false positive/negative results or non-specific irritant reactions [59]. Also, sometimes inadequately made prosthetic works can imitate allergic reactions, and assessing the clinical importance of haptens in dental materials is difficult.

6. Allergy to Acrylates and Methacrylates in Dental Workers and Students

Many acrylic monomers are used in dentistry, so dental workers (dentists, dental technicians, patients, or dental students) can become sensitized when it is necessary to examine the possibility of adverse reactions to dental preparations based on the acrylates to which they are exposed. Numerous studies confirm the high frequency of sensitization to (meth)acrylates in dental professionals and their patients (who are exposed to resin-based materials during dental treatments) [10]. In their daily activities, dental professionals and dental students are exposed to numerous chemical substances, primarily from various dental materials and drugs. Thus, dental products contain numerous allergens and irritants that can cause health problems for dental professionals (during their professional exposure), dental students (during their education), and patients to whom the products are applied.

According to the literature data, the most common positive allergens among dentists and dental nurses are 2-HEMA, ethyl acrylate (EA), TEGDMA, and bis-GMA [10]. At the same time, 2-HEMA is considered the most critical allergen for dentists and dental nurses, while MMA and EGDMA are significant for dental technicians. The relevance of

the positive reaction is also crucial, as positive patch-test reactions to bis-GMA, diethylene glycol diacrylate (DEGDA), TEGDMA, ethyl methacrylate (EMA), and EA are relevant in some patients [10,44,58,60]. In the study population, overall sensitization rates to MAs are relatively high, varying from 25.9% for MMA to 31.7% for TEGDMA. The lowest frequency of sensitization is in dental professionals, while the highest rates vary (depending on the allergens and examined groups). There was significantly more frequent sensitization to MMA and TEGDMA in third- and fourth-year students than in dental professionals, likely related to their recent and intensive exposure to these substances during the second year of training [10]. Due to the occupational nature of the exposure, a patch test for contact allergens is required for the complete diagnosis and evaluation of professional skin allergy to MA in dental staff [9].

Numerous studies confirm the high frequency of sensitization to (meth)acrylates in dental professionals, and in patients who undergo dental treatment and are exposed to resin-based materials [14,61,62]. Several other studies have been conducted to assess the frequency of sensitization to acrylates in various populations (Table 1) [1–7,13,14,19,63,64].

Table 1. Selected data on unwanted reactions to acrylates obtained by different studies.

Author, Year [Reference Number]	Examinees/Patients	Analyzed Factors/Methods	Results	Conclusions
Kanerva L et al., 1993 [64]	4 patients (an orthodontist, 2 dental technicians, and an in-house trained dental worker)	Patch testing for allergens in dental prostheses	All patients had positive allergic patch test reactions to MMA.	Dental personnel working with prostheses had higher risk of sensitization. Patients working with dental prostheses should be patch-tested with MMA, 2-HEMA, dimethacrylates, epoxy acrylates, and urethane acrylates to detect occupational ACD.
Kiec-Swierczynska MK, 1996 [63]	1619 patients suspected of occupational CD (examined between 1990 and 1994)	Patch testing to acrylates and methacrylates including EGDMA, MMA, 2-HEMA, and TEGDMA	The most frequent sensitizers were EGDMA (5 positive patch tests), MMA (4), 2-HEMA (4), and TEGDMA (4). Sensitivity to acrylates was diagnosed in 9 patients (4 dental technicians, 4 dentists, 1 textile printer). The top three sensitizers were EGDMA (17 positive patch tests), 2-HEMA, (14), and TEGDMA (6).	Dentists were more sensitive to (meth)acrylate allergens and other allergens (metals and rubber additives). Dental technicians were mainly sensitive to methacrylates. The textile printer was only sensitive to acrylates.
Geukens S and Goossens A, 2001 [7]	3833 patients suspected of CD (from 1978 to 1999)	Patients were tested by patch test	Almost half the examinees (14/31) were affected by (meth)acrylate-containing dental materials (including dentists and dental technology students).	An increasing trend in dermatological issues associated with the expanding use of (meth)acrylates, particularly in dental professions.

Table 1. Cont.

Author, Year [Reference Number]	Examinees/Patients	Analyzed Factors/Methods	Results	Conclusions
Wrangsjö K et al., 2001 [13]	174 dental personnel referred as patients to the Department of Occupational and Environmental Dermatology, Stockholm (1995–1998)	Patch testing according to the Swedish standard series and a dental screening series. Testing for IgE-mediated allergy to natural rubber latex (NRL).	Hand eczema affected 63% of participants: 67% ICD, and 33% ACD. 59% of participants had positive reactions to standard series substances and 40% to the dental series; 22% had positive reactions to (meth)acrylates, primarily to multiple test preparations, including HEMA, EGDMA, and MMA. Allergy to NRL was recorded in 10% of patients.	Irritant hand dermatitis was the predominant diagnosis among dental personnel. Contact allergy to (meth)acrylate in around 20% of tested patients, mostly to 3 test substances: HEMA, EGDMA, and MMA. (Meth)acrylate allergy often coexisted with atopy and/or other contact allergies.
Goon AT et al., 2006 [14]	1639 subjects were patch-tested at the Department of Occupational and Environmental Dermatology, Malmö, Sweden	Patch tests for either dental patient series or dental personnel series including (meth)acrylate allergens and identification of common allergens and their prevalence in each group.	Positive patch tests for (meth)acrylate allergens were seen in 2.3% (30/1322) of the dental patients and 5.8% (18/310) of the dental personnel. The most common allergens for both groups were 2-HEMA, EGDMA, and MMA.	2-HEMA is an important screening allergen to detect contact allergy to (meth)acrylates used in the dental profession.
Isaksson M et al., 2007 [4]	A case report (dental nurse with facial eczema allegedly caused by airborne methacrylates in the workplace)	Patch testing with serial dilutions of several methacrylates and work provocations in methacrylate environments.	High reactivity to patch testing. Repeated exposure to methacrylates at work led to facial eczema; resolved when away from work. Efforts to collect the sensitizers using air pumps and filters failed. 37/122 patients showed a positive patch test with an extended (meth)acrylate series. 25 cases (67.6%) were occupational.	Facial dermatitis may be associated with airborne methacrylate exposure, which may involve allergy to ≥ 1 allergens.
Ramos L et al., 2014 [5]	An observational and retrospective study (January 2006–April 2013)	Evaluation and correlation of epidemiological and clinical parameters and positive patch test results for (meth)acrylates.	Hand eczema with pulpitis in 32 patients: 28 related to artificial nails, 3 to dental materials, and 2 to industrial work. Oral lesions associated with dental prostheses in 4 patients. 31/37 positive to >1 (meth)acrylate. Beauty technicians with artificial nails accounted for 80% of occupational cases.	HEMA detected in 80.6% of cases; may serve as a reliable screening allergen. A broader range of allergens is advisable for accurate diagnosis.

Table 1. Cont.

Author, Year [Reference Number]	Examinees/Patients	Analyzed Factors/Methods	Results	Conclusions
Muttardi K et al., 2016 [19]	A retrospective study of 241 patients who were patch-tested with meth(acrylates) and cyanoacrylates (January 2012–February 2015)	Patch testing with the mini-acrylate or extended acrylate series.	16/241 patients had positive patch-test reactions to (meth)acrylate or cyanoacrylate. Female predominance (M/F ratio of 1:15).	(Meth)acrylate allergy is mainly occupational, but more common in younger women, especially beauticians and nail technicians.
Havmose M et al., 2020 [2]	1293 female patients were patch-tested with HEMA	Two groups of patients based on their positive/negative patch test reactions to HEMA. MOAHLFA characteristics analyzed for both groups.	31 (2.4%) of the tested examinees tested positive for HEMA.	Sensitization and elicitation of ACD to HEMA primarily from artificial nail modeling systems; a significant health issue for consumers and certain professions.
Gregoriou S et al., 2020 [6]	156 female patients with ACD-using/performing cosmetic nail procedures (January 2009–December 2018)	The incidence of positive sensitization to (meth)acrylates assessed using patch tests.	Contact allergy to ≥ 1 (meth)acrylates in 74.4%: 88.5% occupationally exposed, and 11.5% consumers. A statistically significant increase in (meth)acrylate ACD from 2014 to 2018 (79%) compared with 2009 to 2013 (55%). EGDMA was the most common sensitizer positive in 72.4%. Among acrylate-positive patients, the rate was 97.4%.	A global trend of increasing (meth)acrylate sensitization among nail technicians and users of nail products with ACD. Enhancing preventive measures is essential.
Opalińska S et al., 2022 [3]	8 women with CD related to acrylates found in hybrid varnishes	Manicure using a home acrylic nail kit and a non-professional UV lamp. Clinical and dermoscopic features were assessed.	Allergen contact areas (skin and nails) were affected. Severity correlated with exposure duration. Common findings: subungual hyperkeratosis and onycholysis (8/8 patients), eczematous finger pulp fissuring (2/8 patients) (more specific).	Nail changes from hybrid manicures may resemble onychomycosis or nail psoriasis (patch tests in uncertain cases). ACD was suspected. Confirmed acrylate allergies require patient awareness and avoidance.

Table 1. Cont.

Author, Year [Reference Number]	Examinees/Patients	Analyzed Factors/Methods	Results	Conclusions
de Groot AC, Rustemeyer T, 2024 [1]	24 studies presenting case series and 168 case reports on patients with ACD attributed to HEMA	Review of cross- and co-sensitization, atypical contact allergy manifestations, HEMA versus other (meth)acrylates, HEMA's screening sensitivity, and its presence in commercial products.	Strong cross-allergy exists between HEMA, EGDMA, and HPMA. Reactions to EGDMA often from primary HEMA sensitization. Rare atypical manifestations of HEMA allergy include lichen planus, lymphomatoid papulosis, systemic CD, leukoderma post-positive patch tests, and systemic side effects (nausea, diarrhea, malaise, palpitations).	HEMA is the most common patch test-positive methacrylate; an effective screening agent for other (meth)acrylates allergies. Sensitization to HEMA 2% pet. in patch tests is exceedingly rare.

Abbreviations: ACD—allergic contact dermatitis; CD—contact dermatitis; EGDMA—ethylene glycol dimethacrylate; F—female; HEMA—hydroxyethyl methacrylate; HPMA—hydroxypropyl methacrylate; ICD—irritant contact dermatitis; M—male; MMA—methyl methacrylate; MOAHLFA—male, occupational relevance, a history of atopic dermatitis, hand eczema, leg dermatitis, and facial dermatitis, age > 40 years; TEGDMA—triethylene glycol dimethacrylate; 2-HEMA—2-hydroxyethyl methacrylate.

Due to the frequent use of acrylic monomers in dentistry, dental workers (including staff, patients, and students) sometimes develop sensitivities, as indicated by a positive patch test. It is essential to identify these individuals and assess the significance of their allergies. In addition to proving sensitization to allergens by patch testing, it is necessary to examine the relevance of these reactions [65]. It is also crucial for all acrylics in products, even those in low concentrations, to be labeled.

Safety precautions for dental patients regarding acrylates are crucial to prevent allergic reactions, minimize exposure, and ensure overall health. Before using acrylate-based materials, dental practitioners should review a patient's medical history for any known allergies to acrylates or related compounds. This helps to identify patients at risk for allergic reactions [66]. When possible, dental practitioners should use acrylate materials formulated to minimize allergenic potential. Some newer formulations have reduced levels of residual monomers that can cause sensitization [67]. Acrylate materials should be handled and stored according to manufacturer instructions to prevent premature polymerization and reduce the risk of exposure to volatile compounds [68]. Dental staff should wear appropriate personal protective equipment (PPE), such as gloves and masks, to prevent direct skin contact with uncured acrylate materials. Patients should also be protected from direct skin contact with these materials [69,70]. Dental clinics should be equipped with adequate ventilation systems and fume extraction units to reduce the concentration of airborne acrylate vapors, which can cause respiratory sensitization [71]. Also, ensuring that acrylate materials are properly cured can significantly reduce the amount of residual monomer, thereby minimizing the risk of sensitization and allergic reactions. Furthermore, proper curing protocols should be followed as per the manufacturer's guidelines [72]. Finally, patients should be monitored for any signs of allergic reaction or sensitization after procedures involving acrylates. Immediate steps should be taken if any adverse reactions are observed [66].

7. Preventive Procedures

Health professionals need to be aware that skin reactions in the workplace can be due to acrylates and that applying preventive measures can avoid contact dermatitis [9]. PPE, such as protective gloves, goggles, masks, and disposable aprons should be used. Non-contact techniques are also important ways to avoid exposure [73].

One good option is the use of nitrile rubber gloves, which offer good resistance to MA penetration and lower monomer penetration rates. Nitrile gloves, as opposed to latex gloves, are a more effective option when exposure is shorter (15–20 min), as demonstrated by a patch test on glove fragments [11]. Gloves should also be changed frequently. Morgado et al. concluded that nitrile gloves should be changed during procedures after 30 min [74].

In the beauty industry, in the case of methacrylate contact from nail polish gel 4H (ethylene vinyl/alcohol polyethylene) finger covers can be used under regular gloves when the use of 4H gloves is not preferred [11,28,40,48]. Applying basic preventive measures consistently ultimately helps patients avoid having to change professions due to an allergy [9]. It should not be overlooked that adequate personal protection among students is also essential [10]. In recent years, the number of dental staff allergic to MAs has somewhat decreased due to the increased awareness that acrylates can cause sensitization [11,75].

Looking at the prevention of reactions to acrylates in cosmetics, many irritating reactions of the mucous membranes and skin of beauticians could be prevented with proper ventilation and PPE use [11,55]. Also, the quality of devices, such as UV devices, and following appropriate curing times for nail gel, which is higher when applied at home by untrained individuals, reduce the risk of sensitization to acrylates. [11,31].

Career counseling for a person with an adverse reaction to acrylates, including a potential allergy to acrylates, is also an important issue. Allergy to acrylates can significantly influence a person's ability to work in a particular job or profession [28]. The literature includes the case of a manicurist who, after only three months of work, had an allergic reaction to acrylates. Without understanding that acrylates are also present in dentistry, she became a dental nurse [11]. Shortly thereafter, her skin manifestations recurred due to exposure to 2-HEMA, 2-HPMA, EGDMA, and other acrylates. Thus, she had to change jobs again. Education about re-exposure risks in other industries could prevent reoccurrence and professional hardships [11,76].

Considering this problem, there are various other measures to consider. To improve the quality of acrylates, several techniques and approaches can be employed. Adjusting the conditions under which polymerization occurs, for example, can significantly impact the quality of acrylates. Factors such as temperature, pressure, and the presence of initiators or catalysts can also be optimized [77]. Incorporating cross-linking agents can improve the mechanical properties and stability of acrylates. In other words, cross-linking enhances the structural integrity of the polymer network [78]. Also, stabilizers, such as UV absorbers and antioxidants, can protect acrylates from degradation due to environmental factors [79]. Another possible solution could be altering monomer composition, such as by copolymerizing with other monomers, which tailors the properties of acrylates to specific requirements [80]. Additionally, removing impurities from monomers and polymers can improve the clarity and performance of acrylates [81]. Incorporating nanoparticles into acrylates can enhance their mechanical properties, thermal stability, and other characteristics [82]. Managing molecular weight and its distribution during polymerization can also affect the physical properties of the final product. Techniques such as controlled radical polymerization could also be used [83].

It is important to note that the tolerance exposure limit for acrylates can vary depending on the specific type of acrylate and the regulatory guidelines of different countries. Generally, exposure limits are set to ensure that workers and the general population are not adversely affected by the chemical. Many countries have established occupational exposure limits (OELs) for acrylates. These limits are often expressed as time-weighted averages (TWA) over an 8 h workday. For example, the OEL for methyl methacrylate is set at 50 ppm (parts per million) by OSHA in the United States [84]. Some acrylates also have short-term exposure limits (STELs), where higher concentrations are permitted for short periods (usually 15 min). For instance, the STEL for ethyl acrylate is 25 ppm [85]. Studies on the toxicity of acrylates indicate that prolonged exposure can cause respiratory and skin sensitization. Methyl methacrylate, for example, has been shown to cause respiratory irritation and ACD [86]. Regulatory agencies like the Environmental Protection Agency

(EPA) and European Chemicals Agency (ECHA) provide guidelines on safe handling and exposure limits. For instance, the EPA has set a reference concentration (RfC) for methyl methacrylate at 1 mg/m³ based on respiratory effects [87]. Continuous monitoring of acrylate levels in workplaces is crucial. Techniques such as gas chromatography can be used to ensure that the concentrations remain below the set limits [88].

Alternatives with similar properties to acrylates are sought after in various industries due to concerns about acrylate toxicity, environmental impact, and specific application requirements. Epoxy resins, for example, are known for their excellent adhesion, chemical resistance, and mechanical properties. They are widely used in coatings, adhesives, and composite materials [89]. Polyurethanes offer versatility in terms of flexibility, durability, and resistance to abrasion and chemicals. They are used in coatings, foams, and elastomers [90]. Silicone polymers exhibit excellent thermal stability, flexibility, and biocompatibility. They are often used in medical devices, sealants, and coatings [91]. Vinyl ester resins provide good chemical resistance and mechanical properties, similar to acrylates. They are commonly used in corrosion-resistant coatings and composite materials [92]. Polystyrene and styrene acrylic copolymers can be tailored to achieve similar properties to acrylates, such as clarity, hardness, and chemical resistance. They are used in various applications, including coatings and adhesives [93]. Lastly, polyester resins are known for their durability, chemical resistance, and ease of processing. They are used in coatings, adhesives, and composite materials [94].

In addition, additives can significantly impact the properties of acrylates and potentially reduce unwanted skin irritations. Adding photoinitiators that allow for more complete curing of acrylate resins can reduce the presence of residual monomers, which are often responsible for skin irritation. When properly selected and balanced, photoinitiators ensure better polymerization [95]. Also, inhibitors and stabilizers can be added to acrylate formulations to reduce the likelihood of premature polymerization during storage and handling, which in turn reduces the risk of exposure to reactive monomers that can cause irritation [96]. The method of incorporating plasticizers can make acrylate materials more flexible and less prone to cracking, reducing the risk of skin irritation from rough or brittle surfaces [97]. Antioxidants can be added to acrylate formulations to prevent oxidation and degradation of the polymer, which can produce irritant by-products [98]. Another possible measure could be adding biocompatible modifiers, such as polyethylene glycol (PEG), which improve the biocompatibility of acrylates and make them less likely to cause skin irritation [99]. Also, formulations designed with lower monomer content or using high-purity monomers can reduce the likelihood of skin sensitization and irritation [100].

Therefore, for the successful retraining of people allergic to acrylates, it is crucial to consider the various industries where acrylates are present and how to work with modified materials and products [11,28,40,48,101,102]. Clinicians should be appropriately educated and trained to provide suitable patient care. For example, if a medical procedure is planned, patients allergic to acrylates require cementless arthroplasty and dental materials that do not release acrylates.

8. Ways to Deal with the Unwanted Effects of Acrylate Reactions and Treatment

After confirmation of an acrylate allergy, further contact with acrylates must be avoided. However, when dermatitis (eczema) does appear, it is necessary to treat the lesions adequately. Treatment primarily includes topical corticosteroid preparations and emollients, while, in resistant cases, immune-modulating calcineurin inhibitors (tacrolimus and pimecrolimus preparations) may be helpful. In severe cases, oral steroids may be used but only for a short time. Sometimes, secondary infections may appear and topical or oral antibiotics may be used. Other therapy options include phototherapy or immunosuppressive drugs [103].

9. Conclusions

Acrylates have become integral to numerous industries from their initial applications to their widespread use in various medical and cosmetic products. While their usage offers numerous advantages, the risk of adverse reactions, particularly ACD, should not be overlooked. This review highlights that allergic responses to acrylates, especially ACD, pose a significant health problem across various professions. In the dental industry, acrylates are prevalent in dental prostheses, composite resins, dentin bonding materials, and glass ionomers. Dental personnel are particularly at risk, with common manifestations including facial rashes, eczema with cracked skin on fingers, nail dystrophy, and periungual dermatitis. The beauty industry has also seen a rise in allergic reactions due to the increased use of acrylates in artificial nails, eyelashes, and hair extensions. Additionally, acrylates are used in medical applications such as bone cement for orthopedic endoprostheses, soft contact lenses, hearing aids, histological preparations, and wound dressings, which can also cause allergic reactions. Clinically, ACD due to acrylates presents as skin lesions, often on the face and hands, and can lead to significant morbidity. Diagnosis is primarily confirmed through patch testing, which remains the gold standard for identifying specific acrylate allergens. The frequent cross-reactivity among different acrylates necessitates comprehensive testing and preventive measures to avoid exposure. Preventive strategies are essential to mitigate the risk of ACD among individuals exposed to acrylates. These strategies include the use of appropriate PPE, such as nitrile gloves and protective eyewear, and modifications to work practices to minimize skin contact with uncured acrylates. Increased awareness and education about the risks associated with acrylate exposure are crucial for both professionals and consumers. Given the growing prevalence of acrylate allergies in both occupational and non-occupational settings, there is a pressing need for manufacturers to develop safer alternatives and improve the formulation of products to reduce sensitization risks. Future research should focus on identifying less allergenic substitutes for acrylates and further elucidating the mechanisms of sensitization to enhance prevention and treatment strategies. In sum, while acrylates provide significant benefits across various industries, the potential for adverse skin reactions necessitates vigilant preventive measures, thorough diagnosis, and continued research to safeguard the health of users and professionals alike.

Author Contributions: Conceptualization, L.L.-M.; methodology, L.L.-M.; software, E.F., V.V. and L.P.; validation, L.L.-M., E.P. and B.Š.; formal analysis, L.L.-M., E.P. and B.Š.; investigation, L.L.-M., E.F., V.V., L.P., E.P. and B.Š.; resources, L.L.-M.; data curation, R.T. and E.B.; writing—original draft preparation, L.L.-M., E.F., V.V. and L.P.; writing—review and editing, L.L.-M., E.P., R.T., V.V. and B.Š.; visualization, L.L.-M.; supervision, L.L.-M.; project administration, E.P., R.T., V.V. and B.Š. All authors have read and agreed to the published version of the manuscript.

Funding: This research received no external funding.

Institutional Review Board Statement: Not applicable.

Informed Consent Statement: Informed consent was obtained from all subjects involved in the study.

Data Availability Statement: Not applicable.

Conflicts of Interest: The authors declare no conflicts of interest.

References

1. de Groot, A.C.; Rustemeyer, T. 2-Hydroxyethyl methacrylate (HEMA): A clinical review of contact allergy and allergic contact dermatitis. Part 2. Cross- and co-sensitization, other skin reactions to HEMA, position of HEMA among (meth)acrylates, sensitivity as screening agent, presence of HEMA in commercial products and practical information on patch test procedures. *Contact Dermat.* **2024**, *90*, 1–16.
2. Havmose, M.; Thyssen, J.P.; Zachariae, C.; Johansen, J.D. Contact allergy to 2-hydroxyethyl methacrylate in Denmark. *Contact Dermat.* **2020**, *82*, 229–231. [[CrossRef](#)] [[PubMed](#)]
3. Opalińska, S.; Opalińska, M.; Rudnicka, L.; Czuwara, J. Contact eczema induced by hybrid manicure. The role of acrylates as a causative factor. *Postepy Dermatol. Alergol.* **2022**, *39*, 768–774. [[CrossRef](#)]

4. Isaksson, M.; Zimerson, E.; Svedman, C. Occupational airborne allergic contact dermatitis from methacrylates in a dental nurse. *Contact Dermat.* **2007**, *57*, 371–375. [[CrossRef](#)] [[PubMed](#)]
5. Ramos, L.; Cabral, R.; Gonalo, M. Allergic contact dermatitis caused by acrylates and methacrylates—A 7-year study. *Contact Dermat.* **2014**, *71*, 102–107. [[CrossRef](#)] [[PubMed](#)]
6. Gregoriou, S.; Tagka, A.; Velissariou, E.; Tsimpidakis, A.; Hatzidimitriou, E.; Platsidaki, E.; Kedikoglou, S.; Chatziioannou, A.; Katsarou, A.; Nicolaidou, E.; et al. The rising incidence of allergic contact dermatitis to acrylates. *Dermatitis* **2020**, *31*, 140–143. [[CrossRef](#)] [[PubMed](#)]
7. Geukens, S.; Goossens, A. Occupational contact allergy to (meth)acrylates. *Contact Dermat.* **2001**, *44*, 153–159. [[CrossRef](#)] [[PubMed](#)]
8. Sasseville, D. Acrylates in contact dermatitis. *Dermatitis* **2012**, *23*, 6–16. [[CrossRef](#)] [[PubMed](#)]
9. Cameli, N.; Silvestri, M.; Mariano, M.; Messina, C.; Nisticò, S.P.; Cristaudo, A. Allergic contact dermatitis, an important skin reaction in diabetes device users: A systematic review. *Dermatitis* **2022**, *33*, 110–115. [[CrossRef](#)]
10. Lyapina, M.; Dencheva, M.; Krasteva, A.; Tzekova, M.; Kisselova-Yaneva, A. Concomitant contact allergy to formaldehyde and methacrylic monomers in students of dental medicine and dental patients. *Int. J. Occup. Med. Environ. Health* **2014**, *27*, 797–807. [[CrossRef](#)]
11. Kucharczyk, M.; Słowik-Rylska, M.; Cyran-Stemplewska, S.; Gieroń, M.; Nowak-Starz, G.; Kręcis, B. Acrylates as a significant cause of allergic contact dermatitis: New sources of exposure. *Postepy Dermatol. Alergol.* **2021**, *38*, 555–560. [[CrossRef](#)] [[PubMed](#)]
12. Spencer, A.; Gazzani, P.; Thompson, D.A. Acrylate and methacrylate contact allergy and allergic contact disease: A 13-year review. *Contact Dermat.* **2016**, *75*, 157–164. [[CrossRef](#)] [[PubMed](#)]
13. Wrangsjö, K.; Swartling, C.; Meding, B. Occupational dermatitis in dental personnel: Contact dermatitis with special reference to (meth)acrylates in 174 patients. *Contact Dermat.* **2001**, *45*, 158–163. [[CrossRef](#)] [[PubMed](#)]
14. Goon, A.T.; Isaksson, M.; Zimerson, E.; Goh, C.L.; Bruze, M. Contact allergy to (meth)acrylates in the dental series in southern Sweden: Simultaneous positive patch test reaction patterns and possible screening allergens. *Contact Dermat.* **2006**, *55*, 219–226. [[CrossRef](#)]
15. Fugolin, A.P.; Dobson, A.; Mbiya, W.; Navarro, O.; Ferracane, J.L.; Pfeifer, C.S. Use of (meth)acrylamides as alternative monomers in dental adhesive systems. *Dent. Mater.* **2019**, *35*, 686–696. [[CrossRef](#)] [[PubMed](#)]
16. Rolls, S.; Rajan, S.; Shah, A.; Bourke, J.; Chowdhury, M.; Ghaffar, S.; Green, C.; Johnston, G.; Orton, D.; Reckling, C.; et al. (Meth)acrylate allergy: Frequently missed? *Br. J. Dermatol.* **2018**, *178*, 980–981. [[CrossRef](#)] [[PubMed](#)]
17. Japundžić-Rapić, I.; Macan, J.; Babić, Ž.; Vodanović, M.; Salarić, I.; Prpić-Mehićić, G.; Gabrić, D.; Pondelj, N.; Lugović-Mihčić, L. Work-related and personal predictors of hand eczema in physicians and dentists: Results from a field study. *Dermatitis* **2024**, *35*, 101–105. [[CrossRef](#)] [[PubMed](#)]
18. Piirilä, P.; Kanerva, L.; Keskinen, H.; Estlander, T.; Hytönen, M.; Tuppurainen, M.; Nordman, H. Occupational respiratory hypersensitivity caused by preparations containing acrylates in dental personnel. *Clin. Exp. Allergy* **1998**, *28*, 1404–1411. [[CrossRef](#)] [[PubMed](#)]
19. Muttardi, K.; White, I.R.; Banerjee, P. The burden of allergic contact dermatitis caused by acrylates. *Contact Dermat.* **2016**, *75*, 180–184. [[CrossRef](#)]
20. Uter, W.; Geier, J. Contact allergy to acrylates and methacrylates in consumers and nail artists—Data of the Information Network of Departments of Dermatology, 2004–2013. *Contact Dermat.* **2015**, *72*, 224–228. [[CrossRef](#)]
21. Raposo, I.; Lobo, I.; Amaro, C.; Lobo, M.L.; Melo, H.; Parente, J.; Pereira, T.; Rocha, J.; Cunha, A.P.; Baptista, A.; et al. Allergic contact dermatitis caused by (meth)acrylates in nail cosmetic products in users and nail technicians—A 5-year study. *Contact Dermat.* **2017**, *77*, 356–359. [[CrossRef](#)] [[PubMed](#)]
22. Dudek, W.; Wittczak, T.; Swierczyńska-Machura, D.; Kręcis, B.; Nowakowska-Świrta, E.; Kieć-Świerczyńska, M.; Pałczyński, C. Allergic blepharoconjunctivitis caused by acrylates promotes allergic rhinitis response. *Ann. Allergy Asthma Immunol.* **2014**, *113*, 492–494. [[CrossRef](#)]
23. Kanerva, L.; Alanko, K.; Estlander, T.; Jolanki, R.; Lahtinen, A.; Savela, A. Statistics on occupational contact dermatitis from (meth)acrylates in dental personnel. *Contact Dermat.* **2000**, *42*, 175–176.
24. Heratizadeh, A.; Werfel, T.; Schubert, S.; Geier, J.; IVDK. Contact sensitization in dental technicians with occupational contact dermatitis. Data of the Information Network of Departments of Dermatology (IVDK) 2001–2015. *Contact Dermat.* **2018**, *78*, 266–273. [[CrossRef](#)]
25. Splete, H. Dermatologists Name Isobornyl Acrylate Contact Allergen of the Year. AT ACDS. 2019. Available online: <https://www.mdedge.com/dermatology/article/195656/contact-dermatitis/dermatologists-name-isobornyl-acrylate-contact> (accessed on 6 June 2024).
26. Lin, Y.; Tsai, S.; Yang, C.; Tseng, Y.; Chu, C. Allergic contact dermatitis caused by acrylates in nail cosmetic products: Case reports and review of the literature. *Dermatol. Sin.* **2018**, *36*, 218–221. [[CrossRef](#)]
27. Gatica-Ortega, M.E.; Pastor-Nieto, M.A.; Mercader-García, P.; Silvestre-Salvador, J. Allergic contact dermatitis caused by (meth)acrylates in long-lasting nail polish—Are we facing a new epidemic in the beauty industry? *Contact Dermat.* **2017**, *77*, 360–366. [[CrossRef](#)] [[PubMed](#)]
28. Gonalo, M.; Pinho, A.; Agner, T.; Andersen, K.E.; Bruze, M.; Diepgen, T.; Foti, C.; Giménez-Arnau, A.; Goossens, A.; Johanssen, J.D.; et al. Allergic contact dermatitis caused by nail acrylates in Europe. An EECDRG study. *Contact Dermat.* **2018**, *78*, 254–260. [[CrossRef](#)] [[PubMed](#)]

29. Canizares, O. Contact dermatitis due to the acrylic materials used in artificial nails. *AMA Arch. Derm.* **1956**, *74*, 141–143. [[CrossRef](#)]
30. Gonçalves, M. Nail acrylate allergy: The beauty, the beast and beyond. *Br. J. Dermatol.* **2019**, *181*, 663–664. [[CrossRef](#)]
31. Gatica-Ortega, M.E.; Pastor-Nieto, M.A.; Gil-Redondo, R.; Martínez-Lorenzo, E.R.; Schöendorff-Ortega, C. Non-occupational allergic contact dermatitis caused by long-lasting nail polish kits for home use: ‘the tip of the iceberg’. *Contact Dermat.* **2018**, *78*, 261–265. [[CrossRef](#)]
32. Ródenas-Herranz, T.; Navarro-Triviño, F.J.; Linares-González, L.; Ruiz-Villaverde, R.; Brufau-Redondo, C.; Mercader-García, P. Acrylate allergic contact dermatitis caused by hair prosthesis fixative. *Contact Dermat.* **2020**, *82*, 62–64. [[CrossRef](#)] [[PubMed](#)]
33. Hyry, H.S.I.; Liippo, J.P.; Virtanen, H.M. Allergic contact dermatitis caused by glucose sensors in type 1 diabetes patients. *Contact Dermat.* **2019**, *81*, 161–166. [[CrossRef](#)] [[PubMed](#)]
34. Herman, A.; de Montjoye, L.; Tromme, I.; Goossens, A.; Baeck, M. Allergic contact dermatitis caused by medical devices for diabetes patients: A review. *Contact Dermat.* **2018**, *79*, 331–335. [[CrossRef](#)] [[PubMed](#)]
35. Raison-Peyron, N.; Mowitz, M.; Bonardel, N.; Aerts, O.; Bruze, M. Allergic contact dermatitis caused by isobornyl acrylate in OmniPod, an innovative tubeless insulin pump. *Contact Dermat.* **2018**, *79*, 76–80. [[CrossRef](#)]
36. Mowitz, M.; Herman, A.; Baeck, M.; Isaksson, M.; Antelmi, A.; Hammerius, N.; Pontén, A.; Bruze, M. N,N-dimethylacrylamide—A new sensitizer in the FreeStyle Libre glucose sensor. *Contact Dermat.* **2019**, *81*, 27–31. [[CrossRef](#)]
37. Oppel, E.; Kamann, S. Hydrocolloid blister plaster decreases allergic contact dermatitis caused by Freestyle Libre and isobornyl acrylate. *Contact Dermat.* **2019**, *81*, 380–381.
38. Dittmar, D.; Dahlin, J.; Persson, C.; Schuttelaar, M.L. Allergic contact dermatitis caused by acrylic acid used in transcutaneous electrical nervous stimulation. *Contact Dermat.* **2017**, *77*, 409–412. [[CrossRef](#)]
39. Foti, C.; Lopalco, A.; Stingeni, L.; Hansel, K.; Lopodota, A.; Denora, N.; Romita, P. Contact allergy to electrocardiogram electrodes caused by acrylic acid without sensitivity to methacrylates and ethyl cyanoacrylate. *Contact Dermat.* **2018**, *79*, 118–121. [[CrossRef](#)]
40. Shah, V.; Chaubal, T.V.; Bapat, R.A.; Shetty, D. Allergic contact dermatitis caused by polymethylmethacrylate following intradermal filler injection. *Contact Dermat.* **2017**, *77*, 407–408. [[CrossRef](#)]
41. Marrero-Alemán, G.; Sabater-Abad, J.; Miquel, F.J.; Boix-Vilanova, J.; Mestre Bauzá, F.; Borrego, L. Allergic contact dermatitis to (meth)acrylates involving nail technicians and users: Prognosis and differential diagnosis. *Allergy* **2019**, *74*, 1386–1389. [[CrossRef](#)]
42. Parać, E.; Špiljak, B.; Lugović-Mihić, L.; Bukvić Mokos, Z. Acne-like eruptions: Disease features and differential diagnosis. *Cosmetics* **2023**, *10*, 89. [[CrossRef](#)]
43. Walters, G.I.; Robertson, A.S.; Moore, V.C.; Burge, P.S. Occupational asthma caused by acrylic compounds from SHIELD surveillance (1989–2014). *Occup. Med.* **2017**, *67*, 282–289. [[CrossRef](#)] [[PubMed](#)]
44. Aalto-Korte, K.; Alanko, K.; Kuuliala, O.; Jolanki, R. Methacrylate and acrylate allergy in dental personnel. *Contact Dermat.* **2007**, *57*, 324–330. [[CrossRef](#)] [[PubMed](#)]
45. Rustemeyer, T.; Frosch, P.J. Occupational contact dermatitis in dental personnel. In *Kanerva’s Occupational Dermatology*; John, S., Johansen, J., Rustemeyer, T., Elsner, P., Maibach, H., Eds.; Springer: Berlin/Heidelberg, Germany, 2019; pp. 1–12. ISBN 978-3-319-40221-5.
46. Lugović-Mihić, L.; Ferček, I.; Duvančić, T.; Bulat, V.; Ježovita, J.; Novak-Bilić, G.; Šitum, M. Occupational contact dermatitis amongst dentists and dental technicians. *Acta Clin. Croat.* **2016**, *55*, 293–300. [[CrossRef](#)]
47. Japundžić, I.; Bembić, M.; Špiljak, B.; Parać, E.; Macan, J.; Lugović-Mihić, L. Work-related hand eczema in healthcare workers: Etiopathogenic factors, clinical features, and skin care. *Cosmetics* **2023**, *10*, 134. [[CrossRef](#)]
48. Alamri, A.; Lill, D.; Summer, B.; Thomas, P.; Thomas, B.; Oppel, E. Artificial nail wearing: Unexpected elicitor of allergic contact dermatitis, oral lichen planus and risky arthroplasty. *Contact Dermat.* **2019**, *81*, 210–211. [[CrossRef](#)]
49. Lazarov, A. Sensitization to acrylates is a common adverse reaction to artificial fingernails. *J. Eur. Acad. Dermatol. Venereol.* **2007**, *21*, 169–174. [[CrossRef](#)] [[PubMed](#)]
50. Watanabe, Y.; Okada, K.; Kondo, M.; Matsushita, T.; Nakazawa, S.; Yamazaki, Y. Oral health for achieving longevity. *Geriatr. Gerontol. Int.* **2020**, *20*, 526–538. [[CrossRef](#)] [[PubMed](#)]
51. Savage, N.W.; Boras, V.V.; Barker, K. Burning mouth syndrome: Clinical presentation, diagnosis and treatment. *Aust. J. Dermatol.* **2006**, *47*, 77–83. [[CrossRef](#)]
52. Lugović-Mihić, L.; Špiljak, B.; Blagec, T.; Delaš Aždajić, M.; Franceschi, N.; Gašić, A.; Parać, E. Factors participating in the occurrence of inflammation of the lips (cheilitis) and perioral skin. *Cosmetics* **2023**, *10*, 9. [[CrossRef](#)]
53. Symanzik, C.; Weinert, P.; Babić, Ž.; Hallmann, S.; Havmose, M.S.; Johansen, J.D.; Kezic, S.; Macan, M.; Macan, J.; Strahwald, J.; et al. Allergic contact dermatitis caused by 2-hydroxyethyl methacrylate and ethyl cyanoacrylate contained in cosmetic glues among hairdressers and beauticians who perform nail treatments and eyelash extension as well as hair extension applications: A systematic review. *Contact Dermat.* **2022**, *86*, 480–492.
54. Mattos Simoes Mendonca, M.; LaSenna, C.; Tosti, A. Severe onychodystrophy due to allergic contact dermatitis from acrylic nails. *Ski. Appendage Disord.* **2015**, *1*, 91–94. [[CrossRef](#)]
55. Kieć-Świerczyńska, M.; Świerczyńska-Machura, D.; Chomiczewska-Skóra, D.; Kręcisz, B.; Walusiak-Skorupa, J. Screening survey of ocular, nasal, respiratory and skin symptoms in manicurists in Poland. *Int. J. Occup. Med. Environ. Health* **2017**, *30*, 887–896. [[CrossRef](#)]
56. Pesonen, M.; Kuuliala, O.; Henriks-Eckerman, M.L.; Aalto-Korte, K. Occupational allergic contact dermatitis caused by eyelash extension glues. *Contact Dermat.* **2012**, *67*, 307–308. [[CrossRef](#)] [[PubMed](#)]

57. Japundžić, I. The Impact of Working Conditions and Constitutional Factors on the Onset of Contact Dermatitis of the Hands in Dental Medicine Doctors and Medical Doctors. Ph.D. Thesis, School of Dental Medicine, University of Zagreb, Zagreb, Croatia, 2020. Available online: <https://repozitorij.sfzg.unizg.hr/islandora/object/sfzg:708> (accessed on 12 June 2024).
58. Drucker, A.M.; Pratt, M.D. Acrylate contact allergy: Patient characteristics and evaluation of screening allergens. *Dermatitis* **2011**, *22*, 98–101. [[CrossRef](#)]
59. Minciullo, P.L.; Paolino, G.; Vacca, M.; Gangemi, S.; Nettis, E. Unmet diagnostic needs in contact oral mucosal allergies. *Clin. Mol. Allergy* **2016**, *14*, 10. [[CrossRef](#)] [[PubMed](#)]
60. Aalto-Korte, K.; Henriks-Eckerman, M.L.; Kuuliala, O.; Jolanki, R. Occupational methacrylate and acrylate allergy—Cross-reactions and possible screening allergens. *Contact Dermat.* **2010**, *63*, 301–312. [[CrossRef](#)] [[PubMed](#)]
61. Tillberg, A.; Stenberg, B.; Berglund, A. Reactions to resin-based dental materials in patients—type, time to onset, duration, and consequence of the reaction. *Contact Dermat.* **2009**, *61*, 313–319. [[CrossRef](#)]
62. Prasad Hunasehally, R.Y.; Hughes, T.M.; Stone, N.M. Atypical pattern of (meth)acrylate allergic contact dermatitis in dental professionals. *Br. Dent. J.* **2012**, *213*, 223–224. [[CrossRef](#)]
63. Kieć-Świerczyńska, M.K. Occupational allergic contact dermatitis due to acrylates in Lodz. *Contact Dermat.* **1996**, *34*, 419–422. [[CrossRef](#)]
64. Kanerva, L.; Estlander, T.; Jolanki, R.; Tarvainen, K. Occupational allergic contact dermatitis caused by exposure to acrylates during work with dental prostheses. *Contact Dermat.* **1993**, *28*, 268–275. [[CrossRef](#)] [[PubMed](#)]
65. Budimir, J.; Mravak-Stipetić, M.; Bulat, V.; Ferček, I.; Japundžić, I.; Lugović-Mihić, L. Allergic reactions in oral and perioral diseases—what do allergy skin test results show? *Oral Surg. Oral Med. Oral Pathol. Oral Radiol.* **2019**, *127*, 40–48. [[CrossRef](#)]
66. Syed, M.; Chopra, R.; Sachdev, V. Allergic Reactions to Dental Materials—A Systematic Review. *J. Clin. Diagn. Res.* **2015**, *9*, ZE04–ZE09. [[CrossRef](#)] [[PubMed](#)]
67. Kostić, M.; Igić, M.; Gligorijević, N.; Nikolić, V.; Stošić, N.; Nikolić, L. The Use of Acrylate Polymers in Dentistry. *Polymers* **2022**, *14*, 4511. [[CrossRef](#)]
68. Even, M.; Roloff, A.; Lüttger, N.; Beauchamp, J.; Stalter, D.; Schulte, A.; Hutzler, C.; Luch, A. Exposure Assessment of Toxicologically Relevant Volatile Organic Compounds Emitted from Polymer-Based Costume Masks. *Chem. Res. Toxicol.* **2021**, *34*, 132–143. [[CrossRef](#)] [[PubMed](#)]
69. Akbari, N.; Salehiniya, H.; Abedi, F.; Abbaszadeh, H. Comparison of the Use of Personal Protective Equipment and Infection Control in Dentists and Their Assistants Before and After the Corona Crisis. *J. Educ. Health Promot.* **2021**, *10*, 206. [[PubMed](#)]
70. Petric Vicković, I.; Šimunović, L.; Vodanović, M.; Špiljak, B.; Patekar, L.; Ovčarić, B.; Mendeš, A.; Krolo, I. Prolonged Face Mask Wearing Worsens Self-Reported Dry Eye Symptoms during the COVID-19 Pandemic in Dental Healthcare Practitioners. *Acta Stomatol. Croat.* **2023**, *57*, 133–144. [[CrossRef](#)] [[PubMed](#)]
71. Plaza-Ruiz, S.P.; Barbosa-Liz, D.M.; Agudelo-Suárez, A.A. Ventilation and Air-Conditioning Systems in Dental Clinics and COVID-19: How Much Do We Know? *J. Clin. Exp. Dent.* **2021**, *13*, e692–e700. [[CrossRef](#)] [[PubMed](#)]
72. Jadhav, S.S.; Mahajan, N.; Sethuraman, R. Comparative Evaluation of the Amount of the Residual Monomer in Conventional and Deep-Frozen Heat Cure Polymethylmethacrylate Acrylic Resin: An In Vitro Study. *J. Indian Prosthodont. Soc.* **2018**, *18*, 147–153.
73. Thomas, S.; Padmanabhan, T.V. Methyl methacrylate permeability of dental and industrial gloves. *N. Y. State Dent. J.* **2009**, *75*, 40–42.
74. Morgado, F.; Batista, M.; Gonçalo, M. Short exposures and glove protection against (meth)acrylates in nail beauticians—Thoughts on a rising concern. *Contact Dermat.* **2019**, *81*, 62–63. [[CrossRef](#)] [[PubMed](#)]
75. Aalto-Korte, K.; Pesonen, M. The additive value of patch testing non-commercial test substances and patients' own products in a clinic of occupational dermatology. *Contact Dermat.* **2023**, *88*, 27–34. [[CrossRef](#)] [[PubMed](#)]
76. Kieć-Świerczyńska, M.; Krecisz, B.; Chomiczewska-Skóra, D. Occupational contact dermatitis to acrylates in a manicurist. *Occup. Med.* **2013**, *63*, 380–382. [[CrossRef](#)] [[PubMed](#)]
77. Pirman, T.; Oceppek, M.; Likozar, B. Radical Polymerization of Acrylates, Methacrylates, and Styrene: Biobased Approaches, Mechanism, Kinetics, Secondary Reactions, and Modeling. *Ind. Eng. Chem. Res.* **2021**, *60*, 9347–9367. [[CrossRef](#)]
78. Ceylan, G.; Emik, S.; Yalcinyuva, T.; Sunbuloglu, E.; Bozdog, E.; Unalan, F. The Effects of Cross-Linking Agents on the Mechanical Properties of Poly (Methyl Methacrylate) Resin. *Polymers* **2023**, *15*, 2387. [[CrossRef](#)] [[PubMed](#)]
79. Andraday, A.L.; Heikkilä, A.M.; Pandey, K.K.; Bruckman, L.S.; White, C.C.; Zhu, M.; Zhu, L. Effects of UV Radiation on Natural and Synthetic Materials. *Photochem. Photobiol. Sci.* **2023**, *22*, 1177–1202. [[CrossRef](#)] [[PubMed](#)]
80. Rusli, W.; Tan, S.W.B.; Parthiban, A.; van Herk, A.M. Free Radical Solution Copolymerization of Monomers of Dissimilar Reactivity—Influencing Chemical Composition Distribution and Properties of Copolymers of Methyl Methacrylate and N-Vinyl Imidazole by Varying Monomer Feeding Profiles. *Polymer* **2022**, *247*, 124774. [[CrossRef](#)]
81. Brocken, L.; Whittaker, J.; Price, P.; Baxendale, I.R. Purification of Poly(acrylic acid) Using a Membrane Ultra-filtration Unit in Flow. *React. Chem. Eng.* **2017**, *2*, 656–661. [[CrossRef](#)]
82. Pourhajbagher, M.; Bahador, A. Effects of Incorporation of Nanoparticles into Dental Acrylic Resins on Antimicrobial and Physico-mechanical Properties: A Meta-Analysis of In Vitro Studies. *J. Oral Biol. Craniofac. Res.* **2022**, *12*, 557–568. [[CrossRef](#)]
83. Parkatzidis, K.; Wang, H.S.; Truong, N.P.; Anastasaki, A. Recent Developments and Future Challenges in Controlled Radical Polymerization: A 2020 Update. *Chem* **2020**, *6*, 1575–1588. [[CrossRef](#)]

84. Occupational Safety and Health Administration (OSHA). Occupational Exposure Limits for Chemical Substances. OSHA 2021. Available online: <https://www.osha.gov/chemicaldata/> (accessed on 5 July 2024).
85. American Conference of Governmental Industrial Hygienists (ACGIH). Threshold Limit Values for Chemical Substances and Physical Agents. ACGIH 2020. Available online: <https://www.acgih.org/tlv-bei-guidelines/> (accessed on 5 July 2024).
86. Meek, B.; Bridges, J.W.; Fasey, A.; Sauer, U.G. Evidential Requirements for the Regulatory Hazard and Risk Assessment of Respiratory Sensitisers: Methyl Methacrylate as an Example. *Arch. Toxicol.* **2023**, *97*, 931–946. [[CrossRef](#)]
87. Environmental Protection Agency (EPA). Integrated Risk Information System (IRIS) on Methyl Methacrylate. EPA 2017. Available online: <https://www.epa.gov/iris> (accessed on 5 July 2024).
88. Almeida, C.M.M. Overview of Sample Preparation and Chromatographic Methods to Analysis Pharmaceutical Active Compounds in Waters Matrices. *Separations* **2021**, *8*, 16. [[CrossRef](#)]
89. Kumar, S.; Samal, S.K.; Mohanty, S.; Nayak, S.K. Recent Development of Biobased Epoxy Resins: A Review. *Polym.-Plast. Technol. Eng.* **2017**, *57*, 133–155. [[CrossRef](#)]
90. Das, A.; Mahanwar, P. A Brief Discussion on Advances in Polyurethane Applications. *Adv. Ind. Eng. Polym. Res.* **2020**, *3*, 93–101. [[CrossRef](#)]
91. Zare, M.; Ghomi, E.R.; Venkatraman, P.D.; Ramakrishna, S. Silicone-Based Biomaterials for Biomedical Applications: Antimicrobial Strategies and 3D Printing Technologies. *J. Appl. Polym. Sci.* **2021**, *138*, 50969. [[CrossRef](#)]
92. Motlatle, A.M.; Ray, S.S.; Ojijo, V.; Scriba, M.R. Polyester-Based Coatings for Corrosion Protection. *Polymers* **2022**, *14*, 3413. [[CrossRef](#)]
93. Melo, L.; Benavides, R.; Martínez, G.; Morales-Acosta, D.; Paula, M.M.S.; Da Silva, L. Mechanical Properties and Morphology of Polystyrene-co-Acrylic Acid Synthesized as Membranes for Fuel Cells. *Int. J. Hydrogen Energy* **2017**, *42*, 21880–21885. [[CrossRef](#)]
94. Wang, L.; Kelly, P.V.; Ozveren, N.; Zhang, X.; Korey, M.; Chen, C.; Li, K.; Bhandari, S.; Tekinalp, H.; Zhao, X.; et al. Multifunctional Polymer Composite Coatings and Adhesives by Incorporating Cellulose Nanomaterials. *Matter* **2023**, *6*, 344–372. [[CrossRef](#)]
95. Stiles, A.; Tison, T.-A.; Pruitt, L.; Vaidya, U. Photoinitiator Selection and Concentration in Photopolymer Formulations towards Large-Format Additive Manufacturing. *Polymers* **2022**, *14*, 2708. [[CrossRef](#)]
96. Maafa, I.M. Inhibition of Free Radical Polymerization: A Review. *Polymers* **2023**, *15*, 488. [[CrossRef](#)]
97. Eslami, Z.; Elkoun, S.; Robert, M.; Adjallé, K. A Review of the Effect of Plasticizers on the Physical and Mechanical Properties of Alginate-Based Films. *Molecules* **2023**, *28*, 6637. [[CrossRef](#)] [[PubMed](#)]
98. Almeida, S.; Ozkan, S.; Gonçalves, D.; Paulo, I.; Queirós, C.S.G.P.; Ferreira, O.; Bordado, J.; Galhano dos Santos, R. A Brief Evaluation of Antioxidants, Antistatics, and Plasticizers Additives from Natural Sources for Polymers Formulation. *Polymers* **2023**, *15*, 6. [[CrossRef](#)]
99. Shi, D.; Beasock, D.; Fessler, A.; Szebeni, J.; Ljubimova, J.Y.; Afonin, K.A.; Dobrovolskaia, M.A. To PEGylate or Not to PEGylate: Immunological Properties of Nanomedicine’s Most Popular Component, Polyethylene Glycol and Its Alternatives. *Adv. Drug Deliv. Rev.* **2022**, *180*, 114079. [[CrossRef](#)] [[PubMed](#)]
100. Bialas, I.; Zelent-Kraciuk, S.; Jurowski, K. The Skin Sensitisation of Cosmetic Ingredients: Review of Actual Regulatory Status. *Toxics* **2023**, *11*, 392. [[CrossRef](#)] [[PubMed](#)]
101. Luo, S.; Liu, F.; He, J. Preparation of low shrinkage stress dental composite with synthesized dimethacrylate oligomers. *J. Mech. Behav. Biomed. Mater.* **2019**, *94*, 222–228. [[CrossRef](#)] [[PubMed](#)]
102. Rodrigues, S.B.; Petzhold, C.L.; Gamba, D.; Leitune, V.C.B.; Collares, F.M. Acrylamides and methacrylamides as alternative monomers for dental adhesives. *Dent. Mater.* **2018**, *34*, 1634–1644. [[CrossRef](#)]
103. Lazar, M.; Zhang, A.D.; Vashi, N.A. Topical Treatments in Atopic Dermatitis: An Expansive Review. *J. Clin. Med.* **2024**, *13*, 2185. [[CrossRef](#)]

Disclaimer/Publisher’s Note: The statements, opinions and data contained in all publications are solely those of the individual author(s) and contributor(s) and not of MDPI and/or the editor(s). MDPI and/or the editor(s) disclaim responsibility for any injury to people or property resulting from any ideas, methods, instructions or products referred to in the content.