

Aesthetics in oral implantology: biological, clinical, surgical, and prosthetic aspects

Masih, Misbah Morason

Master's thesis / Diplomski rad

2024

Degree Grantor / Ustanova koja je dodijelila akademski / stručni stupanj: **University of Zagreb, School of Dental Medicine / Sveučilište u Zagrebu, Stomatološki fakultet**

Permanent link / Trajna poveznica: <https://um.nsk.hr/um:nbn:hr:127:637230>

Rights / Prava: [In copyright](#) / [Zaštićeno autorskim pravom.](#)

Download date / Datum preuzimanja: **2025-02-22**



Repository / Repozitorij:

[University of Zagreb School of Dental Medicine Repository](#)





University of Zagreb

School of Dental Medicine

Misbah Morason Masih

**AESTHETICS IN ORAL IMPLANTOLOGY:
BIOLOGICAL, CLINICAL, SURGICAL, AND
PROSTHETIC ASPECTS**

GRADUATE THESIS

Zagreb, 2024

The work was carried out at: Department of Fixed Prosthodontics, School of Dental Medicine, University of Zagreb

Thesis mentor: Associate Professor Andreja Carek, DMD, PhD, Department of Fixed Prosthodontics, School of Dental Medicine, Zagreb

English language proofreader: Professor Steve Garner, Department of Criminology, Sociology and Social Policy, Swansea University

Croatian language proofreader: Kristina Dilica, Professor of the Croatian Language

The thesis contains: 35 pages
6 tables
5 figures

This work is the author's own work, which is written completely independently with an indication of the sources of other authors and documents used in the paper. Unless stated otherwise, all illustrations (tables, pictures, etc.) in the paper are the original contribution of the author to the thesis. The author is responsible for obtaining permission for the use of illustrations that are not his original contribution, as well as for any possible consequences that may arise due to unauthorized downloading of illustrations or failure to indicate their origin.

Acknowledgements

"I can do all things through Christ who strengthens me."

Philippians 4:13

First and foremost, I dedicate this thesis to God Almighty for His guidance, strength, and blessings throughout this journey. His grace has been my source of perseverance and wisdom, and without it, this accomplishment would not have been possible.

To my beloved parents, Moras and Nasim Masih, whose unwavering love and support have been my foundation. Your sacrifices, encouragement, and prayers have been the bedrock of my success. I am eternally grateful for everything you have done for me.

To my four wonderful older brothers, Moses, Mark, Mike, and Mackenzie, thank you for always being there for me with your encouragement, understanding, and unwavering belief in my abilities. Your support has been a constant source of motivation.

I would like to thank my thesis mentor, Professor Andreja Carek, for her invaluable assistance, patience, and guidance throughout writing this thesis.

And to my soul sister, Kosar, with whom I have studied for the last six years, thank you for your constant companionship, support, and the joy you bring into my life. Your friendship has been a cornerstone of my strength, and I would not have been able to accomplish this without you.

AESTHETICS IN ORAL IMPLANTOLOGY: BIOLOGICAL, CLINICAL, SURGICAL, AND PROSTHETIC ASPECTS

Summary

Aesthetics in oral implantology is comprehensively examined in this thesis, focusing on biological, clinical, surgical, and prosthetic aspects. Aesthetics, defined as philosophies concerned with beauty, is vital in dentistry where both functional and visually pleasing results are desired. Osseointegration is the biological foundation of implant stability. It is influenced by features such as bone quality and implant surface treatments and is evaluated via tools such as CBCT. Clinically, successful patient assessment, treatment planning, and utilizing advanced diagnostics, are elemental for predictable outcomes. Surgically, pre-surgical planning and procedures such as flap design and bone grafting are vital for implant success and aesthetics, with digital tools improving precision. Prosthetic considerations involve selecting materials such as zirconia and utilising advanced fabrication techniques to guarantee aesthetic prosthetics, sustained by regular maintenance protocols. The integration of these findings highlights the requirement of a comprehensive approach, linking advanced technology with clinical proficiency to accomplish optimal aesthetic outcomes in oral implantology, in spite of challenges such as biological variability and costs. Future research should concentrate on innovative materials and regenerative techniques to further enhance patient-centred outcomes.

Keywords: fixed prosthodontic; implant; dental ceramic; aesthetics; osseointegration

ESTETIKA U ORALNOJ IMPLANTOLOGIJI: BIOLOŠKI, KLINIČKI, KIRURŠKI I PROTETSKI ASPEKTI

Sažetak

Estetika u oralnoj implantologiji u ovom se radu sveobuhvatno ispituje s fokusom na biološke, kliničke, kirurške i protetske aspekte. Estetika, definirana kao filozofija koja se bavi ljepotom, vitalna je u stomatologiji gdje su poželjni i funkcionalni i vizualno ugodni rezultati. Oseointegracija je biološki temelj stabilnosti implantata. Na njega utječu značajke kao što su kvaliteta kosti i tretmani površine implantata, a procjenjuje se pomoću alata kao što je CBCT. Klinički, uspješna procjena bolesnika, planiranje liječenja i korištenje napredne dijagnostike ključni su za predvidljive ishode. Kirurški, predkirurško planiranje i postupci kao što su dizajn reznja i presađivanje kosti ključni su za uspjeh implantata i estetiku, s digitalnim alatima koji poboljšavaju preciznost. Protetska razmatranja uključuju odabir materijala kao što je cirkonij i korištenje naprednih tehnika izrade kako bi se zajamčila estetska protetika, podržana redovitim protokolima održavanja. Integracija ovih nalaza naglašava zahtjev za sveobuhvatnim pristupom, povezivanjem napredne tehnologije s kliničkim znanjem kako bi se postigli optimalni estetski rezultati u oralnoj implantologiji, unatoč izazovima kao što su biološka varijabilnost i troškovi. Buduća bi se istraživanja trebala usredotočiti na inovativne materijale i regenerativne tehnike kako bi se dodatno poboljšali ishodi usmjereni na pacijenta.

Ključne riječi: fiksna protetika; implantati; dentalna keramika; estetika; oseointegracija

TABLE OF CONTENTS

1. INTRODUCTION	1
2. INTEGRATED APPROACHES TO AESTHETIC IMPLANTOLOGY	4
2.1 Biological Aspects	5
2.1.1 Bone Structure and Density	5
2.1.2 Osseointegration	5
2.1.3 Biological Considerations of Titanium and Zirconium Implants	6
2.1.4 Soft Tissue Management.....	7
2.1.5 Importance of Treatment Planning	7
2.2 Clinical Aspects	7
2.2.1 Patient Assessment.....	8
2.2.2 Diagnostic Tools	8
2.2.3 Treatment Planning.....	8
2.2.4 Clinical Techniques	9
2.2.5 Traditional Surgical Techniques	9
2.2.6 Minimally Invasive Techniques.....	9
2.2.7 Prosthetic Techniques	10
2.2.8 Material Selection	10
2.2.9 Case Study	10
2.2.10 Importance of Postoperative Care.....	11
2.3 Surgical Aspects.....	12
2.3.1 Surgical Planning.....	12
2.3.2 Pre-Surgical Planning for Optimal Aesthetics	12
2.3.3 Surgical Techniques.....	13
2.3.4 Flap Design	13
2.3.5 Bone Grafting.....	14
2.3.6 Soft Tissue Management.....	14
2.3.7 Implant Placement	14
2.3.8 Factors Affecting Implant Positioning for Aesthetics	15
2.3.9 Radiographic Evaluation of Implant Placement	15
2.3.10 Surgical Complications.....	16
2.3.11 Common Surgical Complications and Management	16

- 2.4 Prosthetic Aspects..... 17
 - 2.4.1 Prosthetic Design for Optimal Aesthetic Outcomes 17
 - 2.4.2 Material Selection and Their Impact on Aesthetics 17
 - 2.4.3 Fabrication Techniques..... 18
 - 2.4.4 Prosthetic Maintenance Protocols to Ensure Long-Term Aesthetic Results 18
- 3. DISCUSSION..... 20
- 4. CONCLUSION..... 24
- 5. REFERENCES 27
- 6. CURRICULUM VITAE..... 34

List of Abbreviations

CBCT - Cone Beam Computed Tomography

3D - 3 Dimensional

DSD - Digital Smile Design

CAD - Computer-Aided Design

CAM - Computer-Aided Manufacturing

OPG - Orthopantomogram

1. INTRODUCTION

Dentistry, a fundamental field of healthcare, concentrates on the diagnosis, prevention, and treatment of oral diseases, aiming to improve the overall health and aesthetics of patients. The term 'aesthetics' originates from the Greek word 'aisthetikos' meaning 'the one who pertains/deals with the senses', which was taken from the word 'aisthanomai' meaning 'I perceive, feel, sense' (1). Defined as a set of principles, it deals with the nature and appreciation of beauty (2). It is therefore especially important in dentistry as patients' expectations are increasingly of outcomes that are not only functional, but also visually pleasing. Within the several branches of dentistry, implantology has arisen as a crucial area, offering advanced solutions for tooth replacement that accommodate both functional and aesthetic demands that directly influence a patient's confidence and social interactions.

Oral implantology comprises inserting dental implants into the jawbone to provide support for prosthetic restorations, delivering a long-lasting and stable resolution for missing teeth. This practice has further developed into a discipline known as Implantoprosthodontic therapy, which comprises of implantology with prosthetic dentistry, and is made up of clinical, surgical, prosthetic, and restorative principles which play a critical role in accomplishing successful outcomes (3). This form of therapy concentrates not only on the mechanical stability and functionality of implants but also highlights on the aesthetic integration within the surrounding oral tissues.

In oral implantology, the biological aspect is essential to its success, predominantly concerning bone structure and health. Two vital factors of bone that influence the stability and integration of dental implants are its quality and quantity (4). These factors are assessed accurately by advanced digital imaging techniques like Cone Beam Computed Tomography (CBCT). CBCT delivers detailed three-dimensional images of the jawbone, thereby allowing for precise evaluation and planning of implant placement, which is crucial for guaranteeing functional and aesthetic outcomes.

A cornerstone of successful implantology is treatment planning. Comprehensive planning encompasses assessing the patient's oral condition, specific anatomical features, and overall health. This particular approach helps in choosing the suitable implant type, size, and placement position, ultimately improving the aesthetic results.

Clinically, implant material selection plays a vital role in achieving the finest aesthetics. Titanium and zirconium are the two main resources used for dental implants. Titanium has been the long-standing standard material, used as it has great biocompatibility and mechanical properties. However, zirconium implants have increased in popularity, especially in the area visible when smiling or speaking known as the 'aesthetic zone'. Zirconium implants are ideal

in this zone due to their tooth-like color, which avoids the appearance of a greyish hue that is occasionally visible through gums from titanium implants (5). In addition, zirconium's excellent interaction with soft tissues encourages better gum health and aesthetics.

In the surgical phase, the accurate placement of implants is vital, as it must be positioned precisely in order for the final prosthetic restoration to be well supported and have a natural looking appearance. Additionally, in attaining a pleasing aesthetic outcome, the management of soft issue during surgery also plays an important role.

Zirconium abutments or customized individual abutments are regularly used to support the final restoration within the aesthetic zone. As a result of their colour and biocompatibility, compared to titanium abutments, zirconium abutments deliver a more natural-looking appearance. Various materials such as lithium disilicate, zirconia, or new hybrid materials can be used as the final aesthetic crowns that are placed on the abutments. These materials mimic the natural translucency and colour of teeth while also providing the required strength and durability.

The pursuit of aesthetics in oral implantology involves a comprehensive understanding of biological, clinical, surgical, and prosthetic properties. The integration of advanced imaging techniques, detailed treatment planning, and the meticulous selection of implant materials and prosthetic components are all fundamental to attaining prosperous and aesthetically pleasing results for patients. This thesis will examine these aspects in detail, investigating the latest advancements and best practices in the field of aesthetic oral implantology.

2. INTEGRATED APPROACHES TO AESTHETIC IMPLANTOLOGY

2.1 Biological Aspects

For oral implantology to be successful, many biological aspects such as bone structure, bone density, osseointegration, and soft tissue management need to be understood and managed. It is essential to have the appropriate assessment and planning in these areas to make sure the longevity and functionality of dental implants are guaranteed.

2.1.1 Bone Structure and Density

The success of dental implants heavily relies on the quality and quantity of jawbone (4). In order to achieve a stable foundation for implants, a sufficient volume and density of bone is fundamental. Bone density affects the initial stability and long-term integration of the implant and is often categorized into types D1 to D4, according to Misch (6). Type D1 bone is characterised as the most dense and supportive, whereas type D4 bone is the least dense and provides the lowest support.

The evaluation of bone structure has been transformed by CBCT as it provides three-dimensional imaging, thereby permitting high precision assessment of bone volume, density and anatomy for clinicians. This modern-day technology allows for critical structures, such as the mandibular canal and maxillary sinus to be visualised in detail, thereby decreasing the risk of complications during placement of the implant (7).

2.1.2 Osseointegration

Osseointegration, the functional and structural relationship between the surface of a load-bearing implant and living bone is essential for ensuring the stability and accomplishment of the implant. This procedure is comprised of many biological phases such as, initial healing, bone remodelling and maturation. The characteristics of the implant surface, including roughness and chemical composition, considerably influence osseointegration. Studies have shown that roughened surfaces improve bone-implant contact and encourage faster osseointegration compared to smooth surfaces (8). Implant materials also play an essential role in osseointegration. Titanium, recognised for its mechanical properties and biocompatibility, has been the gold standard for decades. Recent progressions have introduced zirconium implants, which offer similar osseointegration abilities with additional soft tissue response and aesthetic benefits as a result of their tooth-like colour (9). Additionally, in comparison to

titanium, research has shown that inflammatory response and bone loss caused by zirconia implants are considerably lower, thereby proposing that it is a biocompatible material (10).

2.1.3 Biological Considerations of Titanium and Zirconium Implants

Implants made of titanium are widely recognized for their durability, strength, and exceptional osseointegration properties. Successful implant integration can be achieved when the biocompatibility of titanium implants permits for a positive response from the surrounding bone and soft tissues (11). However, within the aesthetic zone, concerns relating to the possibility of grey discoloration of the gingiva as a result of metallic hue from the titanium have led to the investigation of alternative materials.

An alternative viable material that has emerged and is used particularly for the aesthetic zone is Zirconium implants. Zirconium is a ceramic material that demonstrates biocompatibility, high strength, and a natural white colour that imitates the appearance of natural teeth (Figure 1). Research suggests that zirconium implants show exceptional osseointegration and comparable success rates in comparison to titanium implants (12). Furthermore, the favourable interaction of zirconium with soft tissues assists with the prevention of peri-implantitis and other inflammatory conditions thereby further enhancing its suitability for aesthetic purposes (13).



Figure 1. NobelPearl Zirconia Material in Raw Form for Dental Implant Fabrication
Courtesy of Professor Carek

2.1.4 Soft Tissue Management

Another essential aspect of the biological foundation for dental implants is management of soft tissues. The proper integration of soft tissue assists in the formation of a natural appearance and guards the underlying bone from invasion of bacteria and inflammation. The peri-implant soft tissue's health and stability considerably effects the aesthetic outcome and long-term success of the implant (13).

Many different techniques and materials are used to manage and improve the outcomes of soft tissue around implants. These include the use of zirconium abutments, connective tissue grafts, and meticulous surgical procedures to preserve the natural gingival contour and papillae. Zirconium abutments are predominantly valuable within the aesthetic zone as a result of their capacity to blend effortlessly with the surrounding tissues, removing the risk of grey lines that can transpire with abutments made of titanium (13).

2.1.5 Importance of Treatment Planning

Comprehensive treatment planning is vital to address biological properties successfully. Preoperative assessment by means of CBCT imaging, bone quality and quantity evaluation, and careful selection of implant material are crucial steps (4, 14). In addition, soft tissue management planning and ensuring appropriate positioning and alignment of the implant are essential in attaining positive outcomes.

Therefore, understanding and addressing the biological features of oral implantology are crucial to the success of implant treatments. The advancements in imaging technology, techniques and materials continues to improve clinicians' ability to deliver reliable and aesthetically pleasing results for patients.

2.2 Clinical Aspects

In oral implantology, comprehensive clinical aspects are vital to attaining prosperous outcomes that ensure successful implant placement and functionality. This chapter will examine patient assessment, treatment planning, various clinical techniques and materials used in implant dentistry, thereby highlighting their significance for precision and patient-centred approaches in guaranteeing both functional and aesthetic success.

2.2.1 Patient Assessment

A comprehensive patient assessment is a crucial first step for clinical procedures in oral implantology. The aim is to establish whether the patient is a suitable candidate for dental implants by analysing the patient's oral health status, bone structure, and condition of soft tissue to determine a custom-made treatment plan.

Patient assessment is vital as it recognises any underlying health conditions that may hinder the implant procedure. This includes a comprehensive assessment of the patient's dental and medical history, clinical examination, current medications, lifestyle influences such as smoking that could affect healing and implant success, and radiographic assessment, typically using modern technology such as CBCT (15).

2.2.2 Diagnostic Tools

Diagnostic tools are an essential aspect in patient assessment. These include the following:

- **Clinical Examination:** Includes assessing oral hygiene, periodontal health, occlusion and the situation of the adjacent teeth.
- **Radiographic Analysis:** Detailed images of the bone structure are provided by CBCT, permitting precise planning of the implant placement.
- **Photographic Records:** Photographs taken intra-orally and extra-orally assist in recording the baseline condition presented by the patient and planning outcomes that are aesthetically pleasing.

2.2.3 Treatment Planning

In oral implantology, successful treatment planning is fundamental for attaining optimal aesthetic and functional outcomes. This is achieved by the following steps:

1. **Initial Consultation and Goal Setting:** Understanding the expectations and aesthetic wishes of the patient.
2. **Diagnostic Wax-Up:** Constructing a visual representation of the final outcome, to facilitate the surgical and prosthetic phases.
3. **Interdisciplinary Approach:** Partnering with periodontists, prosthodontists, and orthodontists, if required, to address all phases of oral health.
4. **Surgical Planning:** Using CBCT and digital planning software to establish the ideal implant size, position, and angulation.

5. **Prosthetic Planning:** Designing the final prosthesis to confirm it satisfies the aesthetic and functional desires of the patient (16).

2.2.4 Clinical Techniques

Different clinical techniques are used to improve aesthetics in implant dentistry. These procedures are specifically tailored to the needs of each individual patient to make sure the best possible outcome is obtained.

2.2.5 Traditional Surgical Techniques

In implant dentistry, surgical techniques are devised to guarantee the optimal implant placement and ensure correct osseointegration. These procedures can be broadly classified into traditional and minimally invasive surgical techniques.

Traditional implant surgery typically comprises of a two-stage process:

1. **First Stage Surgery:** The initial surgery comprises of placing the implant fixture into the bone, followed by placing sutures on the surgical site to allow for healing. This typically lasts for 3-6 months, to ensure proper osseointegration (17, Table 1).
2. **Second Stage Surgery:** After osseointegration, a second surgery is conducted that reveals the implant and attaches the abutment, thereby preparing it for prosthetic restoration (17, Table 1).

2.2.6 Minimally Invasive Techniques

The purpose of minimally invasive techniques is to lessen patient discomfort and recovery time.

These include:

- **Flapless Surgery:** Without raising a mucoperiosteal flap, implants are placed, thereby reducing the surgical time, soft tissue disturbance, postoperative bleeding, patient discomfort and consequently encouraging faster healing (18, Table 1).
- **Immediate Loading:** In suitable occasions, the implant and prosthesis are placed in a single surgical session, decreasing treatment time and hence improving patient satisfaction (19, Table 1).

Table 1. Comparison of Surgical Techniques (20, 21, 22)

Technique	Advantages	Disadvantages
Traditional	Reliable, well-documented success rates	Longer treatment time, increased patient visits
Flapless Surgery	Reduced healing time, less discomfort	Limited visibility, higher precision required
Immediate Loading	Shorter overall treatment time, immediate aesthetics	Not suitable for all cases, risk of implant failure

2.2.7 Prosthetic Techniques

- **Custom Abutments:** Abutments that are individually designed improve soft tissue management and aesthetic outcomes by offering the best support for the final restoration (23).
- **Immediate Temporization:** Immediately after implant surgery, temporary restorations are placed so that aesthetics and function are preserved during the healing period (23).

2.2.8 Material Selection

Clinical outcomes are significantly impacted by the choice of implant material. The two primary materials used in implant dentistry are titanium and zirconium.

- **Titanium Implants:** Recognised for their biocompatibility, strength and exceptional osseointegration properties. However, there is a concern as they may cause grey discoloration of the gingiva in the aesthetic zone (5).
- **Zirconium Implants:** Known for exhibiting a tooth-like colour makes them ideal for the aesthetic zone. They offer extraordinary biocompatibility and osseointegration whilst preventing grey lines in the gingival area to provide superior aesthetic results (5).

2.2.9 Case Study

The before and after images (Figure 2 and Figure 3) demonstrate the significant aesthetic development accomplished through meticulous planning and execution of implant placement in the aesthetic zone. The pre-treatment image (Figure 2) displays the situation of the patient's dentition before the treatment. The post-treatment image (Figure 3) shows a noticeable improvement in the aesthetic appearance of the upper lateral incisor, which was restored using

a zirconia abutment and crown. This case illustrates the importance of custom-made treatment planning and materials selection that deliver both strength and aesthetic compatibility with the natural teeth of the patient. The overall smile aesthetics and facial harmony of the patient were drastically improved, thereby positively influencing the patient's confidence and social interactions.

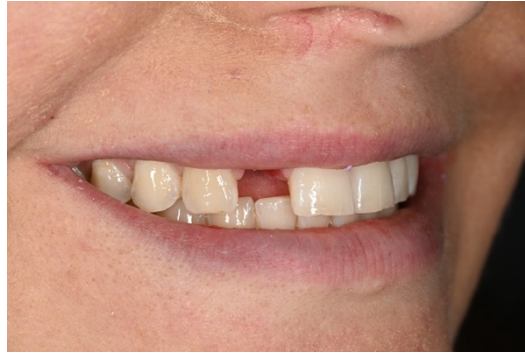

Figure 2. Pre-treatment photograph showing the aesthetic zone prior to implant placement

Courtesy of Professor Carek and DDS Ivasović

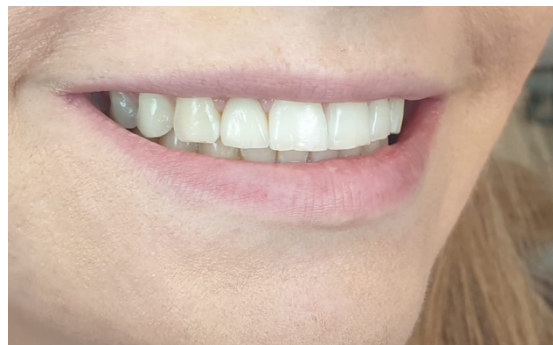

Figure 3. Post-treatment photograph demonstrating the enhanced aesthetic outcome after implant placement

Courtesy of Professor Carek and DDS Ivasović

2.2.10 Importance of Postoperative Care

Postoperative care is fundamental to guarantee dental implant longevity and success. This involves regular follow-up visits, oral hygiene maintenance, and monitoring for any signs of problems such as peri-implantitis.

The clinical aspects of oral implantology are essential to attaining effective and aesthetically pleasing results. Comprehensive patient assessment, meticulous treatment planning, and the use of advanced clinical techniques are integral.

2.3 Surgical Aspects

2.3.1 Surgical Planning

In oral implantology, surgical planning is a vital phase that creates the foundation for gaining the best aesthetic and functional outcomes. Comprehensive pre-surgical planning includes meticulous evaluation and detailed preparation to guarantee the precise placement of implants where they can assist the desired prosthetic outcome in the best way possible.

2.3.2 Pre-Surgical Planning for Optimal Aesthetics

Patient Assessment and Diagnostic Imaging: A comprehensive patient assessment, comprising of medical history, oral examination, and radiographic imaging, is fundamental. CBCT is the diagnostic method that provides 3D images of the patient's bone structure, permitting the accurate planning of implant placement (24, Table 2).

Virtual Treatment Planning: Clinicians can accomplish virtual treatment planning by using advanced software tools. This includes the implant placement simulation on a computer model, considering the anatomical structures and aesthetic goals of the patient. This digital method assists in envisioning the final outcome, and planning the optimal position, as well as the angulation of the implants (25, Table 2).

Guided Surgery: The precision of an implant placement can be improved by using surgical guides made from the virtual treatment plan. These guides make sure that the implants are positioned in reference to the pre-surgical plan, thereby minimising the risk of errors and improving the aesthetic outcome (26, Table 2).

Table 2. Steps in Pre-Surgical Planning

Step	Description
Patient Assessment	Medical and dental history, clinical examination, radiographic imaging
Virtual Treatment Planning	Use of digital tools to plan the implant placement
Guided Surgery	Creation and use of surgical guides for precise implant placement

2.3.3 Surgical Techniques

Several surgical techniques are used to guarantee success of the implant placement and optimal aesthetic outcomes. These techniques comprise of flap design, bone grafting, and management of soft tissue.

2.3.4 Flap Design

Flap design is crucial in order to adequately access the implant site whilst conserving blood supply and reducing trauma. The surgical site and particular clinical scenario dictates which flap design is chosen. Some common flap designs that are used for soft tissue thickening around implants are (27):

- **Full-Thickness Flap:** Comprises of lifting the whole mucoperiosteal flap to reveal the bone (28, Figure 4).
- **Partial-Thickness Flap:** The mucosal layer consisting of only a layer of underlying connective tissue and epithelium is lifted, preserving the periosteum attached to the bone (28, Figure 4).

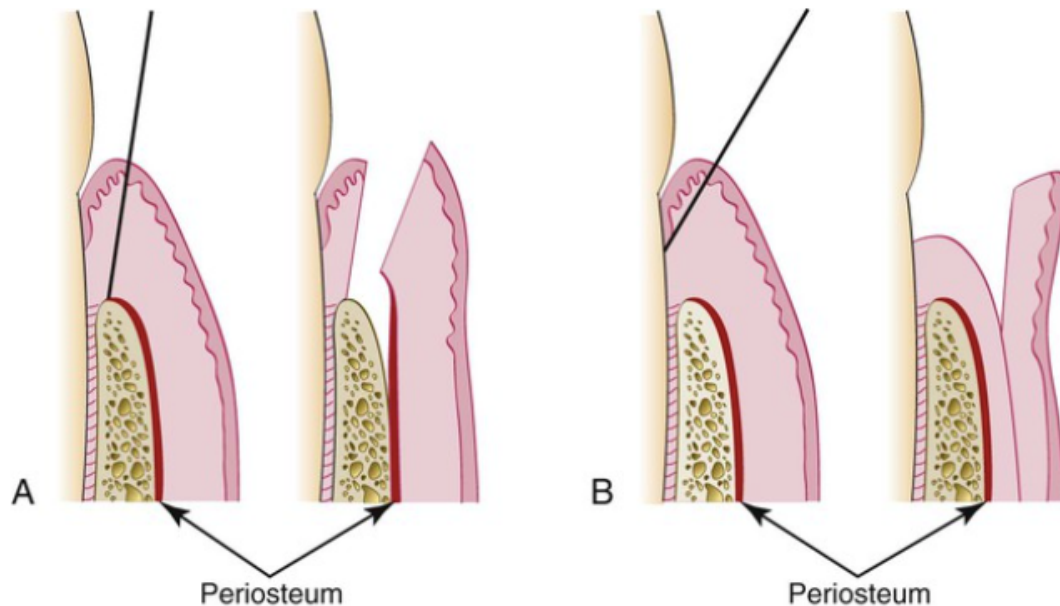


Figure 4. A, Diagram of the full-thickness flap. B, Diagram of the partial-thickness flap (28)

2.3.5 Bone Grafting

Bone grafting is sometimes compulsory in situations where the patient does not have enough bone volume to support the implant. This can include:

- **Autogenous Grafts:** Bone harvested from the patient's own body.
- **Allografts:** Bone from a human donor.
- **Xenografts:** Bone from animal sources.
- **Synthetic Grafts:** Manufactured bone substitutes (29).

2.3.6 Soft Tissue Management

Handling the soft tissue around the implant site is vital for aesthetic outcomes. Techniques include:

- **Flapless Surgery:** Minimises trauma and encourages faster healing, particularly favourable in the aesthetic zone (18).
- **Connective Tissue Grafts:** Used to transform thin tissue to thick tissue by improving the volume and quality of the gingival tissue surrounding the implant (30).

Table 3. Summary of Surgical Techniques in Implantology

Technique	Description
Full-Thickness Flap	Complete exposure of the bone
Split-Thickness Flap	Partial lifting of the mucosal layer
Bone Grafting	Use of autogenous, allografts, xenografts, or synthetic materials to augment bone volume
Soft Tissue Management	Techniques such as flapless surgery and connective tissue grafts to improve aesthetics

2.3.7 Implant Placement

The specific placement of dental implants is also very vital for attaining both functional and aesthetic success. Various factors must be considered to guarantee optimum implant positioning.

2.3.8 Factors Affecting Implant Positioning for Aesthetics

Bone Quality and Quantity: In order to achieve stability and longevity of the implant, adequate bone volume and density are fundamental. Bone grafting might be essential to augment deficient areas (4).

Implant Positioning: Without aesthetics being compromised, the position of implants should be done to assist the planned prosthetic restoration. This incorporates considering the implant depth and angulation to dodge problems such as recession of the gingiva or implant collar exposure (31).

Spacing and Alignment: Adequate spacing in between implants and natural teeth is necessary to preserve the surrounding tissue's health and to guarantee an aesthetically pleasing outcome. The implants being aligned parallel to each other also enables easier prosthetic rehabilitation (32).

2.3.9 Radiographic Evaluation of Implant Placement

The OPG (Figure 5) delivers a comprehensive assessment of the post-surgical implant placement, exemplifying prosperous osseointegration and proper alignment within the upper lateral incisor region. The precise angulation and depth of the implant, as displayed in the OPG, are crucial for both functional and aesthetic success. This imaging approves the accuracy of the surgical technique, which comprised of careful planning to guarantee the implant was positioned optimally relative to adjacent teeth. Furthermore, this radiographic evidence supports the choice to use a zirconia abutment, which improves the aesthetic result by reducing appearance of metal, a common problem with titanium abutments within the aesthetic zone.

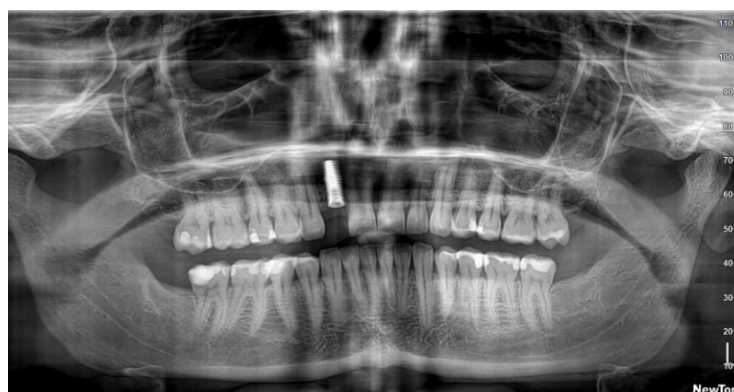

Figure 5. Orthopantomogram (OPG) showing the implant's osseointegration and position in the upper lateral incisor post-treatment

Courtesy of Professor Carek and DDS Ivasović

2.3.10 Surgical Complications

The management of surgical complications is fundamental to guarantee the durability and aesthetics of dental implants. Complications can occur during or after surgery, and in order to mitigate their impact, prompt intervention is essential.

2.3.11 Common Surgical Complications and Management

Infection: Infections can happen at the surgical site. This can result in failure of the implant if not attended to promptly. Some important preventive measures are prophylactic antibiotics and maintaining aseptic surgical practises (33).

Nerve Injury: Inferior alveolar nerve damage or injury to other neural structures can result in numbness or pain. Such problems can be avoided by using correct pre-surgical planning as well as CBCT imaging (34).

Bone Loss: The stability and aesthetics of an implant can be compromised by peri-implant bone loss. Routine follow-ups and proper oral hygiene procedures are essential to prevent peri-implantitis and other bone-related issues (35).

Aesthetic Complications: The aesthetic outcome can be affected because of complications such as gingival recession or improperly positioning the implant. Attending these concerns may need additional surgical interventions or prosthetic adjustments (36).

Table 4 demonstrates the procedures that could be taken beforehand to prevent such surgical complications from happening.

Table 4. Management of Surgical Complications

Complication	Management Strategy
Infection	Prophylactic antibiotics, aseptic techniques, and prompt treatment of infection
Nerve Injury	Pre-surgical planning, use of CBCT imaging, and careful surgical technique
Bone Loss	Regular follow-up, proper oral hygiene, and management of peri-implantitis
Aesthetic Issues	Additional surgical interventions or prosthetic adjustments to address aesthetic concerns

2.4 Prosthetic Aspects

The prosthetic aspects are another vital area to attain optimal functional and aesthetic outcomes. This chapter will explore the key phases of prosthetic design, material selection, fabrication procedures, and maintenance protocols, all of which contribute to aesthetic success.

2.4.1 Prosthetic Design for Optimal Aesthetic Outcomes

Patient-Specific Considerations: Prosthetic design starts from a comprehensive overview of the certain needs and aesthetic goals of the patient (37). These include factors comprising of tooth colour, shape, alignment, and the association of the prosthesis with surrounding tissues are crucial.

Digital Smile Design: Clinicians are able to design the prosthesis with meticulous precision using digital tools. Digital Smile Design (DSD) permits for envisioning the final result and creating required amendments before the actual fabrication. This method improves communication between the patient and the clinician, guaranteeing that the patient's aesthetic goals are met (38).

Occlusal Considerations: Occlusion plays an essential function in the long-term success of the prosthesis. The accuracy of the occlusal design makes sure that the forces are distributed equally, avoiding premature wear and improving the overall aesthetics (39).

2.4.2 Material Selection and Their Impact on Aesthetics

Zirconia: As a result of its exceptional aesthetic properties, strength, and biocompatibility, zirconia is extensively used in dental prosthetics. It imitates the colour and translucency of natural teeth, thereby making it an ideal choice for visible aesthetic areas (9).

Lithium Disilicate: Lithium disilicate ceramics provide excellent aesthetics because of their translucency and capacity to be stained and glazed to mimic the natural colour of teeth. They are frequently used in the anterior region for veneers and crowns (40).

Composite Resins: The aesthetic properties have been improved by advances in composite resins, therefore making them appropriate for certain permanent restorations and provisional implant supported restorations. They provide great colour matching and can be polished to a high gloss (41).

Table 5. Comparison of Prosthetic Materials

Material	Aesthetic Properties	Strength	Common Uses
Zirconia	High translucency	Very strong	Crowns, bridges, implant abutments
Lithium Disilicate	Superior translucency	Strong	Veneers, crowns, anterior restorations
Composite Resins	Good colour matching	Moderate	Temporary prosthetics, fillings

2.4.3 Fabrication Techniques

CAD/CAM Technology: The production of dental prosthetics has been revolutionised by Computer-Aided Design and Computer-Aided Manufacturing (CAD/CAM) technology. It guarantees qualities consistency, high precision, and efficiency in constructing restorations that fulfil both functional and aesthetic obligations (42).

3D Printing: 3D printing technology authorises the manufacture of customized and highly detailed prosthetics. This procedure is specifically beneficial for creating surgical guides, temporary prostheses, and permanent restorations (43).

Layering Technique: The layering technique in ceramics consists of applying various layers of ceramic material to build up the restoration. This procedure permits for a more natural look, duplicating the depth and translucency of natural teeth (44).

Table 6. Overview of Fabrication Techniques in Prosthetic Dentistry

Technique	Description
CAD/CAM Technology	Digital design and manufacturing for high precision and efficiency
3D Printing	Additive manufacturing for detailed and customized prosthetics
Layering Technique	Applying multiple ceramic layers to mimic natural tooth translucency and depth

2.4.4 Prosthetic Maintenance Protocols to Ensure Long-Term Aesthetic Results

Regular Follow-Up: Consistent dental check-ups are vital for supervising the state of the surrounding tissues and the prosthetics. Early discovery of any problems can avoid complications and prolong the prosthesis lifespan (45).

Oral Hygiene Practices: Correct oral hygiene practices should be taught to patients so that the functionality and aesthetics of their prosthesis are preserved. This involves brushing, flossing, and using interdental brushes to avert the build-up of plaque (45).

Professional Cleaning: Regular professional cleanings assist in tartar and plaque removal that cannot be completed with home care alone. Special tools and procedures are utilised to clean around implants and prosthetic mechanisms without causing any damage (45).

3. DISCUSSION

The study of oral implantology involves a method that incorporates biological, clinical, surgical, and prosthetic properties to attain optimal aesthetic results.

Having a comprehensive understanding of the biological basis of osseointegration is essential in oral implantology. According to Mavrogenis AF, osseointegration guarantees dental implant stability by assisting the direct anchorage of the implant to the bone without interference from the fibrous tissue (46). Recent developments have emphasised the function of surface modifications and coatings in improving osseointegration, thereby enhancing implant success rates.

In order to achieve clinical success, patient assessment and treatment planning are vital. Utilizing diagnostic tools such as CBCT permits for planning that is precise, thereby minimising the risk of complications. As mentioned by Nasti S and Jafri Z the predictability of aesthetic results has been improved by techniques like guided surgery and digital smile design (26, 38).

Surgical planning and procedures are vital for the success of implants. Pre-surgical planning, involving the use of digital tools and surgical guides, secures the precise placement of the implant. Approaches such as flap design, bone grafting, and soft tissue management can be mobilised to improve functional and aesthetic results (18, 27, 28, 29, 30). Supervising surgical complications, such as infections and bone loss, is fundamental for long-term success.

The aesthetic result of dental implants is significantly influenced by prosthetic design, material selection, and fabrication techniques. Modern materials such as zirconia and lithium disilicate present superior aesthetic features. Digital technologies like CAD/CAM and 3D printing, improve the precision and customization of prosthetics. As reported by Gulati M, maintenance procedures, comprising of consistent follow-ups and professional cleanings, are essential to guaranteeing the durability of the prosthesis (45).

The integration of outcomes from several oral implantology aspects had various implications for clinical practice. The usage of advanced diagnostic tools and imaging technologies authorizes for better assessment and planning, resulting in more predictable outcomes.

The precision of implant placement is enhanced by digital planning and guided surgery, decreasing the risk of complications, and improving aesthetic outcomes.

The evolution of new biomaterials with exceptional aesthetic and mechanical properties permits for the formation of more natural-looking and resilient prosthetics.

A comprehensive method that comprises of patient education, regular maintenance, and follow-ups guarantees the long-term success of dental implants. Highlighting oral hygiene and

professional cleaning aids in sustaining the aesthetics and functionality of the prosthetics according to Gulati M (45).

Successful communication and collaboration among dental specialists, including prosthodontists, oral surgeons, and periodontists, are vital for attaining the best results for patients.

Regardless of the advancements, various challenges and limitations persist in the area of oral implantology.

Cases consisting of severe bone loss or poor oral health conditions can complicate treatment planning and execution. Bone grafting and sinus lifting are advanced techniques that add complexity and increase the risk of complications.

High costs linked with advanced materials, digital technologies, and complex surgical techniques can limit access to high-quality implant treatments for some patients.

Dependence on digital technologies necessitates important investment in equipment and training. A learning curve is also associated with understanding these technologies, which can be a hinderance for some practitioners.

Biological factors that are specific to the patient like differences in bone quality and healing capacity, can have an impact on the success of implants. The prediction of these variations remains a challenge.

Future research in oral implantology should concentrate on tackling the current challenges and investigating new frontiers:

Establishing new biomaterials with superior properties like better osseointegration and aesthetic results, should be a priority. Carrying out studies into bioactive coatings and surface treatments holds promise for improving implant success rates as stated by Abdulghafor Ma (47).

Progressions in tissue engineering and regenerative medicine could deliver resolutions for complex cases comprising of substantial bone loss. As per Gupta D, research into growth factors and stem cell therapies is ongoing and could revolutionize implantology (48).

Further integration of digital technologies, like machine learning and artificial intelligence, into treatment planning and execution could improve precision and predictability. Studies into fully digital workflows and their clinical effects is necessary.

Long-term research concentrating on patient-centered outcomes, such as quality of life and satisfaction, will contribute valuable insights into the general success of implant treatments. Generating standardized procedures for these results is vital.

Investing in education and training programs to assist clinicians to thoroughly master advanced technologies and techniques is essential. Research into beneficial training approaches and their influence on clinical outcomes can help bridge the knowledge gap.

4. CONCLUSION

The comprehensive investigation of biological, clinical, surgical, and prosthetic aspects of oral implantology emphasises the multifaceted nature of attaining optimal aesthetic results.

The basis of implant stability is osseointegration. It is influenced by aspects such as implant surface modifications and biological compatibility. Developments in surface treatments like nano-coatings, improve bone-to-implant contact and enhance long-term success rates.

Comprehensive assessment using tools such as CBCT is vital for precise treatment planning, decreasing risks and ensuring aesthetic outcomes. Techniques like DSD result in better visualization and planning, thereby supporting patient expectations with clinical results.

Digital tools and guided surgery improve the precision of implant placement, fundamental for aesthetics and function. Procedures like flap design, bone grafting, and soft tissue management are crucial for constructing an appropriate setting for implants and achieving aesthetic results.

Materials such as zirconia and lithium disilicate provide optimal aesthetic properties and durability, necessary for prosthetic success. CAD/CAM and 3D printing technologies allow for accurate and customized prosthetic results, improving both aesthetics and functionality. Regular follow-ups and professional cleanings are fundamental to sustaining the aesthetics and functionality of prosthetic restorations.

Aesthetics in oral implantology is supreme, as it is not only for the visual demand but also for patient psychological well-being and confidence. The integration of biological, clinical, surgical, and prosthetic aspects into an interconnected treatment approach is fundamental for accomplishing the desired aesthetic results.

The arrival of digital technologies has revolutionized every area of implantology, from diagnostics to surgical execution and prosthetic fabrication. These technologies enable exceptional precision and customization, which are crucial for attaining optimal aesthetic outcomes.

Concentrating on patient-specific requirements and expectations is essential. Effective communication and personalized treatment planning make sure that aesthetic targets are aligned with clinical abilities. The use of DSD and other imagining tools can drastically improve this process.

Attaining the best aesthetics involves a multidisciplinary approach involving prosthodontists, oral surgeons, periodontists, and dental technicians. Teamwork and communication amongst these specialists are fundamental to ensure that all aspects of the treatment plan are accomplished perfectly.

Oral implantology is a field that is continuously evolving. Constant education and remaining on track of the latest research and technological developments are elemental for clinicians to

deliver the best possible care. Future research should concentrate on long-term results, patient-centered metrics, and the advancement of new materials and techniques.

In conclusion, the pursuit of perfection in aesthetics within oral implantology is a constant journey. The integration of latest scientific findings, embracing advanced technologies, and upholding a patient-centered method, means clinicians can accomplish extraordinary aesthetic outcomes that considerably enhance the patient's quality of life.

5. REFERENCES

1. Xenakis I, Arnellos A. Aesthetic perception and its minimal content: a naturalistic perspective. *Front Psychol.* 2014;5:1038. Available from: <https://doi.org/10.3389/fpsyg.2014.01038>.
2. Dixon T. Aesthetics | The Cultural History of Philosophy blog [Internet]. 2016. Available from: <https://blogs.history.qmul.ac.uk/philosophy/2016/02/27/aesthetics/>.
3. Sammartino G, Marenzi G, Di Lauro AE, Paolantoni G. Aesthetics in Oral Implantology: biological, clinical, surgical, and prosthetic aspects. *Implant Dent.* 2007;16(1):54–65. Available from: <https://doi.org/10.1097/id.0b013e3180327821>.
4. Fahd A, ElBeshlawy D. Cone beam computed tomography and preoperative bone quality assessment for dental implants: myth and truth. *J Internet.* 2023;2(3):541–9. Available from: <https://doi.org/10.21608/erurj.2023.211464.1026>.
5. Silva B. Dental Implant Materials: Titanium vs. Zirconia [Internet]. *Dental Implants.* 2019. Available from: <https://blog.brightonimplantclinic.co.uk/dental-implant-materials-titanium-vs-zirconia/>.
6. Ce M. Divisions of available bone in implant dentistry [Internet]. U.S. National Library of Medicine; [cited 2024]. Available from: <https://pubmed.ncbi.nlm.nih.gov/2103123/>.
7. The role of CBCT in implant dentistry: uses, benefits and limitations. *BDJ.* 2020;228(7):560–1. Available from: <https://www.nature.com/articles/s41415-020-1522-x>.
8. Alfaraj TA, Al-Madani S, Alqahtani NS, Almohammadi AA, Alqahtani AM, AlQabbani HS, et al. Optimizing Osseointegration in Dental Implantology: A Cross-Disciplinary Review of current and emerging strategies. *Curēus.* 2023. Available from: <https://doi.org/10.7759/cureus.47943>.
9. Singh PV, Reche A, Paul P, Agarwal S. Zirconia Facts and Perspectives for Biomaterials in Dental Implantology. *Curēus.* 2023. Available from: <https://doi.org/10.7759/cureus.46828>.

10. Pereverzyev V. Osseointegration and biocompatibility of zirconia implants. CORE. 2021. Available from: <https://core.ac.uk/outputs/534868245/?source=oai>.
11. Silva RCS, Agrelli A, Andrade AN, Mendes-Marques CL, Arruda IRS, Santos LRL, et al. Titanium Dental Implants: An overview of applied nanobiotechnology to improve biocompatibility and prevent infections. *Materials*. 2022;15(9):3150. Available from: <https://doi.org/10.3390/ma15093150>.
12. Duan C, Ye L, Zhang M, Yang L, Li C, Pan J, et al. Clinical performance of zirconium implants compared to titanium implants: a systematic review and meta-analysis of randomized controlled trials. *PeerJ*. 2023;11. Available from: <https://doi.org/10.7717/peerj.15010>.
13. Tang K, Luo ML, Zhou W, Niu LN, Chen JH, Wang F. The integration of peri-implant soft tissues around zirconia abutments: Challenges and strategies. *Bioact Mater*. 2023;27:348–61. Available from: <https://doi.org/10.1016/j.bioactmat.2023.04.009>.
14. Weiss R, Read-Fuller A. Cone Beam Computed Tomography in Oral and Maxillofacial Surgery: An Evidence-Based Review. *Dent J*. 2019;7(2):52. Available from: <https://www.ncbi.nlm.nih.gov/pmc/articles/PMC6631689/>.
15. Zitzmann N, Margolin M, Filippi A, Weiger R, Krastl G. Patient assessment and diagnosis in implant treatment. *Aust Dent J*. 2008;53(s1). Available from: <https://doi.org/10.1111/j.1834-7819.2008.00036.x>.
16. Boyce RA. Prosthodontic principles in dental Implantology. *Dent Clin North Am*. 2021;65(1):135–65. Available from: <https://doi.org/10.1016/j.cden.2020.09.011>.
17. Alfaer AS, Alharbi NY, Alsulami AA, Alharthi SM, Modahi FH, Modahi NH, et al. A comparative review one-stage and two-stage dental implants. *Int J Community Med Public Health*. 2023;10(9):3387–91. Available from: <https://doi.org/10.18203/2394-6040.ijcmph20232465>.

18. Yadav MK, Verma UP, Parikh H, Dixit M. Minimally invasive transgingival implant therapy: A literature review. *Natl J Maxillofac Surg*. 2018;9(2):117. Available from: https://doi.org/10.4103/njms.njms_52_17.
19. Choudhary D, Girdhar G, Kumar S, Shetty A, Shetty NJ, Sinha S. Flap versus Flapless Immediate Implants with Bone Augmentation: A Novel Study. *J Pharm Bioall Sci*. 2023;15(Suppl 2)
–5. Available from: https://doi.org/10.4103/jpbs.jpbs_211_23.
20. Jain P, Jain M, Haq MdA, Rathore AS, Rai N, Banerjee S, et al. Comparison of the flapped and flapless surgical implant procedure on gingival biotype: A prospective split-mouth study. *J Appl Pharm Sci*. 2023. Available from: <https://doi.org/10.7324/japs.2023.148030>.
21. Kan JYK, Rungcharassaeng K, Deflorian M, Weinstein T, Wang H, Testori T. Immediate implant placement and provisionalization of maxillary anterior single implants. *Periodontol* 2000. 2018;77(1):197–212. Available from: <https://doi.org/10.1111/prd.12212>.
22. Scherer MD, Ingel AP, Kendall K. Flap vs. Flapless: A Practical Guide with Indications, Recommendations, and Techniques for Effective Planning and Surgical Placement of Narrow Diameter Overdenture Implants in the Mandible [Internet]. 2014. Available from: <https://www.semanticscholar.org/paper/Flap-vs.-Flapless%3A-A-Practical-Guide-with-and-for-Scherer-Ingel/6abb4b5d4d94be6446756f68977e616e79f3710e>.
23. Anand D, Gowda V, Sundar M, Reveredo A, Shetty S. Custom anatomic healing abutments. *J Indian Prosthodont Soc*. 2016;16(4):386. Available from: <https://doi.org/10.4103/0972-4052.176518>.
24. Venkatesh E, Elluru SV. Cone beam computed tomography: Basics and applications in dentistry. *J Istanbul Univ Fac Dent*. 2017;51(0). Available from: <https://doi.org/10.17096/jiufd.00289>.

25. Gulati M, Anand V, Salaria SK, Jain N, Gupta S. Computerized implant-dentistry: Advances toward automation. *J Indian Soc Periodontol*. 2015;19(1):5. Available from: <https://doi.org/10.4103/0972-124x.145781>.
26. Nasti S, Anjum S, Kalekhan SM, Ashok A, Bumb PP, Puthenkandathil R. Surgical guides: Precision redefined in implant placement. *IP Int J Periodontol Implantol*. 2023;8(4):177–80. Available from: <https://doi.org/10.18231/j.ijpi.2023.035>.
27. Thoma DS, Mühlemann S, Jung RE. Critical soft-tissue dimensions with dental implants and treatment concepts. *Periodontol 2000*. 2014;66(1):106–18. Available from: <https://doi.org/10.1111/prd.12045>.
28. Themes U. 57: The periodontal flap [Internet]. *Pocket Dentistry*. 2015. Available from: <https://pocketdentistry.com/57-the-periodontal-flap/>.
29. Kumar P, Vinitha B, Fathima G. Bone grafts in dentistry. *J Pharm Bioall Sci*. 2013;5(5):125. Available from: <https://doi.org/10.4103/0975-7406.113312>.
30. Prokuski V, Strohl A. Soft tissue coverage for severe infections. *Hand Clinics [Internet]*. 2020;36(3):369–79. Available from: <https://www.sciencedirect.com/topics/medicine-and-dentistry/connective-tissue-graft#:~:text=Implant%20Treatment&text=A%20connective%20tissue%20graft%20is,placed%20under%20thin%20facial%20gingiva.&text=In%20animal%20studies%2C%20the%20survival%20of%20the%20connective%20graft%20is%20marginal>.
31. Rito-Macedo F, Barroso-Oliveira M, Paranhos L, Rodrigues-Brum J, Pereira-Lima I, Gomes-França F, et al. Implant insertion angle and depth: Peri-implant bone stress analysis by the finite element method. *J Clin Exp Dent [Internet]*. 2021;13(12):e1167–73. Available from: <https://doi.org/10.4317/jced.58930>.
32. Tosh. Why Implant Placement is Crucial to a Dental Implant Journey [Internet]. *Eilertsen Dental Care Inverness*. 2023. Available from: <https://eilertsen-dentalcare.co.uk/dental-implants-inverness/implant-placement/>.

33. Surapaneni H, Yalamanchili PS, Basha H, Potluri S, Elisetti N, Kumar MVK. Antibiotics in dental implants: A review of literature. *J Pharm Bioallied Sci* [Internet]. 2016;8(5):28. Available from: <https://doi.org/10.4103/0975-7406.191961>.
34. Juodzbaly G, Wang HL, Sabalys G. Injury of the Inferior Alveolar Nerve during Implant Placement: a Literature Review. *J Oral Maxillofac Res* [Internet]. 2011;2(1):e2. Available from: <https://doi.org/10.5037/jomr.2011.2101>.
35. Prathapachandran J, Suresh N. Management of peri-implantitis. *Dent Res J* [Internet]. 2012;9(5):516. Available from: <https://doi.org/10.4103/1735-3327.104867>.
36. Chen ST, Buser D, Sculean A, Belser UC. Complications and treatment errors in implant positioning in the aesthetic zone: Diagnosis and possible solutions. *Periodontol 2000* [Internet]. 2023;92(1):220–34. Available from: <https://doi.org/10.1111/prd.12474>.
37. Lee SP, Mitchell C, Repayo K, Tillitt M, Weber C, Chien LC, et al. Patient engagement in cosmetic designing of prostheses: current practice and potential outcome benefits. *Prosthet Orthot Int* [Internet]. 2022;46(4):e335–40. Available from: <https://doi.org/10.1097/pxr.000000000000113>.
38. Jafri Z, Ahmad N, Sawai M, Sultan N, Bhardwaj A. Digital Smile Design-An innovative tool in aesthetic dentistry. *J Oral Biol Craniofac Res* [Internet]. 2020;10(2):194–8. Available from: <https://doi.org/10.1016/j.jobcr.2020.04.010>.
39. Bharali K, Das M, Nongthombam RS, Kumar A, Quazi SSN. Occlusal considerations in implant dentistry. *Int J Med Biomed Stud* [Internet]. 2020;4(7):123–7. Available from: <https://doi.org/10.32553/ijmbs.v4i7.1327>.
40. Ritter RG. Multifunctional uses of a novel ceramic-lithium disilicate. *J Esthet Restor Dent* [Internet]. 2010;22(5):332–41. Available from: <https://doi.org/10.1111/j.1708-8240.2010.00362.x>.
41. Tsujimoto A, Barkmeier WW, Fischer NG, Nojiri K, Nagura Y, Takamizawa T, et al. Wear of resin composites: Current insights into underlying mechanisms, evaluation methods

and influential factors. *Jpn Dent Sci Rev* [Internet]. 2018;54(2):76–87. Available from: <https://doi.org/10.1016/j.jdsr.2017.11.002>.

42. Sajjad A. Computer-assisted design/computer-assisted manufacturing systems: A revolution in restorative dentistry. *J Indian Prosthodont Soc* [Internet]. 2016;16(1):96. Available from: <https://doi.org/10.4103/0972-4052.164905>.

43. Schweiger J, Edelhoff D, Güth JF. 3D printing in digital prosthetic dentistry: An overview of recent developments in additive manufacturing. *J Clin Med* [Internet]. 2021;10(9):2010. Available from: <https://doi.org/10.3390/jcm10092010>.

44. Redazione. Multilayer ceramic layering: Systematic approach technique for the ceramic build up between the facial and the lingual area - Giuseppe Romeo [Internet]. Giuseppe Romeo. 2021. Available from: <https://giusepperomeo.net/multilayer-ceramic-layering-systematic-approach-technique-for-the-ceramic-build-up-between-the-facial-and-the-lingual-area/>.

45. Gulati M, Govila V, Anand V, Anand B. Implant Maintenance: a clinical update. *ISRN Dent* [Internet]. 2014;2014:1–8. Available from: <https://doi.org/10.1155/2014/908534>.

46. Mavrogenis AF, Dimitriou R, Parvizi J, Babis G. Biology of implant osseointegration. *ResearchGate* [Internet]. 2009. Available from: https://www.researchgate.net/publication/26282273_Biology_of_implant_osseointegration.

47. Abdulghafor MA, Mahmood MK, Tassery H, Tardivo D, Falguiere A, Lan R. Biomimetic coatings in implant dentistry: a quick update. *J Funct Biomater* [Internet]. 2023;15(1):15. Available from: <https://doi.org/10.3390/jfb15010015>.

48. Gupta D. Growth factors and dental implantology. In: *Dentistry* [Internet]. 2022. Available from: <https://doi.org/10.5772/intechopen.101082>.

6. CURRICULUM VITAE

Misbah Morason Masih, born on July 10, 1995, in Kuwait and of Pakistani origin, moved to the UK in 2001. She graduated with First Class Honours in Biomedical Science from Essex University in 2017, where her passion for healthcare and research emerged. Driven by a desire to blend science with patient care, Misbah pursued Dentistry in Zagreb, gaining significant clinical experience and a profound appreciation for global health issues.

Fluent in Urdu, Punjabi, and Hindi, and conversant in Spanish, Croatian, and Turkish, Misbah's cultural diversity is matched by her active university life, where she played basketball and cricket, and won a UWCB charity boxing match. Her love for the arts is evident in her self-taught piano skills and henna art.

Deeply committed to community service, Misbah has participated in numerous mission trips, focusing on providing dental care and education to underserved communities. Her involvement extends to her church, where she actively participates in annual camps and activities.

Misbah's life reflects her dedication to personal growth, service, and faith. She aims to integrate these values into her future career as a dentist, aspiring to excel in clinical practice while contributing to global health initiatives, using her skills to make a meaningful impact on the world.