

Effect of photodynamic therapy on the healing of periapical lesions after root canal retreatment: 1-year follow up randomized clinical trial

Pažin, Boris; Lauc, Tomislav; Bago, Ivona

Source / Izvornik: **Photodiagnosis and Photodynamic Therapy, 2024, 45**

Journal article, Published version

Rad u časopisu, Objavljena verzija rada (izdavačev PDF)

<https://doi.org/10.1016/j.pdpdt.2023.103907>

Permanent link / Trajna poveznica: <https://um.nsk.hr/um:nbn:hr:127:583002>

Rights / Prava: [Attribution-NonCommercial-NoDerivatives 4.0 International/Imenovanje-Nekomercijalno-Bez prerada 4.0 međunarodna](#)

Download date / Datum preuzimanja: **2024-11-04**



Repository / Repozitorij:


[University of Zagreb School of Dental Medicine
Repository](#)





Contents lists available at ScienceDirect

Photodiagnosis and Photodynamic Therapy

journal homepage: www.elsevier.com/locate/pdpdt

Effect of photodynamic therapy on the healing of periapical lesions after root canal retreatment: 1-year follow up randomized clinical trial

Boris Pažin^a, Tomislav Lauc^b, Ivona Bago^{c,*}^a Department of Endodontics, Oral Patology and Periodontology, Dental Polyclinic Zagreb, Croatia^b Dental Polyclinic Apolonija, Zagreb, Croatia^c Department of Endodontics and Restorative Dentistry, School of Dental Medicine, University of Zagreb, Gundulićeva 5, Zagreb 10 000, Croatia

ARTICLE INFO

Keywords:

Root canal retreatment
Photodynamic therapy
Ultrasonic irrigation

ABSTRACT

Background: The aim of this randomized clinical trial was to evaluate the effects of photodynamic therapy (PDT) after traditional activated final irrigation protocol (ultrasonically activated irrigation, UAI) on periapical lesion healing after single-visit root canal retreatment.

Methods: We included 36 patients with asymptomatic chronic apical periodontitis with periapical lesions larger than 5 mm and teeth sensitive to percussion and palpation, who had previous root canal treatment. All patients who signed informed consent underwent cone-beam computed tomography (CBCT) to determine and calculate the preoperative volume of the periapical lesion. Patients were randomly distributed into two groups according to the final disinfection protocol: Group 1; UAI (NaOCl, EDTA, and NaOCl), Group 2; UAI + PDT. All patients underwent single-visit root canal retreatment using rotary instrumentation and standardized irrigation (3 % NaOCl) by the same endodontist. The root canals were filled with epoxy resin-based sealer and single-cone gutta-percha, followed by control radiography. After one year, a new CBCT scan of the teeth was performed to calculate the reduction in the initial periapical lesion as a measure of periapical healing. For the statistical analysis, the chi-square test variants, Fisher's exact test and the Fisher-Freeman-Halton test were used at the level of significance set at 5 %.

Results: There were no significant differences between the groups in terms of age, sex, preoperative and post-operative lesion volume ($p > 0.05$), and reduction of periapical lesion volume (median, 86.98 % for UAI and 79.72 % for UAI+PDT) ($p = 0.970$). Additional use of PDT after UAI did not contribute to the healing of periapical lesions.

Conclusion: The UAI and UAI+PDT protocols had equal effects on healing of periapical lesion.

1. Introduction

Photodynamic therapy (PDT) is an additional antibacterial strategy in root canal treatment and retreatment, based on the photochemical action of low levels of laser energy against microorganisms that remain after conventional chemo-mechanical procedures [1,2]. In dental literature, it is also termed photoactivated disinfection (PAD). The antimicrobial action of PDT results from interaction between a nontoxic dye (photosensitizers, PS: toluidine blue, methylene blue), which binds to bacterial cells, and visible laser light of appropriate wavelengths leading to "higher energy state". Because of this interaction and the presence of surrounding oxygen, highly reactive oxygen species (peroxide or superoxide anions) are created and cause direct cell death. The entire

damage process depends on the oxygen and PS concentrations [2,3] and does not affect human gingival fibroblasts or osteoblasts [4].

The use of PDT in root canal treatment has been shown to be effective in bacterial eradication in many *in vivo*, *in vitro*, and *ex vivo* studies [2]. However, recent systematic reviews have reported conflicting conclusions regarding the advantage of PDT inside root canals [5–8]. In most *in vitro* studies, PDT significantly eliminated bacteria and their toxins when used as an adjunctive method [9–11]; however, its efficacy against bacterial biofilms is questionable [11]. *In vivo* studies also showed that the additional application of PDT enhances root canal disinfection but has limitations against mature biofilms [2,6] and sometimes similar efficacy as 2.25 % NaOCl [12]. According to a recent review by Meire et al. [13], PDT does not have a significant effect on the occurrence of

* Corresponding author.

E-mail address: bago@sfzg.hr (I. Bago).<https://doi.org/10.1016/j.pdpdt.2023.103907>

Received 26 August 2023; Received in revised form 22 November 2023; Accepted 22 November 2023

Available online 25 November 2023

1572-1000/© 2024 Published by Elsevier B.V. This is an open access article under the CC BY-NC-ND license (<http://creativecommons.org/licenses/by-nc-nd/4.0/>).

postoperative pain during the first 7 days postoperatively; however, Coelho et al. [14] reported its effect during the first three days after single-visit root canal treatment.

The clinical impact of PDT on the healing of periapical lesions is unknown [2,13]. In a recent animal study, two-session root canal treatment resulted in smaller periapical lesions at the 3-month follow-up than single-visit root canal treatment with PDT [15]. In a randomized clinical study by de Miranda et al. [16], adjunctive PDT provided better periapical healing after 6-month of follow-up, evaluated using periapical radiography. As stated recently in a critical analysis of research methodology to study disinfection protocols, the main interest in clinical endodontic studies should be healing of apical periodontitis [17,18].

This study aimed to analyze the efficacy of PDT, used as an additional antibacterial strategy in single-visit root canal retreatment, on the healing of periapical lesion evaluated by CBCT.

2. Materials and methods

This randomized clinical study was carried out in a Dental Polyclinic between June 2019 and December 2021. The study was registered at clinicaltrials.gov id 021/002-19-208 NCT04072926. Guidelines for randomized trials in Endodontics PIRATE 2020 was followed [19] (Fig. 1).

We calculated the sample size using ANOVA based on two groups, three repeated measures, and significance level $\alpha = 0.05$ with statistical power of 90 %. The analysis showed a minimum sample size of 11 participants per group.

2.1. Patients selection

Patients selected for this single-blinded randomized clinical trial

were regular patients, who had been referred to the Department of Endodontics at the Dental Polyclinic by their general dentist for root canal retreatment. First selection of the participants was made based on the inclusion and exclusion criteria (Table 1) [20]. All patients were examined clinically and the teeth were analyzed radiographically using periapical radiography. Patients received oral and written information about the study, and those, who agreed to participate, had to sign an informed consent. The patients could withdraw from participating in the study without any particular reason. The study protocol was approved by the Local Ethics Committee, number N₀ 05-PA-30-VI-/2019, 12.04.2019, and the whole study protocol was according to the Declaration of Helsinki [21].

Of 64 patients examined, 36 aged between 20 and 65 years (20 men and 16 women) were included in this study (Fig. 1). These patients (study participants) were referred to do Cone Beam Computed Tomography (Cranex 3DX, Soredex, Tusula, Finland) (CBCT, endo-mode with

Table 1
Inclusion and exclusion criteria for participants in this study.

INCLUSION CRITERIA	EXCLUSION CRITERIA
Symptoms of periapical disease after endodontic treatment	Immunocompromised patients
Teeth sensitive to percussion and palpation	Pregnancy
Swelling and sinus tract	Teeth with pocket depth larger than 3 mm
Asymptomatic inadequate endodontic treatment	Teeth with signs and symptoms of vertical root fracture
Apical periodontitis (AP) larger than 5 mm in diameter based on initial periapical radiograph	Severely damaged teeth with no chance for prosthetic or restorative rehabilitation
	Antibiotic intake in the last month

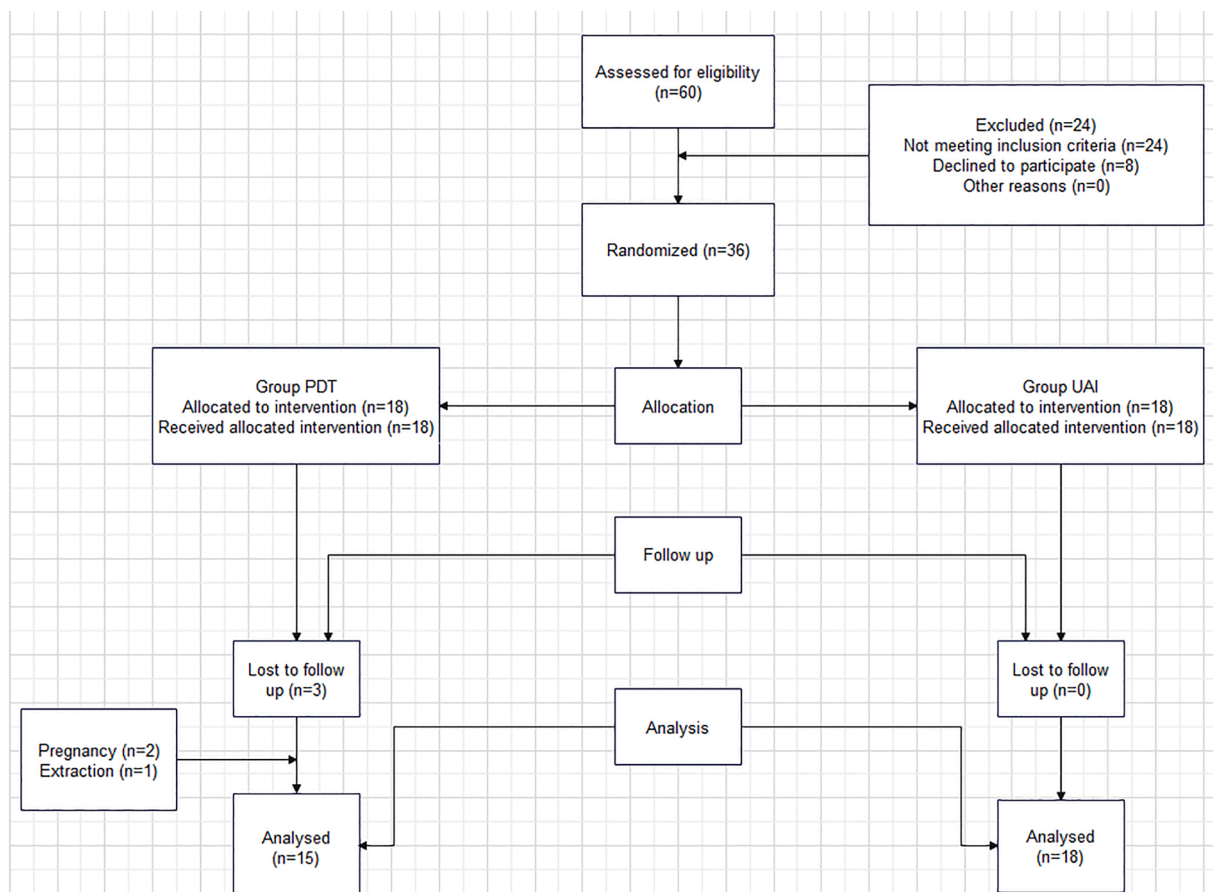


Fig. 1. Flowchart of the study according to PRIRATE guidelines 2020 [1].

5 × 5 field of view and 75 µm voxel size) of the tooth to determine the exact preoperative volume of apical periodontitis (AP).

2.2. Clinical procedures

An investigator (BP), a specialist in endodontics with more than 15 years of experience, conducted single-visit root canal retreatment in all patients. After inclusion in the study, the participants were randomly distributed into two experimental groups depending on the final root canal disinfection protocol used:

Group 1. Ultrasonically activated irrigation (UAI)

Group 2. UAI + PDT

The randomization process was conducted using the wheel decide program (www.wheeldecide.com). The study was single-blinded, meaning that the patients were unaware of the group to which they were allocated.

The clinical procedures were standardized for both groups. Root canal retreatment was performed under local anesthesia (Articain 4 % with Epinephrine 1:100,000, one ampoule, Ubistesin™ forte, 3 M ESPE, Germany) and rubber dam isolation. The traditional access opening was performed under rubber dam isolation. All caries was removed using pear-shaped diamond and round carbide burs under water coolant. In cases where there was a significant loss of coronal tooth structure, class I cavities were reconstructed using a composite material (Clearfill Majesty ES-2 Classic, Kuraray America, Inc. Suite, USA). The working field was disinfected with 5 % NaOCl.

The root canal retreatment was performed with R-endo 1, 2, and 3 rotary files (MICRO-MEGA, Cedex, France) using an endomotor set at 300 rpm and 200 Ncm, according to the manufacturer's recommendations. During retreatment, the root canals were irrigated with 3 % NaOCl (30 G needle, Steri Irrigation Tips, DiaDent; Netherlands). The retreatment was considered complete when no signs of remaining gutta-percha were visible on the instruments or in the canal. The working length was determined and measured using a K-file size #10 or #15 up to the apical foramen (value 0 on the apex locator) on Dualpex apex locator (MICRO-MEGA, Cedex, France). Then, the canals were instrumented up to the apical foramen using 2Shape 1 and 2Shape 2 instruments (2Shape, MICRO-MEGA, Cedex, France) and 5 ml of 3 % NaOCl per canal. Endomotor setup was 300 rpm and 200 Ncm. The presence of clean dentinal shavings, clear irrigant, and glassy smooth walls were the preferred indicators of adequate cleaning of the root canals. Additionally, apical cleaning was confirmed when clean dentinal debris was present at the tip of the rotary instrument.

After completion of instrumentation, the final disinfection protocol included: irrigation with 3 ml of 3 % NaOCl for 30 s, followed by 3 ml of 15 % ethylenediaminetetraacetic acid (EDTA) for 60 s, and finally, 3 ml of 3 % NaOCl for 30 s [22,23]. All irrigation was performed using 30 G needle (30 G needle, Steri Irrigation Tips, DiaDent; Netherlands) and a 2 ml syringe. After each irrigation step and before the next irrigant, the excess irrigant in the root canal was aspirated using 30 G needle and a syringe.

In Group 1 (UAI), EDTA and NaOCl irrigants in the final disinfection protocol were constantly activated using an EndoUltra device 3 (MICRO-MEGA, Cedex, France) with an ultrasonic non-cutting tip placed at 3 mm from the working length. The irrigant was delivered into the root canal, and the ultrasonic device was constantly activated, 30 s for NaOCl and 60 s for EDTA. During activation, irrigants were constantly delivered using 30 G needle and a syringe.

In Group 2 (UAI + PDT), the irrigants were activated in the same manner as explained for Group 1 but with the additional application of photodynamic therapy (PDT) after irrigation. The PDT was applied using an HF diode laser (diode laser 660 nm, 100 mW 60 s/root canal, LASER HF COMFORT; HAGER&WERKEN, Duisburg, Germany) set at continuous mode. First, the PS, Toluidine blue (HF EndoPDT solution,

Hager&Werken), was applied in the root canal and distributed along the dentinal walls using a sterile hand K-reamer size #15. The dye was left in the canal for 60 s, then, removed by rinsing the canal with 2 ml of sterile saline solution and dried with sterile paper points. Finally, the root canals were irradiated using a fiber tip (320 µm diameter), placed initially 2 mm from the working length, and then moved rotationally for 60 s with rotational motion from the apical to the coronal direction.

In the same session, the root canals were obturated using an epoxy resin-based sealer (AH Plus, Dentsply Sirona, Germany) and gutta-percha cones (MICRO-MEGA, Cedex, France) using a single-cone obturation technique. The access cavity was temporarily sealed with a glass ionomer (Fuji IX; GC Corporation, Tokyo, Japan).

2.3. Cone beam computed tomography evaluation

First author (BP), who did the clinical procedures, was not involved in the CBCT analysis. All included patients underwent Cone Beam Computed Tomography (CBCT) to determine the exact volume of the AP before the procedure (Field of view 5 × 5) (Initial CBCT) and one year after root canal filling (Control CBCT). All scans were performed using the same device with standardized parameters (Endo Mode, voxel size 0.085 mm, 450 mGY /mm3, 6.3 mA, 90 kV, 8.7 s), analysis of endodontic space, and evaluation of periapical lesions. Radiological volumetric assessment of periapical lesion healing was performed using CBCT analysis by obtaining the exact lesion volume preoperatively and one year after the retreatment. CBCT scans were evaluated and periapical lesions calculated by two independent researchers, who were not involved in the study protocol. If the volume of the measured lesions differed between researchers, the mean value was recorded. In addition, the initial and control CBCT scans were analyzed at an interval of more than 1 week. Volumetric analysis was performed in the 3D mode of On-Demand software with semiautomatic segmentation and automatic measurement of the grey intensity of the lesion [20]. For the defect area segmentation and volume calculations, the highest resolution using slice thickness and interval of 0.125 mm were used. A grayscale value range selection tool was used for selecting periradicular defects. For multirooted tooth with more than one periapical lesion, the individual volumes of the lesions were added together [24]. After 1 year of root canal retreatment, the follow-up measurement was done. Periapical radiolucency with volume less than twice the width of the periodontal ligament was counted a 0-mm³ defect size and considered healed periapical lesions [24]. Individual defect volumes in multirooted teeth were added together [24]. Cases where periapical radiolucency reduced in size or was absent was classified as healing cases. All CBCT analysis was done on the same computer.

2.4. Statistical analysis

For the statistical analysis, the chi-square test variants, Fisher's exact test and the Fisher-Freeman-Halton test were used at the level of significance set at 5 %.

3. Results

By the end of the study, three participants from group 2 (UAI + PDT) dropped out of the study because of pregnancy (two cases) and extraction (one case). Finally, 33 patients (recall rate, 90 %) were reexamined at 12-month follow-up.

Initial analysis did not show statistically significant differences in age and initial volume of periapical lesions between group 1 (UAI) and group 2 (UAI + PDT) ($p = 0.574$ and $p = 0.828$, respectively). Overall, 23 multi-canals and 10 single-canal teeth were included in the study.

There was no significant difference in the volume of apical periodontitis and no reduction rate between the groups: median reduction rate of AP 86.98 % in UAI, 79.72 % in the UAI + PDT group ($p = 0.601$, $p = 0.910$) after one year (Table 2). Reduction or complete healing of AP

Table 2

Descriptive statistics showing initial volume of apical periodontitis (AP) (mean, minimum, maximum, and median) and control volume of AP at 1-year follow up, and reduction rate of the AP volume.

Group		Mean	SD	Min	Max	Percentiles		
						25th	50th (Median)	75th
Age (years)	PDT	38.40	11.76	24.00	62.00	30.00	35.00	45.00
	UAI	39.44	11.92	20.00	66.00	31.50	40.00	42.00
Initial volume of AP	PDT	520.99	590.75	152.62	2566.06	261.85	320.53	572.45
	UAI	1336.83	3573.72	116.71	15,549.90	188.92	330.16	975.73
Control volume of AP after 1 year	PDT	87.15	86.91	0.00	279.31	0.00	70.73	158.01
	UAI	635.32	1995.56	0.00	8575.65	0.00	30.57	355.34
Reduction rate of the volume of AP (%)	PDT	71.22	29.12	12.81	100.00	54.32	79.72	100.00
	UAI	69.50	34.87	11.13	100.00	37.23	86.98	100.00

AP: apical periodontitis, SD: standard deviation, min: minimum, max: maximum.

was recorded in 92.60 % of the cases, 100 % in the UAI + PDT group and 86.7 % in the UAI group ($p = 0.970$). Overall, complete healing was recorded in 39.39 % of cases, incomplete healing in 60.61 % and failure in 6.06 %. In the UAI group, eight out of 18 cases had complete healing (44.44 %), five cases showed the reduction of the lesion more than 50 % of initial volume, three cases showed reduction of the lesion less than 50 % of initial volume, and in two cases (11.11 %), there was enlargement of the initial lesion volume meaning failure. In the PDT group, no failure was recorded, and five patients had complete healing (33.33 %), seven patients had reduction of the lesion more than 50 % of initial lesion volume, and three patients had minimal reduction of initial lesion volume.

4. Discussion

Healing of apical periodontitis is the primary outcome of interest in clinical endodontics [17]; therefore, more clinical studies with standardized clinical protocols are necessary, especially those evaluating disinfection protocols, including PDT [2,23]. This randomized clinical trial evaluated the clinical benefits of PDT in the healing of AP after single-visit retreatment.

The results of this study did not show any significant benefit of the additional application of PDT after UAI in the final disinfection protocol for the reduction of AP after one year of follow-up. Overall, the complete healing of apical periodontitis shown on the CBCT scans was 48.15 %, with 53.33 % in the UAI group and 33.33 % in the PDT group. Healing cases (reduction in AP) was recorded in 92.60 % of cases, with two cases of unfavorable outcomes (failure) in the UAI group. Brochado Martins et al. [25] reported, in a retrospective study, a similar percentage of healing cases (86.7 %) on CBCT scans 12 months after root canal retreatment, implying similar treatment outcomes in both groups in this study. To the best of our knowledge, this is the first study using CBCT to evaluate the influence of PDT on the healing of periapical lesions. Most previous clinical studies on PDT evaluated its benefit in terms of antibacterial efficacy, showing a significant reduction in endodontic bacteria, including *Enterococcus faecalis*, which is found in more than 80 % of cases requiring retreatment [2,15,26]. In this study, we did not evaluate the antimicrobial status of the root canals after the disinfection protocol; therefore, it was not possible to examine the dependence of these two variables, which should be considered in future studies. However, the results of this study can be interpreted in several ways. First, PDT was used in this study in a one-visit root canal treatment. On the other side, according to Borsatto et al. [15], PDT, applied in a two-visit root canal treatment with a calcium hydroxide intracanal dressing between visits, causes greater healing of periapical lesions at 90 days compared to that applied at one session. A similar observation was reported by Trindade et al. [27], who found that, PDT used with an inter-appointment calcium hydroxide, provided slightly stimulation of periapical healing. However, there was no difference in lesion repair with or without PDT in radiographic and histological analyses. In the same study, PDT did not improve the reduction of bacteria in root canals compared to NaOCl

alone. Therefore, there might be limitations to the efficacy of PDT under clinical conditions. Low concentrations of oxygen in the canals, especially in intracanal complexes, cause blockage of cytotoxic oxygen derivatives and limited penetration of PS in deep areas of the root canals [2]. All these factors may have compromised the efficacy of PDT in this study. Finally, there is a no clear consensus on recommending a protocol of PDT in clinical practice [2] because different PS, irradiation doses, and light sources have been used in different studies [2].

In this study, PDT was used after UAI in the final disinfection protocol and compared to the use of UAI alone in the same protocol. UAI is currently the most popular irrigant activation technique [23], which has been shown to improve the root canal disinfection protocol in many *in vitro* studies [28]; however, clinical trials have not detected any improvement in root canal disinfection compared to conventional irrigation in terms of antimicrobial efficacy, and no clinical study has found any improvement in long-term healing outcomes [28,29]. We used UAI as a control group to the additional PDT protocol because we expected highly virulent bacterial flora organized into bacterial biofilms in clinical cases requiring retreatment [30,31]. Organization of bacteria in biofilms located in anatomic intricacies of the root canal system and the difficulty in eliminating them is the main challenge for irrigation protocol. On the other side, the limitations of mechanical and passive irrigation techniques in complex root canal anatomies are well known, with significant amount of intracanal dentin still covered with debris and bacterial biofilm [32]. Furthermore, recent results showed that for cleaning complex intracanal areas, the energy providing fluid movement is more important than higher concentration of NaOCl [33]. According to recent review by Boutsioukis and Ariaz-Moliz [17], delivery of the irrigants using a syringe and needle and activation by an ultrasonic file are the most popular irrigation methods. Therefore, we consider UAI as important technique in the elimination of bacteria in retreatment cases and also a good enough alternative to PDT. The results did not show that additional use of PDT after UAI contribute significantly to the healing of periapical lesions. However, PDT showed to have better results in terms of greater number of complete healing in more patients and no failure in any compared to only UAI. This study did not evaluate the microbiological status of the canals before and after the treatment so we can not make conclusion regarding the antibacterial efficacy of the two tested protocols.

The results of this study can be discussed based on certain points in the protocol. In this study, we used a continuous UAI protocol with only one cycle of activation with EDTA (60 s) and NaOCl (30 s). Various UAI protocols have been discussed in the literature [23,28], the most popular being 1×60 s. However, other protocols have been used, including 3×20 s and 1×30 s. An interesting finding was published recently by Retsas et al. [34], who showed that the number of cycles of UAI activation was essential for the removal of biofilms, rather than the total activation time. Specifically, the amplitude of the signal that the ultrasonic handpiece receives is larger during the first milliseconds than later on. Therefore, the initiation of activation is crucial for the cleaning efficacy of UAI. Verma et al. [35] found better treatment outcomes

(clinical and radiographic success rates) after repeated UAI than in a control group without UAI.

In this study, we used CBCT to quantitatively measure the healing rate of apical periodontitis. CBCT is a high-sensitive scanning technique which can provide precise changes of bone tissue over time and, thus, objective presentation of treatment outcome [20,36]. In a recent study by Davies et al. [20], CBCT diagnosis provided a significantly lower number of favorable retreatment outcomes than periapical diagnosis. It has been stated that CBCT scans are more accurate and sensitive at diagnosing apical periodontitis than periapical radiographs [37,38]. Therefore, CBCT should be considered for detecting apical lesions and evaluation of treatment outcome during follow-up [38]. The same lesion size might demonstrate a slower healing rate in CBCT than in periapical radiography [20]. In this study, a 12-month follow up was used for the evaluation of treatment outcome. Although this follow-up period may be insufficient to determine the full healing potential, it is in accordance with the recommendation of the quality guidelines for outcome assessment of nonsurgical treatment of apical periodontitis (European Society of Endodontology, 2006). All radiation doses for CBCT scanning in this study adhered to the rule "as low as reasonably achievable" (ALARA). Patel et al. [39] showed that the use of CBCT with ethical approval is justified in the clinical use of small FOV CBCT scans for research purposes, assessment of treatment with new protocols, and disinfection techniques, which will result in a more objective treatment outcome.

This study has limitations that have to be taken into consideration when discussing the clinical significance of the results. First, this study included patients with different types of teeth, single-rooted and multi-rooted distributed among both groups. In the UAI group, 11 multi-canals teeth (1 premolar and 10 molars) and seven single-canal teeth were treated, and in the UAI+PDT group, 12 multi-canals teeth (11 molars and 1 premolar) and three single-canal teeth. Laukkanen et al. [40], reported higher success rate of root canal treatment in anterior teeth and premolars compared to molars. This is due to complex anatomy in molars, especially in the apical part, which is considered difficult to clean, disinfect and obturate [32]. Therefore, different canal anatomy of the teeth could have influenced the results of this study. Furthermore, this study evaluated the additional application of the PDT after the UAI of the final irrigation protocol. UAI is a "golden standard" in activated irrigation and was recommended as an improved irrigation technique [17,28]. However, UAI as an advanced technique may not have left room for PDT to show its full potential in root canal irrigation. Therefore, future studies should evaluate the benefit of the additional application of PDT after conventional irrigation using syringe and needle. This study did not evaluate the microbiological status of the canals before and after the treatment so we can not make conclusion regarding the antibacterial efficacy of the two tested protocols.

5. Conclusion

No significant clinical benefits of PDT, used as an additional protocol after UAI, existed in the healing of apical periodontitis after 1-year follow up of root canal retreatment.

CRedit authorship contribution statement

Boris Pažin: Methodology, Investigation, Data curation. **Tomislav Lauc:** Writing – review & editing, Software. **Ivona Bago:** Writing – original draft, Visualization, Supervision, Resources, Project administration, Funding acquisition.

Conflict of Interest Statement

The authors have stated explicitly that there are no conflicts of interest in connection with this article.

Acknowledgment

This study was performed and financed within the research project "Experimental and clinical evaluation of laser activated photoacoustic streaming and photoactivated disinfection in endodontic treatment" NO 5303 approved by the Croatian Science Foundation.

References

- [1] H. Gursoy, C. Ozcakar-Tomruk, J. Tanalp, S. Yilmaz, Photodynamic therapy in dentistry: a literature review, *Clin. Oral Investig.* 17 (2013) 1113–1125.
- [2] G. Plotino, N.M. Grande, M. Mercade, Photodynamic therapy in endodontics, *Int. Endod. J.* 52 (6) (2019) 760–774, <https://doi.org/10.1111/iej.13057>.
- [3] K. Konopka, T. Goslinski, Photodynamic therapy in dentistry, *J. Dent. Res.* 86 (2007) 694–707.
- [4] Y. Xu, M.J. Young, R.A. Battaglino, et al., Endodontic antimicrobial photodynamic therapy: safety assessment in mammalian cell cultures, *J. Endod.* 35 (2009) 1567–1572.
- [5] S.H. Siddiqui, K.H. Awan, F. Javed, Bactericidal efficacy of photodynamic therapy against *Enterococcus faecalis* in infected root canals: a systematic literature review, *Photodiagn. Photodyn. Ther.* 10 (2013) 632–643.
- [6] M. Pourhajbagher, A. Bahador, Adjunctive antimicrobial photodynamic therapy to conventional chemo-mechanical debridement of infected root canal systems: a systematic review and meta-analysis, *Photodiagn. Photodyn. Ther.* 26 (2019) 19–26.
- [7] L.P. Nunes, G.P. Nunes, T.M. Ferrisse, H.B. Strazzi-Sahyon, L.T.Á. Cintra, P.H. Dos Santos, G. Sivieri-Araujo, Antimicrobial photodynamic therapy in endodontic re-intervention: a systematic review and meta-analysis, *Photodiagn. Photodyn. Ther.* 39 (2022), 103014, <https://doi.org/10.1016/j.pdpdt.2022.103014>.
- [8] A.F.A. Barbosa, C.O. de Lima, T. Moreira, L.M. Sassone, T.K.D.S. Fidalgo, E.J.N. L. Silva, Photodynamic therapy for root canal disinfection in endodontics: an umbrella review, *Lasers Med. Sci.* 37 (6) (2022) 2571–2580, <https://doi.org/10.1007/s10103-022-03569-1>.
- [9] Y. Vendramini, A. Salles, F.F. Portella, M.C. Brew, L. Steier, J.A.P. de Figueiredo, C. S. Bavaresco, Antimicrobial effect of photodynamic therapy on intracanal biofilm: a systematic review of *in vitro* studies, *Photodiagn. Photodyn. Ther.* 32 (2020), 102025, <https://doi.org/10.1016/j.pdpdt.2020.102025>.
- [10] E.G. Alves-Silva, R. Arruda-Vasconcelos, L.M. Louzada, A. de-Jesus-Soares, C.C. R. Ferraz, J.F.A. Almeida, M.A. Marciano, C. Steiner-Oliveira, J.M.M. Santos, B. P. Gomes, Effect of antimicrobial photodynamic therapy on the reduction of bacteria and virulence factors in teeth with primary endodontic infection, *Photodiagn. Photodyn. Ther.* 41 (2023), 103292, <https://doi.org/10.1016/j.pdpdt.2023.103292>.
- [11] D. Hoedke, C. Enseleit, D. Gruner, H. Dommisch, S. Schlafer, I. Dige, K. Bitter, Effect of photodynamic therapy in combination with various irrigation protocols on an endodontic multispecies biofilm *ex vivo*, *Int. Endod. J.* 51 (Suppl 1) (2018) e23–e34.
- [12] S.J. Bonsor, R. Nichol, T.M. Reid, G.J. Pearson, An alternative regimen for root canal disinfection, *Br. Dent. J.* 201 (2) (2006) 101–105, discussion 98; quiz 120.
- [13] M.A. Meire, J.D. Bronzato, R.A. Bomfim, B.P.F.A. Gomes, Effectiveness of adjunct therapy for the treatment of apical periodontitis: a systematic review and meta-analysis, *Int. Endod. J.* 26 (2022), <https://doi.org/10.1111/iej.13838>. Epub ahead of print.
- [14] M.S. Coelho, L. Vilas-Boas, P.Z. Tawil, The effects of photodynamic therapy on postoperative pain in teeth with necrotic pulps, *Photodiagn. Photodyn. Ther.* 27 (2019) 396–401, <https://doi.org/10.1016/j.pdpdt.2019.07.002>.
- [15] M.C. Borsatto, A.M. Correa-Afonso, M.P. Lucisano, R.A. Bezerra da Silva, F. W. Paula-Silva, P. Nelson-Filho, L.A. Bezerra da Silva, One-session root canal treatment with antimicrobial photodynamic therapy (aPDT): an *in vivo* study, *Int. Endod. J.* 49 (6) (2016) 511–518, <https://doi.org/10.1111/iej.12486>.
- [16] R.G. de Miranda, A.P.V. Colombo, Clinical and microbiological effectiveness of photodynamic therapy on primary endodontic infections: a 6-month randomized clinical trial, *Clin. Oral Investig.* 22 (4) (2018) 1751–1761.
- [17] C. Boutsoukakis, M.T. Arias-Moliz, L.E. Chávez de Paz, A critical analysis of research methods and experimental models to study irrigants and irrigation systems, *Int. Endod. J.* 55 (Suppl 2) (2022) 295–329, <https://doi.org/10.1111/iej.13710>. Suppl 2.
- [18] A. Azarpazhooh, A. Sgro, E. Cardoso, M. Elbarbary, N. Laghapour Lighvan, R. Badewy, G. Malkhassian, H. Jafarzadeh, H. Bakhtiar, S. Khazaei, A. Oren, M. Gerbig, H. He, A. Kishen, P.S. Shah, A scoping review of 4 decades of outcomes in nonsurgical root canal treatment, non-surgical retreatment, and apexification studies- part 2: outcome measures, *J. Endod.* 48 (2022) 29–39.
- [19] V. Nagendrababu, H.F. Duncan, L. Bjørndal, T. Kvist, E. Priya, J. Jayaraman, S. J. Pulikkotil, M. Pigg, D.K. Rechenberg, M. Vaeth, P.M.H. Dummer, PRIRATE 2020 guidelines for reporting randomized trials in endodontics: a consensus-based development, *Int. Endod. J.* 53 (6) (2020) 764–773.
- [20] A. Davies, F. Mannocci, P. Mitchell, M. Andiappan, S. Patel, The detection of periapical pathoses in root filled teeth using single and parallaxperiapical radiographs versus cone beam computed tomography – a clinical study, *Int. Endod. J.* 48 (6) (2015) 582–592.
- [21] WMA, World, Declaration of Helsinki. Ethical principles for medical research involving human subjects, *Jahrb. Wiss. Ethik* 14 (2009), <https://doi.org/10.1515/9783110208856.233>.

- [22] Y. Shen, Y. Gao, J. Lin, J. Ma, Z. Wang, M. Haapasalo, Research on irrigation: methods and models, in: B. Bassrani (Ed.), *Endodontic Irrigation*, 1st edition, Springer, Cham, 2015, pp. 65–99.
- [23] C. Boutsoukias, M.T. Arias-Moliz, Present status and future directions - irrigants and irrigation methods, *Int. Endod. J.* 55 (Suppl 3) (2022) 588–612, <https://doi.org/10.1111/iej.13739>, Suppl 3.
- [24] T. Schloss, D. Sonntag, M.R. Kohli, F.C. Setzer, A Comparison of 2- and 3-dimensional healing assessment after endodontic surgery using cone-beam computed tomographic volumes or periapical radiographs, *J. Endod.* 43 (7) (2017) 1072–1079, <https://doi.org/10.1016/j.joen.2017.02.007>.
- [25] J.F. Brochado Martins, O. Guerreiro Viegas, R. Cristescu, P. Diogo, H Shemesh, Outcome of selective root canal retreatment-a retrospective study, *Int. Endod. J.* 56 (3) (2023) 345–355, <https://doi.org/10.1111/iej.13871>.
- [26] I. Bago Jurić, V. Plečko, D. Gabrić Pandurić, I Anić, The antimicrobial effectiveness of photodynamic therapy used as an adjunct to conventional endodontic re-treatment: a clinical study, *Photodiagn. Photodyn. Ther.* 11 (4) (2014) 549–555.
- [27] A.C. Trindade, J.A.P. de Figueiredo, S.D. de Oliveira, V.C. Barth Junior, S.W. Gallo, C. Follmann, C.F.B. Wolle, L. Steier, R.D. Morgental, J.B.B Weber, Histopathological, microbiological, and radiographic analysis of antimicrobial photodynamic therapy for the treatment of teeth with apical periodontitis: a study in rats' molars, *Photomed. Laser Surg.* 35 (7) (2017) 364–371, <https://doi.org/10.1089/pho.2016.4102>.
- [28] P.E. Căpută, A. Retsas, L. Kuijk, L.E. Chávez de Paz, C Boutsoukias, Ultrasonic irrigant activation during root canal treatment: a systematic review, *J. Endod.* 45 (1) (2019) 31–44, <https://doi.org/10.1016/j.joen.2018.09.010>, e13.
- [29] Y.H. Liang, L.M. Jiang, L. Jiang, X.B. Chen, Y.Y. Liu, F.C. Tian, X.D. Bao, X.J. Gao, M. Versluis, M.K. Wu, L. van der Sluis, Radiographic healing after a root canal treatment performed in single-rooted teeth with and without ultrasonic activation of the irrigant: a randomized controlled trial, *J. Endod.* 39 (2013) 1218–1225.
- [30] J.F. Siqueira Jr., Aetiology of root canal treatment failure: why well-treated teeth can fail, *Int. Endod. J.* 34 (2001) 1–10.
- [31] H. Zandi, A.K. Kristoffersen, D. Ørstavik, I.N. Rôças, J.F. Siqueira Jr., M Enersen, Microbial Analysis of Endodontic Infections in Root-filled Teeth with Apical Periodontitis before and after Irrigation Using Pyrosequencing, *J. Endod.* 44 (2018) 372–378.
- [32] J.F. Siqueira Jr., A.R. Pérez, M.F. Marceliano-Alves, J.C. Provenzano, S.G. Silva, F. R. Pires, G.C.S. Vieira, I.N. Rôças, F.R.F. Alves, What happens to unprepared root canal walls: a correlative analysis using micro-computed tomography and histology/scanning electron microscopy, *Int. Endod. J.* 51 (2018) 501–508.
- [33] T.C. Pereira, C. Boutsoukias, R.J.B. Dijkstra, X. Petridis, M. Versluis, F.B. de Andrade, W.J. van de Meer, P.K. Sharma, L.W.M. van der Sluis, M.V.R. So, Biofilm removal from a simulated isthmus and lateral canal during syringe irrigation at various flow rates: a combined experimental and computational fluid dynamics approach, *Int. Endod. J.* 54 (2021) 427–438.
- [34] A. Retsas, R.J.B. Dijkstra, L. van der Sluis, C. Boutsoukias, The Effect of the ultrasonic irrigant activation protocol on the removal of a dual-species biofilm from artificial lateral canals, *J. Endod.* 48 (6) (2022) 775–780, <https://doi.org/10.1016/j.joen.2022.03.005>.
- [35] A. Verma, R.K. Yadav, A.P. Tikku, A. Chandra, P. Verma, R. Bharti, V.K. Shakya, A randomized controlled trial of endodontic treatment using ultrasonic irrigation and laser activated irrigation to evaluate healing in chronic apical periodontitis, *J. Clin. Exp. Dent.* 12 (2020) e821–e829.
- [36] J.F. Brochado Martins, O. Guerreiro Viegas, R. Cristescu, P. Diogo, H Shemesh, Outcome of selective root canal retreatment-a retrospective study, *Int. Endod. J.* 56 (3) (2023) 345–355, <https://doi.org/10.1111/iej.13871>.
- [37] F.W.G. Paula-Silva, M.S. Junior, M.R. Leonardo, L.A.D. da Silva, P.R. Wesselink, Accuracy of periapical radiography and cone-beam computed tomography scans in diagnosing apical periodontitis using histo-pathological findings as a gold standard, *J. Endod.* 35 (2009) 1009–1012.
- [38] S. Patel, R. Wilson, A. Dawood, F. Foschi, F. Mannocci, The detection of periapical pathosis using digital periapical radiography and cone beam computed tomography – Part 2: a 1-year post-treatment follow-up, *Int. Endod. J.* 45 (8) (2012) 711–723.
- [39] S. Patel, C. Durack, F. Abella, H. Shemesh, M. Roig, K. Lemberg, Cone beam computed tomography in Endodontics - a review, *Int. Endod. J.* 48 (1) (2015) 3–15.
- [40] E. Laukkanen, M.M. Vehkalahti, A.K. Kotiranta, Impact of type of tooth on outcome of non-surgical root canal treatment, *Clin. Oral Investig.* 23 (11) (2019) 4011–4018.