

Prevention of peri-implant diseases

Gabrić, Dragana

Other document types / Ostale vrste dokumenata

Publication year / Godina izdavanja: **2015**

Permanent link / Trajna poveznica: <https://urn.nsk.hr/urn:nbn:hr:127:944321>

Rights / Prava: [In copyright](#) / [Zaštićeno autorskim pravom.](#)

Download date / Datum preuzimanja: **2025-02-28**



Repository / Repozitorij:

[University of Zagreb School of Dental Medicine
Repository](#)



PREVENTION OF PERI-IMPLANT DISEASES

Author: Assistant Professor Dragana Gabrić, DDM, PhD, Specialist in Oral Surgery, Department of Oral Surgery, School of Dental Medicine, University of Zagreb



Assistant Professor Dragana Gabrić, DDM, PhD

- 2004 Degree, Doctor of Dental Medicine, University of Zagreb
- 2005 Dean's Award for Study Success
- 2007 Oral Surgeon Trainee, Department of Oral Surgery, Clinical Hospital Center Zagreb
- 2010 PhD Degree, dissertation, field of experimental laser bone surgery
- 2011 Specialist in Oral Surgery, Department of Oral Surgery, Clinical Hospital Center Zagreb,
- 2013 Senior Research Scientist, Department of Oral Surgery, School of Dental

INTRODUCTION

The usage of dental implants in the therapy of complete and partial loss of teeth daily results in a growing number of complications and cases of peri-implant diseases, and consequential loss of implant stability and osseointegration. According to Brånemark, osseointegration is the bone ability to bond with the endosteal implant without soft tissue impo- sition (1). The successfulness and durability of the implant depend on

proper indication, good planning and execution of prosthetic suprastructure, the therapist's skill, but also on the patient's oral hygiene (2). Special attention is paid to general medical (general condition, nourishment level, age, current medication, metabolic diseases, hematologic diseases, heart and vascular system condition, bone metabolism problems, collagenosis, implant as a potential bacterial focus) and intraoral (anatomically unfavourable inter-jaw relation, changed occlusal and functional relations, pathological finding in jaw-bone, pathological changes of mucous membrane, xerostomia, macroglossia, untreated remaining teeth, poor oral hygiene) contraindications that have to be recognised during diagnostic and preparatory procedure. There are also time-limited contraindications (acute inflammatory disease and infection, pregnancy, temporary usage of certain medications, stressful situations of body and mind) and mentally conditioned contraindications (insufficient co-operation of the patient and failure to understand the therapy plan, alcohol or drug consumption, smoking, neuroses and psychoses, problematic patients) that also have to be taken into consideration (3). Although in numerous clinical cases implant placement results in long-term success, it does not guarantee absolute lack of complications, so it is necessary to consider the fact that complications are possible even after a successful implant placement. With regard to the course and maintenance of implants, which primarily means osseointegration of the implant and the patient's oral hygiene, biological complications occur in the form of peri-implant mucositis and peri-implantitis, as well as inflammations of soft and hard tissue (4).

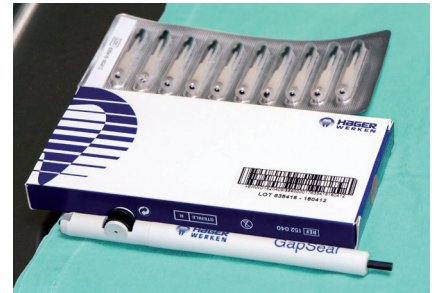

Fig. 1: GapSeal® (Hager & Werken, Duisburg, Germany) disposable sterile tips with applicator.

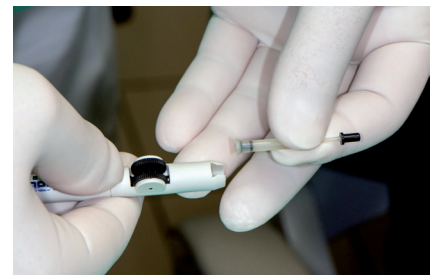


Fig. 2: Simple insertion of carpule into the applicator.

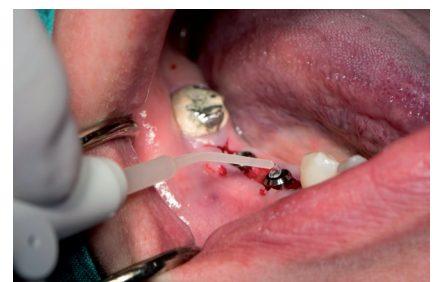

Fig. 3: Application of the material into the osseointegrated dental implant.

ETIOLOGY AND PREVALENCE OF PERI-IMPLANT DISEASES

Failure in therapy with dental implants can be divided into early, which occurs immediately after implantation, and late which occurs when the restoration supported by the implant is put in function. Early failure of the implant can be caused by: improper site preparation, bacterial contamination and extensive inflammation of the wound, unfavourable mechanical stability of the implant after placement and premature or inadequate implant burden. Late failures occur when there is a loss of osseointegration of previously stable and functional implant and it is a result of excessive burdening or infection (5). Prevalence of peri-implant diseases is difficult to determine because of the variation from 2 to 10 per cent of the cases of all implant insertions (5). The published research mentions the prevalence of peri-implant mucositis up to 48 per cent during the monitoring period from 9 to 14 years (6). There are numerous risk factors that can lead to the development of peri-implant mucositis and peri-implantitis. Some of these factors are the following: previous periodontal disease, poor plaque control, residual cement, smoking, genetic factors, diabetes, occlusal overload, alcohol consumption and connective tissue diseases (7-21).

DIVISION OF PERI-IMPLANT DISEASES

Peri-implant mucositis is a reversible inflammation restricted to soft tissue surrounding the implant, without signs of any loss of the supporting bone, which results from plaque accumulation. 39.4 per cent to 80 per cent of persons with dental implants experience it (22-24). Gingiva and mucosa around the implant respond to the colonisation of microbiota by developing apparent lesions i.e. by the infiltration of leukocytes in connective tissue. In comparison with a natural tooth, mucous membrane lesions spread more and progress apically, since the mucous membrane surrounding the implant contains less fibro-

blasts. The mucous membrane surrounding the implant is less efficient in restricting lesions connected with the plaque. A small number of fibroblasts fail to produce sufficient collagen and matrix during the reparatory stage which results in further advancement and spreading of inflamed infiltrate in the membrane surrounding the implant (5).

Peri-implantitis

Peri-implantitis is defined as an inflammatory process that affects the tissue surrounding osseointegrated implant in function and results in the loss of the supporting bone, and it is a consequence of the progression of peri-implant mucositis. Peri-implant tissue, unlike the tissue surrounding a healthy tooth, is organised more poorly, so progressive lesions connected with plaque are more difficult to stop (5).

It occurs as a consequence of overheating during osteotomy, implant overload following the implant-prosthetic rehabilitation and contamination of dental implant during the production or insertion. Radiolucency is radiologically visible in the coronal part of the implant, and it further progresses towards the top of the implant (5).

Retrograde peri-implantitis

Retrograde peri-implantitis is defined as a clinically symptomatic periapical lesion diagnosed as a radiolucency that develops shortly after implant insertion, and the coronal portion of the implant sustains a normal bone-to-implant interface (25). This condition was first described by McAllister et al (26). The etiology of the condition may be attributed to several causes and includes pre-existing inflammation of a residual root top or adjacent tooth, foreign body within bone tissue or insertion of a dental implant in an infected maxillary sinus (27).

PREVENTION OF PERI-IMPLANT DISEASES

Therapy of already existing conditions in peri-implant diseases is extremely complicated and is conducted in several stages. Considering the known causes of peri-implant diseases, a combination of systemic therapy by antibiotics and some of surgical or

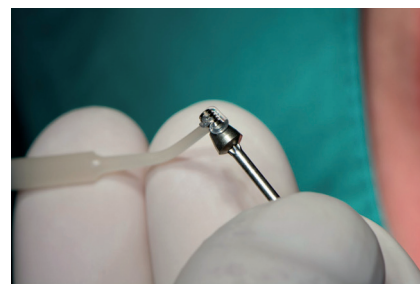


Fig. 4: Application of the material during fixation of the cover screw.

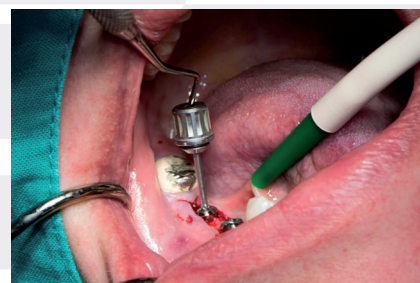

Fig. 5: Fixation of the cover screw after application of GapSeal®.

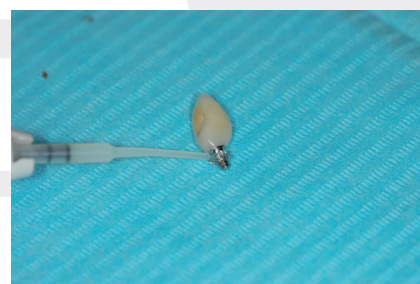

Fig. 6: Application of the material for the prosthetic suprastructure.

non-surgical methods (debridement, detoxification and guided bone regeneration) are applied in their treatment. It is important to note that the treatment of any peri-implant disease is difficult, and the success and clinical results are uncertain. After the insertion of dental implants and the conclusion of implant-prosthetic therapy, the patients have to be informed about the importance of proper oral hygiene. Additionally, during regular follow-ups it is necessary to conduct professional removal of soft and hard plaque with the aim of removing present bacteria as the lead factor in the occurrence of peri-implant diseases (28).

One of the most prominent and recent theories about the occurrence of peri-implant diseases is based on reinfection of peri-implant tissue from the inside of the implant (29). Between implants and suprastructure there is a gap that can be minimised, but not completely removed. According to the literature, marginal area amounts to 14 to 160 microns and is usually unable to resist infiltration of germs from the mouth cavity, because pathogenic microorganisms are regularly several times smaller than the existing gap between the implant surface and suprastructure. The colonisation of microorganisms occurs immediately after the fixation of cover screw or prosthetic suprastructures, whereas the heat and moist conditions within the implant enable the growth of microbes. During chewing, due to capillary forces and micromovements, an exchange of fluids occurs between the inside of the implant and peri-implant tissue. This mechanism leads to permanent reinfection which is the most frequent cause of peri-implantitis. Even the highest level of precision in the implant making cannot fully eliminate the need to add some materials into the implant in order to compensate for the rough surface of the implant and suprastructure (28).

Primarily because of that some preparations appeared on the market to fill the gap and thus contribute to the prevention of peri-implant diseases: gold foil, self-hardening silicon materials, vaseline, antibiotic gels, chlorhexidine gel, Paldur® and Ledermix®.

Regardless of which of the afore mentioned preparations is used for the treatment of this important area, it should be emphasised that they are unstable and that the prevention of this type is a short-term one and needs to be repeated. Due to that, based on the past ten years of experimental and clinical work at the University of Düsseldorf, the material called Gap-Seal® has been developed (Hager & Werken, Duisburg, Germany). The material is based on essential components from high viscose silicone basis and an ingredient combination complex with bactericidal, fungicidal, virucidal properties, which enables long-term softness and efficient sealing on implant gap. Considering that it is not possible to remove by rinsing, but it has to be done mechanically, it is the only material that ensures long-term protection from reinfection from the inside of the implant. It is packed in prefilled sterile tips, with the applicator that can be autoclaved, and that makes the application fast and simple. The application is indicated in all stages of dental implant insertion, in the fixation of the cover screw of the implant, fixation of gingiva formers and final prosthetic construction.

CONCLUSION

Since the largest number of peri-implant diseases occurs as a result of peri-implant tissue reinfection from the inside of the implant, it seems reasonable to attempt to prevent peri-implant diseases by using recent sealants of gaps based on high viscose silicones between the implant surface and prosthetic suprastructure with the aim of preventing and disabling mechanisms of reinfection of peri-implant area.

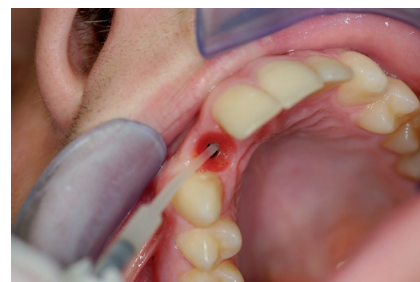


Fig. 7: Application of the material into the inside of the dental implant.

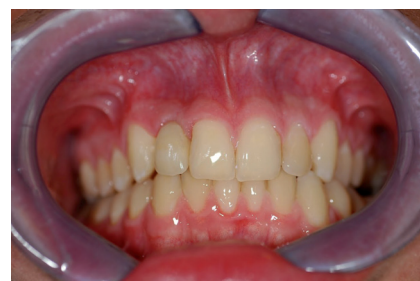

Fig. 8: Final clinical aspect after fixation of the prosthetic suprastructure.

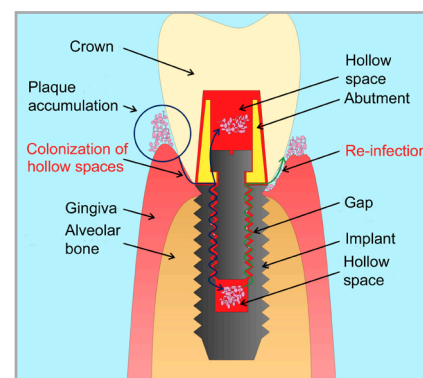


Fig. 9: Mechanism of reinfection from the inside of the implant. (Courtesy of Hager & Werken, Duisburg, Germany)

GapSeal Set (applicator with 10 Tips)
GapSeal Refill Pack (10 Tips à 0,06 ml)
Applicator separately

REF 152 041
REF 152 040
REF 152 042



Video



LITERATURE

- Brånemark PI. Osseointegration and its experimental background. *J Prosthet Dent.* 1983 Sep;50(3):399-410.
- Aurer A. Periimplantatne bolesti. *Medix.* 2003;9(51):137-8.
- Čelić R, Pandurić J, Klaić B. Razumijevanje okluzije – ključ za uspjeh oseointegracije. *Medix.* 2005;11(60/61):180-4.
- Academy report. Peri-implant mucositis and peri-implantitis: a current understanding of their diagnoses and clinical implications. *J Periodontol.* 2013;84(4):436-43.
- Lindhe J, Karring TH, Lang NP. Klinička parodontologija i dentalna implantologija. Zagreb: Globus; 2004.
- Roos-Jansåker AM, Lindahl C, Renvert H, Renvert S. Nine- to fourteen-year follow-up of implant treatment. Part II: Presence of peri-implant lesions. *J Clin Periodontol.* 2006;33(4):290-5.
- Klokkeveld PR, Han TJ. How do smoking, diabetes, and periodontitis affect outcomes of implant treatment? *Int J Oral Maxillofac Implants.* 2007;22(Suppl):173-202.
- Serino G, Strom C. Peri-implantitis in partially edentulous patients: Association with inadequate plaque control. *Clin Oral Implants Res.* 2009;20(2):169-74.
- Wilson TG Jr. The positive relationship between excess cement and peri-implant disease: A prospective clinical endoscopic study. *J Periodontol.* 2009; 80(9):1388-92.
- Linkevicius T, Puisys A, Vindasiute E, Linkeviciene L, Apse P. Does residual cement around implant-supported restorations cause peri-implant disease? A retrospective case analysis. *Clin Oral Implants Res.* 2013;24(11):1179-84.
- Strietzel FP, Reichart PA, Kale A, Kulkarni M, Wegner B, Kuchler I. Smoking interferes with the prognosis of dental implant treatment: A systematic review and meta-analysis. *J Clin Periodontol.* 2007;34(6):523-44.
- Hinode D, Tanabe S, Yokoyama M, Fujisawa K, Yamauchi E, Miyamoto Y. Influence of smoking on osseointegrated implant failure: A meta-analysis. *Clin Oral Implants Res.* 2006;17(4):473-8.
- Heitz-Mayfield LJ, Huynh-Ba G. History of treated periodontitis and smoking as risks for implant therapy. *Int J Oral Maxillofac Implants.* 2009;24(Suppl.):39-68.
- Bormann KH, Stühmer C, Z'Graggen M, Kokemöller H, Rücker M, Gellrich NC. IL-1 polymorphism and peri-implantitis. A literature review. *Schweiz Monatsschr Zahnmed.* 2010;120(6):510-20.
- Bornstein MM, Cionca N, Mombelli A. Systemic conditions and treatments as risks for implant therapy. *Int J Oral Maxillofac Implants.* 2009;24(Suppl.):12-27.
- Mombelli A, Cionca N. Systemic diseases affecting osseointegration therapy. *Clin Oral Implants Res.* 2006;17(Suppl 2):97-103.
- Salvi GE, Carollo-Bittel B, Lang NP. Effects of diabetes mellitus on periodontal and peri-implant conditions: Update on associations and risks. *J Clin Periodontol.* 2008;35(8):398-409.
- Stanford CM, Brand RA. Toward an understanding of implant occlusion and strain adaptive bone modeling and remodeling. *J Prosthet Dent* 1999;81(5):553-61.
- Fu JH, Hsu YT, Wang HL. Identifying occlusal overload and how to deal with it to avoid marginal bone loss around implants. *Eur J Oral Implantol.* 2012;5(Suppl:S)91-103.
- Krennmair G, Seemann R, Piehslinger E. Dental implants in patients with rheumatoid arthritis: Clinical outcome and peri-implant findings. *J Clin Periodontol.* 2010;37(10):928-36.
- Galindo-Moreno P, Fauri M, Avila-Ortiz G, Fernandez-Barbero JE, Cabrera-Leon A, Sanchez-Fernandez E. Influence of alcohol and tobacco habits on peri-implant marginal bone loss: A prospective study. *Clin Oral Implants Res.* 2005;16(5):579-86.
- Rinke S, Ohl S, Ziebolz D, Lange K, Eickholz P. Prevalence of peri-implant disease in partially edentulous patients: a practice-based cross-sectional study. *Clin Oral Implants Res.* 2011;22(8):826-33.
- Koldslund OC, Scheie AA, Aass AM. Prevalence of peri-implantitis related to severity of the disease with different degrees of bone loss. *J Periodontol.* 2010; 81(2):231-8.
- Zitzmann NU, Berglundh T. Definition and prevalence of peri-implant diseases. *J Clin Periodontol.* 2009;20(12):1326-32. 2008; 35(8):286-91.
- Quirynen M, Gijbels F, Jacobs R. An infected jawbone site which compromised a successful osseointegration. *Periodontol 2000.* 2003;33:129-44.
- McAllister BS, Masters D, Meffert RM. The treatment of the implants which demonstrated periapical radiolucencies. *Pract Periodontics Aesthet Dent.* 1992;4(9):37-41.
- Zhou W, Han C, Li D, Li Y, Song Y, Zhao Y. The endodontic treatment of teeth induces retrograde peri-implantitis. *Clin Oral Implants Res.* 2009;20(12):1326-32. 2008; 35(8):286-91.
- Laney WR, Tolman DE. *Tissue Integration in Oral, Orthopedic & Maxillofacial Reconstruction*, Mayo Medical Center Rochester, Minnesota, 1990.
- Fritzemeier CU. Peri-implantitis prophylaxis by sealing implant gaps and hollow spaces. *Implants* 2013 (3) 41-43