

# Splitting and expansion of the alveolar ridge prior to implant placement

---

**Gabrić, Dragana**

**Other document types / Ostale vrste dokumenata**

*Publication year / Godina izdavanja:* **2017**

*Permanent link / Trajna poveznica:* <https://um.nsk.hr/um:nbn:hr:127:994145>

*Rights / Prava:* [In copyright](#)/[Zaštićeno autorskim pravom.](#)

*Download date / Datum preuzimanja:* **2025-04-02**



*Repository / Repozitorij:*

[University of Zagreb School of Dental Medicine  
Repository](#)



# CHAPTER 1B



## SPLITTING AND EXPANSION OF THE ALVEOLAR RIDGE PRIOR TO IMPLANT PLACEMENT BY ASS. PROF. DRAGANA GABRIC

### Aim of Treatment

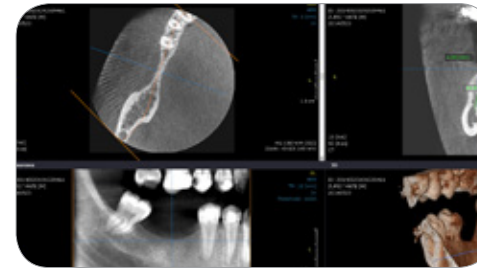
Ridge splitting and expansion is an effective and time-saving technique to develop sites in connection with implant placement. In order to prevent bone resorption the procedure should be as minimally invasive as possible. For this reason piezoelectric cutting with delicate inserts is the method of choice. Due to the minimal invasive design and controlled action of the device bone and soft tissue can be better preserved in comparison with conventional methods.

### Instruments for this case

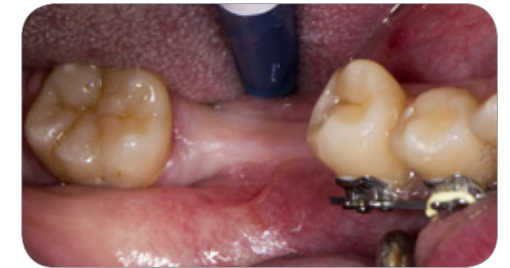

### Clinical Case

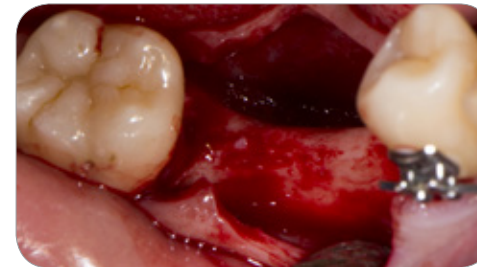In a 25-year-old male patient two implants are planned at positions 46 and 47. In order to allow insertion of 4.1 diameter implants the alveolar ridge is split with piezoelectric inserts and subsequently expanded with screws.



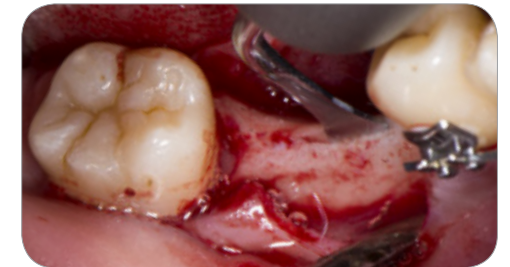1 The reduced width of the implant site requires a horizontal bone management procedure (upper left: axial view, lower left: lateral view, upper right: transversal/coronal view, lower right: 3D reformation).



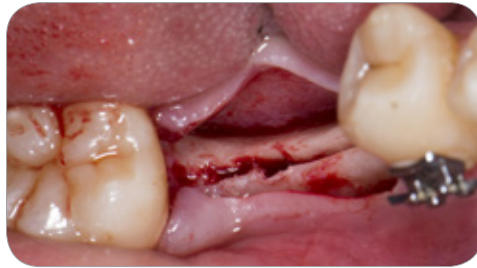2 The clinical baseline finding is a narrow edentulous ridge more than 5 years after tooth loss, combined with a reduced keratinized tissue width.



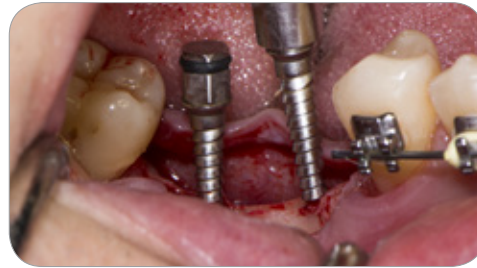
3 After buccal and oral preparation of a full thickness flap the ridge is ready for the splitting procedure.



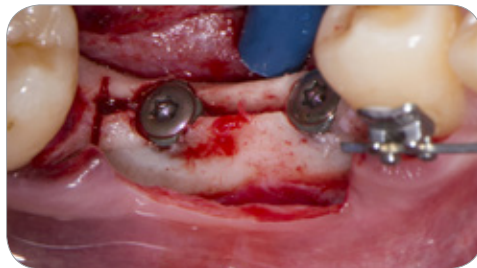
4 With the Piezomed B1 insert the ridge is split along the alveolar crest.



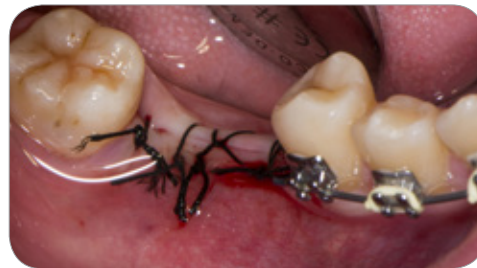5 Result of piezoelectric splitting prior to ridge expansion. A vertical releasing osteotomy has been prepared at the distal site (see Fig. 8).



6 Prior to implant placement expansion is accomplished with specific screws (Split Control, Meisinger).



7 After preparation of the implant bed with system-specific burs the 4.1 / 8.0 mm implants (Bone Level, Straumann) have been inserted. Implant drills were used to keep the gap open for insertion of the first implant.



8 Flaps are finally repositioned and sutured.

## Description of technique

### Options for horizontal augmentation prior to implant placement

The thickness of bone around implants should be at least 1 mm, ideally 2–3 mm, especially on the buccal side [1]. Concerning the hardware, in contrast to older recommendations, implants require a minimum diameter of only 3.3 mm [2]. As a consequence, alveolar ridges with a width of less than approximately 6 mm at implant shoulder level should be augmented to allow insertion of implants with a good long-term prognosis [3].

Lateral augmentation techniques include bone blocks [4], guided bone regeneration (GBR) [5], and ridge splitting and expansion [6]. Splitting of the alveolar ridge, which can be accomplished with an array of hand and mechanical instruments, has shown high implant survival and success rates [7]. An additional alveolar ridge width of 3–4 mm can be achieved, most predictably in the more elastic maxillary bone.

Ridge splitting and expansion can be performed in one stage, combined with simultaneous grafting of the area and submerged implant placement. In comparison with other procedures this saves time and is potentially less invasive. However, as the split bone laminae are often very thin a loss of buccal bone must be anticipated [7]. Therefore additional buccal GBR measures may be indicated.

### Access to the site and crestal osteotomy

Based on diagnostic data and case-specific implant planning an access flap is prepared. If a minimum residual ridge width of 2–3 mm is available the crestal osteotomy can be performed. Conventional surgical instruments for this procedure include micromotor-driven rotary carbide burs and rotary, sagittal, reciprocating or oscillating saws (micromotor, sonic). Due to their size rotary instruments are relatively traumatic, which is less than optimal in bone deficient sites [3].

Due to their design and cutting action saws driven by micro motors or sonic devices may allow only limited access to the site, especially near natural teeth. The crestal (sagittal) osteotomy line should be prepared to a distance of 1.0 to 1.5 mm from the periodontium of neighboring teeth. Piezoelectric devices show a unique, well-controlled cutting action and have a minimal-invasive insert design. Therefore they are the technology of choice in this area. This applies also to the vertical release osteotomy on the buccal side, which requires delicate instruments and an optimal view over the surgical area. The crestal osteotomy is prepared as a function of the implant hardware and the expansion technique, in most cases to a depth corresponding to the implant length. The (distal and/or mesial) vertical

release osteotomy should be long enough to prevent fracturing of the buccal bone, which is especially important in the less elastic mandibular bone (8).

#### Ridge expansion and implant placement

Expansion of the ridge can now be performed with dedicated instruments, which are available as hand osteotomes or chisels with graduation marks, or as expansion screws with increasing diameter (9). Additional horizontal expansion devices can be used for controlled alveolar ridge expansion. Implants are placed after defined osteotomic preparation of the implant bed(s) with specific kits of hand or mechanic (rotary or ultrasonic) instruments.

### Challenge of the procedure and benefits of the Piezomed

Splitting and expansion of the crestal alveolar bone to allow placement of implants is a predictable procedure. However, care must be taken to preserve as much bone as possible and to use a minimal invasive cutting technique. Piezoelectric devices like the Piezomed cut bone in a highly efficient manner. At the same time the specific cutting action of the device, exit of irrigant near the tip of the Piezomed inserts and the bright LED light allow optimal operative control and view over the surgical area.

In the present clinical example the mandibular site was successfully split with a piezoelectric saw (Piezomed B1). Alternatively the finely-toothed and highly effective saws B6/B7 could have been used for the purpose. These delicate instruments allow preparation of split lines with a width of only 0.25 mm (B6) and 0.5 mm (B1), respectively. As the mandibular bone of the young patient was relatively resilient it was possible to expand the site minimal-invasively to accommodate two 4.1 diameter implants.

### Author information

Assistant Professor Dragana Gabrić Pandurić, DMD, PhD

- > 2004 Doctor of Dental Medicine (DMD), University of Zagreb, 2005 Dean's Award for Study Success
- > 2006 Junior Assistant, 2010 Senior Assistant, Department of Oral Surgery, School of Dental Medicine, University of Zagreb
- > 2007 Oral Surgeon Trainee, Department of Oral Surgery, Clinical Hospital Center Zagreb

- > 2010 PhD, dissertation in the field of experimental laser bone surgery; 2011 Specialist in Oral Surgery, Department of Oral Surgery, Clinical Hospital Center Zagreb
- > 2011 Associate Research Scientist, 2013 Senior Research Scientist, 2014 Assistant Professor and PhD Tutor, Department of Oral Surgery, School of Dental Medicine, University of Zagreb
- > Author of numerous scientific papers and four book chapters (medical genetics; dental implantology and bone augmentation surgical procedures; laser soft tissue surgery)
- > Editorial board member of the Journal of Lasers, Optics & Photonics; review board member of several international scientific journals (e.g. Journal of Periodontology, Journal of Dentistry)

### References

1. Buser D, Chen ST, Weber HP, Belser UC. Early implant placement following single-tooth extraction in the esthetic zone: biologic rationale and surgical procedures. *Int J Periodontics Restorative Dent* 2008;28:441-451.
2. Klein MO, Schiegnitz E, Al-Nawas B. Systematic review on success of narrow-diameter dental implants. *The International journal of oral & maxillofacial implants* 2014;29 Suppl:43-54.
3. Vercellotti T. *Essentials in Piezosurgery: Clinical Advantages in Dentistry*: Quintessence Publishing, 2009.
4. Nystrom E, Ahlqvist J, Kahnberg KE, Rosenquist JB. Autogenous onlay bone grafts fixed with screw implants for the treatment of severely resorbed maxillae. Radiographic evaluation of preoperative bone dimensions, postoperative bone loss, and changes in soft-tissue profile. *International journal of oral and maxillofacial surgery* 1996;25:351-359.
5. Buser D, Bragger U, Lang NP, Nyman S. Regeneration and enlargement of jaw bone using guided tissue regeneration. *Clinical oral implants research* 1990;1:22-32.
6. Simion M, Baldoni M, Zaffe D. Jawbone enlargement using immediate implant placement associated with a split-crest technique and guided tissue regeneration. *Int J Periodontics Restorative Dent* 1992;12:462-473.
7. Bassetti MA, Bassetti RG, Bosshardt DD. The alveolar ridge splitting/expansion technique: a systematic review. *Clinical oral implants research* 2015.
8. Vercellotti T. Piezoelectric surgery in implantology: a case report--a new piezoelectric ridge expansion technique. *Int J Periodontics Restorative Dent* 2000;20:358-365.
9. Stricker A. Augmentation in der oralen Implantologie. Bone splitting als Alternative zum Knochenblock. *Der Freie Zahnarzt* 2013;78-87.