Advanced Applications of the Er:YAG Laser in Oral and Maxillofacial Surgery

Gabrić, Dragana; Baraba, Anja; Batinjan, Goran; Blašković, Marko; Vučićević Boras, Vanja; Filipović Zore, Irina; Miletić, Ivana; Gjorgievska, Elizabeta

Source / Izvornik: **A Textbook of Advanced Oral and Maxillofacial Surgery: volume 2, 2015, 799 - 838**

Book chapter / Poglavlje u knjizi

Publication status / Verzija rada: **Published version / Objavljena verzija rada (izdavačev PDF)**

https://doi.org/10.5772/59273

Permanent link / Trajna poveznica: https://urn.nsk.hr/urn:nbn:hr:127:108548

Rights / Prava: Attribution-NonCommercial-NoDerivatives 4.0 International/Imenovanje-Nekomercijalno-Bez prerada 4.0 međunarodna

Download date / Datum preuzimanja: **2024-05-15**

Repository / Repozitorij:

University of Zagreb School of Dental Medicine Repository

Chapter 34

Advanced Applications of the Er:YAG Laser in Oral and Maxillofacial Surgery

Dragana Gabrić, Anja Baraba, Goran Batinjan, Marko Blašković, Vanja Vučićević Boras, Irina Filipović Zore, Ivana Miletić and Elizabeta Gjorgievska

Additional information is available at the end of the chapter

http://dx.doi.org/10.5772/59273

1. Introduction

Lasers are becoming widely used in medicine and dentistry due to their beneficial effects such as: coagulation properties (less postoperative bleeding), less pain and edema. Lasers also allow good and rapid healing, a very low level of discomfort both during and after intervention and a rapid disappearance of symptoms.

Four responses within tissues are described when the laser beam hits the target tissue namely reflection, absorption, transmission and scattering. The main mechanisms of interaction between the lasers and biological tissues are: photothermic, photoacoustic and photochemical. The effect of lasers on the soft tissues is based on the transformation of light energy into heat. Operator-dependent factors affecting the effect of lasers are: power density, energy density, pulse repetition rate, pulse duration and the mode of energy transferred. Operator non-dependent factors which affect laser treated areas are specific laser wavelengths and optical properties of the target tissues [1].

Effects on the tissues when lasers are applied include the increase in the temperature, coagulation, hemostasis, tissue sterilization, tissue welding, incision, excision, ablation and vaporization [1]. When laser energy is absorbed in the water of the hard tissues, a rapid volume expansion of the evaporating water occurs as a result of a substantial temperature elevation at the interaction site. Micro-explosions are produced causing hard tissue disintegration. If pulp temperatures are raised beyond 5 degrees, pulp damage is irreversible. If heat is intensive and lasts for an extended period of time the consistency of the intracellular ground substance may not be preserved [1].

INTECH
open science | open minds

© 2015 The Author(s). Licensee InTech. This chapter is distributed under the terms of the Creative Commons Attribution License (http://creativecommons.org/licenses/by/3.0), which permits unrestricted use, distribution, and eproduction in any medium, provided the original work is properly cited.

Erbium-yttrium-aluminum-garnet (Er: YAG) lasers produce invisible infrared light at a wavelength of 2.940 nm which is ideal for absorption by hydroxylapatite and water [2]. Therefore, they can be used for treatment of both soft and hard tissues (unlike for example diode lasers). As the Er: YAG wavelength corresponds to the absorption coefficient of water, Er: YAG laser irradiation transforms water within tissue into steam leading to the development of micro-explosions [3].

2. Advantages of Er: YAG laser treatment

Laser technology has certain advantages such as accuracy of the incision, absence of vibration and manual pressure during use; this is also true for Er: YAG laser application. Due to laser positive coagulation effects during surgical procedure, better sight of the work field is obtained. Komori [4] and Gouw-Soares [5] have reported that Er: YAG lasers are appropriate for the treatment of hard dental tissues without inducing discomfort, vibration or noise. Furthermore, risk of surgical field contamination and damage to the surrounding tissues is decreased when compared to the other similar techniques. Additionally Er: YAG lasers are characterized by low intraoperative and postoperative pain levels. Decreased pain levels by use of Er:YAG as well as other lasers may be explained by the fact that laser application leads to the formation of protein coagulum on the surface of the wound which acts as a dressing [6]. Furthermore, lasers have the ability to seal sensory nerve endings which results in decreased pain perception. Last but not least, Er: YAG lasers produce rapid wound healing [7].

3. Possible hazards of laser use

It is very important to acknowledge possible thermal damage induced by Er: YAG lasers in the clinical setting. Kreisler [8] suggested that temperature elevation did not exceed 47°C after 120 seconds of Er:YAG laser irradiation with pulse energy between 60 and 120 mJ and frequency of 10 Hz. Geminiani [9] reported that application of Er:YAG lasers in continuous mode for 10 seconds generated a high temperature which was above critical threshold. Monzavi [10] reported that use of Er: YAG was safe without cooling and that, an increase of 4.30°C was observed. Use of air and air water cooling eliminated the risk of possible thermal damage. Mitsunaga [11] retrieved literature data from the year 2001 to 2012 with regard to complications after laser irradiation such as cervicofacial subcutaneous emphysema. They [11] reported 13 such cases, of which eight had undergone CO2 laser treatment and two had undergone Er: YAG laser treatment. Nine patients had emphysema following laser irradiation for soft tissue incision [11].

4. Application of ER: YAG laser in soft tissue surgery

Lasers have played an integral part in the evolution of oral and maxillofacial surgery (OMS); and rapidly became the standard of care for many procedures performed by oral surgeons.

The reason for this transition is simple: many procedures can be executed more efficiently and with less morbidity using lasers when compared with scalpel, electrocautery or high frequency devices. Onisor [12] performed an *in vitro* study using Er: YAG and CO_2 laser for crown lengthening, gingivoplasty and maxillary labial frenectomy. The same authors [12] concluded that Er: YAG is able to provide good cutting and coagulation effects on soft tissues. Specific parameters have to be defined for each laser in order to obtain the desired effect. Reduced or absent water spray, defocused light beam, local anesthesia and use of long pulses are important in order to obtain optimal coagulation and bleeding control. Kaya [13] described a case of pyogenic granuloma around an implant seven years after its insertion which they treated by use of Er: YAG laser. Türer [14] compared Er: YAG laser to the scalpel in the preparation of the recipient site for free gingival grafts. The same authors [14] stated that Er: YAG laser may be used with similar effectiveness as the scalpel for this purpose.

Laser surgery has emerged as an established method in advanced medicine. Laser-induced remote tissue treatment provides a number of advantages: controllable coagulation and cutting of surgical tissues with wavelength tissue-specific cutting efficiency [15]. At the Department of Oral Surgery, School of Dental Medicine, University of Zagreb, two clinical studies of Er: YAG laser use for soft tissue surgery was performed.

4.1. Er: YAG laser-assisted surgery of benign oral tumors

The aim of first study was to evaluate the efficacy of a high power diode laser, Er:YAG and Nd:YAG laser in surgical therapy of benign oral lesions in comparison to the conventional methods on the basis of following temperature difference in surrounding tissue during the laser operation procedure.

Infrared thermography is a diagnostic method with ability to record infrared radiation emitted by the skin and convert it into electronic video signals. Infrared thermography is unique in its capability to show physiological and/or pathological temperature changes [16]. One hundred and twenty patients who had indication for surgical removal of benign oral lesions were randomly divided into four groups dependent on the type of therapy. First group (Diode group) received diode laser therapy with Laser (Hager & Werken GmbH & Co., Germany). Depending on the indications settings specified by the manufacturer for removal of fibroma a "Fibroma removal mode" was used (wavelength of 975 nm, power of 5W, CW). Second (Er: YAG) and third (Nd: YAG) groups received Er: YAG and Nd: YAG therapy modules. All settings of the Er: YAG and Nd: YAG laser were according to manufacturer specifications. Light Walker AT (Fotona, Slovenia) was used for Er: YAG and Nd: YAG treatments. The laser settings were 150 mJ for fibroma removal in pulse mode QSP and 15 Hz frequency. Non-contact X-Runner digitally controlled handpiece was used for treatments. The shape with the X-Runner handpiece was selected according to the required treatment area. The handpiece was held at the distance 15 mm from the treatment tissue, without water spray (Figures 1-3). In the fourth group (scalpel group) procedure was performed using the conventional methods using the cold knife for fibroma removal and afterwards the wounds were sutured.

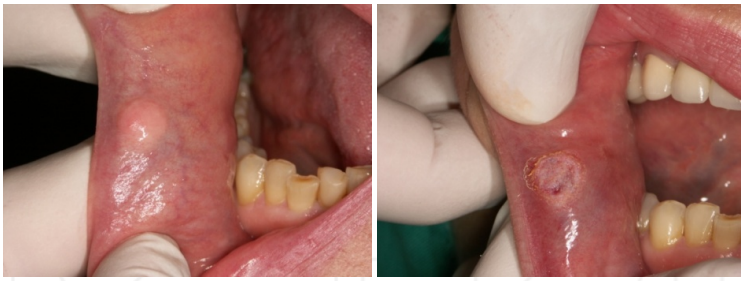

Figure 1. Fibroma of the right cheek (left) and removal of the lesion using Er: YAG laser with X-Runner handpiece (right)

Figure 2. Fibroma of the hard palate (left) and removal of the lesion using Er: YAG laser with X-Runner handpiece (right)

Figure 3. Follow-up (case from Figure 2), 3 weeks after surgery

4.2. Thermographic measurement and thermogram processing

Prior to the start of the procedure each patient spent 15 minutes in operating anteroom in which the temperature and humidity are the same as the operating room since both areas have

controlled environment (air conditioned). Camera was set on a tripod at fixed, predetermined distance (30 cm from the head of the patient), thus camera settings were always the same. Infrared (IR) camera in general records temperature distribution in a given area. In this case it recorded temperature distribution in the oral cavity prior to, during and after laser treatment and during postoperative check-up. Taking thermographic images (thermograms) allowed us to monitor the effects of laser treatment on tissues, i.e. the changes in temperature of tissue treated with the laser (and surrounding tissue in close proximity) caused by the effects of laser on the tissues, i.e. the effects during the procedure. Thermographic images taken using FLIR T335 camera (Flir systems, USA) during laser procedure were stored on the computer for later processing. Images had to be spatially calibrated firstly during image interpretation in order to obtain data regarding spatial temperature distribution in the image. Spatial market, metal equilateral triangle of known dimensions, was used for that purpose. Metal triangle was easily visible on thermographic images since its temperature was a few degrees lower. Since the triangle dimensions were known and well defined, triangle outlines on the image were used for spatial measurement. In this procedure metal triangle was used as spatial marker in the same way as a ruler (as a "standard" spatial marker) is used (Figure 4, in the middle).

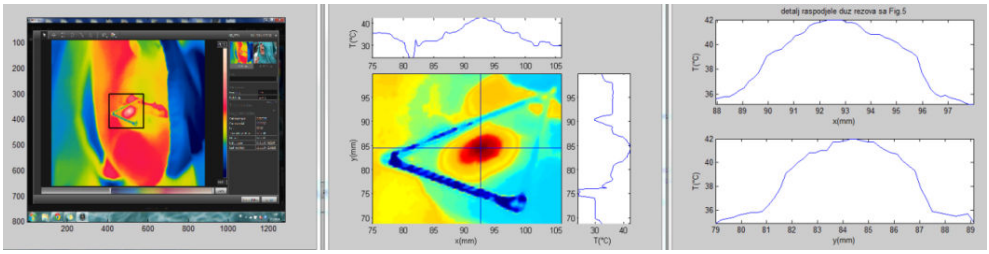

Figure 4. Thermographic image processing

In all the surgical procedures performed, thermal increase was evaluated until the end of the procedure; thermal decrease was evaluated in the few seconds after surgery. Matlab program (MathWorks, USA) was used for processing thermograms in the RGB format. The oral health related quality of life (OHRQoL) was assessed in all four groups after the surgical procedure. All participants filled-out the Oral Health Impact (OHIP) 14-CRO Questionnaire. The questions were related to the period during and after the surgical procedure. Patients answered each question using the 0-4 Likert scale (0=absence of problems; 4=the most severe problems). The OHIP Summary Score was calculated for statistical analysis. Results of this study showed no significant temperature differences between diode and Nd: YAG group during the surgical procedure. They had almost the same temperature in the region ($p=0.76$). Er: YAG group had significantly lower temperature increase in the operative areas when compared to the other two laser groups ($p<0.001$). The highest superficial thermal increase was recorded for diode laser, the lowest one for Er: YAG laser (Table 1). Participants in all three laser groups had significantly lower OHIP14-CRO summary scores ($p<0.001$, Table 2).

LASER	THERMAL EFFECT Mean (μm) ± SD
Er:YAG	38,92 ± 19,92
Nd:YAG	81,23 ± 3,53
Diode laser	82,76 ± 5,38

Table 1. Thermal effect of the operated area during the surgical procedure, mean value and standard deviation (SD)

	Group	mean (OHIP score)	SD	t	P
OHIP Summary score	Laser groups	12.65	3.84	-6.776	<0.001 *
	Scalpel group	26.50	8.29		

Degree of freedom = 38, * significant at 99% probability, p<0.01

Table 2. Difference in the OHIP 14 scores as well as in the OHIP 14 Summary Scores between the laser groups and the scalpel group together with significance of the differences

Most laser excisional or incisional procedures are accomplished at 100°C, where vaporization of intracellular and extracellular water causes ablation or removes biological tissues. Clinicians must be aware of the heat generated within tissues during a procedure. If the tissue temperature exceeds 200°C during a laser procedure, carbonization and irreversible tissue necrosis will occur. This adverse consequence can be avoided completely by using the lowest power setting necessary to achieve the desired treatment goal [17].

Er: YAG lasers operate at a higher wavelength on the principle of ablation in non-contact mode at a 2940 nm wavelength, while the diode and Nd: YAG laser work at smaller wavelength on the principle of excision in contact mode which denotes a more aggressive approach. That is probably the reason why the diode and Nd:YAG lasers cause higher heating of the surrounding tissues and a higher dispersion of energy which damages more surrounding structures within targeted therapeutic areas and result in slower healing. However, they result in better hemostasis and less swelling due to the effects of diode laser on tissue targets (melanin and hemoglobin). When considering use of diode laser for soft tissue surgery, the clinician must consider several factors. Diode lasers are attracted to pigment, and frena are typically thicker fibrous tissue and have very little pigment. The lack of pigment and more fibrous nature of the tissue mean that higher energies and patience are required to ablate this tissue. Other lasers, such as Er: YAG lasers may ablate frena faster, and can be used in non-contact mode, but the drawback compared to diode lasers is an increased risk of bleeding. Er: YAG lasers are not well absorbed in hemoglobin as the soft tissue diode lasers are, so hemostasis can be an issue with these wavelengths. Some studies [18-23] compared the efficacy of diode and Er: YAG lasers in soft tissue oral surgery. Some studies showed that the Er:YAG laser induced deeper gingival tissue injury than diode laser, as judged by bleeding at surgery, delayed healing and deformed specimen for histopathological analysis [23]. In some studies the use of diode laser showed additional advantages over Er: YAG in terms of less postoperative discomfort and

pain, but some studies show no difference between these two lasers [3]. Some studies indicate that only the Er: YAG laser can be used for lingual frenectomy without local anesthesia, and there was no difference between the two groups regarding the degree of the postsurgical discomfort except in the first 3 hours [19]. Results indicate that the Er: YAG laser is more advantageous than the diode laser in minor soft-tissue surgery because it can be performed without local anesthesia and with only topical anesthesia.

Since the introduction of the lasers in clinical practice, different wavelengths have been used for oral surgery on the basis of the different characteristics and affinities of each. One study compared different laser wavelengths in relation to both thermal increase and "histological quality" in a model of soft tissue surgery procedures. Thermal evaluation was noticed, during laser-assisted surgery excision performed on a bovine tongue, by a thermal camera device to evaluate thermal increase on the surface of the sample and with four thermocouples to evaluate thermal increase on the depth of the specimen. Temperature was recorded before start of the surgical procedure and at the peak of every excision. The results of this study are similar to ours because the highest in depth thermal increase was recorded for the 5 W diode lasers, the lowest one for Er: YAG laser [21].

4.3. Evaluation of Er:YAG laser for surgical treatment of precancerous lesion (leukoplakia)

Leukoplakia is a white precancerous lesion of the oral cavity with a recognizable risk of malignant transformation. According to the World Health Organization, the name leukoplakia can be used to describe the clinical finding of white patches on the oral mucosa that cannot be removed or classified as other oral diseases. Histologically, leukoplakia consists of epithelial hyperplasia, with or without hyperkeratosis, minimal inflammation, and different degrees of dysplasia. Oral leukoplakia is the most common potentially malignant lesion of the oral cavity, and the incidence of malignant transformation increases during the years. Treatment options are: scalpel excision, electrocoagulation, cryotherapy and CO_2 laser therapy. Extremely extensive lesions are the biggest challenge. Pharmacological treatments include vitamin A and retinoids, topical antioxidants and bleomycin [24-26]. Out of all available ablative lasers in the treatment of leukoplakia Er: YAG laser is emphasized due to the highest degree of absorption in water. The latest laser technology allows extremely precise ablation or excision of these lesions using computerizing, automatic guided laser beams with precise and individually determined limits by use of QSP mode (X-Runner, LightWalker, Fotona, Slovenia, 2013). Besides complete visibility during ablation due to its coagulation effect, speed, precision of the procedure and rapid healing without postoperative complications or healing without scar are its main advantages [27].

We evaluated the effectiveness of ablative Er: YAG laser in the treatment of leukoplakia and frequency of recurrence after ablative laser therapy. By regular monitoring of postoperative pain via visual analogue scale of pain scores (VAS), the impact of leukoplakia at the quality of life (QoL) using OHIP-14 questionnaire was also assessed. The study was conducted at the School of Dentistry, University of Zagreb, Croatia. Ablative Er: YAG laser was used on 28 lesions with histologically confirmed diagnosis of oral leukoplakia. Lesions were measured (in millimeters), which was necessary for monitoring results and the potential recurrence, as

well as for the choice of laser parameters. During surgery, after applying a local anesthetic (Ubistesin 2%, 3M ESPE), depending on the size of the lesion, the size of the working field of the laser was selected. All hyperkeratotic lesions were removed by ablation. Their degree was recorded as was the number of sessions required for ablation. Patients were seen at follow-up a week, two weeks, four weeks and eight weeks after the irradiation. At the follow-up, lesions were re-measured for each patient when applicable and the results were compared with the initial data. Postoperative pain was assessed by VAS where the patient rated the degree of pain after the procedure on the scale from 1-10. Also, each patient filled-out the OHIP - 14 questionnaire of the impact of lesions on the quality of their life (Figures 5-15). All data were used for statistical analysis.

Figure 5. Leukoplakia of the right cheek (left) and removal using Er: YAG laser with X-Runner handpiece (right)

Figure 6. Immediate postoperative view (left) and follow-up 3 weeks after surgery (right)

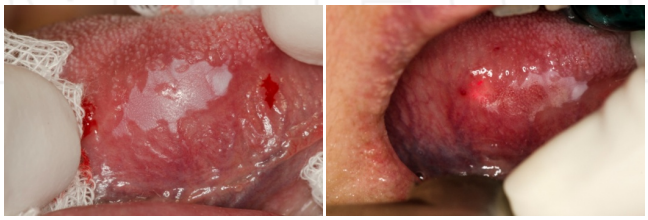

Figure 7. Leukoplakia of the right lateral tongue (left) and removal using Er: YAG laser with X-Runner handpiece (right)

http://dx.doi.org/10.5772/59273

Figure 8. Immediate postoperative view (left) and follow-up 3 weeks after surgery (right)

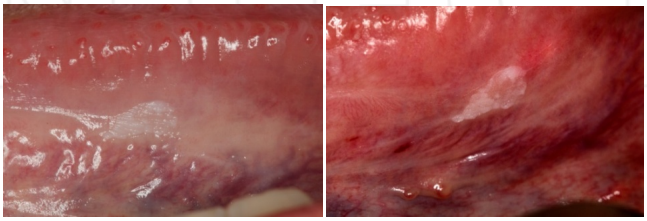

Figure 9. Leukoplakia of the left lateral tongue (left) and removal using Er: YAG laser with X-Runner handpiece (right)

Figure 10. Immediate postoperative view (left) and follow-up 3 weeks after surgery (right)

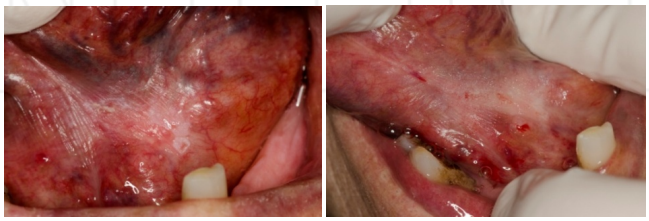

Figure 11. Sublingual leukoplakia (left) and immediate postsurgical view after removal using Er: YAG laser with X-Runner handpiece (right)

Figure 12. Follow-up 3 weeks after surgery

Figure 13. Leukoplakia of the upper lip (left) and removal using Er: YAG laser with X-Runner handpiece (right)

Figure 14. Leukoplakia of the alveolar ridge (left) and removal using Er: YAG laser with X-Runner handpiece (right)

Figure 15. Follow-up 6 weeks after surgery

The results of our study confirmed that treatment of leukoplakia by Er: YAG laser had less edema, post-operative bleeding and pain, in comparison to the conventional surgical methods of treatment such as scalpel. The procedure was easily tolerated and postoperative pain was low or absent. Significant differences between men and women regarding the location of the lesions, number of laser sessions and VAS were found (Tables 3 and 4).

Gender N (%)		**Differences in gender**	**Differences compared to the recurrence**
Male	10 (37)		0.148
Female	17 (63)		
Age (mean ± SD)	53.3. ± 13.3	0.459	0.643
Smoking Yes	9 (33.3)	0.260	0.121
Smoking No	18 (66.7)		
Cigarettes per day (mean ± SD)	18.3 ± 10	0.809	0.471
Lesion in mm^2 (mean ± SD)	74.8 ± 90.4	0.166	0.381
Buccal mucosa	11 (40.7)	**<0.001***	**0.004***
Tongue	6 (22.2)		
Sublingual mucosa	3 (11.1)		
Other	7 (26)		

Table 3. Demographic data regarding participants and location of the leukoplakia lesions.

Laser parameters – shape N (%)		**Differences in gender**	**Differences compared to the recurrence**
Circle	10 (37)	0.456	0.926
Rectangle	8 (29.6)		
Combination	9 (33.3)		
Number of ablations ≤10	7 (25.9)	0.05	0.694
11-20	16 (59.3)		
>20	4 (14.8)		
Number of laser sessions (mean ± SD)	2.1 ± 0.8	**0.036***	**<0.001***
Recurrence Yes	20 (74.1)	0.148	
Recurrence No	7 (25.9)		
VAS (mean ± SD)	2.68 ± 3.28	**0.008***	0.200
OHIP	9.6 ± 9.8	0.493	0.283

Table 4. Data regarding laser parameters, number of ablations, recurrence rate as well as VAS scores and OHIP results.

The results indicate that sublingual leukoplakia lesions tend to recur less frequently in comparison to the ones situated on the buccal mucosa, tongue and on other parts of the oral mucosa. All leukoplakia lesions found sublingually were seen in women. Women tended to have higher VAS scores in comparison to the men. Men had less laser sessions compared to the women due to the fact that lesions in men were mostly located on the buccal mucosa.

In the published literature there are few papers on treatment of leukoplakia which is refractory to conventional therapy. In the recent years, lasers are having shown to be highly effective in the soft tissue surgery due to the properties of coagulation during surgery and post-operative swelling and pain reduction [28-31]. It was found that laser-assisted removal of the precancerous lesion with the non-contact, digitally controlled X-Runner handpiece was very safe and pleasant for the patient and very effective and comfortable for the operator. The operational field is very clear, especially because there is no bleeding during the operation with the QSP mode. The interventions were performed very quickly because of the automatic coverage of the area with the X-Runner handpiece [27].

4.4. Gingival melanin depigmentation

So far, there are not many published studies regarding the use of Er: YAG lasers in the treatment of gingival melanin pigmentations (Figures 16 and 17). The results of the study of Simsek Kaya. [3] have showed that both diode and Er:YAG laser applied at 1 W can perform gingival depigmentation. However, it seems that treatment duration is longer when Er: YAG lasers are applied compared to the diode lasers. This difference may be explained by the fact that diode lasers penetrate deeper in comparison to the Er: YAG lasers. Furthermore, wavelength of diode lasers lies within the spectrum absorbed by melatonin. Overall, it seems that Er: YAG lasers limit the thermal damage of the surrounding tissues due to the lower penetration force [3]. Ergun [32] reported a case of refractory pigmentations on the lips and oral mucosa in a female patient with Laugier-Hunziker syndrome, successfully treated with Er: YAG laser. Similar skin lesions (hyperkeratosis, nevus, spots and patches) can also be removed using Er: YAG laser with X-Runner handpiece (Figures 18 and 19).

Figure 16. Gingival melanin pigmentation (left) and removal using Er: YAG laser with X-Runner handpiece (right); QSP mode, 120 mJ, 20 Hz, 10 ml/min

Figure 17. Follow-up 6 weeks after surgery

Figure 18. Isolated keratosis of the left elbow (left) and removal using Er: YAG laser with X-Runner handpiece (right); QSP mode, 120 mJ, 20 Hz, 10 ml/min

Figure 19. Immediate postoperative view

5. Application of ER: YAG laser in endodontic surgery

The main goal of endodontic treatment is to remove necrotic tissue and microorganisms from root canals by means of mechanical preparation and disinfection in order to seal the root canal space and to prevent subsequent recontamination. According to the literature, the success of primary endodontic treatment reaches values from 47-97% [33]. Failures of orthograde root

canal fillings occur in cases with pre-operative presence of periapical radiolucency, root canal filling with voids or root canal fillings more than 2 mm short of the radiographic apex and inadequate coronal restoration [34]. If microorganisms remain present in the root canal system or invade the periradicular tissues or periradicular tissues become contaminated with root canal filling materials, inflammatory and immune response or foreign body reaction may occur, causing local bone destruction and impairment of tissue healing. Failures in endodontic treatment can be managed by retreatment or endodontic surgery although certain clinical situations can only be resolved by means of surgical endodontics. Endodontic surgery has been reported to have a success rate from 44-95% [35] while modern techniques and materials used in endodontic surgery nowadays yield even more consistent success rates, from 88-96% [36-8].

5.1. Endodontic surgery indications

- periradicular disease due to iatrogenic or developmental anomalies which prevent orthograde root canal treatment;
- periradicular disease in root canal of filled teeth in which conventional retreatment cannot be performed or has failed or if the orthograde access to root canal may be detrimental to the retention of the tooth;
- when biopsy of periradicular tissue is required;
- when visualization of the periradicular tissues and tooth root is required, i.e. when perforation or root fracture is suspected [39].

Although there are only few absolute contraindications for endodontic surgery, some factors should be considered. Regarding patients, it is important to assess medical history and the presence of any systemic diseases as well as psychological conditions (uncooperative patient) [40]. Factors which may also preclude surgical approach are local anatomical factors (e.g., inaccessible root end), unusual bony or root configurations, possible involvement of neurovascular structures, tooth with inadequate periodontal support and nonrestorable tooth or tooth without function [40]. Skills, training and experience of the operator as well as available facilities should also be considered.

Endodontic surgical treatment or apicectomy is a procedure performed through a transosseous approach with resection of the root apex, removal of inflammatory periapical tissue and retrograde obturation of root apex in order to prevent microbes or their byproducts from reaching the periapical tissues.

Conventional techniques for apicectomy may include the use of scalpels, curettes, burs and ultrasound tips. This surgical procedure starts with soft tissue flap design depending on a number of factors such as: access to and size of the periradicular lesion, periodontal status, state of coronal tooth structure, the nature and extent of coronal restorations, aesthetics and adjacent anatomical structures. After flap reflection, hard tissue management or osteotomy is performed and the bone should be removed accurately in order to have an access to the root. Bone can be removed using diamond, steel or tungsten carbide burs with continuous cooling with saline sterile water. In cases of missing or very thin cortical bone plate even curettes may

be used for osteotomy. Although osteotomy should provide clear visibility and adequate access to root apex, microsurgical approach is recommended [41]. Soft tissue in the periradicular inflammatory region should be removed, usually using curettes, ensuring good visualization of the operating field. When resecting the root, the angle of the resection should be 90 degrees to the long axis of the tooth in order to reduce the number of exposed dentinal tubules [42]. Regarding the length of the resected part of the root, at least 3 mm of root end should be resected to eliminate the majority of anomalies in the apical third. Traditionally, root end resection is done using rotating burs. It is important to examine the resected root surface for presence of any cracks or canal irregularities [43, 44]. The traditional way for root-end preparation is using small round or inverted cone steel burs. The goal of root-end preparation is to surgically remove root canal ramifications, enhance access to the apex, create a working surface for retrograde preparation, facilitate debridement of periapical tissues and to remove irritants from root canal space [45]. Root end preparation should ensure space for root end obturation providing adequate seal apically and optimizing conditions for pariapical tissue healing [45]. This preparation should be 3 mm deep, following the long axis of the tooth. This became easier to achieve in the early 1990s, when sonically or ultrasonically driven microsurgical retrotips were commercially available. When compared to burs, the advantages of ultrasonic tips are: easier access to root ends, smaller osteotomy needed due to angulation and small size of the retrotips, preparation of deeper cavities following more closely the original path of the root canal which also lessens the risk of lateral perforations [45, 46]. The use of retrotips does not require a beveled root end resection decreasing the possible leakage through dentinal tubules. Furthermore, ultrasonic preparations demonstrated less smear layer when compared to the bur preparation, however, bur preparations showed less superficial debris and better canal debridement of gutta-percha [45]. More cracks and microfractures were found after sonic or ultrasonic root-end preparation but it is still unknown if these influence the healing success [45]. Apical leakage studies did not show any difference between the bur and retrotip cavity preparation, although when coronal leakage was investigated using polymicrobial marker, a better seal was established with ultrasonically prepared cavities [45].

Lasers can also be used in periapical surgery for apex resection or for improving the apical sealing following apicectomy and retrograde filling. Different authors have evaluated ruby, CO_2, Nd: YAG, Er: YAG, excimer and argon laser or combinations of different lasers and their effects upon soft and hard tissues, as well as on dental materials and instruments [47-50]. The main advantages of laser use in endodontic surgery in comparison to the conventional techniques are reduction in tissue trauma and lower risk of contamination [47].

Among all other lasers, Er: YAG laser has shown the greatest potential in periapical surgery application. This laser can be used in almost all steps of periradicular surgery: incision for flap lifting, bone removal, removal of granulation tissues, apex resection and retrograde cavity preparation because of its efficacy in soft tissue, bone and hard dental tissues removal.

Er: YAG laser was approved by the FDA (Food and Drug Administration) in 1997 and has been since used in dentistry. This laser has a wavelength of 2.940 nm which coincides with the peak of water absorption. The main principle of Er: YAG laser operation is that during laser irradiation, the energy delivered causes vaporization of water within a mineral substrate

giving volume expansion and disruption of dental tissues by micro-explosions, with ejection of both organic and inorganic particles [51, 52]. There is also a small absorption at around 2.800 nm by the hydroxyl group of the hydroxyapatite, although water is the main absorber of laser energy. Regarding mineralized tissues, water is present among the crystals in enamel, dentin, bone and cementum in ascending quantity [53, 54].

Oral soft tissues also contain water and when healthy or minimally pigmented, wavelengths which are highly absorbed in water, like the wavelength of Er: YAG laser, will provide efficient ablation [55]. Er: YAG laser affects 10 to 50 microns thick layers in soft tissues which are important to avoid thermal damage to underlying periosteum and hard dental tissues which are vulnerable to excessive heat, especially in sites with thin oral mucosa [56, 57]. Er: YAG laser use for management of soft oral tissues is advantageous in comparison to scalpel as it provides better hemostasis [58, 59]. Hemostasis occurs due to tissue absorption of laser energy and controlled heating of the tissues, resulting in blood proteins coagulation and sealing of small blood vessels [60-62]. After surgical treatment, bacteria can cause infection and subsequent reduction of bacteria by using Er: YAG laser is also important. Several different mechanisms are responsible for bactericidal effect of the Er: YAG laser. High temperatures during laser irradiation cause changes in the cell wall and membrane of bacteria, denaturization of proteins and damage of nucleic acid which result in bacterial death via photothermal effects [63].

Photothermal effect after absorption of a laser beam in water also causes microexplosions and breakup of bacteria [64]. Yamaguchi [65] found that lipopolysaccharides in the cell membrane of Gram negative bacteria have peak value of absorption of 2.92 μm, which is close to the wavelength of the Er:YAG laser. Furthermore, it was also found that amines and amine groups which are present in bacteria also absorb the wavelength of the Er: YAG laser leading to bacterial death due to photochemical effects [66]. One study performed on the animals compared nociceptive response during Er: YAG laser oral tissue incision and scalpel incision and found less pain when the laser was used [67], which is promising. All these beneficial effects make Er: YAG laser a desirable tool for incision of soft oral tissues for endodontic surgery procedures. Besides the incision, Er: YAG laser may also be used for vaporization of granulation tissue.

Removal of bone by conventional drills in order to perform apicectomy increases the chance of thermal bone damage, causes bacterial decontamination and produces vibrations which are uncomfortable for the patient. Er: YAG laser enables bone ablation to be carried out with minimal thermal damage and the whole procedure is more convenient for the patient due to reduced vibration. In a study by Gabric Panduric [68] Er:YAG laser showed shorter preparation time, a lower heat generation, sharp edges of the preparation sites without bone fragments and minimal thermal alterations of the bone tissues in comparison to the surgical drill. Studies investigating healing of laser-ablated bone showed that the reduction of physical trauma, tissue heating and bacterial contamination may lead to uncomplicated healing processes when compared to conventional surgical methods [69-71]. When compared to the mechanical bur and CO_2 laser groups, Er:YAG irradiated bone tissue showed a more pronounced inflammatory cell infiltration, fibroblastic reaction and a faster revascularization adjacent to the irradiated bone surface with a significantly greater and more rapid bone neo-formation [70], all being desirable after surgical treatments.

Er: YAG laser is also efficient in hard dental tissue removal, namely enamel, dentin and cement. However, the lower ablation rates of the early Er: YAG lasers in comparison to the mechanical bur presented a limitation of their use in dental practice [72-74]. With development of new technology incorporated into Er: YAG laser system with high energies and low pulse durations, the speed of ablation is faster than the diffusion of heat into the tissue, enabling a cold and efficient ablation. Therefore, ablation rates even higher than those obtained with a mechanical handpiece can be achieved [75, 76]. After using different pulses of Er: YAG laser, dentin surface is irregular and clean, with open dentin tubules and no smear layer [76] which may enhance apical seal with modern retrograde filling materials. This makes Er: YAG laser suitable for both root-end resection and preparation.

Different studies have investigated the performance of Er: YAG laser in endodontic surgery. In comparison to Ho: YAG laser, Er: YAG laser produced smoother and cleaner surfaces in the resection area without any thermal damages [77]. Er: YAG laser was also superior in reduction of postoperative complaints and showed better wound healing in comparison to the ultrasound and diamond drills [78]. Another study also confirmed better postoperative healing with Er: YAG laser when compared to the traditional surgical techniques [79]. Cavities prepared with Er: YAG laser had significantly lower microleakage of different retrograde filling materials in comparison to the cavities prepared with ultrasonic [80]. In a study by Grgurevic [81], optimal settings for apicectomy with Er: YAG laser were 380 mJ/100 at microseconds/20 Hz and there was no difference in time needed for root resection in comparison to mechanical handpiece.

Beneficial effects of Er: YAG laser in periradicular surgery are attributed to biostimulatory effect and disinfection of the operating field which promote early healing [82], as well as stimulation of platelet-derived growth factor which enhances the healing of osteotomy sites [83]. Furthermore, Er:YAG laser enhances osteoblast proliferation through activation of the mitogen-activated protein kinase which helps promote healing in periodontal or implant sites [84].

Therefore, Er: YAG laser can be considered as a suitable method for periapical surgery (Figures 20 and 21) as it is an efficient and safe surgical method which ensures good post-operative healing.

Figure 20. Use of Er: YAG laser for bone removal prior to apicectomy (X-Runner, QSP mode, 750 mJ, 10 Hz, 10 ml/min)

Figure 21. Laser-assisted apicectomy of the upper left central and lateral incisors (X-Runner, QSP mode, 750 mJ, 10 Hz, 10 ml/min)

6. Application of ER: YAG laser in bone surgery

Common instruments used for osteotomies in oral surgery are diamond or steel burrs, oscillating saws, chisels or mills [85, 86]. Despite the fact that they are considered a gold standard for bone osteotomies, these instruments have some disadvantages; they are used in contact with the bone tissue with some extent of grinding pressure causing increase of focal temperature, deposition of metal shavings, biomechanical stress, microfractures and dispersal of bony particles and debris into surrounding tissue and osteotomy walls. Bone fragments and fibrin like debris can be found which cover the osteotomy walls after drill instrumentation and can be contributing factor in the infection. The debris can interfere with the wound healing process thus impairing the adhesion of blood elements to the osteotomy walls [68, 86-89]. Hence, alternative methods have been developed for hard tissue surgery [90]. Continuous wave (CW) carbon dioxide (CO_2) laser was the first laser in oral surgery for soft tissue treatment which was introduced in the year 1964 [91]. Shortly after, the development and research of hard tissue laser assisted ablation began [92, 93]. Different types of high energy laser have been investigated, among which the Erbium: Yttrium-Aluminum-garnet (Er: YAG) laser demonstrated the most promising results [94-99]. Er: YAG emits at a wavelength 2.94 μm which has a high absorption in water and hydroxyl ions of hydroxyapatite [100- 102]. The water absorption coefficient of Er: YAG laser is 10 higher than the CO_2 lasers, and 15,000- 20,000 times higher than Nd: YAG lasers [103]. This high absorption rate enables bone ablation with minimal adjacent thermal damage, making Er: YAG lasers safe for use in oral surgical procedures [68, 104, 105, 106]. Erbium laser was the first dental laser cleared by the US Food and Drug Administration for use in cutting human teeth *in vivo* [107].

6.1. Removal of partially erupted third molars

The Er: YAG laser can be used successfully for third molar removal. Histological analyses found no signs of carbonization or charred surfaces which might lead to undisturbed bone

healing. Another advantage of laser ablation was no bone particle or other kind of debris deposits found within the surgery site, absence of mechanical pressure and accurate cut geometry [68, 98, 105-121]. Higher percentage of patients found that the laser assisted surgery was more acceptable compared to the standard drill osteotomy which was explained by the absence of friction sound and vibration. On the other side, the laser osteotomy is more time consuming. Inadequate suction of operative field may lead to prolonged ablation time because increase in volume of irrigation fluid and blood slow down the laser ablation [121]. When a contact free handpiece was used, the ablation process was faster but the intraoral maneuverability of the articulated arm was more difficult, requiring additional care to ensure only ablation of the target tissues [121]. Prolonged treatment may be responsible for an elevated incidence of trismus and swelling in the patients treated with laser in comparison to the surgical bur [122]. Er: YAG lasers lack the feedback of depth control. Hence, in cases of tooth apex proximity to the inferior alveolar nerve, it is recommendable to finish the osteotomy using the surgical bur in order to prevent nerve damage [121].

6.2. Bone graft harvesting

The osteotomy for harvesting bone blocks plays an important role in the success of the bone grafting technique. Incorrect harvesting technique may cause mechanical and thermal damage with reduced or loss of bone vitality. When performed with classical surgical bur or oscillating saw, clinicians are faced with some limitations during bone block grafting due to the mechanical pressure and vibrations, accumulation of debris within the osteotomy lines and in the adjacent soft tissue as well as possible injury of adjacent vital structures. When Er:YAG contact free handpiece with variable squared pulse (VPS) was employed for bone block harvesting excellent results were obtained resulting in reasonable time necessary to finish the osteotomies (2 minutes for the chin bone block harvesting) [105, 114, 123]. The histological results obtained from the bone blocks specimens, showed sharp cutting edges (Figures 22 and 23) and vital bone containing osteocyte lacunae occupied with cells thus presenting normal osteocyte structural characteristics [124]. The anatomical situation in the distal part of the lower jaw limited the access of the laser handpiece preventing the maintenance of predetermined distance between bone surface and the handpiece. Furthermore, deficient aspiration led to water and blood accumulation which inhibited laser ablation because the accumulated fluid formed a protective layer against the laser beam. Afore mentioned reasons make the Er: YAG block osteotomy difficult or impossible in the ramus region [123]. On the other hand, the osteotomy in the symphysis area is straightforward, allowing control of the direction of laser beam and maintenance of predetermined distance. The procedure was much more comfortable for the patients owing to the absence of mechanical stress or vibrations. Lasers are less traumatic when ablating bone compared to surgical burs, hence less bleeding tendency can be observed (Figures 25-27). One major disadvantage of lasers is the lack of depth control which is time consuming and difficult in the ramus region. Periodontal probes can be used for controlling the osteotomy depth [123].

Figure 22. Macroscopic comparison of laser (left) and surgical drill (right) osteotomy (106)



Figure 23. Light microscopy comparison of laser (left) and surgical drill (right) osteotomy (106)



Figure 24. SEM (scanning electron microscopy) comparison of laser (left) and surgical drill (right) osteotomy (106)

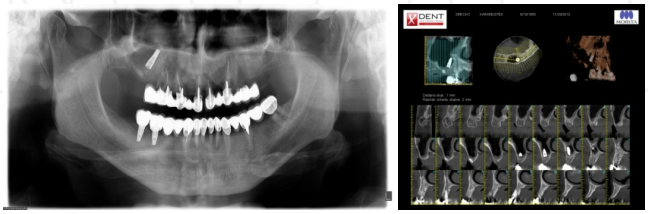

Figure 25. OPG and CBCT of the patient with dislocated dental implant in the right maxillary sinus, after transcrestal sinus floor elevation procedure

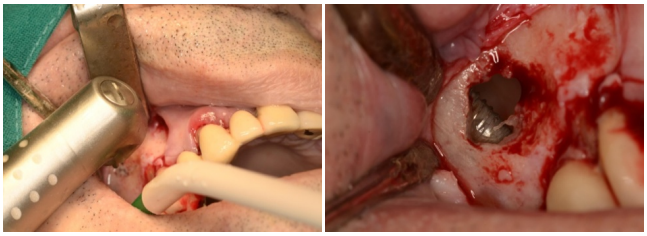

Figure 26. Removal of the cortical plate of the maxilla using Er: YAG laser (X-Runner, QSP mode, 750 mJ, 10 Hz, 10 ml/min) to show the implant within the sinus and to allow implant removal

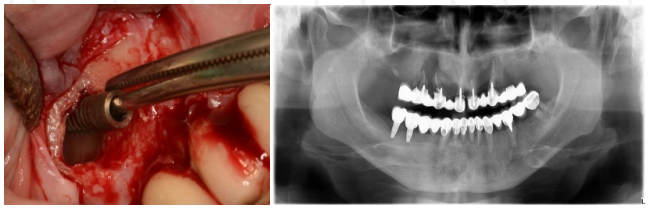

Figure 27. Removal of the implant after laser-assisted sinus surgery (left) and follow-up OPG 3 months after surgery (right)

6.3. Use of Er: YAG laser in the treatment of bisphosphonate-related osteonecrosis of the jaws

In the last decade, there has been an exponentially increasing number of bisphosphonate-related osteonecrosis of the jaws (BRONJ) reports; however its treatment still remains a dilemma. Promising results were accomplished using lasers in the therapy for BRONJ. Er: YAG laser therapy was used for ablation of necrotic bone [105, 83, 125, 126]. When the laser ablation was used in combination with low level laser therapy (LLLT) additional benefits were observed in terms of mucosal healing [83, 125]. Surgical sites treated with Er: YAG showed superior results when compared with traditional surgical treatment and remained stable for a mean follow-up period of 13 months [83]. Atalay [127] evaluated the use of Er:YAG laser (200 mJ, 20 Hz) using a fiber tip 1.3 mm in diameter and 12 mm in length in order to remove necrotic and granulation tissue from the area of avascular necrosis in 10 patients with BRONJ. Their findings [127] suggest that Er: YAG laser surgery is a beneficial alternative in the treatment of patients with BRONJ.

Laser ablation of oral hard tissues has progressively improved. Initial drawbacks, extensive thermal damage of the adjacent tissue, impaired haling and prolonged time necessary for laser osteotomy, were gradually resolved by development of Er: YAG laser with the pulse mode and water spray cooling. Numerous advantages associated with laser bone ablation lead to the fast and safe procedure resulting in the less trauma to the surrounding tissues. Some of these advantages are: minimal thermal damage to the bone, rapid osseous healing, precise cut

geometry with regular shaped borders, absence of organic debris or metal shavings, reduced hard tissue bleeding, the possibility of operating with non contact handpiece, elimination of pressure and vibration from the procedure and decreased risk of injury to the adjacent tissues. Despite these advantages, routine use of Er: a YAG laser has not been established in clinical practice. Some factors which limit the everyday clinical application of lasers in bone ablation are: difficult access in the distal part of the lower jaw, inhibited laser ablation because the fluid accumulation in the deep parts of the surgical field and the lack of depth control. These issues are to be improved in the future. The main disadvantage of laser osteotomies is the inability to control the depth of the cut which my complicate the procedure.

7. Application of ER: YAG laser in dental implantology

7.1. Implant site preparation and second stage surgery

The bone preparation for implant site determines the beginning and the progression of bone healing and the subsequent success of osseointegration of the implant. Direct bone to implant contact (BIC) established without the interposition of non-bone or connective tissue is mandatory for successful osseointegration. Atraumatic bone ostetomy leads to less bone injury, less bone remodeling, better implant to bone contact and hence better implant stability in the early stage of healing [105, 115, 116] (Figures 28 and 29).

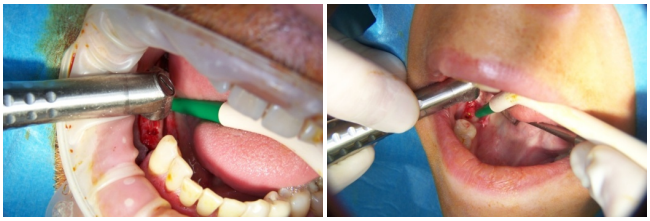

Figure 28. Er:YAG laser (LightWalker, Fotona, Slovenia) usage for preparation of the dental implant site in the lateral part of the right mandible; cortical bone – H02, SP mode, 1000 mJ, 20 Hz, 20 W, water 6, air 4; spongious bone – H14, SP mode, 600 mJ, 20 Hz, 12 W, water 6, air 2 (Courtesy of Dr. Jean Jacques Paverani)

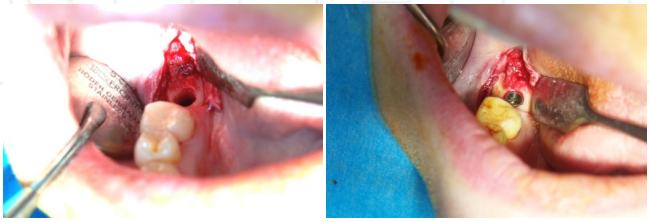

Figure 29. Implant site prepared using laser-assisted surgery (left) and dental implant inserted after laser preparation (right) (Courtesy of Dr. Jean Jacques Paverani)

Since the late 1990 different Er: YAG lasers were tested for implant bed preparation in numerous animal studies. The primary concern was how the thermally changed layer of bone tissue would affect the bone healing and osseointegration. All the authors demonstrated that osseointegration could be successfully achieved after Er: YAG implant bad bone preparation [117-120]. The carbonized amorphous tissue layer produced no irreversible damage and was progressively substituted with new bone in the first 2-12 weeks [118]. Significantly better bone-to-implant contact (BIC) was seen in the surgical drill group compared to the Er: YAG group within first two weeks. Afterwards the differences gradually disappeared and after 12 weeks they were not evident [119]. Some authors found even better results for Er: YAG group compared to the surgical drill group. Histological evaluation revealed higher BIC percentages in the laser prepared bone compared to the drill prepared bone after 3 weeks and 3 months of healing [120].

It can be concluded that Er:YAG laser ablation presents a promising tool for implant bed preparation and second stage surgery for dental implants exposure (Figures 30-32), but some major disadvantages limit the everyday clinical application: manual guided laser osteotomy resulted in a more imprecise osteotomy with a wide gap around implant. Prolonged time required for Er: YAG ablation compared to the surgical drill preparation caused by bleeding at the bottom of the osteotomy cavity can be a potential risk of accidental tissue damage [105].

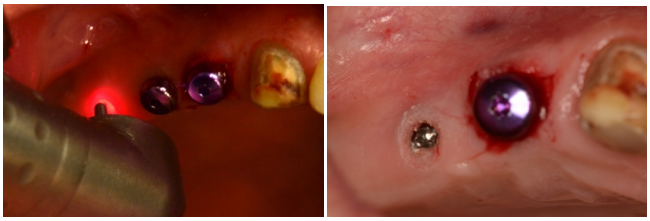

Figure 30. Second stage surgery using Er: YAG laser (X-Runner, QSP mode, 120 mJ, 20 Hz, 10 ml/min)

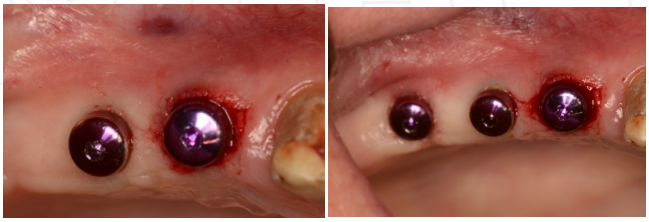

Figure 31. Comparison between Er: YAG laser (lateral implants) and scalpel for second stage surgery (first/mesial implant)

Figure 32. Follow-up healing evaluation 3 days after surgery, same patient.

7.2. Implant surface temperature changes during Er: YAG laser irradiation

It is known that Er: YAG lasers do not induce damage to the titanium implant surfaces when used within appropriate energies. The results of studies have showed that Er: YAG irradiation at 100 mJ/pulse and 10 pps for 60 seconds was safe for use on hydroxylapatite implant surfaces without any microscopic changes noticed. Furthermore, bacterial load on implant surfaces decreased up to 98%. It has been reported that energies exceeding 140-180 mJ/pulse result in implant surface alterations. Monzavi [10] used Er:YAG laser with a wavelength of 2.94 on the sheep model, energy output of 100 mJ/pulse, repetition rates of 10 pps and pulse duration of 230 μs delivered with a non-contact handpiece (4 mm above surface) for 60 seconds. However, Leja [128] reported that irradiation of Er: YAG laser on dental implants for 18 seconds increased the temperature up to 10°C. Fornaini [129] studied in an animal model thermal elevation induced by four different laser wavelengths (diode, Nd: YAG, Er: YAG, KTP) during implant uncovering. The same authors [129] reported that thermocouples recorded a lower increase in temperature for Er: YAG and KTP laser; Nd: YAG and diode lasers produced similar increase in temperature characterized by higher values. The thermo-camera pointed out lower increase for Er: YAG and higher for diode laser. KTP laser resulted in faster uncovering of the implants and diode laser was the one with which more time was needed for the same procedure. This *in vitro* study showed that laser utilization with the recommended parameters is without risk of dangerous thermal elevation to the tissues and implants [129]. Geminiani [9] concluded that irradiation of implant surfaces with CO_2 and Er: YAG lasers may produce a temperature increase above the critical threshold 10^0C after ten seconds of continuous irradiation. Galli [130] reported that Er:YAG laser at energy levels at 150 and 200 mJ/pulse at 10 Hz can alter the surface profile of titanium implants and that these changes may negatively affect the viability and the activity of osteoblastic cells. Therefore, the same authors [130] concluded that Er: YAG lasers should be used with caution on titanium surfaces. Shin [131] evaluated surface roughness and microscopic changes of irradiated dental implant surfaces *in vitro* after use of Er: YAG laser. Irradiation with Er: YAG laser led to the decrease in implant surface roughness that was not significant. The melting and fusion phenomenon of implant surfaces were observed with at all application times (1, 1.5 or 2 minutes) with 180 mJ/pulse irradiation. The sand-blasted, large-grit and acid-etched (SLA) surface implants are stable with laser intensities of less than

140 mJ/pulse and irradiation times less than 2 minutes. With SLA surfaces no significant change in surface texture could be found on any implant surface in the 100 and 140 mJ/pulse subgroups. The anodic oxidized surfaces were not stable with laser intensities of 100 mJ/pulse when Er: YAG laser was used to detoxify implant surfaces [131].

7.3. Implant surface microbial changes during Er: YAG laser irradiation

Tosun [132] examined CO_2, diode and Er:YAG laser irradiation on *Staphylococcus aureus* contaminated, sandblasted, large-grit, acid-etched surface titanium discs and concluded that complete or near complete elimination of surface bacteria on titanium surfaces can be accomplished *in vitro* by use of CO_2, diode and Er:YAG laser as long as appropriate parameters are used [132].

7.4. Treatment of peri-implantitis

In the published literature, there are several reports upon use of Er: YAG lasers for debridement which results in decontamination of implant surface in patients suffering from peri-implantitis [133-137]. As lasers use unidirectional light beams they gain better access to all implant surfaces in comparison to the manual curettes and ultrasonic tips. Furthermore, Er: YAG does not cause alterations of the implant surface. Also Er: YAG lasers are suitable for calculus elimination. Badran [138] used Er: YAG laser (energy 120 mJ; frequency 10 Hz) and sterile water irrigation for the treatment of severe peri-implantitis. Each site was irradiated with Er: YAG laser for 60 seconds, with a 10-15 degree working angulation during six weeks. The results of their study [138] showed that severe cases of peri-implantitis may be cured by use of Er: YAG laser. Fast healing, ease of use, bactericidal effect, effective ablation, hemostasis and adaptation with irregular implant surface are the main advantages of laser beam for treatment of peri-implantitis. Major side effects of laser application on metal objects inserted in the vital bone is thermal increase. Eriksson [139] demonstrated that increase of 10°C during 60 seconds leads to the permanent damage of bone tissues. Renvert [140] compared treatment of severe peri-implantitis either by use of air-abrasive or Er: YAG monotherapy. The same authors concluded that there were no differences between the bleeding on probing (BOP), periodontal pocket depth (PPD) and bone gain regarding the type of the aforementioned treatments [140]. Schwarz [141] reported that 4-year clinical outcomes obtained following combined surgical resective-regenerative therapy of advanced peri-implantitis were not influenced by the method of surface decontamination, i.e. Er: YAG laser or with plastic curettes/cotton pellets/sterile saline. Taniguchi [137] concluded that optimized irradiation parameters effectively removed calcified deposits from contaminated titanium microstructures without causing substantial thermal damage. It seems that Er:YAG laser irradiation at pulse energies below 30 mJ/pulse (10.6 J/cm^2/pulse) and 30 Hz with water spray in near contact mode did not cause damage and resulted in effective debriding of the microstructure surfaces (except for anodized microstructures). Nevins [142] investigated use of Er:YAG laser in order to decontaminate complex rough surface of the implant by stripping the contaminated oxide laser for induction of hard and soft tissue adaptation to a compromised or failing implant. The results

have shown that new bone-implant contact was established along the whole defect area without any evidence of inflammation.

8. Conclusion

Laser technology has made rapid progress over the past decades, and lasers have found a niche in many surgical specialties. Because of their many advantages, lasers have become indispensable in OMS as a additional modality for soft and hard tissue surgery. There are many uses for lasers in OMS, and the advent of new wavelengths will undoubtedly lead to new procedures that can be performed with laser technology. Practitioners should seek novel clinical approaches with a sound scientific basis. Despite the enthusiastic acceptance of this technology by professionals and the public, further research, including controlled clinical studies, to investigate the higher efficacy, as well as side effects of laser therapy, are still needed.

> *"The medical application of the laser is fascinating for two reasons. It is an optimistic mission, on the one hand, while on the other it counteracts the original impression of the laser being a death ray."*

Dr. Theodore Maiman, the inventor of the first laser

Acknowledgements

The authors are grateful to Fotona D.D. for technical support. We would like to thank our clinical photographers Mirjana Krajačić and Darije Petolas, and especially all employees of the Department of Oral Surgery and Department of Oral Medicine, School of Dental Medicine, University of Zagreb.

Author details

Dragana Gabrić[1*], Anja Baraba[2], Goran Batinjan[1], Marko Blašković[1], Vanja Vučićević Boras[3], Irina Filipović Zore[1], Ivana Miletić[2] and Elizabeta Gjorgievska[4]

*Address all correspondence to: dgabric@sfzg.hr

1 Department of Oral Surgery, School of Dental Medicine, University of Zagreb; University Dental Clinic, Clinical Hospital Center Zagreb, Zagreb, Croatia

2 Department of Endodontics and Restorative Dentistry, School of Dental Medicine, University of Zagreb; University Dental Clinic, Clinical Hospital Center Zagreb, Zagreb, Croatia

3 Department of Oral Medicine, School of Dental Medicine, University of Zagreb; University Dental Clinic, Clinical Hospital Center Zagreb, Zagreb, Croatia

4 Department of Pediatric and Preventive Dentistry, Faculty of Dentistry, University of Skopje, Macedonia

References

[1] Moshonov J, Stabholz A, Leopold Y, Rosenberg I, Stabholz A. Lasers in dentistry. Part B-Interaction with biological tissues and the effect on the soft tissues of the oral cavity, the hard tissues of the tooth and the dental pulp. Refuat Hapeh Vehashinayim 2001;18(3-4): 107-108.

[2] Fujii T, Bachni PC, Kawai O, Kwawkomi T, Matsuda K, Kowashi Y. Scanning electron microscopic study of the Er:YAG laser on root cementum. Journal of Periodontology 1998;69(11): 1283-1290.

[3] Simşek Kaya G, Yapici Yavuz G, Sümbüllü MA, Dayi E. A comparison of diode laser and Er:YAG lasers in the treatment of gingival melanin pigmentation. Oral Surgery Oral Medicine Oral Pathology Oral Radiology and Endodontology 2012; 113(3): 293-9.

[4] Komori T, Yokoyama K, Matsumoto Y, Matsumoto K. Erbium:YAG and holmium: YAG laser root resection of extracted human teeth. Journal of Clinical Laser Medicine Surgery 1997; 15(1): 9-13.

[5] Gouw-Soares S, Tanji E, Haypek P, Cardoso W, Eduardo CP. The use of Er:YAG, Nd:YAG and Ga-Al-As lasers in periapical surgery: a 3-year clinical study. Journal of Clinical Laser Medicine Surgery 2001;19(4): 193-198.

[6] Fisher SE, Frame JW, Browne RM, Tranter RM. A comparative histological study of wound healing following CO_2 laser and conventional surgical excision of canine buccal mucosa. Archives of Oral Biology 1983;28(4): 287-291.

[7] Schuller DE. Use of laser in the oral cavity. Otorhinolaryngology Clinics of North America 1990;23(1): 31-42.

[8] Kreisler M, Al Haj H, d'Hoedt B. Temperature changes at the implant-bone interface during simulated surface decontamination with an Er:YAG laser. International Journal of Prosthodontics 2002;15(6): 582-7.

[9] Geminiani A, Caton JG, Romanos GE. Temperature increase during CO_2 and Er:YAG irradiation on implant surfaces. Implant Dentistry 2011;20(5): 379-382.

[10] Monzavi A, Shahabi S, Fekrazad R, Behruzi R, Chiniforush N. Implant surface temperature changes during Er:YAG laser irradiation with different cooling systems. Journal of Dentistry 2014;11(2): 210-215.

[11] Mitsunaga S, Iwai T, Kitajima H, Yajima Y, Ohya T, Hirota M Cervicofacial subcutaneous emphysema associated with dental laser treatment. Australian Dental Journal 2013;58(4): 424-427.

[12] Onisor I, Pecie R, Cheskelis I, Krejci I. Cutting and coagulation during intraoral soft tissue surgery using Er:YAG laser. European Journal of Paediatric Dentistry 2013;14(2): 140-145.

[13] Kaya A, Ugurlu F, Basel B, Sener CB. Oral pyogenic granuloma associated with a dental implant treated with an Er:YAG laser: a case report. Journal of Oral Implantology 2013; doi: 10.1563/AAID-JOI-D-13-00251

[14] Türer CC, Ipek H, Kirtiloglu T, Acikgoz G. Dimensional changes in free gingival grafts: scalpel versus Er:YAG laser: a preliminary study. Lasers in Medical Science 2013; doi: 10.1007/s10103-013-1349-7

[15] Stelzle F, Terwey I, Knipfer C, Adler W, Tangermann-Gerk K, Nkenke E The impact of laser ablation on optical soft tissue differentiation for tissue specific laser surgery-an experimental ex vivo study. Journal of Translational Medicine 2012; doi: 10.1186/1479-5876-10-123

[16] Fikáčková H, Navrátilová B, Dylevský I, Navrátil L, Jirman R. Assessment of the effect of non invasive laser on the process of healing of an extraction wound by infrared thermography: preliminary study. Journal of Applied Biomedicine 2003; 1: 175–180.

[17] Lomke MA. Clinical applications of dental lasers. General Dentistry 2009; 57(1): 47-59.

[18] Namour, S. Atlas of current oral laser surgery. Florida, USA: Universal-Publishers Boca Raton;2011.

[19] Aras MH, Göregen M, Güngörmüş M, Akgül HM. Comparison of diode laser and Er:YAG lasers in the treatment of ankyloglossia. Photomedicine and Laser Surgery 2010; 2: 173-177.

[20] Koort HJ, Hopp M, Gabrić Pandurić D. A combined device for optimal soft tissue applicaions in laser dentistry. Laser 2013;5(4) 24-29.

[21] Merigo E, Clini F, Fornaini C, Oppici A, Paties C, Zangrandi A, Laser-assisted surgery with different wavelengths: a preliminary ex vivo study on thermal increase and histological evaluation. Lasers in Medical Science 2013; 28(2): 497-504.

[22] Fornaini C, Rocca JP, Bertrand MF, Merigo E, Nammour S, Vescovi P. Nd:YAG and diode laser in the surgical management of soft tissues related to orthodontic treatment and laser surgery. Photomedicine and Laser Surgery 2007; 25(5): 381-392.

[23] Tomov GT, Bachurska SY, Tashkova DA, Ivanov GP. Pathomorphological distinction between Er:YAG and diode lasers on the excisional biopsy of the oral mucosa. Russian Open Medical Journal 2013; 2(1): 107-111.

[24] van der Waal I. Potentially malignant disorders of the oral and oropharyngeal mucosa; present concepts of management. Oral Oncology 2010;46(6): 423-425.

[25] Lodi G, Porter S. Management of potentially malignant disorders: evidence and critique. Journal of Oral Pathology and Medicine 2008;37(2): 63-69.

[26] van der Waal I, Schepman KP, van der Meij EH, Smeele LE. Oral leukoplakia: a clinicopathological review. Oral Oncology 1997;33(5): 291–301.

[27] Gabrić Pandurić D, Katanec D, Filipović Zore I. Clinical cases of soft-tissue surgery with X-Runner in QSP mode. Journal of Laser and Health Academy 2013;2(2) 34-37.

[28] Brouns E, Baart J, Karagozoglu K, Aartman I, Bloemena E, van der Waal I. Treatment results of CO(2) laser vaporisation in a cohort of 35 patients with oral leukoplakia. Oral Diseases 2013;19(2): 212-216.

[29] Jerjes W, Upile T, Hamdoon Z, Al-Khawalde M, Morcos M, Mosse CA, Hopper C.CO2 laser of oral dysplasia: clinicopathological features of recurrence and malignant transformation. Lasers in Medical Science 2012;27(1): 169-179.

[30] Deppe H, Mücke T, Hohlweg-Majert B, Hauck W, Wagenpfeil S, Hölzle F. Different CO2 laser vaporization protocols for the therapy of oral precancerous lesions and precancerous conditions: a 10-year follow-up. Lasers in Medical Science 2012;27(1): 59-63.

[31] Roodenburg JL. Dissertations 25 years after date 29. CO2 laser surgery of leukoplakia of the oral mucosa. Nederlands Tijdschrift voor Tandheelkunde 2011;118(10): 496-500.

[32] Ergun S, Saruhanoglu A, Migliari DA, Maden I, Tanyeri H. Refractory pigmentation associated with Laugier-Hunziker syndrome following Er:YAG laser treatment. Case Reports in Dentistry 2013; doi: 10.1155/2013/561040.

[33] Friedman S. Treatment outcome and prognosis of endodontic therapy. In: Ørstavik D, Pitt Ford TR, eds. Essential endodontology: Prevention and treatment of apical periodontitis. Oxford: Blackwell Science; 1998.

[34] Ng YL, Mann V, Rahbaran S, Lewsey J, Gulabivala K. Outcome of primary root canal treatment: systematic review of the literature– Part 2: Influence of clinical factors. International Endodontic Journal 2008;41(1) 6–31.

[35] Rahbaran S, Gilthorpe MS, Harrison SD, Gulabivala K Comparison of clinical outcome of periapical surgery in endodontic and oral surgery units of a teaching hospi-

tal: A retrospective study. Oral Surgery Oral Medicine Oral Pathology Oral Radiology and Endodontology 2001;91(6) 700–709.

[36] Saunders WP. A prospective clinical study of periradicular surgery using mineral trioxide aggregate as a root-end filling. Journal of Endodontics 2008;34(6) 660–665.

[37] Tsesis I, Faivishevsky, Kfir A, Rosen E. Outcome of surgical endodontic treatment performed by a modern technique: a meta-analysis of the literature. Journal of Endodontics 2009;35(11) 1505–1511.

[38] Setzer FC, Shah SB, Kohli MR, Karabucak B, Kim S. Outcome of endodontic surgery: A meta-analysis of the literature –Part 1: Comparison of traditional root-end surgery and endodontic microsurgery. Journal of Endodontics 2010;36(11) 1757–1765.

[39] el-Swiah JM, Walker RT. Reasons for apicectomies. A retrospective study. Endodontics & Dental Traumatology 1996;12(4) 185–191.

[40] ESE/European Society of Endodontology: Consensus report of the European Society of Endodontology on quality guidelines for endodontic treatment. International Endodontic Journal 1994;27(3) 115-124.

[41] Tsesis I, Faivishevsky, Kfir A, Rosen E. Outcome of surgical endodontic treatment performed by a modern technique: a meta-analysis of the literature. Journal of Endodontics 2009;35(11) 1505–1511.

[42] Gilheany PA, Figdor D, Tyas MJ. Apical dentin permeability and microleakage associated with root end resection and retrograde filling. Journal of Endodontics 1994;20(1) 22–26.

[43] Hsu YY, Kim S. The resected root surface. The issue of canal isthmuses. Dental Clinics of North America 1997;41(3) 529–540.

[44] Wada M, Takase T, Nakanuma K, Arisue K, Nagahama F, Yamazaki M. Clinical study of refractory apical periodontitis treated by apicectomy – Part 1: Root canal morphology of resected apex. International Endodontic Journal 1998;31(1) 53–56.

[45] von Arx T, Walker WA. Microsurgical instruments for root-end cavity preparation following apicectomy: a literature review. Endodontics & Dental Traumatology 2000;16(2) 47–62.

[46] von Arx T, Kurt B, Ilgenstein B, Hardt N Preliminary results and analysis of a new set of sonic instruments for root-end cavity preparation. International Endodontic Journal 1998;31(1) 32-38.

[47] Bader G, Lejeune S. Prospective study of two retrograde endodontic apical preparations with and without the use of CO_2 laser. Endodontics & Dental Traumatology 1998;14(2) 75-78.

[48] Moritz A, Gutknecht N, Goharkhay K, Schoop U, Wemish J, Sperr W. The carbon dioxide laser as an aid in apicectomy: an in vitro study. Journal of Clinical Laser Medicine & Surgery 1997;15(4) 185-188.

[49] Kimura Y, Wilder-Smith P, Matsumoto K. Lasers in endodontics. A review. International Endodontic Journal 2000;33(3) 173-185.

[50] Gouw-Soares S, Tanji E, Haypek P, Cardoso W, Eduardo CP. The use of Er:YAG, Nd:YAG and Ga-Al-As lasers in periapical surgery: a 3-year clinical study. Journal of Clinical Laser Medicine & Surgery 2001;19(4) 193-198.

[51] Gurgan S, Kiremitci A, Cakir FY, Yazici E, Gorucu J, Gutknecht N. Shear bond strength of composite bonded to erbium:yttrium-aluminum-garnet laser-prepared dentin. Lasers in Medical Science 2009;24(1) 117-122.

[52] Hossain M, Nakamura Y, Yamada Y, Kimura Y, Nakamura G, Matsumoto K. Ablation depths and morphological changes in human enamel and entin after Er:YAG laser irradiation with or without water mist. Journal of Clinical Laser Medicine & Surgery 1999;17(3) 105-109.

[53] Meister J, Franzen R, Forner K, Grebe H, Stanzel S, Lampert F, Apel C. Influence of water content in dental on ablation with erbium YAG and erbium YSGG lasers. Journal of Biomedical Optics 2006;11(3) 34030.

[54] Wigdor H, Abt E, Ashrafi S, Walash JT Jr. The effect of lasers on dental hard tissues. Journal of American Dental Association 1993;124(2) 65-70.

[55] Coluzzi D. Fundamentals of dental lasers: Science and instruments. Dental Clinics of North America 2004;48(4) 751-770.

[56] Walsh JT Jr, Flotte TJ, Deutsch TF. Er:YAG laser ablation of tissue: Effect of pulse duration and tissue type on thermal damage. Lasers in Surgery and Medicine 1989;9(4) 314-326.

[57] Cobb C, Low SB, Coluzzi DJ. Lasers and the treatment of chronic periodontitis. Dental Clinics of North America 2010;54(1) 35-53.

[58] Ishikawa I, Aoki A, Takasaki AA. Potential applications of erbium:YAG laser in periodontics. Journal of Periodontal Research 2004;39(4) 275-285.

[59] Coluzzi DJ. Fundamentals of lasers in dentistry: Basic science, tissue interaction, and instrumentation. Journal of Laser Dentistry 2008;16(Spec. Issue) 4-10.

[60] Black JF, Barton JK. Chemical and structural changes in blood undergoing laser photocoagulation. Photochemistry and Photobiology 2004;80 89-97.

[61] Zhu D, Luo Q, Zhu G, Liu W. Kinetic thermal response and damage in laser coagulation of tissue. Lasers in Surgery and Medicine 2002;31(5) 313-321.

[62] Mordon S, Rochon P, Dhelin G, Lesage JC. Dynamics of temperature dependent modifications of blood in the near-infrared. Lasers in Surgery and Medicine 2005;37(4) 301-307.

[63] Wilson M. Photolysis of oral bacteria and its potential use in the treatment of caries and periodontal disease. The Journal of Applied Bacteriology 1993;75(4) 299-306.

[64] Ando Y, Aoki A, Watanabe H, Ishikawa I. Bactericidal effect of Erbium YAG laser on periodontopathic bacteria. Lasers in Surgery and Medicine. 1996;19(2) 190-200.

[65] Yamaguchi H, Kobayashi K, Osada R, Sakurabe E, Nomura T, Arai T, Nakamura J. Effects of irradiation of an erbium:YAG laser on root surfaces. Journal of Periodontology 1997;68(12) 1151-1155.

[66] Socrates G. Infrared and Raman Characteristics group frequencies: tables and charts, Chichester: John Wiley & Sons; 2001.

[67] Zeredo JL, Sasaki Km, Yozgatian JH, Okada Y, Toda K. Comparison of jaw-opening reflexes evoked by Er:YAG laser versus scalpel incisions in rats. Oral Surgery Oral Medicine Oral Pathol Oral Radiology and Endododontology 2005;100(1) 31-35.

[68] Gabrić Pandurić D, Bago I, Katanec D, Zabkar J, Miletić I, Anić I. Comparison of Er:YAG laser and surgical drill for osteotomy in oral surgery: an experimental study. Journal of Oral and Maxillofacial Surgery 2012;70(11) 2515-2521.

[69] Wang X, Ishizaki NT, Suzuki N, Kimura Y, Matsumoto K. Morphological changes of bovine mandibular bone irradiated by Er:YSSG laser: An in vitro study. Journal of Clinical Laser Medicine and Surgery 2002;20(5) 245-250.

[70] Pourzarandian A, Watanabe H, Aoki A, Ichinose S, Sasaki KM, Nitta H, Ishikawa I. Histological and TEM examination of early stages of bone healing after Er:YAG laser irradiation. Photomedicine and Laser Surgery 2004;22(4) 342-350.

[71] Donnell RJ, Deutsch RJ, Flotte RJ, Lorente CA, Tomford WW, Mankin HJ, Schomacker KT. Effect of Er:YAG laser on osteoinduction in demineralized rat calvarial allografts. Journal of Orthopaedic Research 1996;14(1) 108-113.

[72] Jelínková H, Dostálová T, Doležalová L, Krejsa O, Hamal K, Kubelka J, Prochazka S. Comparison of preparation speed of Er:YAG laser and conventional drilling machine. Lasers in Dentistry III. 1997; doi:10.1117/12.273573.

[73] Yamada Y, Hossin M, Nakamura Y, Suzuki N, Matsumoto K. Comparison between the removal effect of mechanical, Nd: YAG, and Er: YAG laser systems in carious dentin. Journal of Clinical Laser Medicine & Surgery 2001; 19(5) 239-243.

[74] Furtado Messias DC, de Souza-Gabriel AE, Palma-Dibb RG, Rodriguez AL, Campos Serra M. Efficiency and effectivness of Er: YAG laser on carious tissue renoval. Journal of Oral Laser Applications 2006; 6 181-186.

[75] Lukac M, Marincek M, Grad L, Bozic Z. Dental laser drilling: State of art with the latest of the Variable Square Pulse Erbium dental laser systems. Journal of the Laser and Health Academy 2007;6(1) 1-4.

[76] Baraba A, Miletić I, Jukić Krmek S, Perhavec T, Božić Ž, Anić I. Ablative potential of the Er:YAG laser and conventional handpieces: A comparative study. Photomedicine and Laser Surgery 2009;27(6) 921-927.

[77] Komori T, Yokoyama K, Matsumoto Y, Matsumoto K. Erbium:YAG and holmium:YAG laser root resection of extracted human teeth. Journal of Clinical Laser Medicine & Surgery 1997;15(1) 9–13.

[78] Zhao XY, Wang SM, Zhang CF. Root resection by Er:YAG laser: a scanning electron microscope study. Hua Xi Kou Qiang Yi Xue Za Zhi 2010;28(5) 526–528.

[79] Lietzau M, Smeets R, Hanken H, Heiland M, Apel C. Apicectomy using Er:YAG laser in association with microscope: a comparative retrospective investigation. Photomedicine and Laser Surgery. 2013;31(3) 110-115.

[80] Karlovic Z, Pezelj-Ribaric S, Miletic I, Jukic S, Grgurevic J, Anic I. Erbium:YAG laser versus ultrasonic in preparation of root-end cavities. Journal of Endodontics 2005;31(11) 821-823.

[81] Grgurević J, Grgurević L, Miletić I, Karlović Z, Jukić Krmek S, Anić I. In vitro study of the variable square pulse Er:YAG laser cutting efficacy for apicectomy. Lasers in Surgery and Medicine 2005;36(5) 347–350.

[82] Vescovi P, Manfredi M, Mergio E, Meleti M, Fornaini C, Rocca JP, Nammour S. Surgical approach with Er:YAG laser on osteonecrosis of the jaws (ONJ) in patients under bisphosphonate therapy (BPT). Lasers in Medical Science 2010;25(1) 101–113.

[83] Kesler G, Shvero DK, Tov YS, Romanos G. Platelet derived growth factor secretion and bone healing after Er:YAG laser bone irradiation. Journal of Oral Implantology 2011;37(Spec No) 195–204.

[84] Aleksic V, Aoki A, Iwasaki K, Takasaki AA, Wang CY, Abiko Y, Ishikawa I, Izumi Y. Low-level Er:YAG laser irradiation enhances osteoblast proliferation through activation of MAPK/ERK. Lasers in Medical Science 2012;25(4) 559–569.

[85] Stopp S, Deppe H, Lueth T. A new concept for navigated laser surgery. Lasers in Medical Science 2008;23(3) 261-6.

[86] Rupprecht S, Tangermann K, Kessler P, Neukam FW, Wiltfang J. Er:YAG laser osteotomy directed by sensor controlled systems. Journal of Craniomaxillofacial Surgery 2003;31(6) 337-42.

[87] Barone CM, Jimenez DF, Yule GJ, Strauch B. Analysis of bone formation after cranial osteotomies with a high-speed drill. Journal of Craniomaxillofacial Surgery 1997;8(6): 466-70.

[88] Kerawala CJ, Martin IC, Allan W, Williams ED. The effects of operator technique and bur design on temperature during osseous preparation for osteosynthesis self-tapping screws. Oral Surgery Oral Medicine Oral Pathology Oral Radiology and Endodontology 1999;88(2) 145-50.

[89] Kondo S, Okada Y, Iseki H, Hori T, Takakura K, Kobayashi A, Nagata H. Thermological study of drilling bone tissue with a high-speed drill. Neurosurgery 2000;46(5) 1162-8.

[90] Sulewski JG. Historical survey of laser dentistry. Dental Clinics of North America 2000;44(4) 717-752.

[91] Wlodawsky RN, Strauss RA. Intraoral laser surgery. Oral Maxillofacial Surgery Clinics of North America 2004;16(2) 149-163.

[92] Horch HH. Current status of laser osteotomy. Der Orthopade 1984;13(2):125-132.

[93] Clayman L, Fuller T, Beckman H. Healing of continuous-wave and rapid superpulsed, carbon dioxide, laser-induced bone defects. Journal of Oral Surgery 1978;36(12) 932-937.

[94] Peavy GM, Reinisch L, Payne JT, Venugopalan V. Comparison of cortical bone ablations by using infrared laser wavelengths 2.9 to 9.2 microm. Lasers in Medical Science 1999;25(5) 421-434.

[95] Bader C, Krejci I. Indications and limitations of Er:YAG laser applications in dentistry. American Journal of Dentistry 2006;19(3) 178-186.

[96] Bornstein ES, Lomke MA. The safety and effectiveness of dental Er:YAG lasers. A literature review with specific reference to bone. Dentistry Today 2003;22(10) 129-133.

[97] Buchelt M, Kutschera HP, Katterschafka T, Kiss H, Lang S, Beer R, Losert U. Er:YAG and Hol:YAG laser osteotomy: the effect of laser ablation on bone healing. Lasers in Surgery and Medicine 1994;15(4) 373-381.

[98] Sasaki KM, Aoki A, Ichinose S, Ishikawa I. Ultrastructural analysis of bone tissue irradiated by Er:YAG. Lasers in Surgery and Medicine 2002;31(5) 322-332

[99] Sasaki KM, Aoki A, Ichinose S, Yoshino T, Yamada S, Ishikawa I. Scanning electron microscopy and Fourier transformed infrared spectroscopy analysis of bone removal using Er:YAG and CO2 lasers. Journal of Periodontology 2002;73(6) 643-652.

[100] Iaria G. Clinical, morphological, and ultrastructural aspects with the use of Er:YAG and Er,Cr:YSGG lasers in restorative dentistry. General Dentistry 2008;56(7) 636-639.

[101] Convissar RA. The biologic rationale for the use of lasers in dentistry. Dental Clinics North America 2004;48(4) 771-794.

[102] Kang HW, Oh J, Welch AJ. Investigations on laser hard tissue ablation under various environments. Physics in Medicine and Biology 2008 ;53(12) 3381-3390.

[103] Schwarz F, Aoki A, Sculean A, Becker J. The impact of laser application on periodontal and peri-implant wound healing. Periodontology 2000. 2009; doi: 10.1111/j.1600-0757.2009.00301.x..

[104] Pandurić DG, Jurić IB, Musić S, Molčanov K, Sušić M, Anić I. Morphological and ultrastructural comparative analysis of bone tissue after Er:YAG laser and surgical drill osteotomy. Photomedicine and Laser Surgery 2014;32(7) 401-408.

[105] Stübinger S. Advances in bone surgery: the Er:YAG laser in oral surgery and implant dentistry. Clinical, Cosmetic and Investigational Dentistry 2010;2(1) 47-62.

[106] Gabrić Pandurić D. Physical and ultrastructural bone effect comparison between laser and surgical drill. PhD thesis. University of Zagreb; 2010.

[107] Cozean C, Arcoria CJ, Pelagalli J, Powell GL. Dentistry for the 21st century? Erbium:YAG laser for teeth. Journal of the American Dental Association 1997;128(8) 1080-1087.

[108] Nuss RC, Fabian RL, Sarkar R, Puliafito CA. Infrared laser bone ablation. Lasers in Surgery and Medicine. 1988;8(4) 381-391.

[109] Nanni C. Complications of laser surgery. Dermatology Clinics. 1997;15(3) 521-534.

[110] Walsh JT Jr, Deutsch TF. Er:YAG laser ablation of tissue: measurement of ablation rates. Lasers in Surgery and Medicine 1989;9(4) 327-337.

[111] de Mello ED, Pagnoncelli RM, Munin E, Filho MS, de Mello GP, Arisawa EA, de Oliveira MG. Comparative histological analysis of bone healing of standardized bone defects performed with the Er:YAG laser and steel burs. Lasers in Medical Science 2008;23(3) 253-260.

[112] Choi B, Welch AJ. Analysis of thermal relaxation during laser irradiation of tissue. Lasers in Surgery and Medicine 2001;29(4) 351-359.

[113] Yoshino T, Aoki A, Oda S, Takasaki AA, Mizutani K, Sasaki KM, Kinoshita A, Watanabe H, Ishikawa I, Izumi Y. Long-term histologic analysis of bone tissue alteration and healing following Er:YAG laser irradiation compared to electrosurgery. Journal of Periodontology 2009;80(1) 82-92.

[114] Stübinger S, Landes C, Seitz O, Sader R. Er:YAG laser osteotomy for intraoral bone grafting procedures: a case series with a fiber-optic delivery system. Journal of Periodontology 2007;78(12) 2389-2394.

[115] Sharawy M, Misch CE, Weller N, Tehemar S. Heat generation during implant drilling: the significance of motor speed. Journal of Oral and Maxillofacial Surgery 2002;60(10) 1160-1169.

[116] Wu X, Deng F, Wang Z, Zhao Z, Wang J. Biomechanical and histomorphometric analysis of the osseointegration of microscrews with different surgical techniques in

beagle dogs. Oral Surgery Oral Medicine Oral Pathology Oral Radiology and Endodontology 2008;106(5) 644-650.

[117] el-Montaser M, Devlin H, Dickinson MR, Sloan P, Lloyd RE. Osseointegration of titanium metal implants in erbium-YAG laser-prepared bone. Implant Dentistry 1999;8(1) 79-85.

[118] Salina S, Maiorana C, Iezzi G, Colombo A, Fontana F, Piattelli A. Histological evaluation, in rabbit tibiae, of osseointegration of mini-implants in sites prepared with Er:YAG laser versus sites prepared with traditional burs. Journal of long-term effects of medical implants 2006;16(2) 145-156.

[119] Schwarz F, Olivier W, Herten M, Sager M, Chaker A, Becker J. Influence of implant bed preparation using an Er:YAG laser on the osseointegration of titanium implants: a histomorphometrical study in dogs. Journal of Oral Rehabilitation. 2007;34(4) 273-281.

[120] Kesler G, Romanos G, Koren R. Use of Er:YAG laser to improve osseointegration of titanium alloy implants--a comparison of bone healing. International Journal of Oral & Maxillofacial Implants. 2006;21(3) 375-379.

[121] Stübinger S, von Rechenberg vB, Zeilhofer HF, Sader R, Landes C. Er:YAG laser osteotomy for removal of impacted teeth: clinical comparison of two techniques. Lasers in Surgery and Medicine 2007;39(7) 583-588.

[122] Abu-Serriah M, Critchlow H, Whitters CJ, Ayoub A. Removal of partially erupted third molars using an Erbium (Er):YAG laser: a randomised controlled clinical trial. British Journal of Oral & Maxillofacial Surgery. 2004;42(3) 203-208.

[123] Stübinger S, Nuss K, Landes C, von Rechenberg B, Sader R. Harvesting of intraoral autogenous block grafts from the chin and ramus region: preliminary results with a variablesquare pulse Er:YAG laser. Lasers in Surgery and Medicine. 2008;40(5) 312-318.

[124] Stübinger S, Ghanaati S, Saldamli B, Kirkpatrick CJ, Sader R Er:YAG laser osteotomy: preliminary clinical and histological results of a new technique for contact-free bone-surgery. European Surgical Research 2009;42(3) 150-156.

[125] Vescovi P, Merigo E, Meleti M, Manfredi M, Fornaini C, Nammour S. Surgical Approach and Laser Applications in BRONJ Osteoporotic and Cancer Patients. Journal of Osteoporosis 2012;doi:10.1155/2012/585434.

[126] Angiero F, Sannino C, Borloni R, Crippa R, Benedicenti S, Romanos GE. Osteonecrosis of the jaws caused by bisphosphonates: evaluation of a new therapeuticapproach using the Er:YAG laser. Lasers in Medical Science 2009;24(6) 849-856.

[127] Atalay B, Yalcin S, Emes Y, Aktas I, Aybar B, Issever H, Mandel NM, Cetin O, Oncu B. Bisphosphonate-related osteonecrosis: laser-assisted surgical treatment or conventional surgery? Lasers in Medical Science 2011; 26(6) 815-823.

[128] Leja C, Geminiani A, Caton J, Romanos GE. Thermodynamic effects of laser irradiation of implants placed in bone: an in vitro study. Lasers in Medical Science 2013;28(6) 1435-1440.

[129] Fornaini C, Merigo E, Vescovi P, Bonanini M, Antonietti W, Leoci L, Lagori G, Meleti M. Different laser wavelengths comparison in the second-stage implant surgery: an ex vivo study. Lasers in Medical Science 2014; doi: 10.1007/s10103-014-1623-3.

[130] Galli C, Macaluso GM, Elezi E, Ravanetti F, Cacchioli A, Gualini G, Passeri G. The effects of Er:YAG laser treatment on titanium surfce profile and osteoblastic cell activity: an in vitro study. Journal of Periodontology 2011; 82(8) 1169-1177.

[131] Shin Sl, Min HK, Park BH, Kwon YH, Park JB, Herr Y, Heo SJ, Chung JH. The effect of Er:YAG laser irradiation on the scanning electron microscopic structure and surface roughness of various implant surfaces: an in vitro study. Lasers in Medical Science 2011; 26(6) 767-776.

[132] Tosun E, Tasar F, Strauss R, Kivanc DG, Ungor C. Comparative evaluation of antimicrobial effects of Er:YAG, diode and CO_2 lasers on titanium discs: an experimental study. Journal of Oral and Maxillofacial Surgery 2012; 70(5): 1064-1069.

[133] Stubinger S, Homann F, Etter C, Miskiewicz M, Wjeland M, Sader R. Effect of Er:YAG, CO_2 and diode laser irradiation on surface properties of zirconia endosseous dental implants. Lasers in Surgery and Medicine 2008; 40(3): 223-228.

[134] Takasaki AA, Aoki A, Mizutani K, Kikuchi S, Oda S, Ishikawa I. Er:YAG laser therapy for peri-implant infection: a histological study. Lasers in Medical Science 2007; 22(3): 143-157.

[135] Sculean A, Schwarz F, Becker J. Anti-infective therapy with an Er:YAG laser: influence on peri-implant healing. Expert Review of Medical Devices 2005; 2(3): 267-276.

[136] Schwarz F, Sculean A, Rothamel D, Schwenzer K, Georg T, Becker J. Clinical evaluation of an Er:YAG laser for non-surgical treatment of peri-implantitis: a pilot study. Clin Oral Implants Research 2005; 16(1): 44-52.

[137] Taniguchi Y, Aoki A, Mizutani K, Takeuchi Y, Ichinose S, Takasaki AA, Schwarz F, Izumi Y. Optimal Er:YAG laser irradiation parameters for debridement of microstructured fixture surfaces of titanium dental implants. Lasers in Medical Science 2013; 28(4): 1057-1068.

[138] Badran Z, Bories C, Struillou X, Saffarzadeh A, Verner C, Soueidan A. Er:YAG laser in the clinical management of severe peri-implantitis: a case report. Journal of Oral Implantology 2013; 37:212-217.

[139] Eriksson AR, Albrektsson T. Temperature threshold levels for heat-induced bone tissue injury: a vital microscopic study in the rabbit. Journal of Prosthetic Dentistry 1983; 50(1):101-107.

[140] Renvert S, Lindahl C, Roos Jansaker AM, Persson GR. Treatment of peri-implantitis using an Er:YAG laser or an air-abrasive device: a randomized clinical trial. Journal of Clinical Periodontology 2011; 38(1) 65-73.

[141] Schwarz F, Hegewald A, John G, Sahm N, Becker J. Four-year follow-up of combined surgical therapy of advanced peri-implantitis evaluating two methods of surface decontamination. Journal of Clinical Periodontology 2013; 40(10) 962-967.

[142] Nevins M, Nevins ML, Yamamoto A, Yoshino T, Ono Y, Wang CW, Kim DM. Use of Er:YAG laser to decontaminate infected implant surface in preparation for reestablishment of bone to implant contact. International Journal of Periodontics and Restorative Dentistry 2014; 34(4) 461-466.