

# Tooth in the maxillary sinus

---

**Grubišić, Anđela**

**Master's thesis / Diplomski rad**

**2024**

*Degree Grantor / Ustanova koja je dodijelila akademski / stručni stupanj:* **University of Zagreb, School of Dental Medicine / Sveučilište u Zagrebu, Stomatološki fakultet**

*Permanent link / Trajna poveznica:* <https://um.nsk.hr/um:nbn:hr:127:028874>

*Rights / Prava:* [In copyright](#)/[Zaštićeno autorskim pravom.](#)

*Download date / Datum preuzimanja:* **2024-12-01**



*Repository / Repozitorij:*

[University of Zagreb School of Dental Medicine  
Repository](#)





University of Zagreb  
School of Dental Medicine

Andela Grubišić

# **TOOTH IN THE MAXILLARY SINUS**

GRADUATE THESIS

Zagreb, 2024.

This work has been carried out at the: Department of Oral Surgery, University Hospital Dubrava, Zagreb

Thesis mentor: Assist. Prof. Josip Biočić ; Department of Oral Surgery, University Hospital Dubrava, Zagreb

English language proofreader: prof. eng. jezika Anđela Kraljević

Croatian language proofreader: prof. hrv. jezika : Ilija Barišić

Thesis contains: 41 pages  
0 tables  
4 figures

The work presented here is the author's work, written independently while citing other authors and documents used. Unless otherwise stated, all illustrations (tables, pictures, etc.) in the paper are the original contribution of the post-graduate author's specialist work. The author is responsible for obtaining permission to use illustrations that are not his original contribution, as well as for all possible consequences that may arise due to the illegality downloading of illustrations, i.e. failure to state their origin.

## Acknowledgments:

*Thank you, God, for the gifts and the grace you have given me, and the strength to get through this.*

*"May the love for my art actuate me at all times; may neither avarice nor miserliness, nor thirst for glory or for a great reputation engage my mind; for the enemies of truth and philanthropy could easily deceive me and make me forgetful of my lofty aim of doing good to Thy children.*

*May I never see in the patient anything but a fellow creature in pain.  
.... here am I ready for my vocation and now I turn unto my calling."*

*- Oath of Maimonides*

*I dedicate this work to my father Marinko; my mother Vesna  
my brother Ivan; my sisters Tina, Iva, Katarina, and Lucija;  
and my nieces and nephews: Marko, Lucia, Max, Niko and Maria.  
Thank you for your love and support throughout these six years of my studies.*

*Thank you for always believing in me. I am truly blessed to have you!*

I completed this graduation thesis with the guidance and expertise of my mentor, doc. dr. sc. Josip Biočić. I am deeply grateful for your invaluable help and patience throughout the process.

I want to express my gratitude to Tina Papac for her kindness and contribution to my English; to Prof. Matijević for generously sharing his expertise and life wisdom, to Mr.sc Sunčica Gabelica, who has guided me with her knowledge and advice; to my best friends Sara, Mara, Petra and Nikolina for making this journey easier; and to my colleagues, with whom six years have passed in the blink of an eye, thank you for the unforgettable student days that I will cherish forever.

## TOOTH IN THE MAXILLARY SINUS

### Summary

The accidental displacement of teeth into the maxillary sinus during extractions is rare but can have serious consequences. Due to their proximity to the sinus, this mostly happens during maxillary molar extractions. Developmental disorders, iatrogenic events, trauma, or pathological processes such as tumours or cysts can cause ectopic tooth eruption in the maxillary sinus. In certain situations, a tooth may become ectopic if associated with a follicular cyst that grows toward the maxillary sinus and perforates its membrane.

Maxillary sinusitis, characterized by symptoms such as nasal congestion and sinus pressure, can be caused by tooth displacement. Treatment decisions depend on the severity of symptoms and the presence of infection or inflammation. Displacement of a tooth into the maxillary sinus without causing inflammation may justify its retention, while inflammation may necessitate its removal.

An accurate diagnosis depends on advanced radiologic tools such as Computed Tomography (CT) or Cone-beam CT (CBCT) to precisely locate the displaced tooth and assess sinus pathology. Retrieval of a displaced tooth typically requires surgical intervention, such as the Caldwell-Luc technique, exploration by transalveolar or endoscopic approaches. Timely and appropriate management, including close monitoring and skilled surgical intervention, is crucial for positive outcomes. This emphasizes the importance of precise tooth extractions and the need for expert surgical skills when addressing tooth displacement into the maxillary sinus.

**Keywords:** tooth extraction, maxillary sinus, displaced teeth, complication, trauma, ectopic tooth, follicular cyst, sinusitis, Caldwell-Luc, endoscopic approaches

## ZUB U MAKSILARNOM SINUSU

### Sažetak

Slučajno je pomicanje zuba u maksilarni sinus tijekom vađenja rijetko, ali može imati ozbiljne posljedice. Zbog blizine sinusu to se uglavnom događa tijekom vađenja maksilarnih molara. Erupcija ektopičnog zuba u maksilarnom sinusu može biti uzrokovana razvojnim poremećajima, iatrogenim događajima, traumom ili patološkim procesima poput tumora ili cista. U određenim situacijama zub može postati ektopičan ako je povezan s folikularnom cistom koja raste prema maksilarnom sinusnom i perforira njegovu membranu.

Maksilarni sinusitis, koji karakteriziraju simptomi poput nazalne zčepljenosti i pritiska u sinusu, može biti uzrokovan potisnutim zubom. Odluke o liječenju ovise o težini simptoma i prisutnosti infekcije ili upale. Minimalne perforacije bez upale mogu opravdavdati zadržavanje zuba, dok značajne perforacije ili upale mogu zahtijevati vađenje.

Točna dijagnoza ovisi o naprednim radiološkim metodama poput kompjutorske tomografije (CT) ili konusne snimke (CBCT) kako bi se precizno locirao potisnuti zub i procijenila patologija sinusa. Povlačenje potisnutog zuba obično zahtijeva kirurške intervencije, poput Caldwell-Luc tehnike, eksploracije transalveolarnim ili endoskopskim pristupom. Pravovremeno i prikladno upravljanje, uključujući blisko praćenje i vješte kirurške intervencije, ključne su za pozitivne rezultate. To ističe važnost preciznog vađenja zuba i potrebu za stručnim kirurškim vještinama prilikom rješavanja potisnutog zuba u maksilarnom sinusu.

**Ključne riječi:** vađenje zuba, maksilarni sinus, potisnuti zubi, komplikacija, trauma, ektopični zub, folikularna cista, sinusitis, Caldwell-Luc tehnika, endoskopski pristupi

# Table of Contents

<b>1. INTRODUCTION.....</b>	<b>1</b>
<b>2. THE MAXILLARY SINUS AND TEETH.....</b>	<b>3</b>
<b>2.1 The maxillary sinus.....</b>	<b>4</b>
2.1.1 The Anatomy of the maxillary sinus.....	5
2.1.2 Diagnostic imaging of the maxillary sinus.....	6
<b>2.2 The anatomical relationship between the maxillary sinus and teeth.....</b>	<b>7</b>
<b>2.3 Displacement of a tooth into the maxillary sinus.....</b>	<b>8</b>
2.3.1 Iatrogenic displacement of a tooth into the maxillary sinus.....	8
2.3.2 Trauma-induced displacement of a tooth into the maxillary sinus.....	11
2.3.3 Ectopic tooth in the maxillary sinus.....	12
<b>2.4 Complications caused by a tooth in the maxillary sinus.....</b>	<b>16</b>
2.4.1 Odontogenic sinusitis.....	16
2.4.2 Oroantral fistula.....	20
2.4.3 Orbital cellulitis.....	23
<b>2.5 Retrieval of displaced tooth.....</b>	<b>25</b>
2.5.1 The Caldwell-Luc procedure.....	25
2.5.2 Endoscopic approach.....	28
<b>3. DISCUSSION.....</b>	<b>30</b>
<b>4. CONCLUSION.....</b>	<b>33</b>
<b>5. REFERENCES.....</b>	<b>35</b>
<b>6. CURRICULUM VITAE.....</b>	<b>40</b>

**List of Abbreviations:**

CT – Computed tomography

CBCT – Cone-beam CT

MRI – Magnetic resonance imaging







## **1. INTRODUCTION**

Knowledge of the paranasal sinuses dates back to the 16th century when Leonardo da Vinci made drawings referencing them. During this time, a physician named Berengar del Carpi became the first to mention the sinuses, while the anatomist Vesalius believed that these sinuses contained only air and nothing else (1).

In the 19th century, anatomists Adolf Onodi and Zuckerkandl laid the foundation for the modern understanding of the maxillary sinus. Their findings were later confirmed in the 20th century by the radiologist Zinreich using computerized tomography (CT) (1).

There are four air-filled paranasal sinuses in the maxillary region and skull: the maxillary, ethmoid, frontal, and sphenoid (2). The paranasal sinuses have multiple functions. They enhance voice resonance, humidify, heat, and filter inhaled air, increase the surface area of the mucosa, absorb shock directed to the head, secrete mucus that keeps the nasal cavity moist, participate in facial growth, lighten the skull bones to maintain balance, insulate sensitive structures such as the teeth and eyes from temperature changes in the nasal cavity, play a role in the immune response, and serve as auxiliary olfactory organs (1).

The largest of these sinuses is the maxillary sinus. Nathaniel Highmore extensively researched this complex structure in the 17th century, leading to it being referred to as the antrum of Highmore (1,2).

The maxillary sinus is closely related to the roots of the posterior maxillary teeth, explaining why many clinical conditions of the maxillary sinus originate from odontogenic sources (2).

The purpose of this work is to emphasize the etiology, diagnosis, and treatment options for the presence of a tooth in the maxillary sinus.



## **2. THE MAXILLARY SINUS AND TEETH**

## 2.1 The maxillary sinus

The formation of the paranasal sinuses results from the invagination of the nasal fossa into the frontal, maxillary, ethmoidal, or sphenoid bones (1). Among the four paranasal sinuses, the maxillary sinus is the first to develop, beginning as early as the 10th week of intrauterine life (1,4).

The development of the maxillary sinus is a process that involves the invagination of the mucosa towards the surrounding mesenchyme in the lower anterior region of the ethmoid infundibulum by the 11th week, forming the earliest recognizable structure of the maxillary sinus. Initially, this primordial maxillary sinus is oval-shaped with smooth walls (4).

The ossification of the maxillary sinus begins in the 16th week. It starts from the lateral walls of the maxillary sinus and progresses to the anterior and posterior walls by the 20th and 21st weeks, respectively. The ossification of the medial wall is expected to begin by the 37th week (4).

At birth, the maxillary sinus is small, with an anteroposterior diameter of less than 7.0 mm, a height of less than 4.0 mm, and a width of less than 2.7 mm (4). Due to its small size, the sinus is barely visible on routine radiographic examinations of newborns (1). At this stage, it is mainly filled with fluid, which appears as an opacity in the early stages of life and is considered normal (1).

The maxillary sinus experiences significant growth between the ages of one and eight years. This growth is driven by the pressure from the eyeball and surrounding muscles, pulling the sinus downward from the third year, as well as the eruption of permanent teeth. During life, the roof of the maxillary sinus, which initially adopts an inferolateral position in childhood, becomes more horizontal over time (4). By the age of 12, the sinus primarily grows laterally towards the zygomatic bone, forming the zygomatic recess. Additionally, alveolar maxillary pneumatization directs growth inferiorly towards the hard palate, extending 4-5 mm below the nasal floor level (1).

Primary dentition has minimal impact on the growth and development of the maxillary sinus due to the presence of a thick bony layer separating them. However, the permanent dentition, which is in closer proximity to the sinus, significantly influences its growth and development. Consequently, the maxillary sinus reaches its maximum size between the ages of 18 and 21, coinciding with the eruption of the last molar, the wisdom tooth. In adults, the average dimensions of the maxillary sinus are approximately 27.96 mm in length, 19.57 mm in width, and 25.33 mm in height (4). Over time, the shape and size of the sinus can change due to tooth loss and mineral deficiencies in the surrounding bone matrix, resulting in a decrease in size (1).

### 2.1.1 The Anatomy of the maxillary sinus

Anatomically, the maxillary sinus, which is pyramid-shaped, is the largest paranasal cavity. Its anterior wall is formed by the facial surface of the maxilla, accommodating structures such as the canine fossa, infraorbital groove, and infraorbital foramen. The canalis sinuosus, visible on the internal aspect of the anterior wall, conveys the anterior superior alveolar nerve and vessels. The pterygopalatine fossa is enclosed by the posterior wall of the maxillary sinus, which is formed by the infratemporal part of the maxilla. The superior wall, or the orbit floor, is a sensitive triangular area that also contains the infraorbital groove. As the sinus approaches the marginal edge of the orbit, its thickness increases, measuring 0.4-0.5 mm in the region of the infraorbital canal (4).

The medial wall of the maxillary sinus, rectangular in shape, separates the sinus from the nasal cavity at the area of the inferior nasal concha. This smooth plate of the medial wall thins where parts of the palate, ethmoid bone, and lacrimal bone meet, forming the maxillary sinus ostium, also known as the hiatus. In adults, this ostium is located between the middle and posterior thirds of the ethmoidal infundibulum and opens into the middle nasal meatus. The lateral part of the maxillary sinus extends to the zygomatic bone. The floor of the maxillary sinus, formed by the palatal and alveolar processes, lies below the nasal cavity, extending from the mesial side of the first premolar to the distal side of the third molar (4). The sinus's lowest point is located above the second premolar and first molar, below the level of the nasal floor (5).

Like all paranasal sinuses, the maxillary sinus is lined with mucosa composed of pseudostratified columnar epithelium. This mucosa produces mucus, which is transported by cilia to the specific sinus opening (1, 4). The epithelial layer in the sinuses is thinner than that in the nasal cavity. Fluids from the sinuses drain into the nasal cavity through the ostiomeatal unit. Any blockage in this drainage process increases the risk of mucosal thickening, inflammation, polyp formation, and cysts (1).

The vascular supply to the maxillary sinus includes the posterior superior alveolar artery, which runs along the medial wall of the sinus, the infraorbital artery, which exits through the infraorbital foramen to the anterior maxilla, and the posterior lateral nasal artery. These arteries anastomose at the anterolateral wall of the sinus to supply the mucous membrane of the nasal cavity. Innervation of the maxillary sinus is provided by branches of the maxillary nerve, specifically the infraorbital and anterior, middle, and posterior superior alveolar branches, which offer sensory innervation. The anterior ethmoidal branch of the ophthalmic nerve innervates the infundibulum, while the middle superior alveolar branch contributes to the mucosal innervation (4).

### 2.1.2 Diagnostic imaging of the maxillary sinus

In addition to CT as the gold standard for exploring paranasal sinuses, advanced imaging techniques such as magnetic resonance imaging (MRI), dental CT scan, and cone beam CT (CBCT) are utilized to evaluate sinus volume and structure (3,6). CBCT enables the clinician to locate the position of the tooth in three dimensions accurately, thus evaluating possible perforations of the tooth roots into the sinus (6,7). Ultrasound provides insights into the mucosal layer and fluid content within the sinus (3).

Panoramic radiography is valuable for determining the relationship between tooth roots and the sinus floor, as well as diagnosing potential periapical lesions, cysts, and other radiopaque foreign bodies in the maxillary sinus, which may result in local swellings (3). Other radiological tools used to determine the position of foreign bodies in the paranasal sinuses include Waters' projection and Lateral skull radiographs (6).

## 2.2 The anatomical relationship between the maxillary sinus and teeth

In the molar region, the sinus floor is in closer anatomical relation than in the premolar region, separated by a thin compact bony boundary. Radiological studies show that the average distance between the roots of the molars and premolars and the maxillary sinus is 1.97 mm (4).

The bony septum that extends across the floor of the maxillary sinus is sometimes perforated by the roots of certain posterior maxillary teeth. However, due to individual variations in the size of the maxillary sinus, it is difficult to precisely identify which teeth are in direct relation to the sinus. It is generally considered that the floor of the maxillary sinus can be elevated or perforated by the roots of the canines, first, second, and third molars (1).

The buccodistal root of the second molar is usually closest to the sinus, while the distance between the sinus floor and the apex of the palatal root of the first premolar is the greatest (4).

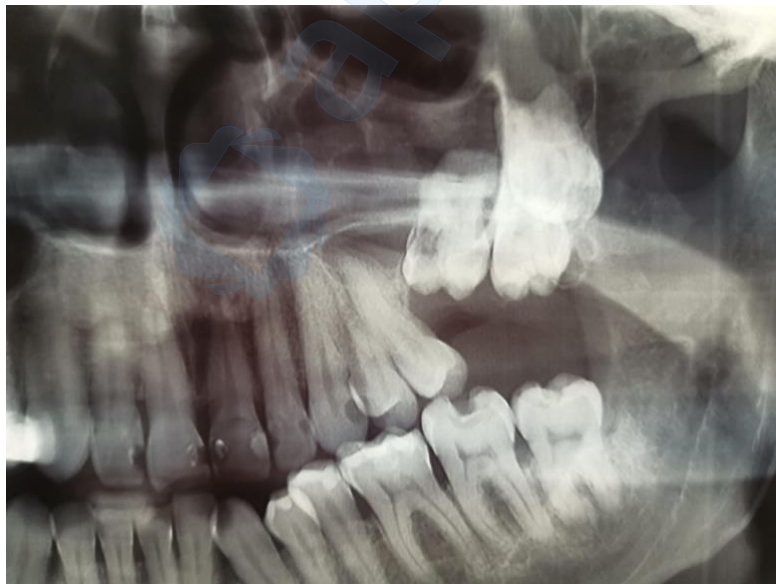

Figure 1. Close anatomical relationship between the maxillary sinus and teeth.

Courtesy of : Assist. Prof. Josip Biočić

## 2.3 Displacement of a tooth into the maxillary sinus

### 2.3.1 Iatrogenic displacement of a tooth into the maxillary sinus

During the extraction maneuver, the displacement of a tooth into adjacent spaces is a rare but significant occurrence. The maxillary sinus is the most commonly affected area by this complication, often requiring surgical intervention to rectify the situation (8). These cases can be asymptomatic or symptomatic, with patients presenting with sinus tension and complications such as sinusitis, swelling, trismus, and psychological distress, which often lead to medicolegal issues (9,10).

The most common cause of teeth being displaced into the maxillary sinus is accidental displacement during extraction, followed by trauma. This complication is more frequently observed in men. The maxillary first molar and third molar are the most commonly dislocated teeth into the maxillary sinus, with a prevalence of 0.6-3.8% (8). It is considered the most common complication during the extraction of an impacted upper wisdom tooth (10). Failing to consider the proximity of anatomical structures and using excessive, uncontrolled force with an elevator increases the risk of perforating and displacing the tooth into the maxillary sinus (8, 9). This is often attributed to the clinician's inexperience and inadequate radiological assessment, leading to an inappropriate surgical plan and approach (8,10).

To achieve optimal outcomes, it is essential to understand the tooth's morphology, the number and shape of its roots, the angle of their inclination, and the depth of their position, particularly for impacted teeth. The likelihood of this undesired outcome is increased with teeth having single or fused roots and proximity to the maxillary sinus. A radiological evaluation of the maxillary sinus structure is essential to identify potential pathological lesions and assess pneumatization (8).

Suppose a tooth is iatrogenically pushed into the maxillary sinus. In that case, it may be lodged between the buccal mucosa and the outer cortical plate, between the sinus floor and its mucosa, or completely perforate the sinus membrane. When this occurs, oroantral communication and a missing tooth in the dental arch confirm the incident clinically. Still, radiological analysis is necessary to pinpoint the exact location of the displaced tooth in the sinus (8).



Panoramic radiography is often sufficient for radiological confirmation, but CT provides a better surgical plan and approach and assesses the sinus condition (8).

Acute inflammation of the maxillary sinus mucosa is the most common complication due to oroantral communication or general irritation of the maxillary sinus. This results from compromised integrity and harmony caused by the displaced tooth (8).

The typical symptoms of sinusitis include congestion, postnasal discharge, and facial pain (11). Oroantral communication allows the maxillary sinus to be infected through the oral cavity or ostium, leading to the thickening of the Schneiderian membrane and compromising ciliary function through physical and chemical irritation of the mucosa, causing inflammation (6, 12). Other complications include oroantral fistula, epistaxis, and epiphora (13).

Sinusitis is treated using endoscopic or Caldwell-Luc methods. The displaced dental fragment or tooth is removed from the sinus, then the pathological mucosa is treated (8). This surgical procedure should not be delayed, as sinusitis can spread to other paranasal sinuses (8). Due to their proximity to the orbit, sinusitis and pansinusitis can spread and cause orbital cellulitis, leading to changes in the orbit and soft tissue of the eye, which may result in an orbital abscess and severe orofacial pain in the supraorbital area (6, 14).

Although some believe that asymptomatic cases of a smaller dental fragment displaced into the maxillary sinus do not need to be treated, many agree that even these should be removed to prevent possible pathological complications (8).

There is a debate about whether to immediately remove a tooth from the maxillary sinus trans alveolarly in the first attempt, thus preventing sinus infection if left untreated. If the tooth is not visible and cannot be grasped with an instrument, it should not be attempted to be removed from the sinus (10). Persistent attempts to remove the tooth can further push it into the maxillary sinus and increase oroantral communication, causing unnecessary tissue damage and morbidity (8,10). A case was recorded where a dentist caused significant damage trying to extract a tooth from the maxillary sinus for six hours (10).

In such situations, it is recommended to inform the patient about the issue, provide antibiotics, analgesics, and decongestants, and refer them to an oral and maxillofacial surgeon as soon as possible (10). This will allow for the surgical removal of the tooth and help prevent undesirable consequences (10).

While many authors believe that surgical removal of the tooth from the maxillary sinus should be done as soon as possible, as the chances of complications such as pain, swelling, and trismus increase after 24 hours, many agree that it is better to wait for fibrosis to set in, which will reduce the mobility of the tooth in the maxillary sinus and facilitate the surgical procedure (10). Therefore, the authors recommended to wait 4 to 6 weeks and then approach the stabilized tooth in the maxillary sinus (15).

Once the surgical procedure to remove the tooth from the maxillary sinus is initiated, it is crucial first to perform adequate radiological imaging, preferably using CBCT, to locate the tooth precisely and develop a surgical plan using one of the surgical methods for extracting the tooth from the maxillary sinus (10).

The transalveolar approach is used when the tooth or dental fragment is smaller than the existing opening in the alveolar ridge through which it can be extracted (15). Suppose it is impossible to remove the tooth this way; surgical methods, such as Caldwell Luc or the endoscopic approach, should be used after a well-developed surgical plan and radiological evaluation (10).

The surgical procedure is followed by postoperative instructions, which recommend rest, proper oral hygiene, soft food, and cold compresses. Suppose the patient notices a high temperature, swelling, difficulties lasting longer than three days, constant pain, excessive bleeding, or an inability to open the mouth. In that case, they should contact their doctor due to possible unsuccessful surgery (15).

### 2.3.2 Trauma-induced displacement of a tooth into the maxillary sinus

Traumatic injuries in the maxillofacial region affect 1 to 3% of the population. In any case of trauma, the patient's condition should first be assessed by checking the airway, breathing, and circulation. Once the vital signs are stable, a detailed clinical examination is performed to check for possible fractures of the maxilla and mandible (16).

After assessing the condition of the perioral and intraoral soft tissues, hard tissues are checked, too. Any missing tooth not visible during a clinical examination should be considered aspirated or displaced into the nasal cavity, maxillary sinus, or other neighboring tissues until proven otherwise through radiological analysis of the head, neck, chest, and abdomen (16).

Cases of tooth intrusion and displacement into the maxillary sinus due to maxillofacial trauma have been reported (17). Intrusion of the tooth presents the least favorable prognosis, with a 100% chance of necrosis in teeth with closed apices (18). Displacement of a tooth into the maxillary sinus can lead to chronic sinusitis, nasal sinus fistula, pain, and potential disturbances in the development of permanent dentition if primary teeth are involved in intrusion (17,18). Therefore, clinicians recognize the importance of early retrieval of the displaced tooth (17).

An intrusive luxation often occurs when a tooth is forcefully impacted in the apical direction, causing it to move within the alveolar bone. This can lead to a fracture of the alveolar bone, making tooth reimplantation difficult. It is recommended to have the tooth removed promptly to prevent infection (17).

The primary pathway for tooth displacement is mainly parallel to the long axis. Due to the increased exposure of the anterior alveolar area, tooth dislocation is more common in the front rather than the posterior region. Posterior teeth are less likely to be affected due to their position and multiple roots unless a significant impact force is present (17,18).

However, in cases of injury, completely intrusive teeth can involve the maxillary sinus because the maxillary sinus is the largest of the paranasal sinuses and makes up a significant part of the maxilla. It is also located in the most prominent part of the face, where its inferior wall is relatively thin, approximately 1 to 7 mm. However, despite these factors, cases of traumatic teeth being displaced into the maxillary sinus are still rare (17).

Despite the advancement and widespread use of medical imaging technology, CT still presents a golden standard for diagnosing maxillofacial trauma, significantly reducing the possibility of misdiagnosis (18).

Tooth displacement into the maxillary sinus can be addressed using two main methods: the trans-alveolar pathway and the Caldwell-Luc operation. Many clinicians recommend using an endoscope for surgical retrieval. It is advised to wait at least one month before surgically removing a displaced tooth from the soft tissue for fibrosis to set in place, which will limit the movement of the displaced tooth within the maxillary sinus. There have been documented cases where the molars were entirely covered in a blood clot just several days after the injury. This helped secure them in the maxillary sinus, facilitating the procedure (17).

### 2.3.3 Ectopic tooth in the maxillary sinus

A series of complex interactions between the oral epithelium and mesenchymal tissue result in tooth formation. The formation of dental lamina begins in the 6th week of embryonic development, marking the start of the growth and development of primary teeth. Subsequently, between the 5th and 10th month after birth, proliferation of the ectodermal layer occurs, which will determine the permanent dentition. Any atypical interaction between these tissues can result in the formation of ectopic teeth in non-dental areas such as the nasal septum, mandibular condyle, coronoid process, palate, and very rarely in the maxillary sinus (19).

Ectopic teeth are teeth found outside the alveolar ridge, with wisdom teeth being the most common (20). The etiology of ectopic teeth is not yet fully understood but is believed to be the result of developmental disorders, iatrogenic events, trauma, or pathological processes such as tumors or cysts (21).

Ectopic teeth in the maxillary sinus can cause sinusitis or ophthalmic problems. On the other hand, they may also be asymptomatic for many years and are often incidentally detected during radiological examinations (19).

The presence of teeth in the maxillary sinus may not cause any symptoms until an infection occurs (20). This can lead to recurrent or chronic sinusitis followed by classic symptoms of sinus pathology, such as facial pain, swelling, headache and nasolacrimal obstruction, and sometimes they could be accompanied by large cysts causing ophthalmological and nasal problems that have been observed. There have been cases where an ectopic tooth in the maxillary sinus caused nasolacrimal duct obstruction as well as epiphora due to the exerted pressure of the impacted molar of the maxillary sinus on the nasolacrimal duct (21).

Although rare, a tooth may be found in the maxillary sinus as a result of the growth of a follicular cyst, which expands with the causative tooth into surrounding structures like the maxillary sinus (19, 20). The incidence of impacted teeth being affected by follicular cysts is 1.44% (22).

Follicular cysts are the most common odontogenic developmental cysts, arising from a disturbance in odontogenesis. The stage of tooth growth and development at which this disturbance occurs determines the type of cyst. This second most common odontogenic cyst typically forms when the crown of the tooth is complete, but the tooth has not yet erupted from the bone (23). It is a typical odontogenic cyst, composed of non-keratinized stratified squamous epithelium with an external fibrous tissue layer (20,23). It is filled with a fluid or pasty substance, with the cystic lining originating from the reduced enamel epithelium at the enamel-cement junction of the tooth, separating the tooth follicle from the crown (23).

Follicular cysts are found in 70% of cases in the mandible and 30% in the maxilla, often affecting distal regions (20). Their etiology is closely linked to impacted or unerupted wisdom teeth, which are the most common, followed by canines and second molars (19, 20).

When a maxillary tooth that has not erupted is affected by a follicular cyst, it can grow several centimeters, leading to the resorption of surrounding bone and the displacement of the affected tooth into adjacent anatomical spaces, such as the maxillary sinus (19).

As they grow, they can partially or completely occupy the space of the maxillary sinus (20). These cysts can grow asymptotically for several years and are often discovered incidentally during radiological examinations (21).

When the maxillary sinus is affected by a cyst and ectopic tooth, symptoms typically appear later, ranging from obstruction of sinus drainage to potential vision impairment (21).

Follicular cysts usually grow slowly and without any symptoms, until a potential bacterial infection occurs. This can lead to pain, swelling, and the formation of pus. Without proper radiological analysis, there is a risk of misdiagnosis with the cysts being mistaken for an abscess. Differentiating between an infected cyst and an intraoral abscess remains a significant challenge for dentists without specialized training in oral or maxillofacial surgery (24).

Further spread of the cyst into the pterygomaxillary fossa, nasal cavity, ethmoidal sinus, or orbit can lead to serious functional, morphological, neural, and infectious complications. Therefore, it is important to diagnose follicular cysts in the maxilla early, as pathological proliferation and cystic degeneration of the follicular tissue, when it reaches a larger size, can cause severe problems (25).

Radiologically, a cyst appears as an unilocular radiolucency with a well-defined crown of the causative tooth (20). A smaller cyst may be misdiagnosed as a normal follicle (20). If the distance between the crown and the dental follicle is 2.5-3mm, it indicates a follicular cyst (26).

Given their similarity in radiological analysis, the differential diagnosis should exclude radicular cysts, keratocystic, adenomatoid odontogenic tumors, unilocular ameloblastomas, and keratocytes (24).

Once the diagnosis of an ectopic tooth in the maxillary sinus and its associated cyst is confirmed, the cystic formation is enucleated, and the causative tooth is extracted using the Caldwell-Luc procedure or transnasal endoscopic method (20). The transnasal method is possible when the tooth is small and close to the maxillary ostium (21).

The endoscopic approach avoids incision of the outer mucosa, prevents the formation of an oroantral fistula, and reduces the risk of sinusitis. It is a minimally invasive method with a generally favorable prognosis (22).

For large cysts, marsupialization can be performed to reduce the bone defect and encourage the eruption of the ectopic tooth. There is a recorded case where marsupialization resulted in the eruption of an ectopic second premolar associated with a follicular cyst (21).

However, it is important to note the negative aspects of this technique regarding recurrence and reappearance, which, given the nature of follicular cysts, is not an optimal option (21). Marsupialization is useful when it is desirable to preserve the causative tooth, especially in younger patients (24). Besides Caldwell-Luc and endoscopic methods, there is also a new approach to treatment in the form of piezoelectric surgery (26).

Regular annual check-ups are essential due to the 12-14% recurrence rate of follicular cysts and the possibility of transformation into tumors such as ameloblastoma or epidermoid carcinoma. Mucoepidermoid carcinoma, which has also been recorded, poses a risk as well (20).

Therefore, surgical extraction of the ectopic tooth and complete removal of the associated cyst are necessary in cases of maxillary sinus involvement to prevent this (19).

## **2.4 Complications caused by a tooth in the maxillary sinus**

When the integrity of the maxillary sinus is compromised due to iatrogenic, traumatic, or cystic displacement of a tooth through its membrane, a wide range of symptoms can arise. These symptoms can range from obstruction of the maxillary sinus to serious ophthalmic issues (21).

### **2.4.1 Odontogenic sinusitis**

The sinuses are typically sterile compared to the nose, which contains bacteria. This is likely due to the presence of nitric oxide and constant mucociliary clearance (27). However, if inflammation of the nasal sinus mucosa occurs, it can lead to sinusitis, which is characterized by two or more symptoms, such as nasal blockage, runny nose, facial pain or pressure, and partial or complete loss of smell (28). Acute sinusitis can be triggered by factors such as trauma, diving in polluted water, a secondary effect of the common cold, or a dental infection (27).

Odontogenic sinusitis is a bacterial infection that affects the maxillary sinus, causing inflammation that can spread to the surrounding structures (29). As a result, the maxillary sinus is closely related to the fields of maxillofacial surgery, dental medicine, and otorhinolaryngology, often requiring a multidisciplinary approach to treatment (28).

The literature indicates that 10-41% of all cases of sinusitis are related to dental issues (30). These cases also account for 45-75% of unilateral opacities in the maxillary sinus (29). This type of sinusitis is more common in people in their 50s, affecting both men and women equally, and it typically presents as a chronic inflammation caused by anaerobic bacteria (28, 29). The acute form, characterized by a mix of anaerobic and aerobic organisms, can spread to the orbital and intracranial regions (28, 29). Sinusitis is considered acute if it lasts for less than 12 weeks, while it is classified as chronic if it persists for more than 12 weeks without relief from symptoms (28).

Apical periodontitis, oroantral communication, and iatrogenic procedures associated with foreign bodies in the maxillary sinus, resulting in perforation of Schneider's membrane, are common causes of odontogenic sinusitis (28,29).



In addition to the typical symptoms of sinusitis, odontogenic sinusitis may be suspected if there is unilateral opacification of the maxillary sinus and maxillary dental issues, unilateral pus in the middle meatus, polyps and edema seen during endoscopy, foul odor, and evidence of odontogenic bacteria on an antibiogram (28,29).

Odontogenic maxillary sinusitis is characterized by the origin in the teeth and the maxillary sinus. Throughout life, these two anatomical structures change, and their relationship with each other is dynamic. Between the ages of 12 and 14, the maxillary sinus reaches a volume of 15-20 mL (28). Throughout life, its shape changes in relation to tooth loss and pneumatization. This can lead to the sinus cavity expanding, creating a thin layer of alveolar bone between the oral cavity and the sinus (1,28).

Research indicates that the first molar is most often responsible for odontogenic sinusitis (35.6%), followed by the second molar (17.4%) and the second premolar (15.4%). These teeth also the first to lead to perforation in the maxillary sinus: first molar (55%), second molar (34%), and second premolar (8%) (28).

Although the mesiobuccal root of the second molar is closest to the floor of the maxillary sinus, the palatal root of the first molar is most often associated with the perforation of the maxillary sinus (28).

Iatrogenic perforation of the maxillary sinus can occur during dental extractions (29.6% of cases), endodontic procedures, dental implant surgery, orthognathic maxillary surgery, pre-prosthetic surgery, and sinus lift and graft operations. This can lead to a bacterial infection. It is believed that the number of risky dental surgeries has increased in recent years, leading to more cases of iatrogenic odontogenic sinusitis (28).

The diagnosis of odontogenic maxillary sinusitis begins with careful history taking, followed by clinical and radiological examination (28).

During a clinical examination of the cheeks and buccal vestibule, they may appear swollen and inflamed. Patients may experience pain when palpating the anterior wall of the maxillary sinus. Subsequently, a dental examination focuses on identifying the tooth that could be the root cause. The dentist assesses for any dental issues and their relation to surrounding anatomical structures while also searching for potential oroantral fistulas that may lead to odontogenic sinusitis (28).

Due to damage to Schneider's membrane, the initial symptom is usually nasal obstruction, which is typically accompanied by purulent rhinorrhea, pus on the back wall of the throat, odontogenic and facial pain, fatigue, halitosis, and hyposmia. It can present as symptomatic sinusitis, but it may also be asymptomatic in some individuals (28).

On radiological examination, if the mucous membrane of the maxillary sinus is thicker than 3 mm, it indicates a pathological condition. If it is 2 mm thick and accompanied by symptoms, it also represents a pathological situation (26). Periapical and panoramic radiography can be used for diagnosing odontogenic sinusitis, but CBCT and CT are the most accurate methods (28).

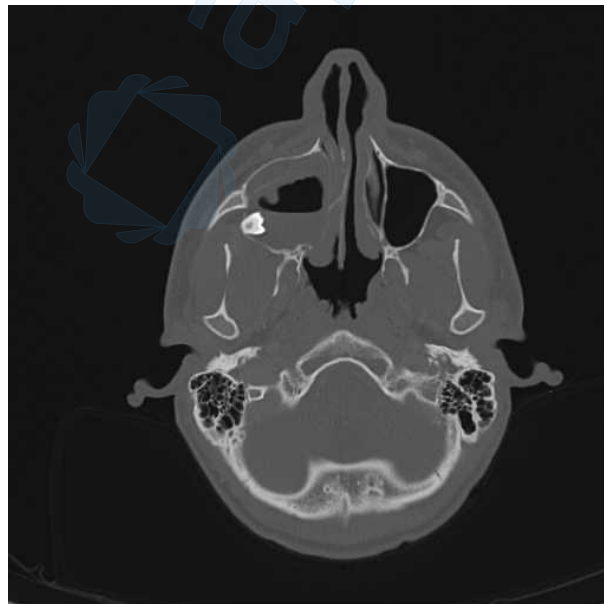


Figure 2. Inflammation of the maxillary sinus associated with a displaced tooth (CT).

Courtesy of : Assist. Prof. Josip Biočić

It is crucial to diagnose odontogenic sinusitis to prevent potential serious complications accurately. Studies indicate that 20% of cases are incorrectly diagnosed with odontogenic sinusitis, and 33% do not respond to initial therapy. Additionally, antibiotic therapy is ineffective in 79% of cases. For this reason, conservative antibiotic treatment is often insufficient and may necessitate surgical sinus therapy (28).

The most commonly prescribed antibiotic therapy is ampicillin combined with a  $\beta$ -lactamase inhibitor. While some clinicians recommend a 21-28 day course of antibiotics, it is now considered sufficient to use it for at least 7 to 14 days after the symptoms disappear (28).

When addressing dental problems, the focus is on eliminating the cause of the symptoms, which depends on the dental procedure that initially resulted in sinusitis.

Accidental displacement of a tooth fragment or the entire tooth into the maxillary sinus during extraction can lead to sinusitis, and the decision to extract them depends on the severity of the clinical situation (28).

If a dental fragment without signs of infection or inflammation is accidentally pushed into the sinus, and there is no visible perforation of the sinus lining or if it is less than 3 mm, the tooth or tooth fragment can be left in place. Regular check-ups are necessary, and antibiotics may be prescribed initially along with decongestants until the defect is anatomically repaired. Extraction of the tooth is necessary if the perforation is larger than 3 mm or if there are symptoms of inflammation due to infection (28).

#### 2.4.2 Oroantral fistula

During posterior maxillary tooth extraction or enucleation of maxillary cysts, iatrogenic formation of oroantral communication and its chronic form, oroantral fistula, which represents an abnormal pathological osteomucosal union of the oral cavity and sinuses, may occur (28). Oroantral fistula is the most common cause of odontogenic sinusitis (30).

It differs from an oroantral communication in its epithelium, which is composed of squamous epithelium of the oral mucosa and pseudostratified ciliary epithelium arising from the sinus mucosa (28).

Factors that can increase the risk of oroantral fistula formation include the epithelialization of the osteomucosal junction between the maxillary sinus and the oral cavity, cysts, foreign bodies, and tumors (28).

The oral cavity assessment includes evaluating the size and duration of the fistula and any accompanying signs of inflammation in the maxillary sinus. This evaluation is used to determine the appropriate course of therapy based on both subjective complaints and objective findings (31).

Regarding subjective findings, patients with oroantral fistula may experience unpleasant symptoms such as halitosis, maxillary tooth pain, postnasal discharge, as well as reduced sense of smell and vision (31).

Most of the oroantral communications with a smaller diameter between 1-2 mm without epithelialization close spontaneously, if there are no signs of sinus inflammation present or it has been successfully repaired (28,31). Suturing the surrounding gingiva may be sufficient for those between 3-5 mm to successfully close the communication (31).

If the communication is larger than 5 mm, a surgical procedure involving a suitable flap is necessary (28, 31). If the communication persists for longer than 3 weeks, a surgical procedure is needed, even if it is smaller than 5 mm (28). If possible, it is recommended to close the oroantral communication within 48 hours to prevent further complications (31).

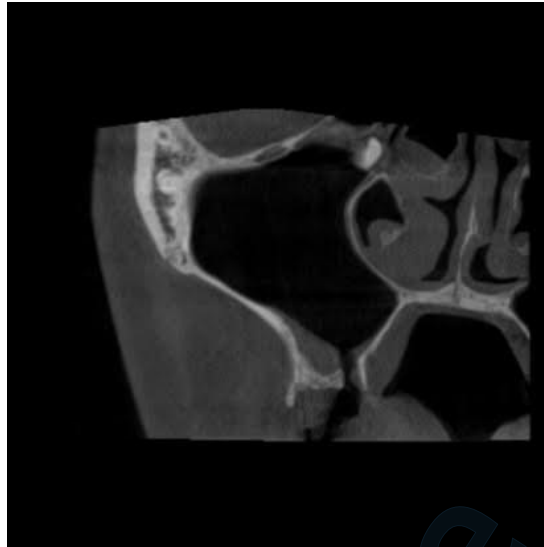


Figure 3. Oroantral communication associated with a displaced tooth in the maxillary sinus (CT scan). Courtesy of : Assist. Prof. Josip Biočić

If there are signs of a sinus infection, the first step is to control the sinus inflammation before proceeding with surgery. The therapeutic protocol is designed this way because the oroantral fistula serves as a natural drainage between the sinuses and the oral cavity. As a result, inflammation can go unnoticed by the patient. Closing the fistula can then exacerbate the inflammation (31).

Recent studies recommend prescribing amoxicillin/clavulanate 1g/125mg three times per day for 10-14 days to reduce acute inflammation. This is in addition to saline irrigation, nasal decongestants, and nonsteroidal anti-inflammatory drugs, which have been proven to be effective (31).

In cases of severe chronic sinusitis infection, either endoscopic sinus surgery or Caldwell-Luc procedures may be necessary. When there are no more signs of sinusitis, a simple suture technique or one of the possible flaps is used to close the oroantral communication, depending on its size (31).

The flap technique can be classified as local or distant flaps. Commonly used flaps include the buccal flap, buccal fat pad, palatal rotating flap, and distant flap procedures involving the tongue. The oldest flap is the mucoperiosteal buccal flap of a trapezoidal shape, which is raised and used to cover the defect. Although it provides sufficient blood flow, it creates a problem for those wearing dentures, as it leaves a shallow sulcus. This issue can be avoided by using a buccal sliding flap designed by Moczair. With this method, the fistula is closed by shifting the flap distally for the distance of one tooth. While this prevents the reduction of the buccal sulcus, it can lead to periodontal problems in the form of recession due to large dentogingival detachment (31).

Using a buccal fat pad as a graft is also an option in treating oroantral fistula. When placed in a defect, the exposed buccal fat pad epithelizes within 4-6 weeks due to the rich vascular supply of that area. However, this technique is not used for large fistulas because it can lead to necrosis of the graft and the consequent formation of new fistulas. In patients who have undergone radiation therapy, the buccal fat pad may be less mobile, making the procedure challenging (31).

Oroantral fistulas persisting for a long time and larger than 10 mm are typically treated with rotational palatal flaps. This procedure involves cutting out the fistula in a circular shape because it is typically larger internally than it appears externally. Then, a flap from the palate is lifted, including the greater palatine artery, to ensure it is thick and strong. The flap is rotated and passed through the tunnel connecting it to the fistula.

The flap is rotated and pulled through the oroantral fistula and then sutured. The palatal donor site is expected to heal within 2 weeks. In this method, the buccal vestibule is not reduced as with the buccal flap. Its advantages include the strong durability of the flap and the rich blood supply. The thickness of the flap makes it difficult to rotate, so it is recommended to include subepithelial connective tissue in the rotation to reduce tension and facilitate the surgical procedure (31).

Although each flap is demanding to perform and can lead to complications, its correct and precise execution is necessary for the procedure to be successful (31).

### 2.4.3 Orbital cellulitis

Orbital cellulitis is the inflammation of the tissue surrounding the eye. In 84% of cases, it occurs due to an infection spreading from the sinuses (32). This high percentage can be attributed to the orbit being closely connected anatomically and vascularly to the paranasal sinuses (33). The most common causes of the disease are bacteria such as *Staphylococcus Aureus* and alpha-hemolytic *Streptococcus*. Other causes of orbital cellulitis include trauma, a foreign body in the orbit, dacryocystitis, and endophthalmitis (32).

In 2-5% of cases, orbital cellulitis can be of odontogenic origin, when Schneider's membrane integrity is compromised by infection progression or iatrogenic perforation. Thus, cases of orbital cellulitis have been reported as a possible complication following extractions (32).

Extraction of the maxillary lateral teeth can release microorganisms into the maxillary sinus directly or from the oral cavity through an oroantral fistula (33). The disruption of the normal anatomy and physiology of the maxillary sinus can compromise mucociliary clearance, mucosal blood flow, sinus ostia patency, and gas exchange. This often manifests as mucosal thickening of the maxillary sinus on CT, indicating infectious sinusitis. If the balance between the host defense mechanism and the bacteria is disrupted in favor of the bacteria, they can extend beyond the paranasal sinuses to the orbit (33). In the worst-case scenario, bacteria can travel to the orbit through the paranasal sinuses and then potentially spread further to the cavernous sinus and the brain, leading to conditions such as cavernous sinus thrombosis, meningitis, or encephalitis. Delayed drainage of a brain abscess can lead to fatal consequences (32).

The authors list four groups of people with a predisposition to the development of orbital cellulitis. This is associated with their altered or compromised immunological state or metabolic disorders. The groups are pregnant women, heroin addicts, diabetics, and those with nephrotic syndrome (33).

Orthopantomography is used to locate the origin of an odontogenic infection that has spread to the orbit (32). When patients experience symptoms such as eyelid swelling, proptosis, ophthalmoplegia, and decreased visual acuity, a CT scan is performed to assess the condition of the maxillary sinus and orbit. This helps to determine if there is inflammation in the sinus and orbit and if there are any potential cerebral complications. The presence of air on the CT scan indicates an abscess in the orbit. MRI is used to visualize the soft tissues of the retro maxillary region and cavernous sinus (33).

The initial symptoms include inflammation of the conjunctiva, drooping eyelids, discharge from the eye, redness, and swelling of the eye and surrounding area. Later, symptoms may progress to eye displacement, bulging eyes, reduced vision, and color discrimination, accompanied by pain when moving the eye (32).

Inflammation in the preseptal area is caused by microbes entering through the skin, resulting in eyelid swelling. Typically, treatment involves antibiotics and, in some cases, corticosteroids (32).

In cases of postseptal inflammation, the orbital tissue can become infected and may progress to involve the brain. Treatment may involve incision, drainage, addressing dental causative agents, administering antibiotics, and surgical procedures such as endoscopic transnasal drainage of purulent contents. In cases of bulbar perforation and endophthalmitis, orbital evisceration surgery may be necessary. The severity of the clinical presentation depends on the involvement of inflammatory cells and bacteria in the cerebral and postseptal areas (32).

Infectious sinusitis can be caused by various microbes. It is believed that odontogenic infections, in the same manner as nonodontogenic infections, can spread to the orbit and cause vascular occlusion in the ocular and orbital arteries, as well as damage to the optic nerve, ultimately resulting in blindness (33).

For this reason, it is important to diagnose odontogenic orbital cellulitis in a timely manner, given that it is much easier to treat in its early stages (32).



## **2.5 Retrieval of displaced tooth**

### 2.5.1 The Caldwell-Luc procedure

The Caldwell-Luc procedure is a traditional surgical technique used for over a century to treat maxillary sinus pathology. Americans Caldwell and the Frenchman Luc developed it independently. The procedure aims to provide a clear view of the maxillary sinus and completely remove any diseased mucosa. This procedure aims to treat chronic sinusitis, which, among other possible reasons, can be caused by intrinsically displaced foreign bodies, such as teeth, or by an impacted tooth in the maxillary sinus (28,34).

In addition, a surgical procedure is performed to create an opening in the inferior meatus for postoperative drainage (34,35).

The Caldwell-Luc procedure is performed in cases of repairing defects caused by trauma, oroantral fistula, removal of foreign bodies, neoplasms, fungal balls, or more complicated procedures such as ligating vessels in the pterygomaxillary space. It is also used for orbital decompression in Graves' ophthalmology (34,35).

Even though endoscopic-assisted surgery and antrostomy have been used since the 1980s, in cases where a maxillary tooth has been displaced into the sinus due to extraction or if there is a cyst, polyp, or tumor present, the endoscopic technique may not provide enough access to the maxillary sinus. In such cases, greater insight and access to the maxillary sinus is needed, especially if there is a need to look into the pterygomaxillary fossa or to ligate the internal maxillary artery (34,35).

Given that this method of opening and accessing the maxillary sinus is invasive, it does not preserve the integrity of the natural mucociliary drainage of the sinus. This often results in the loss of clearance of the sinus mucosa due to the absence of the natural mucosa and the newly built mucosa (28, 34).

In retrospective studies, the Caldwell-Luc operation has had high complication rates. For instance, Defreitas and Lucete reported that out of 670 Caldwell-Luc interventions, 522 resulted in complications. These complications included facial swelling in 89% of patients, high fever in 12% of patients, and significant bleeding in 3% of cases. Later issues included facial asymmetry, numbness, opening between mouth and sinus, reopening of gum wounds, inflammation of the tear duct, tooth nerve damage, sinus infections, and repeated growths in varying proportions (28).

In case of the extraction, the surgical procedure begins by placing the patient in a supine position to allow gravity to do its work so that the tooth is mobile and falls into the narrow part of the posterior side of the maxillary sinus. After anesthetizing the posterior superior alveolar artery and greater palatine artery with a local block, we infiltrate the buccal mucosa in the projection where the vestibular incision will be made (36).

A vestibular horizontal incision is made from above the canine to the first molar. For proper repositioning of the flap later, a vertical incision of sufficient height is crucial (35).

After raising the mucoperiosteal flap to expose the canine fossae, we access the maxillary sinus through an anterior antrostomy to avoid damaging the infraorbital nerve (35,36).

To enter the sinus, we can use electric drills, trocars, and Kerrison punches, as well as more risky techniques such as a hammer and chisel (35).

Once the maxillary sinus is opened, the displaced tooth is removed, making sure not to injure the superior alveolar artery and the infraorbital nerve (35,36).

If a tooth is displaced but still movable, it can be removed directly from the posterior part of the sinus using a sterile metal suction (36). However, if the tooth is trapped between the sinus mucosa and the bone, it is removed by first lifting the mucosa lining. If the tooth is stuck inside the sinus by the sinus mucosa, it is first loosened using a curette (36).

When there is chronically inflamed mucosa present, part of the Caldwell Luc technique is to lift and remove such mucosa, most often with Coakley curettes and forceps. After this, an antrostomy is performed in the area of the inferior meatus, enabling postoperative blood drainage (35). The anterior maxillary wall is left open, and the flap is repositioned with an absorbable suture (35). Non-absorbable sutures are usually removed one week after the operation (36). The wound heals primarily (36).

The first postoperative follow-up is scheduled for the day after the operation, then one week later, and finally six weeks after the procedure to check for any potential complications.

After the surgery, the oroantral communication is checked several hours later. If it is less than 5 mm, gel foam is sufficient. If it is greater than 5 mm, then suturing is necessary.

Patients should be warned that they will bleed normally for the next 2-3 days. They are given antibiotics and advised to avoid blowing their nose, use straws, and eat softer food. Subsequent examinations check for possible Caldwell-Luc complications, such as bleeding, swelling, and facial numbness (36).

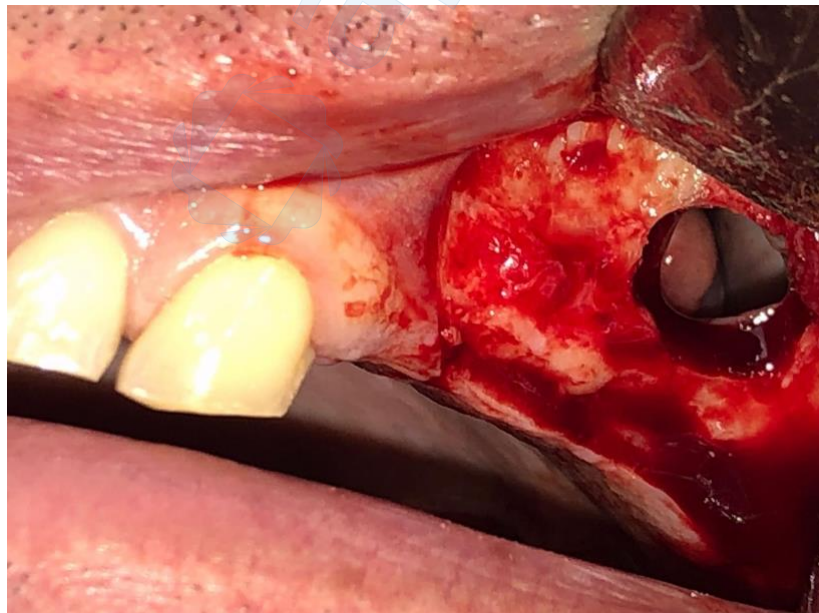


Figure 4. Surgical extraction of a displaced tooth from the maxillary sinus (CT scan).

Courtesy of: Assist. Prof. Josip Biočić

### 2.5.2 Endoscopic approach

This minimally invasive technique removes pathological mucosa, foreign bodies, and displaced teeth while preserving the physiological function of the ciliated epithelium (11,32). The transnasal endoscopic approach offers adequate visualization of the surgical area, resulting in minimal patient discomfort and high patient acceptance (15, 37).

Unlike the Caldwell-Luc procedure, the endoscopic approach requires minimal incisions, leaves no scars in the oral cavity, and does not require a long hospital stay. It allows the operator to identify the cause of sinus problems without impacting its function, thus reducing the risk of complications. One study suggests a success rate of 99% for this procedure (28).

Endoscopic tooth extraction involves using an endoscope with a camera to locate and extract the tooth using angled nasal forceps (8,38). If pathologically changed mucosa is present, it is also removed during the procedure (8).

The nasal endoscopy procedure is typically done under general anesthesia, with local anesthesia used to minimize bleeding. First, a rigid 0-degree endoscope is inserted into the middle meatus, 4mm, and an uncinectomy is performed. Once the ostium is located, it is expanded posteriorly with an antrostomy, allowing access to the maxillary sinus. Subsequently, a 45-degree and 70-degree endoscope is employed to enter the maxillary sinus. The direction of movement depends on the type of sinusotomy (28).

Ectopic teeth may be found anywhere in the maxillary sinus. The authors recommend that those located posteriorly and laterally be assisted with a trans-canine fossa approach in addition to the endoscopic approach. Nowadays, cases have been reported where ectopic teeth were successfully extracted endoscopically, regardless of their location, whether medial, lateral, posterior, or in the area of the orbital floor (38).

Before the surgical procedure, it is important to accurately locate the tooth. CT and CBCT are the best options for evaluating the sinus, understanding the anatomy of the ectopic tooth, and identifying any possible pathology. The proper analysis of radiological images is crucial for determining the approach to a surgical procedure (38).

Depending on the location of the tooth, the maxillary sinus is approached accordingly. When the tooth is in the upper parts of the maxillary sinus, we use a middle meatal antrostomy. If the tooth is in the posterior or inferior part, an inferior meatal antrostomy is performed. The tooth is extracted using grasping instruments such as Blakesley forceps. If the tooth is too large for this procedure, the extraction can also be done through the nasopharynx into the oral cavity (38).

In many cases, an ectopic tooth is associated with a cyst. In such situations, in addition to extraction, the cyst is enucleated using the same approach (38).

Complications of this surgical procedure are possible, especially if the operator is not familiar with anatomical landmarks, which can lead to iatrogenic injuries to the greater palatine artery, posterior lateral nasal branches, and sphenopalatine artery. Although orbital injuries occur only in 0.5%, they can have serious consequences. Post-operative nasolacrimal duct injury occurs in 15% of cases, but it does not have lasting effects. Additionally, mucosal recirculation can occur when the surgical antrostomy fails to connect with the natural ostium, resulting in sinus pressure, nasal congestion, and recurrent sinusitis (39). Given this, the process requires a high level of expertise and precision (11).



### **3. DISCUSSION**

Displacement of a tooth into the maxillary sinus can pose significant challenges and risks, leading to symptoms such as sinusitis, swelling, and trismus and potentially resulting in legal issues (10). Iatrogenic displacement during dental procedures is widespread with the maxillary first and third molars, with an approximate prevalence of 0.6-3.8% (8). Contributing factors include poor anatomical consideration, excessive force during extraction, and inadequate radiological assessment (8,9).

This emphasizes the need for careful planning and execution of dental procedures to minimize the risk of such complications. The successful management of this complication relies on an accurate diagnosis and the implementation of appropriate treatment strategies. Radiological imaging, particularly CT scans, is crucial in detecting tooth displacement and planning surgical procedures (8).

Treatment typically involves tooth extraction and addressing associated mucosal issues through endoscopic or Caldwell-Luc procedures. Early surgical intervention is recommended to prevent further complications (8). Various factors, including developmental disorders, trauma, and pathological processes, contribute to formation of ectopic teeth (21). The diagnosis and treatment depend on many factors but usually involve removing the cyst and extracting the tooth (20). Traumatic maxillofacial injuries, although less common, can also result in tooth displacement into neighboring tissues. Prompt assessment and radiological analysis are crucial for identifying such injuries and initiating appropriate treatment (16).

Maxillary sinusitis is the primary complication of tooth displacement into the maxillary sinus caused by an oroantral communication or irritation from the displaced teeth (8). Treatment options for tooth displacement include trans-alveolar extraction, Caldwell-Luc operation or endoscopic techniques. Careful consideration is given to the stability of the tooth before surgical removal, with fibrous connective tissue helping limit the movement of the tooth within the sinus (17).

The decision to extract a tooth from the maxillary sinus depends on the severity of the clinical situation (28).

If a tooth or dental fragment is accidentally pushed into the sinus without signs of infection or inflammation, and there is no visible perforation of the sinus lining or if it is less than 3 mm, the tooth or tooth fragment can even be left in place, but under careful follow-up (28).

Regular check-ups are necessary, and antibiotics may be prescribed initially, along with decongestants, until the defect is anatomically repaired.

Extraction of the tooth is required if the perforation is more significant than 3 mm or if there are symptoms of inflammation due to infection (28).

Authors recommend removing these foreign bodies, even in asymptomatic cases, to prevent sinus infections and their complications (8).







#### **4. CONCLUSION**

Although not very common, displacement of a tooth into the maxillary sinus is a potentially serious complication that requires prompt, careful and delicate treatment. To minimize the risk of such incidents, it is crucial to provide careful guidance during the extraction procedure and perform precise radiological examinations and diagnostic methods to identify potential risk factors before the procedure. Additionally, continuous refinement of dental techniques and approaches can further help minimize the risk of such iatrogenic complications.

Even if complications occur, doctors of dental medicine must be prepared to expertly and conscientiously handle the situation, upholding their oath. This commitment emphasizes the responsibility to provide proper care to patients while avoiding unnecessary interventions or neglecting treatment options.





## **5. REFERENCES**

1. Abdalla MA. Human maxillary sinus development, pneumatization, anatomy, blood supply, innervation and functional theories: an update review. *Siriraj Med J.* 2022;74(7):472-9.
2. Whyte A, Boeddinghaus R. The maxillary sinus: physiology, development and imaging anatomy *Dentomaxillofac Radiol.* 2019;48(8):33-8.
3. Somayaji K, Muliya VS, KG MR, et al. A literature review of the maxillary sinus with special emphasis on its anatomy and odontogenic diseases associated with it. *Egypt J Otolaryngol.* 2023;39:173.
4. Iwanaga J, Wilson C, Lachkar S, Tomaszewski KA, Walocha JA, Tubbs RS. Clinical anatomy of the maxillary sinus: application to sinus floor augmentation. *Anat Cell Biol.* 2019 ;52(1):17-24.
5. Reihe D. *Anatomija.* Zagreb:Medicinska naklada 2018. 1042-1048 p.
6. Tilaveridis I, Stefanidou A, Kyrgidis A, Tilaveridis S, Tilaveridou S, Zouloumis L. Foreign Bodies of Dental Iatrogenic Origin Displaced in the Maxillary Sinus - A Safety and Efficacy Analysis of a Retrospective Study. *Ann Maxillofac Surg.* 2022;12(1):33-38.
7. Kirkham-Ali K, La M, Sher J, Sholapurkar A. Comparison of cone-beam computed tomography and panoramic imaging in assessing the relationship between posterior maxillary tooth roots and the maxillary sinus: A systematic review. *J Investig Clin Dent.* 2019;10(3):1-7.
8. Toledano-Serrabona J, Cascos-Romero J, Gay-Escoda C. Accidental dental displacement into the maxillary sinus during extraction maneuvers: a case series. *Med Oral Patol Oral Cir Bucal.* 2021;26(1):102-7.
9. Allen DZ, Sethia R, Hamersley E, Elmaraghy CA. Presentation of an iatrogenically displaced third molar into the maxillary sinus in a 14-year-old patient successfully removed with an endoscopic approach: a case report and a review of the literature. *J Surg Case Rep.* 2020;2020(10):1-3.
10. Khan M, Mehboob B, Kundi JA. Pattern and management of iatrogenic displacement of teeth in maxillofacial anatomical spaces. *Pak Oral Dent J.* 2015;35:186-9.
11. Aukštakalnis R, Simonavičiūtė R, Simuntis R. Treatment options for odontogenic maxillary sinusitis: a review. *Stomatologija.* 2018;20(1):22-26.
12. Sahin YF, Muderris T, Bercin S, Sevil E, Kırıs M. Chronic maxillary sinusitis associated with an unusual foreign body: a case report. *Case Rep Otolaryngol.* 2012;2012:1-4.

13. Asmael HM. The Modified Caldwell-Luc Approach in Retrieval of Accidentally Displaced Root into the Maxillary Sinus. *J Craniofac Surg.* 2018;29(2):130-31.
14. Wilk G, Modrzejewska M, Lachowicz E, Lisiecka-Opalko K, Myśliwiec L, Rutkowski D, et al. From ophthalmologist to dentist via radiology. *Pol J Radiol.* 2012;77(1):21-7.
15. Amorim Kde S, da Silva VT, da Cunha RS, Souto ML, São Mateus CR, Souza LM. Removal of an upper third molar from the maxillary sinus. *Case Rep Dent.* 2015;2015:517149.
16. Reddy LV, Bhattacharjee R, Misch E, Sokoya M, Ducic Y. Dental Injuries and Management. *Facial Plast Surg.* 2019;35(6):607-13.
17. Wang H, Yang CY, Li Z. Traumatic displacement of teeth into maxillary sinus and the retrieval assisted by computer-assisted navigation: A case report. *Medicine (Baltimore).* 2018;97(51):1-5.
18. Chrcanovic BR, Bueno SC, da Silveira DT, Custódio AL. Traumatic displacement of maxillary permanent incisor into the nasal cavity. *Oral Maxillofac Surg.* 2010;14(3):175-82.
19. Ramanojam S, Halli R, Hebbale M, Bhardwaj S. Ectopic tooth in maxillary sinus: Case series. *Ann Maxillofac Surg.* 2013;3(1):89–92.
20. Guruprasad Y, Chauhan DS, Kura U. Infected dentigerous cyst of maxillary sinus arising from an ectopic third molar. *J Clin Imaging Sci.* 2013;3(1):7.
21. Buyukkurt MC, Omezli MM, Miloglu O. Dentigerous cyst associated with an ectopic tooth in the maxillary sinus: a report of 3 cases and review of the literature. *Oral Surg Oral Med Oral Pathol Oral Radiol Endod.* 2010;109(1):67-71.
22. AlKhudair B, AlKhatib A, AlAzzeh G, AlMomen A. Bilateral dentigerous cysts and ectopic teeth in the maxillary sinuses: A case report and literature review. *Int J Surg Case Rep.* 2019;55:117-20.
23. Lukšić I. i sur. Maksilofacijalna kirurgija. Zagreb:Naklada Ljevak 2019. 64 p.
24. Chybicki D, Popielarczyk A, Markowski W, Torbicka G, Janas-Naze A. Infected Dentigerous Cyst of Maxillary Sinus Mimicking Intraoral Abscess in a Pediatric Patient: Management of Misdiagnosis and Inaccurate Treatment. *Case Rep Dent.* 2022.
25. Lo Faro C, Santillo V, Lo Giudice G, Troiano A, Montella M, D'Amato S, et al. Large Follicular Cyst Associated with Upper Third Molar in the Maxillary Sinus with Pterygomaxillary Space Extension: Reflection on a Case Report. *Open Access Maced J Med Sci.* 2021;9(1):16-9.

26. Kumar A, Srivastava RK, Saxena A, Khanna R, Ali I. Removal of Infected Maxillary Third Molar from the Infra-temporal Fossa by Caldwell Luc Procedure - Rare Case Report with Literature Review. *J Clin Diagn Res.* 2016;10(12):1-3.
27. Scadding GK. Rhinitis and Sinusitis. *Clinical Respiratory Medicine.* 2008;409–23.
28. Martu C, Martu MA, Maftai GA, Diaconu-Popa DA, Radulescu L. Odontogenic Sinusitis: From Diagnosis to Treatment Possibilities-A Narrative Review of Recent Data. *Diagnostics (Basel).* 2022;12(7):1600.
29. Craig JR. Odontogenic sinusitis: A state-of-the-art review. *World J Otorhinolaryngol Head Neck Surg.* 2022;8(1):8–15.
30. Sakkas A, Weiß C, Ebeling M, Pietzka S, Wilde F, Evers T, et al. Factors Influencing Recurrence after Surgical Treatment of Odontogenic Maxillary Sinusitis: An Analysis from the Oral and Maxillofacial Surgery Point of View. *J ClinMed.* 2023;12(11):3670.
31. Kwon MS, Lee BS, Choi BJ, Lee JW, Ohe JY, Jung JH, et al. Closure of oroantral fistula: a review of local flap techniques. *J Korean Assoc Oral Maxillofac Surg.* 2020;46(1):58–65.
32. Antonio R, Stefania T, Umberto C, Antonio A, Dell'Aversana Orabona G, Francesco S, et al. Surgical Approaches in Odontogenic Orbital Cellulitis (OOC): Our Experience and Review of Literature. *Indian J Otolaryngol Head Neck Surg.* 2022;74(3):4552-61.
33. Youssef OH, Stefanyszyn MA, Bilyk JR. Odontogenic orbital cellulitis. *Ophthalmic Plast Reconstr Surg.* 2008;24(1):29-35.
34. Gadad RD, Saxena V, Rangarajan H. Caldwell Luc in the era of endoscopic approach for maxillary sinus. *J Dent Def Sect.* 2022;16(2):171-73.
35. Matheny KE, Duncavage JA. Contemporary indications for the Caldwell-Luc procedure. *Curr Opin Otolaryngol Head Neck Surg.* 2003;11(1):23-6.
36. Huang IY, Chen CM, Chuang FH. Caldwell-Luc procedure for retrieval of displaced root in the maxillary sinus. *Oral Surg Oral Med Oral Pathol Oral Radiol Endod.* 2011;112(6):59-63.
37. Viterbo S, Griffa A, Boffano P. Endoscopic removal of an ectopic tooth in maxillary sinus. *J Craniofac Surg.* 2013;24(1):46-8.

38. Masalha M, Schneider S, Kassem F, Koren I, Eliashar R, Margulis A, et al. Endoscopic treatment of ectopic teeth in the maxillary sinus. *J Clin Exp Dent.* 2021;13(3):227-33.
39. McCormick JP, Hicks MD, Grayson JW, Woodworth BA, Cho DY. Endoscopic Management of Maxillary Sinus Diseases of Dentoalveolar Origin. *Oral Maxillofac Surg Clin North Am.* 2020;32(4):639-48.





## **6. CURRICULUM VITAE**



Andela Grubišić was born on February 7th, 2000, in Zagreb, Croatia. She started her education at Vukomerec Primary School in Zagreb. In 2014, she continued her studies at the III. Gymnasium, also located in Zagreb. In 2018, Andela enrolled in the School of Dental Medicine at the University of Zagreb. In her third year of studies, Andela started assisting Professor Matijević in his private practice in Zagreb. During this period, she participated in several student congresses and symposiums as a member of the Prosthodontics Section. In the academic year 2023/24, she became the leader of the Prosthodontics Section. She was awarded for all the help and contribution to the sixth and seventh "Student symposiums of dental medicine" for the academic years 2022/23 and 2023/24.

In the summer of 2023, she earned a diploma from the New York University College of Dentistry for completing the International Summer Practicum for dental students, which took place in July and August.

Andela was also awarded the Dean's Award for best student of "The Dental Medicine Study Program in English" for her academic achievement in the fourth year of 2021/2022.

