

Paleodontološka analiza zuba iz željeznodobne pećinske grobnice kod Gornjeg Vakufa, Bosna i Hercegovina

Zukanović, Amila; Vodanović, Marin; Mulaomerović, Jasminko

Source / Izvornik: **Acta medico-historica Adriatica : AMHA, 2012, 10, 9 - 22**

Journal article, Published version

Rad u časopisu, Objavljena verzija rada (izdavačev PDF)

Permanent link / Trajna poveznica: <https://urn.nsk.hr/urn:nbn:hr:127:966529>

Rights / Prava: [Attribution 4.0 International](#)/[Imenovanje 4.0 međunarodna](#)

Download date / Datum preuzimanja: **2024-06-30**



Repository / Repozitorij:

[University of Zagreb School of Dental Medicine
Repository](#)



PALAEODONTOLOGICAL ANALYSIS OF AN IRON AGE DENTAL SAMPLE FROM A CAVE BURIAL SITE NEAR GORNJI VAKUF, BOSNIA AND HERZEGOVINA

PALEODONTOLOŠKA ANALIZA ZUBA IZ ŽELJEZNODOBNE PEĆINSKE GROBNICE KOD GORNJEG VAKUFA, BOSNA I HERCEGOVINA

Amila Zukanović*, Marin Vodanović**, Jasminko Mulaomerović***

SUMMARY

This article presents the results of a palaeocultural and palaeodontological research of Cave No. 5 near the villages of Bistrica and Krupa in the municipality of Gornji Vakuf, southwest Bosnia. This cave is located on the west slope of Mt Vranica. Inside the cave, several artefacts and skeletal remains of about 20 persons have been found.

Radiocarbon ^{14}C analysis of one bone sample showed that people whose remains were found in the cave lived 2765 ± 75 years ago. Palaeodontological examinations on a total sample of 36 human teeth included tooth status, occlusal tooth wear, presence of developmental enamel defects, and odontometric analysis.

Key words: *Paleodontology, Iron Age, Cave burial, Bosnia and Herzegovina*

* University of Sarajevo, Faculty of Dentistry, Department of preventive and pediatric dentistry, Sarajevo, Bosnia and Herzegovina

** University of Zagreb, School of Dental Medicine, Department of dental anthropology, Zagreb, Croatia

*** Center for karst and speleology, Sarajevo, Bosnia and Herzegovina.

Address for correspondence: Amila Zukanović, DDM, MSc, PhD. Faculty of Dentistry, University of Sarajevo, Bolnička 4a, BH - 71000 Sarajevo. E-mail: amila.zukanovic@hotmail.com

INTRODUCTION

According to Whittaker (1989), forensic dentistry can aid anthropologists, palaeopathologists, and archaeologists in their study of ancient populations. A multidisciplinary approach that includes forensic dentistry is essential when anthropologists and archaeologists need to interpret jaws and teeth of animal or human remains found during excavations. A problem often encountered in forensic cases is how to determine whether the skeletal findings are of recent origin or of archaeological significance. In these circumstances, a special branch of forensic dentistry – palaeodontology – comes to the fore.

Palaeodontology is a science that investigates teeth, features of stomatognathic system and oral health of ancient populations or early forms of life through skeletal or fossil remains (Vodanović, 2007). Methods used in forensic dentistry are often used also in palaeodontology. Skeletal remains of individuals are a valuable source of data necessary for reconstruction of life of a whole population. Like in forensic dentistry, the work of a dentist familiar with archaeological or anthropological research may help to determine the age, ancestry, habits, and occupation of a person, dental history, and to study jaws and teeth. Data about dental caries, antemortem tooth loss, periapical abscess, enamel hypoplasia, dental calculus and alveolar resorption are part of a dental pathology profile of earlier human populations. These data provide valuable clues regarding diet, food preparation, nutrition, and subsistence. The distribution of dental diseases by age, sex, and status can aid in identifying differential effects of nutritional stress within a population (Iscan, 1989). Diagnosis and interpretation of dental illnesses in palaeodemographic contexts are important steps in attempting to reconstruct past lives.

In recent times, the number of palaeodontological investigations increased all over the world because the need for a multidisciplinary approach to historical and cultural questions led to the development of bioarchaeology (including palaeodontology) and analysis of human skeletons in an archaeological and environmental context.

Very few dental investigations have been carried out on ancient Bosnian human remains by dentists, and up to now no investigation has been performed on an Iron Age sample. The aim of this study was to make a thorough dental examination on Iron Age human remains excavated from a cave near Gornji Vakuf in Bosnia and Herzegovina

MATERIALS AND METHODS

THE SITE

The research was carried out on skeletal remains found in the spring of 2003 in an Iron Age archaeological site located in a cave named Cave No. 5, near the town of Gornji Vakuf and Mt Vranica in southwest Bosnia (Fig. 1).

The excavations and research were organised and supported by the local municipality and included geological, speleological, archaeological, anthropological, and palaeodontological explorations. Most of the exploration involved speleological objects around the villages of Bistrica and Krupa near Gornji Vakuf (Fig. 2). As much as we know, earlier speleological explorations included a few caves near Krupa between 1971 and 1973, with the intention to find water supply resources and tourist attractions. Some explorations may have taken place even earlier, during geological researches of Mt Vranica in the late 1950s, but there is no evidence to support this. None of the researchers mentioned burial sites and human remains and little was known about artefacts in any of the caves in the area.

An archaeological site with a stone wall and ceramic fragments, located on the hill above the source of Krušnica river, has been dated to older Iron Age (Marijan, 1988). During field recognition, pieces of ceramic were

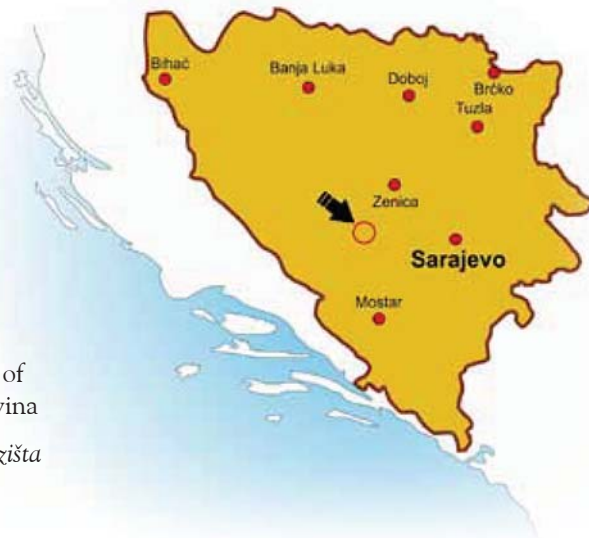

Figure 1 - The site location on the map of Bosnia and Herzegovina

Slika 1. Lokacija nalazišta na mađi Bosne i Hercegovine

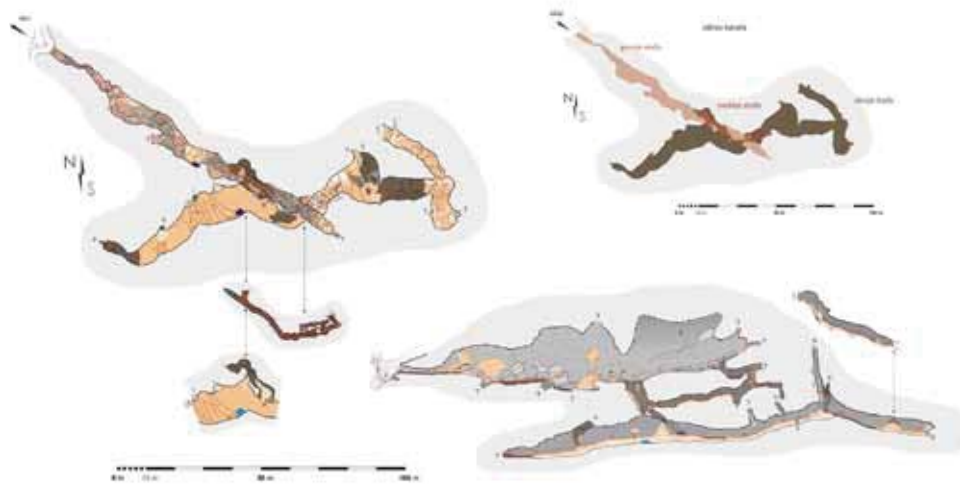


Figure 2 - The map of the cave

Slika 2. – Maĥni prikaz jame

found under the Baba Janja cave and Velika Pećina cave, Pećina in Guser cave, Caves number 4, 5, 6, and 7, Mala Pećina cave, and Cave with Three Entrances (Mulaomerović, 2005).

Cave No. 5 proved to be the most interesting from an anthropological point of view due to the finding of a huge number of human remains (bone fragments and teeth) during the last exploration. The remains were found at the end of a passage, covering 10 to 15 meters of the passage's length. Some of them were covered and fixed with cave sediments on a slope formed under a small chimney that leaked water. Along the corridor inside the cave, a large number of ceramic fragments was also found; these were later dated to a period between Iron Age and Middle Ages (Zukanović, 2007).

MATERIAL

In this study, all available teeth and bone fragments from Cave No. 5 were analysed, regardless of the level of damage. The state of preservation varied from completely preserved jaws to cases where only small fragments of the maxilla or mandible or only single teeth were preserved. Human remains were poorly preserved because of sedimentation and water leakage.

Moreover, the cave can easily be accessed from the nearest village, and local people may have compromised the preservation of this archaeological site. The part of the human remains fixed with cave sediments and impossible to remove without serious damage was left inside the cave for future research.

METHODS

Skeletal remains were commingled and often badly preserved without postcranial bones and therefore no attempt was made to determine the remains' sex and age at death. Only in cases where primary teeth were present, it was possible to estimate age at death. Figures 3, and 4 show some of the palaeodontological findings from the archaeological site.

Bone samples from the cave burial site were dated using ^{14}C at the Ruđer Bošković Institute in Zagreb, Croatia. The age span has been determined based on the dendrochronological calibrating curve according to

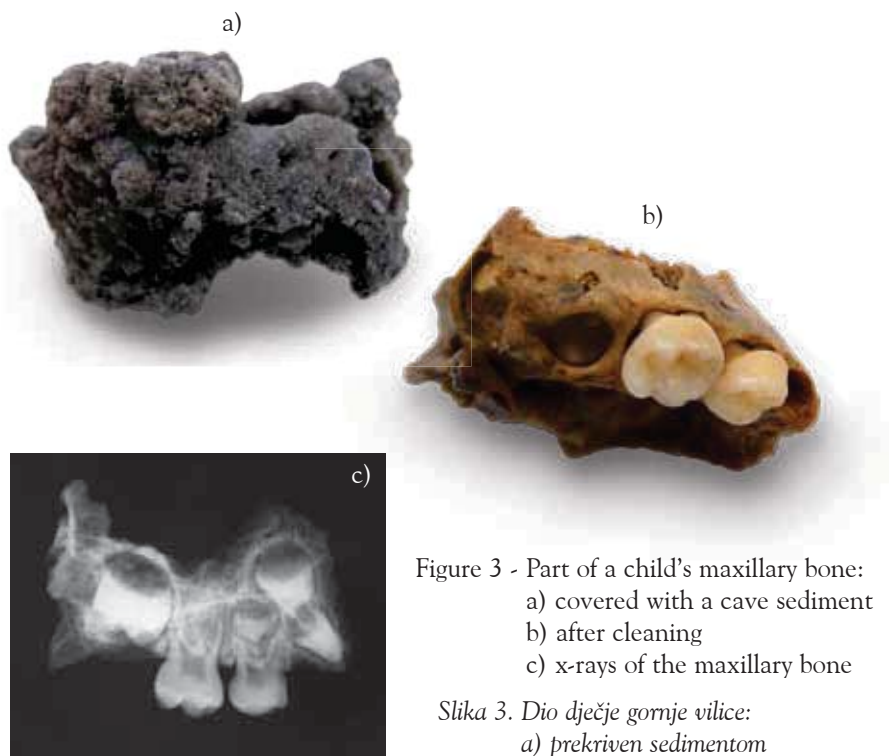
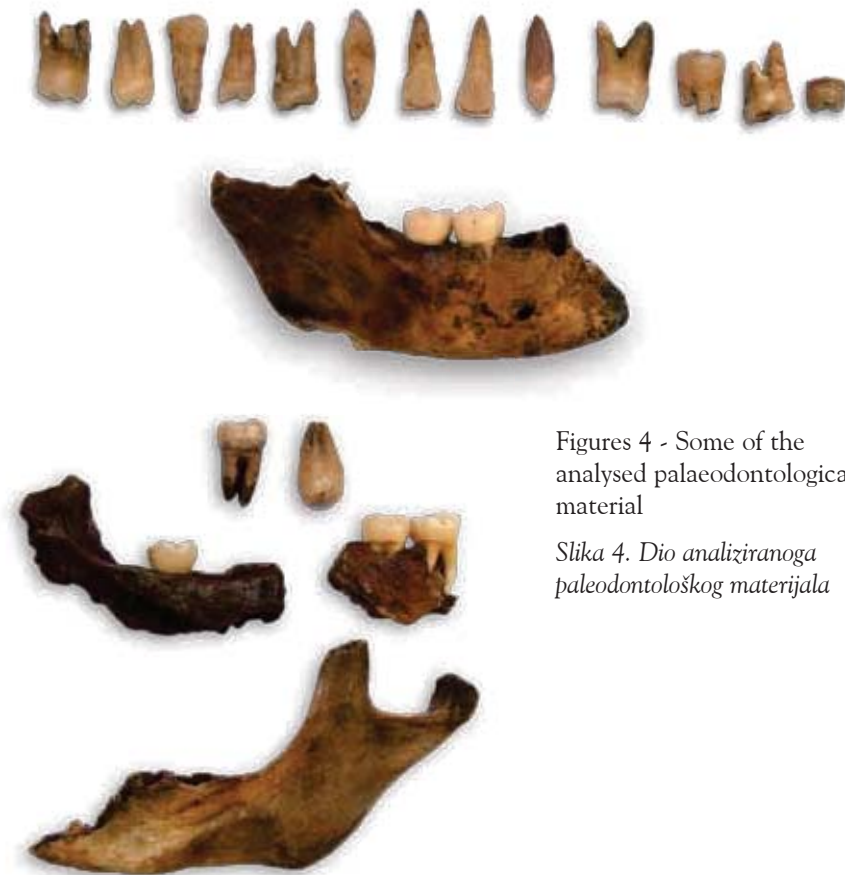

Figure 3 - Part of a child's maxillary bone:
a) covered with a cave sediment
b) after cleaning
c) x-rays of the maxillary bone

*Slika 3. Dio dječje gornje vilice:
a) prekriven sedimentom
b) nakon čišćenja
c) rendgenska snimka gornje vilice*



Figures 4 - Some of the analysed palaeodentological material

Slika 4. Dio analiziranoga paleodontološkog materijala

Stuver and Reimer (1986) and Bronk and Ramsey (1995), and is given in historical ages (AD/BC), with probability expressed in percentages within 1σ error, and has been determined based on dendrochronological calibrating curve according to Stuver&Reimer (Stuver, Reimer., 1986) and Bronk&Ramsey (Bronk, Ramsey., 1995).

This palaeodentological analysis included determining tooth status, occlusal tooth wear, presence of developmental enamel defects, and odontometric analysis. Presence of teeth and *antemortem/postmortem* teeth loss were registered using the criterion by which if the alveolus is empty, the tooth was lost *post mortem*. If there was no sign of alveolus, the tooth was lost *antemortem*.

Caries was diagnosed macroscopically under a bright light, with the help of a dental probe. A lesion was considered caries if there was a clear defect in tooth tissue. Colour changes of the enamel were not considered caries unless there was a cavity underneath. Caries was classified in three categories: 0 – no caries, 1 – *caries superficialis*, 2 – *caries media*, and 3 – *caries profunda*. Caries was diagnosed by one observer.

Occlusal tooth wear was classified in three categories: 0 – no wear, 1 – wear in enamel, and 2 – dentin exposed.

Measurements of deciduous and permanent teeth were taken with a sliding caliper. Measures of each bone and each tooth were taken three times, at one month intervals, after which the mean of those individual measures was taken as the final measure. All measurements were performed by the same person.

Mesiodistal diameter of the tooth crown was taken as the greatest mesiodistal dimension parallel to the occlusal and facial surface. Mesiodistal diameter of the tooth cervix was taken as the greatest mesiodistal dimension parallel to the occlusal and facial surface measured in the cervical part of the tooth crown. Buccolingual crown diameter was the greatest distance between the facial and lingual surfaces of the crown, taken at right angles to the plane in which the mesiodistal diameter was taken. Crown height was measured as the distance from the tip of the highest cusp to the cervical line on the buccal side. To avoid error caused by tooth wear, only teeth with a low level of abrasion and without exposed dentine were measured. Robustness (total crown area) was calculated by multiplying the mesiodistal and buccolingual diameter of the tooth crown.

ENAMEL OPACITIES/HYPOPLASIA

We used a modified index of developmental defects of the enamel (DDE), where enamel abnormalities are classified into one of three types on the basis of their appearance (FDI Commission on Oral health, 1992). The codes and criteria are as follows:

- Normal
- Demarcated opacity. Enamel with normal thickness and intact surface, with alteration in the translucency of the enamel, variable in degree. It is demarcated from the adjacent normal enamel with a distinct and clear boundary and can be white, cream, yellow or brown in colour.

- Diffuse opacity. Also alteration in the translucency of the enamel, variable in degree, with no clear boundary between the adjacent normal enamel. Opacity can be linear or patchy or have confluent distribution.
- Hypoplasia. A defect involving the surface of the enamel and associated with a localised reduction in the thickness of the enamel. It can occur in the form of pits, grooves, partial or complete absence of the enamel over a considerable area of dentine. The affected enamel may be translucent or opaque.
- Other defects
- Demarcated and diffuse opacities
- Demarcated opacity and hypoplasia
- Diffuse opacity and hypoplasia
- All three conditions
- Not recorded

RESULTS

Material analysis confirmed the presence of several individuals. Anatomical and morphological analysis of the available teeth and bones showed that they belonged to at least 13 to 20 persons. Considering that all material from the site was not analysed, the number of people can easily be more than 20, which is to be confirmed by further research.

Radiocarbon ^{14}C analysis of one bone sample (showed that people whose remains were found lived 2765 ± 75 years ago, that is, in the Iron Age.

Table 1 Dental sample: number of permanent teeth

Tablica 1. Zubni uzorak – broj trajnih zuba

	Maxilla	Mandible	Total
I1	3	0	3
I2	1	0	1
C	0	1	1
P1	3	0	3
P2	3	1	4
M1	2	8	10
M2	2	5	7
M3	1	0	1
Total	15	15	30

Table 2 Dental sample: number of primary teeth

Tablica 2. Zubni uzorak – broj mliječnih zuba

	Maxilla	Mandible	Total
i1	0	0	0
i2	0	0	0
c	0	0	0
m1	1	1	2
m2	1	3	4
Total	2	4	6

The total dental sample consisted of 36 teeth (30 permanent and 6 primary teeth) (Table 1 and 2).

Odontometrics was carried out on all teeth (n=36). For 10 teeth (27%), crown height couldn't be measured due to tooth wear, and six teeth (19.5 % of the total dental sample) were excluded from all odontometric measurements due to abrasion of the second degree (occlusal tooth wear where dentin is exposed). Odontometric results (mesiodistal and buccolinqual crown diameter, crown height and robustness) are presented in Table 3.

In the total sample, 23 teeth (64 %) showed occlusal tooth wear. Occlusal tooth wear of the enamel was documented in 14 teeth (38.1%), and of the dentin in 29 teeth (25%). Proximal tooth wear of the enamel was seen in seven teeth (19.4%), mostly located on the mesioaproximal surface.

Twelve teeth (33.3%) showed developmental enamel defects (opacities and/or hypoplasia). Of these, two (5.55 %) had demarcated opacities, four (11.3%) diffuse opacities, four (11.3%) hypoplasia, and two diffuse opacities and hypoplasia. Sixty-six percent of the teeth were without any developmental enamel defects.

Eight teeth (22 %) had initial occlusal caries and just one tooth had caries that extended into the dentin (*caries media*), also on the occlusal surface. None of the examined teeth had deep carious lesions.

The presence of caries, cervical lesions, tooth wear, and developmental enamel defects (opacities and/or hypoplasia) is shown in Table 4.

Table 3. Odontometric findings

Tablica 3. Rezultati odontometrijskih analiza

Code	Tooth	Mesiodistal length	Buccolingual breadth	Crown height	Total crown area
1	M1-mand, right	10.85	10.00	-	108.50
2	M1-max, right	11.00	10.75	7.15	118.25
3	P1-max, right	7.75	10.30	8.90	79.80
4	P2-max, right	7.25	10.50	8.52	76.12
5	M2-max, right	9.15	10.45	6.70	95.61
6	P2-max, right	6.40	9.15	7.20	58.56
7	P2-mand, right	-	-	-	-
8	P1-max, left	5.85	7.60	6.17	44.46
9	P1-max, left	-	-	-	-
10	C1-mand, right	5.70	6.85	9.80	39.04
11	I1-max, right	-	-	-	-
12	I1-max, left	-	-	-	-
13	I2-max, left	6.50	6.40	9.27	41.60
14	M1-max, right	9.85	11.70	6.45	115.24
15	M2-mand, left	9.75	9.70	6.70	94.57
16	M1-mand, left	-	-	-	-
17	M1-mand, right	10.02	10.65	-	106.70
18	M2-mand, right	9.75	9.40	-	91.65
19	M3-max, right	9.40	7.35	6.50	-
20	M2-mand, left	10.95	10.90	6.75	119.35
21	P2-max, left	8.42	10.57	7.00	88.90
22	M1-mand, left	11.70	10.30	-	120.51
23	M1-mand, left	11.70	10.30	-	120.51
24	M2-mand, left	10.70	9.85	-	105.39
25	M1-mand, right	11.10	10.50	-	116.55
26	M2-mand, right	10.50	10.20	-	107.10
27	C1-max, right	-	-	-	50.90
28	m1-mand, left	7.70	8.05	6.50	61.98
29	m2-mand, left	9.60	8.75	6.80	84.00
30	M1-mand, right	10.6	10.35	-	109.71
31	M1-mand, left	10.72	10.05	-	107.73
32	m2-mand, right	-	-	-	-
33	m2-mand, left	-	-	-	-
34	m1-max, right	7.55	9.20	5.65	69.46
35	m2-max, right	9.80	9.82	6.75	96.23
36	M2-max, left	10.05	12.45	7.10	125.12

Table 4. Caries, cervical lesions, tooth wear, and developmental enamel defects (opacities and/or hypoplasia)

Tablica 4. Prisutnost karijesa, cervikalnih lezija, istrošenosti zuba i razvojnih anomalija cakline (zamućenja i/ili hipoplazija)

Code	Tooth	Caries	Cervical lesion	Tooth wear		DDI
				occlusal	aproximal	
1	M1-mand, right	2 occlusal and labial	0	2	0	0
2	M1-max, right	1 occlusal	0	0	0	0
3	P1-max, right	0	0	0	0	0
4	P2-max, right	0	0	0	0	0
5	M2-max, right	0	0	0	0	0
6	P2-max, right	0	0	0	0	0
7	P2-mand, right	0	0	2	0	3
8	P1-max, left	0	0	0	0	3
9	P1-max, left	0	vestibular	2	0	0
10	C1-mand, right	0	0	0	0	7
11	I1-max, right	0	0	2	0	3
12	I1-max, left	0	0	2	0	0
13	I2-max, left	0	0	0	0	0
14	M1-max, right	0	0	1	1 mesioaproximal	0
15	M2-mand, left	1 occlusal	0	1	0	7
16	M1-mand, left	0	0	2	1 mesioaproximal	0
17	M1-mand, right	1 occlusal	0	1	0	0
18	M2-mand, right	0	0	1	0	0
19	M3-max, right	1 occlusal	0	0	0	2
20	M2-mand, left	1 occlusal	0	1	1 mesioaproximal 1 distoaproximal	3 vestibular
21	P2-max, left	0	0	1	1 mesioaproximal	2
22	M1-mand, left	0	mesioaproximal	1	1 mesioaproximal	1 vestibular
23	M1-mand, left	0	0	1	0	1
24	M2-mand, left	0	0	1	0	2
25	M1-mand, right	0	lingual	1	1 mesioaproximal	0
26	M2-mand, right	1 occlusal	vestibular	1	0	0
27	C1-max, right	0	0	2	0	0
28	m1-mand, left	1 occlusal	0	0	0	0
29	m2-mand, left	0	0	0	0	0
30	M1-mand, right	0	0	1	0	2
31	M1-mand, left	1 occlusal	0	1	0	0
32	m2-mand, right	0	0	2	0	0
33	m2-mand, left	0	0	2	0	0
34	m1-max, right	0	0	0	0	0
35	m2-max, right	0	0	0	0	0
36	M2-max, left	0	0	1	1 mesioaproximal	0

DISCUSSION AND CONCLUSION

The excavation site described in this manuscript is interesting in many aspects, particularly as a necropolis. Archaeological findings that include numerous pieces of ceramics and one metal needle date this necropolis back to the Iron Age. This has been confirmed by subsequent ^{14}C analysis of bone fragments from the excavation site, which sets them to 2765 ± 75 years from now.

The interpretation of odontometric results was limited by the small sample size and in some cases significant tooth wear. However, taking into account that there are but a few similar investigations of the same historic period in this area, these results seem to add pieces to the puzzle about teeth dimensions of the Iron Age inhabitants of today's Bosnia and Herzegovina. As shown in Table 3, only three tooth dimensions could be determined: mesiodistal and buccolingual tooth width and crown height. Our results are similar to results obtained by Teschler-Nicola (1998) and Vodanović (2007), who examined the same period or a similar geographic area. A more comprehensive analysis and better comparison between historic periods and geographic areas would require a larger sample.

As expected, tooth wear affected two thirds of the examined sample. Existing historical evidence suggests that Iron Age populations had significant tooth wear, mainly caused by dietary patterns and food preparation (Nelson, 1999). Unfortunately, because of the poorly preserved sample, we could not determine sex and estimate age at death. Considering the highly positive correlation between tooth wear and age, the significant prevalence of tooth wear in the examined sample suggests that the analysed remains probably belonged to elderly people.

High prevalence of developmental enamel defects (33.3%) suggests that stress in childhood, including infectious diseases which disturbed the normal development of teeth, was more common than in recent populations. In contrast, compared to other historical periods, it seems that the prevalence of enamel hypoplasia in our study (33.3%) is lower than in other ancient populations, where it reached 37.5% (Poundbury Camp, England 4 c. AD) and even 100.0% (Vicenne; Italy 6–8 c. AD) (Slaus, 2008).

Nelson et al. (1999) and Vodanović (2005) compared the prevalence of carious teeth in the Iron Age at different sites from all over the world and found that it ranged from 0.0% in the area of former Yugoslavia in the Mesolithic (705 teeth were examined) to 32.4% in the Samad Oasis (182

teeth were examined). In this respect, caries prevalence in our sample (25%) seems relatively high, but this finding has a limited value due to the small sample size.

It is well known that in the Bronze and Iron Age cave burials in tumuli and flat necropoleis were as common as cremation. In our cave necropolis, we found human remains of about 20 persons, including a few skeletal remains that certainly belonged to children. Poor site preservation renders it impossible to definitely establish the number of persons buried inside, at least for the moment. A great number of skeletal remains is covered with cave sediments and fixed to the underlying surface, which did not allow collection of all material for analysis. A comprehensive archaeological and anthropological research is needed to give answers about the characteristics of this cave necropolis that would be of anthropological and historical value. For now, all we know about this and other caves near the villages of Bistrica and Krupa is that they had a ritual use.

REFERENCES

1. Bordeaux, A. 1987: "Narodna Bosna". In: Fojnica kroz vijekove.- Skupština opštine Fojnica & SOUR "Veselin Masleša", Fojnica – Sarajevo. (According to issue of PLON, Paris, 1904.).
2. Bronk, R.C. 1978: Radiocarbon calibration and analysis of stratigraphy: the OxCal program. - Radiocarbon 37: 425-30.
3. FDI Commission on Oral health, Research and Epidemiology. 1992: An epidemiological index of developmental defects of dental enamel (DDE index). Int Det J 42:411-26.
4. Iscan MY, Kennedy KAR. 1989: Reconstruction of life from the skeleton. Alan R. Liss Inc, New York.
5. Marijan, B. 1988: Gradina, Krupa, Gornji Vakuf . In: Arheološki leksikon Bosne i Hercegovine, T. 2., Zemaljski muzej BiH, Sarajevo.
6. Mulaomerović, J. 2004: Tragovi kultura u pećinama okolice Gornjeg Vakufa u Bosni. Speleozin, XII, 17: 60-3.
7. Nelson GC, Lukacs JR, Yule P. 1999: Dates, caries, and early tooth loss during the Iron Age of Oman. Am J Phys Anthropol 108:333-43.
8. Slaus M. 2008: Osteological and dental markers of health in the transition from the Late Antique to the Early Medieval period in Croatia. Am J Phys Anthropol 136:455-69.

9. Stuiver M, Reimer P. J. 1986: A computer program for radiocarbon age calculation. - Radiocarbon 28: 1022-30.
10. Teschler-Nicola M, Prossinger, H. 1998: Sex determination using tooth dimensions. In: Alt KW, Roßsing FW, Teschler-Nicola M. (eds.). Dental Anthropology, Fundamentals, Limits and Prospects. Springer-Verlag, Wien, pp. 479e501.
11. Vodanović M, Brkić H, Šlaus M, Demo Ž. 2005: The frequency and distribution of caries in the mediaeval population of Bijelo Brdo in Croatia (10th-11th century). Arch Oral Biol 50:669-80.
12. Vodanović M, Demo Ž, Njemirovskij V, Keros J, Brkić H. 2007: Odontometrics: a useful method for sex determination in an archaeological skeletal population? J Arch Sc 34:905-13.
13. Whittaker DK, MacDonald DG. 1989: A Colour Atlas of Forensic Dentistry. Wolfe Publishing, Ipswich.
14. Zukanović A, Mulaomerović J, Marjanović D. 2007: Results of paleostomatological analysis of material from the cave near Gornji Vakuf (South-west Bosnia). Acta Carsologica 36:485-92.

SAŽETAK

U radu su prezenitrani rezultati paleokulturalnih i paleodontoloških istraživanja iz Pećine br. 5, smještene u blizini sela Bistrica i Krupa kod Gornjeg Vakufa, na području jugozapadne Bosne. Pećina je smještena na obroncima planine Vranice. U pećini su pronađeni skeletni ostaci najmanje dvadeset osoba, uključujući i evidentne tragove ljudske kulture iz različitih vremenskih razdoblja. Radiokarbonskom analizom uzoraka kostiju osteološki je materijal datiran na starost od 2765 ± 75 godina. Paleodontološka ispitivanja obavljena su na ukupno 36 zuba iz pećinske grobnice i uključivala su ispitivanja zubnog statusa, abrazije, prisutnosti razvojnih defekata cakline i odontometrijsku analizu.

Ključne riječi: paleodontologija, željezno doba, pećinska grobnica, Bosna i Hercegovina

Acknowledgements

This research was supported by the International Association for Paleodontology (www.paleodontology.com).

Our thanks goes to Professor Damir Marjanović and the Institute for Genetic Engineering and Biotechnology, University of Sarajevo for making ^{14}C analysis possible, to Ana Bakšić from the Speleological Section of PDS Velebit, Croatia for providing the map of the cave, to all participants of the speleological explorations, and to the local municipality for support during explorations.