

Symmetry of mental foramen in a Croatian archaeological sample

Pavušek, Ivan; Šimović, Marija; Vodanović, Marin

Source / Izvornik: **Bulletin of the International Association for Paleodontology, 2014, 8, 233 - 243**

Journal article, Published version

Rad u časopisu, Objavljena verzija rada (izdavačev PDF)

Permanent link / Trajna poveznica: <https://um.nsk.hr/um:nbn:hr:127:100055>

Rights / Prava: [Attribution-NonCommercial-NoDerivatives 4.0 International](#)/[Imenovanje-Nekomercijalno-Bez prerada 4.0 međunarodna](#)

Download date / Datum preuzimanja: **2024-05-16**



Repository / Repozitorij:

[University of Zagreb School of Dental Medicine Repository](#)



Symmetry of mental foramen in a Croatian archaeological sample

• Ivan Pavušek (1), Marija Šimović (1), Marin Vodanović (2) •

1- Students of the School of Dental Medicine University of Zagreb

2- Department of Dental Anthropology School of Dental Medicine University of Zagreb

Address for correspondence:

Marin Vodanović

University of Zagreb School of Dental Medicine

Department of Dental Anthropology

Gundulićeva 5, HR-10000 Zagreb, Croatia

E-mail: vodanovic@sfzg.hr

Bull Int Assoc Paleodont. 2014;8(2):233-243.

Abstract

The purpose of this research is to analyze the symmetry of mental foramen due to its size and location. The aim is to obtain data on the size and position of the foramen on skeletal Croatian population, and to determine whether there are differences between the left and right side of the jaw or between men and women. The study was conducted on digital photographs of skeletal remains of 54 adult mandibles (27 women and 27 men) recorded in standard lateral projection. Position of mental foramen is defined by the following average values: distance from mental foramen to the alveolar ridge of the mandible was 12.33 mm, to the lower edge of mandible 11.03 mm, to mental protuber 11.8mm, to the angle of the mandible 57.26mm. Average values for mesiodistal diameters were 2.29 mm, craniocaudal diameter 1.78 mm and scope of mental foramen 5.94 mm. The study did not show any statistically significant difference between the left and right side of the position and dimensions of mental foramen. There is a statistically significant difference between males and females.

Keywords: Mental foramen; Paleodontology; Croatia

Introduction

Mental foramen marks the end of the mandibular canal in the mandible where the lower alveolar nerve is located. In this part of the mandibular canal the canal branches and creates a mental and incisive canal. Mental nerve passes through mental foramen and innervates the soft tissue of the chin, lower lip and gingiva on the same side of the jaw. There is a MF on each side of the jaw through which travel the mental arteries and veins and mental nerve. Number of nerves can vary between individuals, between one and three (1). There have been described the existence of more MF and in rare cases MF can be absent (2). MF can be oval or round in shape and is usually bilateral but may be unilateral. Finding the correct position of MF is usually a very difficult. Generally it is described as in the projection of the second premolar or between the first and second premolars halfway between the border of the mandible and the alveolar ridge and has posterosuperior orientation. However the position of the hole varies so it can be placed between the apex of the lower premolar or below the apex of the second lower premolar (1). Failure to locate the MF can lead to failure when administering local anaesthesia, but also to difficulties when performing other operational procedures (3). In terms of the size Phillips et al. have shown that the average size of the foramen is 4.6 mm horizontally and 3.4 mm vertically. As far as the horizontal relationship between MF and lower teeth many studies have shown that the most common position is below the second premolar (1). Phillips et al showed that MF is usually mesial and below the x-ray apex of the second premolar (1). Localization and dimensions of the chin opening of the lower jaw are essential in cases of local and conduction anaesthesia on mental nerve which may be necessary when performing various dental procedures. Extraoral orthopantomogram has gained popularity in the last four decades. Advantages of this technique versus intraoral radiography is that orthopantomogram has a larger area of coverage and continuity. The ability to view the entire corpus should allow for more accurate location of the MF in both horizontal and vertical dimension. Orthopantomogram is therefore often used when planning the therapy of dental implants (4).

Based on the X-ray appearance MF is classified by Yosue and Brooks (5) into four types:

- Type I: MF goes continuously with the mandibular canal
- Type II: MF is clearly separated from the mandibular canal
- Type III: diffuse with a pronounced border opening
- Type IV: "unidentified group"

Materials and methods

The study was conducted on digital photographs of skeletal remains of mandible recorded in a standard lateral projection. We analysed images of 54 adults (27 women and 27 men) which are in

the archives of the Institute of Dental Anthropology, Faculty of Dentistry, University of Zagreb. Mandibles are of archaeological origin from areas Privlake, Osijek, Sibenik and Glavice. Children were excluded from the study. All measurements were made with a computer program to extract data from the graphic objects VistaMetrix, SkillCrest, USA. Before each measurement was performed the program was calibrated according to the forensic scale which was in every digital photo.

The following measurements were conducted:

1. Maximum mesiodistal diameter of the MF (MD)
2. Maximum craniocaudal diameter of the MF (KK)
3. Distance from the MF to the upper edge of the alveolar ridge (AG)
4. Distance from the MF to the lower border of the mandible (DR)
5. Distance from the MF to the protuberancia of mandible (PM)
6. Distance from the MF to the angulus mandible (AM)
7. Circumference of MF

Measurements were made on the left and right side of the lower jaw. Statistical analysis was performed with the computer program Statistica for Windows 5.0, StatSoft Inc. Tulsa, USA. Incorporating descriptive statistics. The difference between the observed variables was tested by Student's t-test for independent samples. The level of significance was set at p value <0.05.

Results

Results of mean values and standard deviations of the position and shape of the MF in males are shown in Table 1 and women in Table 2

Statistical analysis found no statistically significant differences between the observed parameters with respect to the side of the jaw (Figure 1, Figure 2) nor in men or women. From this we can conclude that MF is symmetrical in both males and females on the left or right side of the jaw with respect to the size and position.

Student's t-test showed that there were statistically significant differences between the individual parameters between men and women (Figure 3, Figure 4). In men with statistically significantly higher:

- MF distance to the alveolar ridge right side (p <0.05)
- MF distance to the bottom edge of the right and left sides (p <0.05)

- MF distance to the angle of the mandible right side ($p < 0.05$)

In women mesiodistal diameter of MF on left side of the jaw was statistically significantly bigger ($p < 0.05$).

Given that these are measurements on digital photographs, rather than the skeletal remains obtained results were further checked in a way that the results of measurements made on digital images were compared with the results of measurements on the skeletal remains. Statistical analysis revealed no statistically significant differences.

Discussion

The position and size of the chin openings are important because they affect the choice of therapy in oral surgery and prosthetics especially for implant placement and in planning removable dentures (6,7). The position of the chin and the aperture can vary (8,9) and after the loss of teeth and resorption of the alveolar ridge its position is lower (10). It was proved by Ulm et al. (11) in a study where after tooth extraction and bone resorption mental opening was closer to the alveolar ridge. To avoid nerve damage and associated vascular structures the distance between the anterior border of the chin and the aperture of the implant must be allowed a certain safety margin. Also finding the foramen is difficult but despite that anaesthesia is mostly successful which can be attributed to permeation of nerve fibres located in the soft tissue of the chin area (12). Damage to the mental nerve can cause paraesthesia, decreased sensation, increased sensitivity or complete loss of sensation in the teeth, lower lip and the surrounding tissue (13) which may complicate function of the lower jaw such as chewing, speech and create problems in maintaining hygiene (14).

Compared to the study of Apinhasmit et al. (15) where the average value of the distance from the mouth to the chin mental protuber was 28.83 mm, the distance from the chin to the opening to the angle of the mandible was 68.85 mm and the distance from the chin to the bottom edge of the opening of the lower jaw was 14.88 mm. Kane et al. (16) measured the average value for the distance from the chin to the bottom edge of the opening of the lower jaw 14.2 mm and the distance from the chin to the opening of the alveolar ridge of the lower jaw 19.3 mm. According to Phillips and colleagues (1) the average value of the mesiodistal diameter is 4.6 mm and craniocaudal diameter 3.4 mm. According Vodanović (17) distance from the chin to the bottom edge of the opening of the lower jaw was 13.0 mm, the distance from the chin to the opening of the alveolar ridge was 16.4 mm, mesiodistal diameter 4.9 mm and 3.4 mm was the craniocaudal diameter. Bohte (18) measured the left mesiodistal diameter, craniocaudal diameter and distance from the chin to the opening angle of the mandible with the 3.89 mm, 2.41 mm and 63.62 mm and the right mesiodistal diameter, craniocaudal diameter and distance from the chin to the opening angle of the mandible with 3.83 mm, 2.38 mm and 63.48 mm. According Igbigbi (19) distance from the chin to the bottom edge of the opening of the lower jaw was 13.36 mm, the distance from the chin to the opening of the alveolar ridge 13.37 mm, the distance

from the mouth to the chin protuber of mandible 26.4 mm, the distance from the chin opening to the angle of the mandible 73.58 mm. All the above studies have measured higher values for all parameters than in this study. The difference between the data obtained in this study and the data of other authors can be explained by the fact that this study was done on digital photographs, not the skeletal remains. Although additional measurements carried out on the same samples determined no difference in the results obtained by measuring the photos or skeletal remains. Larger sample is needed for the resulting data and conclusions to be reliable. The study showed no statistically significant difference between the left and right side. According Vodanović (17) no statistically significant differences in the measurements of the lower jaw between the left and right side were observed. In the study t - test showed that there were significant differences between men and women. Males have larger parameters for the right distance from the chin to the opening of the alveolar ridge of the mandible, distance from the chin to the lower edge of the opening of the mandible from the chin and distance from mental opening to the angulus of mandible and left distance from the chin to the bottom edge of the opening of the lower jaw. Women have higher values for the parameter of the left mesiodistal diameter. According Vodanović (17) all measured values of males are larger than those measured in females. According Bohte (18) values for the distance to the right side of the alveolar ridge and the distance from the angle of the mandible on right and left sides are higher in men and the values of the left and right mesiodistal diameter and left craniocaudal diameter were higher in females.

Conclusion

The study did not show any statistically significant difference between the left and right side of the jaw with respect to the size and position of the mental foramen in men as well as women. However it was found statistically significant differences between men and women in some observed parameters. In men demonstrated greater distances MF to the right side of the alveolar ridge, the distance to the bottom edge of the right and left sides and the distance to the angle of the mandible on the right side. Women demonstrated greater mesiodistal diameter of MF on the left side.

	N	Mean value (mm)	Standard deviation (mm)
right maximum mesiodistal diameter of the MF	27	2,24	0,72
left maximum mesiodistal diameter of the MF	27	2,06	0,55
right maximum craniocaudal diameter of the MF	27	1,72	0,56
left maximum craniocaudal diameter of the MF	25	1,76	0,62
right distance from alveolar ridge	27	13,26	2,54
left distance from alveolar ridge	25	12,48	2,89
right distance from the MF to the lower border of the mandible	27	11,61	1,65
left distance from the MF to the lower border of the mandible	25	11,93	1,99
right distance from the MF to the protuberancia of mandible	27	11,98	2,66
left distance from the MF to the protuberancia of mandible	25	10,74	3,03
right distance from the MF to the angulus mandible	24	59,35	7,6
left distance from the MF to the angulus mandible	24	58,46	6,19
right circumference of MF	27	5,78	1,53
left circumference of MF	25	5,63	1,41

Table 1. Mean values and standard deviations of the position and shape of the MF in males

	N	Mean value (mm)	Standard deviation (mm)
right maximum mesiodistal diameter of the MF	27	2,4	0,91
left maximum mesiodistal diameter of the MF	26	2,46	0,74
right maximum craniocaudal diameter of the MF	27	1,86	0,74
left maximum craniocaudal diameter of the MF	26	1,79	0,69
right distance from alveolar ridge	27	11,47	2,36
left distance from alveolar ridge	26	11,9	2,34
right distance from the MF to the lower border of the mandible	27	10,71	1,54
left distance from the MF to the lower border of the mandible	26	10,97	0,87
right distance from the MF to the protuberancia of mandible	27	12,38	3,17
left distance from the MF to the protuberancia of mandible	26	12,1	2,62
right distance from the MF to the angulus mandible	25	55,28	3,9
left distance from the MF to the angulus mandible	22	55,93	3,27
right circumference of MF	27	6,1	2,14
left circumference of MF	26	6,25	1,72

Table 2. Mean values and standard deviations of the position and shape of the MF in females

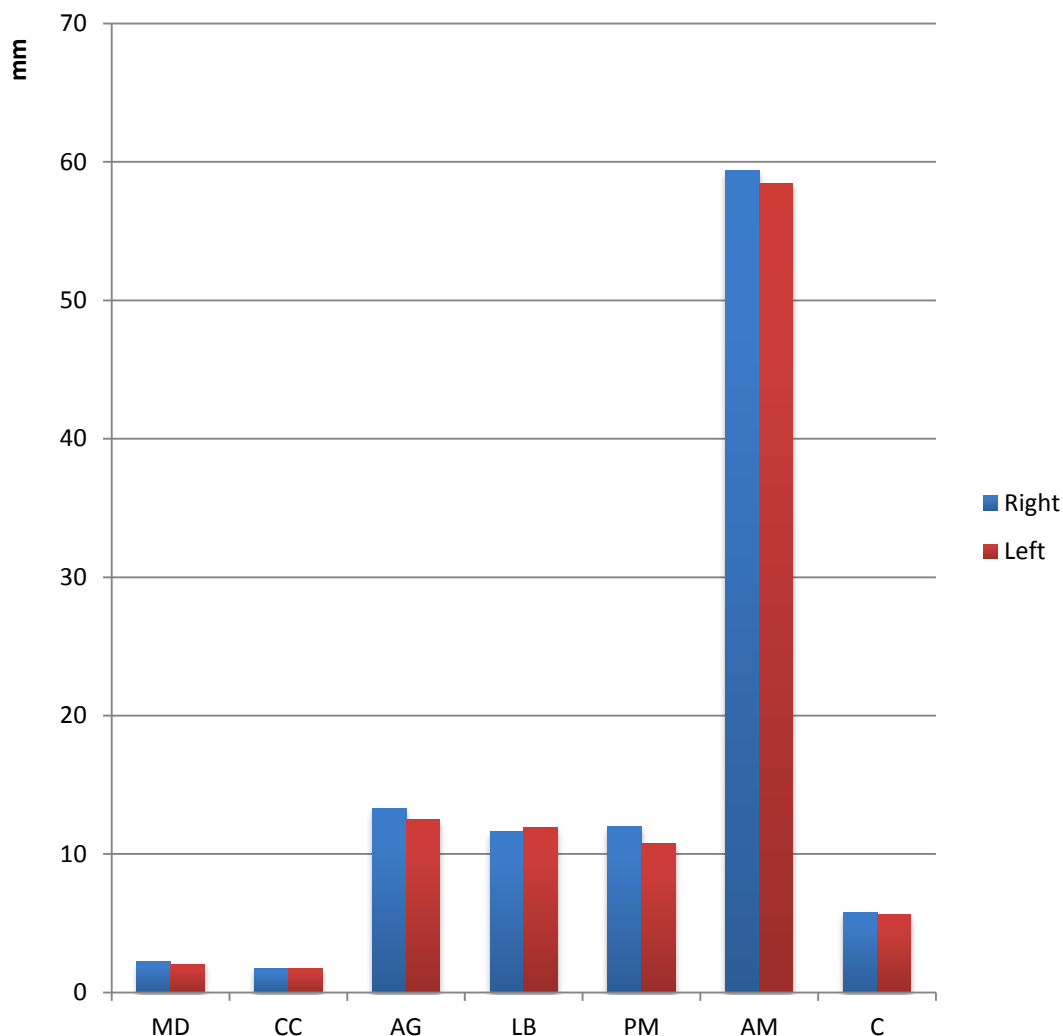


Figure 1. Comparison of parameters of left and right side in men

MD - Maximum mesiodistal diameter of the MF

CC - Maximum craniocaudal diameter of the MF

AG - Distance from the MF to the upper edge of the alveolar ridge

LB - Distance from the MF to the lower border of the mandible

PM - Distance from the MF to the protuberancia of mandible

AM - Distance from the MF to the angulus mandible

C - Circumference of MF

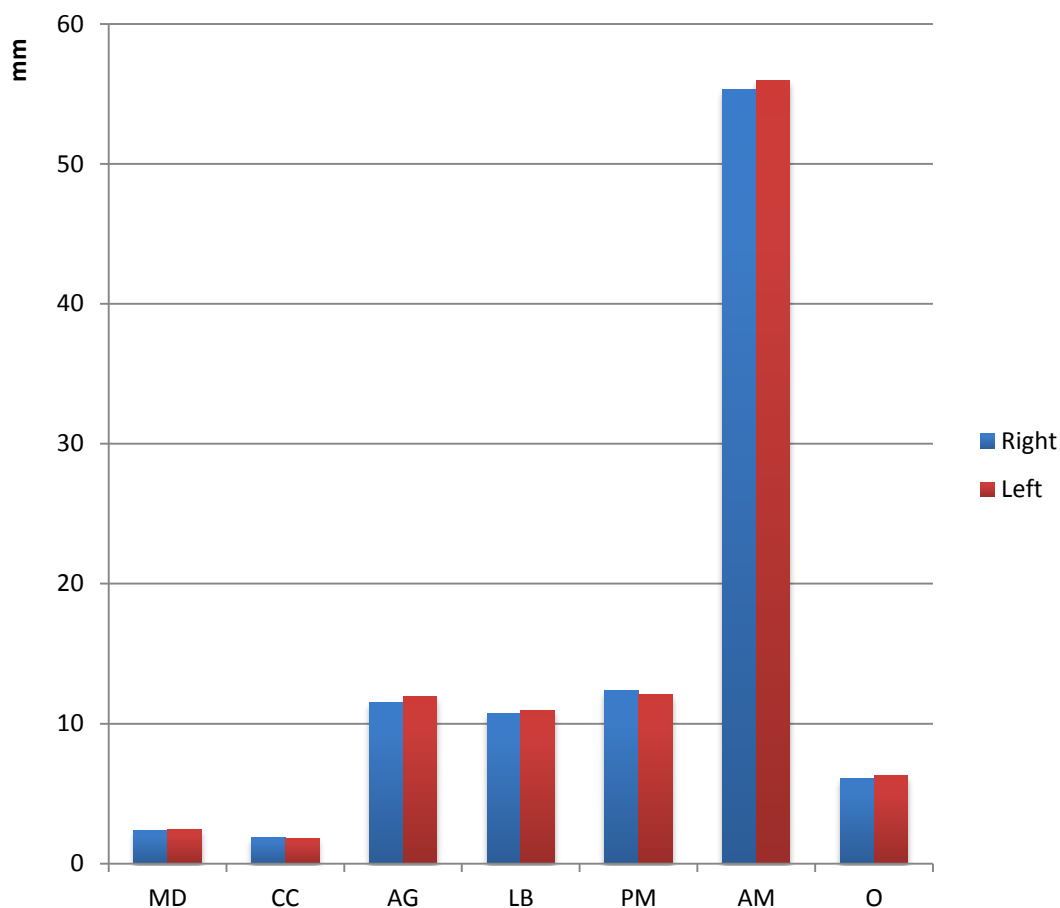


Figure 2. Comparison of parameters of left and right side in women

MD - Maximum mesiodistal diameter of the MF

CC - Maximum craniocaudal diameter of the MF

AG - Distance from the MF to the upper edge of the alveolar ridge

LB - Distance from the MF to the lower border of the mandible

PM - Distance from the MF to the protuberancia of mandible

AM - Distance from the MF to the angulus mandible

C - Circumference of MF

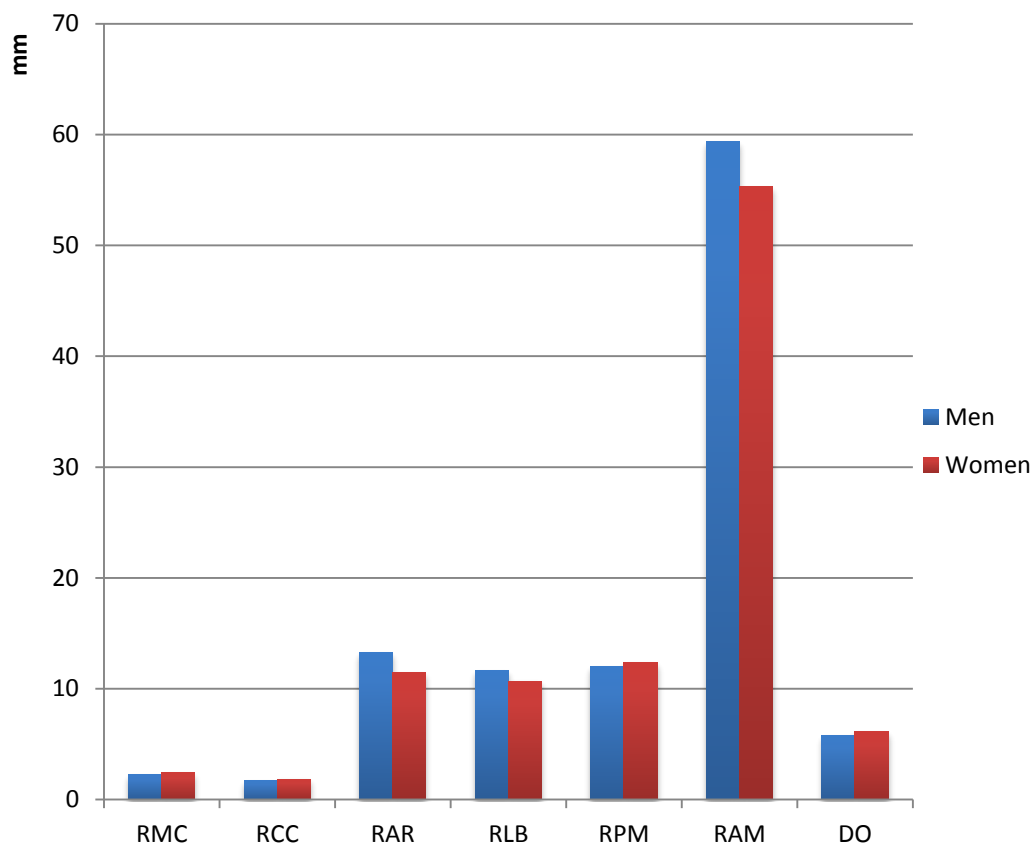


Figure 3. Comparison of parameters of right side between man and women

RMD – right maximum mesiodistal diameter of the MF
 RCC – right maximum craniocaudal diameter of the MF
 RAR – right distance from alveolar ridge
 RLB – right distance from the MF to the lower border of the mandible
 RPM – right distance from the MF to the protuberancia of mandible
 RAM – right distance from the MF to the angulus mandible
 RC – right circumference of MF

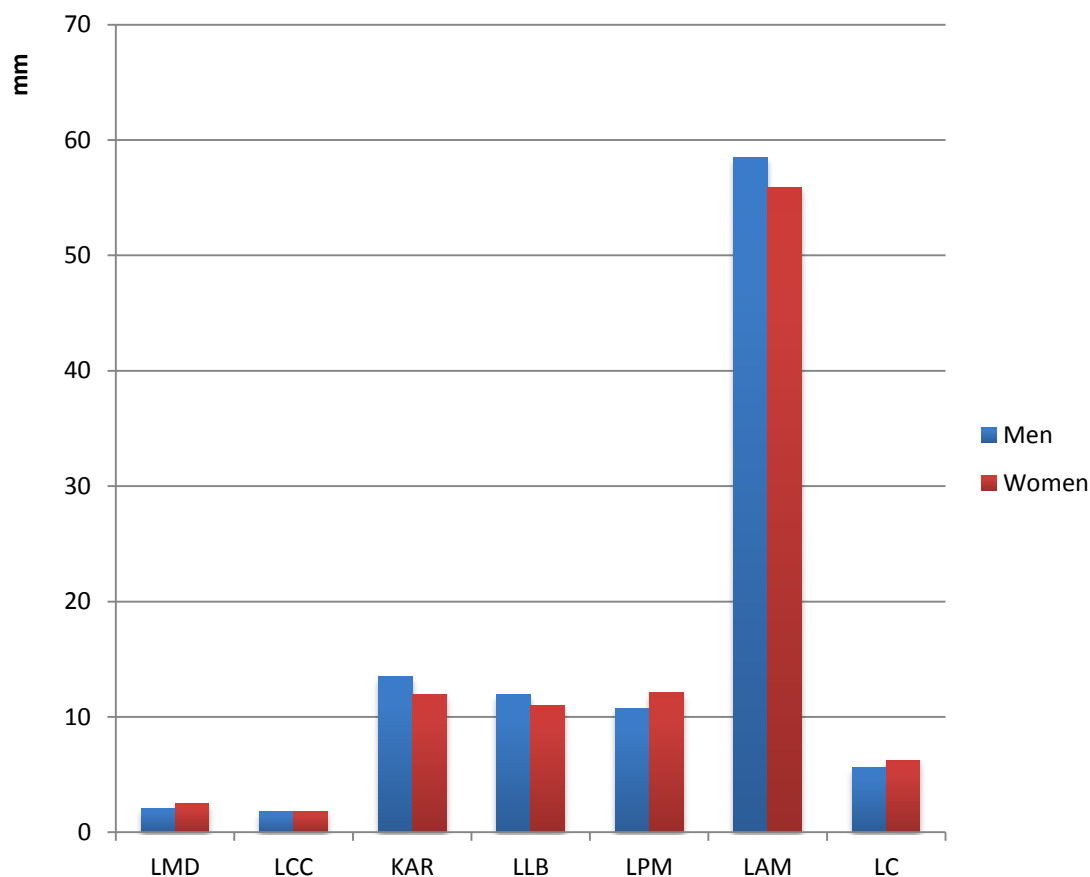


Figure 4. Comparison of parameters of left side between man and women

LMD – right maximum mesiodistal diameter of the MF

LCC – right maximum craniocaudal diameter of the MF

LAR – right distance from alveolar ridge

LLB – right distance from the MF to the lower border of the mandible

LPM – right distance from the MF to the protuberancia of mandible

LAM – right distance from the MF to the angulus mandible

LC – right circumference of MF

References

1. Phillips JL, Weller RN, Kulild JC. The mental foramen: 1. Size, orientation, and positional relationship to the mandibular second premolar. *J Endod.* 1990 May;16(5):221-3.
2. Al Jasser NM, Nwoku AL. Radiographic study of the mental foramen in a selected Saudi population. *Dentomaxillofac Radiol.* 1998 Nov;27(6):341-3.
3. Yeşilyurt H, Aydinlioglu A, Kavakli A, Ekinci N, Eroglu C, Hacıaliogullari M, Diyarbakirli S. Local differences in the position of the mental foramen., *Folia Morphol (Warsz).* 2008 Feb;67(1):32-5.
4. Gungor K, Ozturk M, Semiz M, Brooks SL. A radiographic study of location of mental foramen in a selected Turkish population on panoramic radiograph., *Coll Antropol.* 2006 Dec;30(4):801-5.
4. Yosue T, Brooks SL. The appearance of mental foramina on panoramic radiographs. I. Evaluation of patients. *Oral Surg Oral Med Oral Pathol.* 1989 Sep;68(3):360-4.

6. Bou Serhal C, Jacobs R, Flygare L, Quirynen M, van Steenberghe D. Perioperative validation of localisation of the mental foramen. *Dentomaxillofac Radiol.* 2002 Jan;31(1):39-43.
7. Güler AU, Sumer M, Sumer P, Biçer I. The evaluation of vertical heights of maxillary and mandibular bones and the location of anatomic landmarks in panoramic radiographs of edentulous patients for implant dentistry. *J Oral Rehabil.* 2005 Oct;32(10):741-6.
8. Rouas P, Nancy J, Bar D. Identification of double mandibular canals: literature review and three case reports with CT scans and cone beam CT. *Dentomaxillofac Radiol.* 2007 Jan;36(1):34-8.
9. Greenstein G, Tarnow D. The mental foramen and nerve: clinical and anatomical factors related to dental implant placement: a literature review. *J Periodontol.* 2006 Dec;77(12):1933-43.
10. Lindhe J. *Klinička parodontologija i dentalna implantologija.* Zagreb: Nakladni Zavod Globus; 2004.
11. Ulm CW, Solar P, Blahout R, Matejka M, Watzek G, Gruber H. Location of the mandibular canal within the atrophic mandible. *Br J Oral Maxillofac Surg.* 1993 Dec;31(6):370-5.
12. Mihelić Z. *Morfološka i klinička podloga provodne anestezije u stomatologiji [doktorska disertacija].* Zagreb: Stomatološki fakultet sveučilišta u Zagrebu; 1996.
13. Bartling R, Freeman K, Kraut RA. The incidence of altered sensation of the mental nerve after mandibular implant placement. *J Oral Maxillofac Surg.* 1999 Dec;57(12):1408-12.
14. Wismeijer D, van Waas MA, Vermeeren JI, Kalk W. Patients' perception of sensory disturbances of the mental nerve before and after implant surgery: a prospective study of 110 patients. *Br J Oral Maxillofac Surg.* 1997 Aug;35(4):254-9.
15. Apinhasmit W., Methathathip D., Chompoopong S., Sangvichien S. Mental foramen in Thais: an anatomical variation related to gender and side. *Surg Radiol Anat.* 2006 Oct;28(5):529-33.
16. Kane AA, Lo LJ, Chen YR, Hsu KH, Noordhoff MS. The course of the inferior alveolar nerve in the normal human mandibular ramus and in patients presenting for cosmetic reduction of the mandibular angles. *Plast Reconstr Surg.* 2000 Oct;106(5):1162-74; discussion 1175-6.
17. Vodanović M. *Analiza stomatognatnog sustava srednjevjekovnog koštanog uzorka iz Bijelog Brda kod Osjeka [magistarski rad].* Zagreb: Stomatološki fakultet Sveučilišta u Zagrebu; 2005.
18. Bohte A. *Foramen mandibule i foramen mentale – različitost oblika i položaja [magistarski rad].* Zagreb Stomatološki fakultet Sveučilišta u Zagrebu; 2008.
19. Igbigbi PS, Lebona S. The position and dimensions of the mental foramen in adult Malawian mandibles. *West Afr J Med.* 2005 Jul-Sep;24(3):184-9.